



Case Report

Transrectal Ultra Sonography based evidence of *Ksharasutra* therapy for Fistula-in-ano – A case series

Aditya Nema, Sanjay Kumar Gupta*, Tukaram S. Dudhamal, Vyasadeva Mahanta

Dept. of Shalyatantra, I.P.G.T. & R.A., Gujarat Ayurved University, Jamnagar, Gujarat 361 008, India

ARTICLE INFO

Article history:

Received 11 June 2016

Received in revised form

4 November 2016

Accepted 28 January 2017

Available online 7 June 2017

Keywords:

Bhagandara

Fistula-in-ano

Ksharasutra

TRUS

ABSTRACT

Ksharasutra (parasurgical procedure using a thread treated by alkalies) is being practiced in Indian system of medicine since ancient time for management of ano-rectal disorders; particularly for Bhagandara, (fistula in ano), and generally difficult to treat. In this case series, standard *Ksharasutra* was prepared as per the Ayurvedic Pharmacopeia of India and used to treat the different cases of Bhagandara. In this case series total 6 patients of Bhagandara were treated with *Ksharasutra* and partial fistulectomy. The average Unit Cutting Time and healing (UCTH) was observed 7.86 days/cm. During treatment *Panchawalkala Kwatha* (decoction of five medicinal plant's bark), *Shatdhautaghrita*, *Jatyaditaila* and *Erandabhrishtaharitaki Churna* were used as adjuvant drugs. To generate quality evidence Transrectal Ultra Sonography (TRUS) was used in pre as well as post-treatment and showed remarkable tool to assess effect of treatment. Substantial clinical result was observed at the end of treatment and all the patients were free of fistula. No recurrence was observed in any case during the 12 follow up of 12 months. The treatment was reported safe and well tolerated in all the patients.

© 2017 Transdisciplinary University, Bangalore and World Ayurveda Foundation. Publishing Services by Elsevier B.V. This is an open access article under the CC BY-NC-ND license (<http://creativecommons.org/licenses/by-nc-nd/4.0/>).

1. Introduction

Bhagandara/Fistula-in-ano is a chronic abnormal communication, lined by unhealthy granulation tissue, runs from ano-rectum towards peri-anal skin presented as external opening on the perineum or buttock [1]. It is believed to be of crypto-glandular origin and most commonly fistulous tract is formed secondary to impaired drainage of anal glands [2]. It commonly produces pain, swelling, discharge, itching, social embarrassment etc. [3] Fistulectomy, fistulotomy and some new techniques like fibrin glue, fistula plug, Video Assisted Anal Fistula Treatment (VAAFT), Ligation of Inter-sphincteric Fistula Tract (LIFT) etc. are also available as treatment options with their own merits and demerits [4]. On the other hand, well accepted *Ksharasutra* therapy is available for Bhagandara with least rate of recurrence (3.33%) [5]. Sushruta has described application of *Kshara* (Ash of a plant, highly alkaline) in Bhagandara [6] and Charaka has mentioned of *Ksharasutra* whereas

Chakrapani and Bhavamishra have described detailed preparation and application of *Ksharasutra* in Bhagandara later on [7–9].

Transrectal Ultra Sonography (TRUS) has been accepted as a imaging modality to evaluate anomalies of lower rectum, anal sphincters, and pelvic floor in patients. Knowledge of normal ultrasonographic anatomy of rectal wall and anal canal with use of improved ultrasonographic transducer and three-dimensional (3D) imaging equipments are important foundation for determining various anorectal abnormalities (Fig. 1) [10].

2. Management

Total six patients (5 male and 1 female) of Bhagandara, 20–60 years of age, were treated with *Ksharasutra*. All patients were examined by TRUS to know details of the fistulous tract and related structures before intervention of *Ksharasutra* and same was repeated after completion of the treatment.

Routine physical examination and investigations for blood as well as urine examinations were done to determine fitness of patients for surgery. Necessary examinations were done to exclude tuberculosis, hypertension, diabetes mellitus, osteomyelitis, chronic or acute ulcerative colitis, Crohn's disease, malignancy,

* Corresponding author.

E-mail address: drskgupta17@gmail.com (S.K. Gupta).

Peer review under responsibility of Transdisciplinary University, Bangalore.

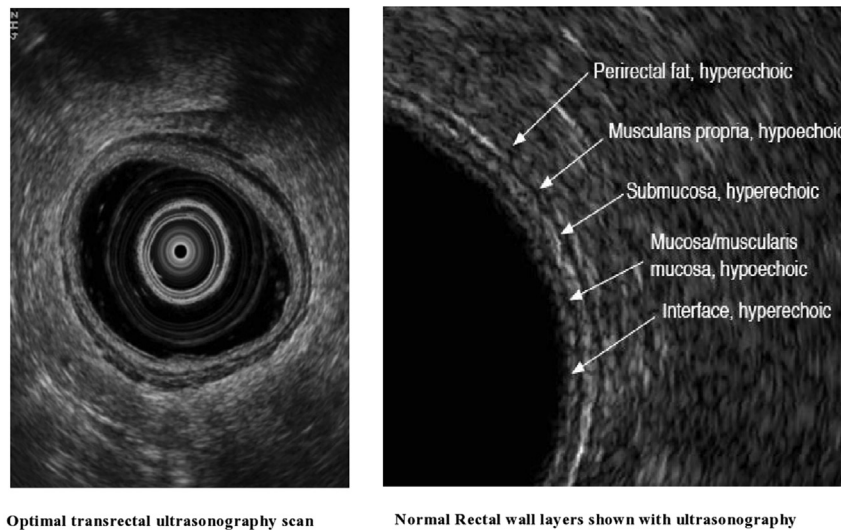


Fig. 1. Optimal and normal rectal wall layers with ultrasonography images.

venereal diseases, Australia antigen and pregnancy in female cases. The TRUS examination was performed at Vedant Imaging Center, Jamnagar by an expert radiologist (Dr. V. Karmura).

The *Ksharasutra* was prepared in Shalya Tantra department as per standard operative procedure (SOP) as mentioned below [11].

Preparation of *Ksharasutra*: The ingredients of *Ksharasutra* are Barbour linen thread no. 20, latex of *Snuhi* (*Euphorbia nerifolia* Linn.), *Apamarga Kshara* (Alkaline powder of *Achyranthes aspera* Linn.) and *Haridra Churna* (powder of *Curcuma longa* Linn.). The linen barber thread no. 20 was autoclaved and then it was mounted on hanger. Initial 11 coatings were done with latex of *Snuhi*; later on 7 coatings of latex of *Snuhi* and *Apamarga Kshara* were done. Finally 3 coatings of latex of *Snuhi* and *Haridra* powder were done. After every coating the hangers were kept in the *Ksharasutra* cabinet for drying and sterilization purpose. A total 21 coating were done. The *Apamarga Ksharasutra* was cut into pieces of 10 inch and each piece of *Ksharasutra* was packed in air tight glass tube.

Panchawalkala Kwatha, *Shatdhautaghrita*, *Jatyaditaila* and *Erandabhrishtaharitaki Churna* were prepared in the pharmacy of study centre and were used as adjuvant therapy.

Pre-operative: After taking written informed consent, peri-anal part was prepared for operative by routine method and a soap-water enema was given early in the morning on the day of operation. Injection of Tetanus Toxoid, 0.5 cc was given intra-muscularly and sensitivity test for injection xylocaine was also performed.

Operative procedure: After spinal anaesthesia, peri-anal skin was painted with Betadine solution and draped by a sterile cut sheet in lithotomy position. After performing partial excision of fistulous tract with the help of scalpel and electric cautery *Ksharasutra* was applied in the remaining part of tract. After achieving haemostasis, sterilized dressing with T-bandage was applied before shifting patient to the ward.

Post-operative: Suitable intravenous fluids, antibiotic and analgesic were given in post-operative period for initial 3–5 days. From next morning, patients were advised warm sitz bath with *Panchawalkala Kwatha* for 10–15 min, twice a day. Dressing with *Shatdhautaghrita* was done after instillation of 10 ml *Jatyaditaila* per rectum once daily. *Erandabhrishtaharitaki Churna*, 5 g with lukewarm water at bedtime daily was also prescribed.

***Ksharasutra* Change:** *Ksharasutra* was changed with a new one by rail-road technique at weekly interval. The progress of healing and length of thread was noted to assess the Unit Cutting Time and

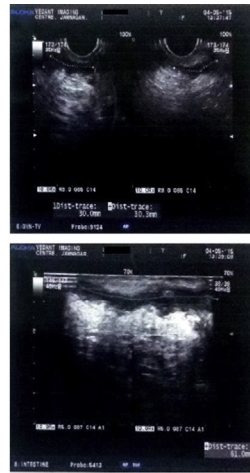Healing (UCTH) till the complete cure of fistulous tract was achieved.

Diet and lifestyle advice: Green and leafy vegetables, fruits and plenty of liquids were advised with routine non-spicy diet. Half an hour walk and routine work was allowed. Patient was also advised to avoid non-veg, junk foods, tobacco and alcohol consumption during course of treatment.

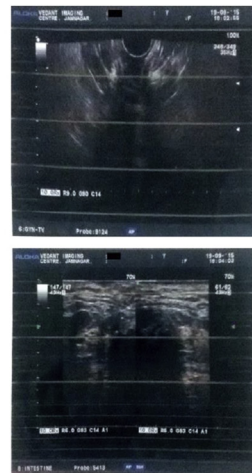
Common Protocol: The above said drugs, pre-operative, operative, post-operative, method of change of *Ksharasutra* and diet and lifestyle were same for all patients.

Case Report 01: A 35 year old male patient visited with complaints of peri-anal pain, pus discharge, constipation and intermittent fever, presented since last seven days. He was habituated to consume non-vegetarian diet, spicy foods and tobacco. On per rectal examination one external opening at 1 O'clock position, just below the scrotum was observed with discharging pus, pain and tenderness. After gentle probing from external opening, a tract was revealed which seemed to be connected with internal opening at 12 O'clock position in anal canal. It was confirmed by TRUS examination (Fig. 2a). Fistulous tract was partially excised and *Ksharasutra* threading was done in remaining part of the tract (Fig. 2c). The *Ksharasutra* was changed 08 times at weekly interval. It was healed completely in about two months (Fig. 2d). The UCTH of fistulous tract was 7.5 days per cm. After completion of treatment, TRUS examination was done again which revealed a healed scar in place of fistulous tract with no any other abnormality (Fig. 2b).

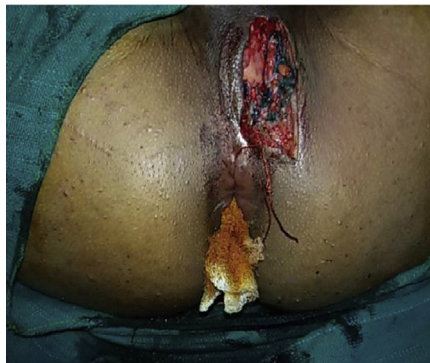Case Report 02: A 33 year old male patient visited with complaints of pain in anal canal during defecation and bleeding per rectal during defecation in drops with protrusion of mass which was self-reducible since last five years. There was on and off pus discharge with pain from an opening present at 12 O'clock position on peri-anal skin since last one week. Patient was not habituated to any addiction. On inspection uncomplicated external piles at 3, 7 and 9 O'clock positions were seen. On per rectal examination no spasm and no pain was noticed but a pit was felt at 12 O'clock position in anal canal. On proctoscopic examination, internal external piles at 3, 7 and 9 O'clock position were observed. A straight fistulous tract was revealed at 12 O'clock position on TRUS examination (Fig. 3a). All pile masses were ligated by *Ksharasutra* and in fistulous tract *Ksharasutra* threading was done (Fig. 3c). The *Ksharasutra* was changed 09 times on weekly interval. The tract was



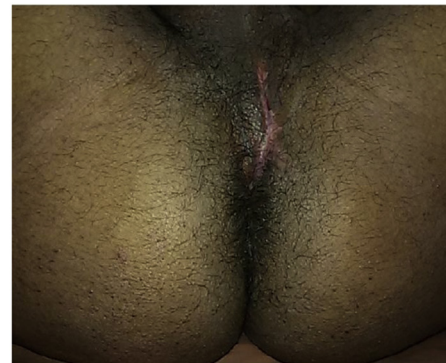
a.
60 MM LONG LINEAR NON BRANCHING FISTULA IS SEEN IN LEFT PERIANAL REGION WITH EXTERNAL OPENING AT 1 O'CLOCK POSITION AND INTERNAL OPENING AT 12 O'CLOCK POSITION. INTERNAL OPENING JUST PROXIMAL TO ANAL VERGE.



b.
SUBCUTANEOUS FIBROUS SCAR SEEN IN LEFT PERIANAL REGION AT THE SITE OF PREVIOUSLY NOTED FISTULA.
NO E/O PERINAL ABSCESS AND FISTULA



c. Post-Operative



d. After Complete Remission

Fig. 2. a: Case 1-Pre-operative TRUS image. b: Case 1-Post-operative TRUS image. c: Case 1-Post-operative picture of *Ksharasutra Threading*. d: Case 1-Picture after complete remission.

completely healed in about two months (Fig. 3d). The UCTH was 8.75 days per cm and patient was observed to be completely cured and on TRUS examination, a healthy scar was revealed in place of fistulous tract without any other abnormality (Fig. 3b).

Case Report 03: A 45 year old male patient visited with complaints of peri-anal swelling with painless pus discharge with feeling of passing gas from an external opening present at 4 O'clock position since last two months. Patient had the history of chronic constipation and habituated for spicy food but no any addiction. On examination, one external opening at 4 O'clock position, approx. 2 cm away from anal verge was noted. After gentle probing, a tract was revealed, seemed to be connected internally at 6 O'clock position in anal canal. It was confirmed by TRUS examination (Fig. 4a). That tract was partially excised and *Ksharasutra* threading was done (Fig. 4c). The *Ksharasutra* was changed 08 times on weekly interval. The UCTH of fistulous tract was 7 days per cm. In that case, fistulous tract was completely cured in about two and half months (Fig. 4d). Patient got complete relief and TRUS report was found normal (Fig. 4b).

Case Report 04: A 27 year old male patient visited with complaints of peri-anal swelling, pain, pus discharge and itching since last one and half month. Patient had irregular bowel habit and no any history of addiction. On examination, one external opening was present at 11 O'clock position, approximately 2 cm away from the anal verge. After probing, a tract was revealed which seemed to be connected with internal opening at 8 O'clock position. It was confirmed by TRUS examination (Fig. 5a). The fistulous tract was partially excised and *Ksharasutra* threading was done in the remaining part of the tract (Fig. 5c). The *Ksharasutra* was changed 12 times on weekly interval. The UCTH of fistulous tract was 9.6 days per cm. The tract was completely healed in about three months (Fig. 5d). Patient got complete relief and post-treatment TRUS report was suggestive of normal configuration except the finding of a healthy scar in place of fistulous tract (Fig. 5b).

Case Report 05: There was a 60 year old female patient having complaints of peri-anal swelling, pain and pus discharge from an external opening present near the anus since last two months with no history of addiction. On examination, one external opening at 9

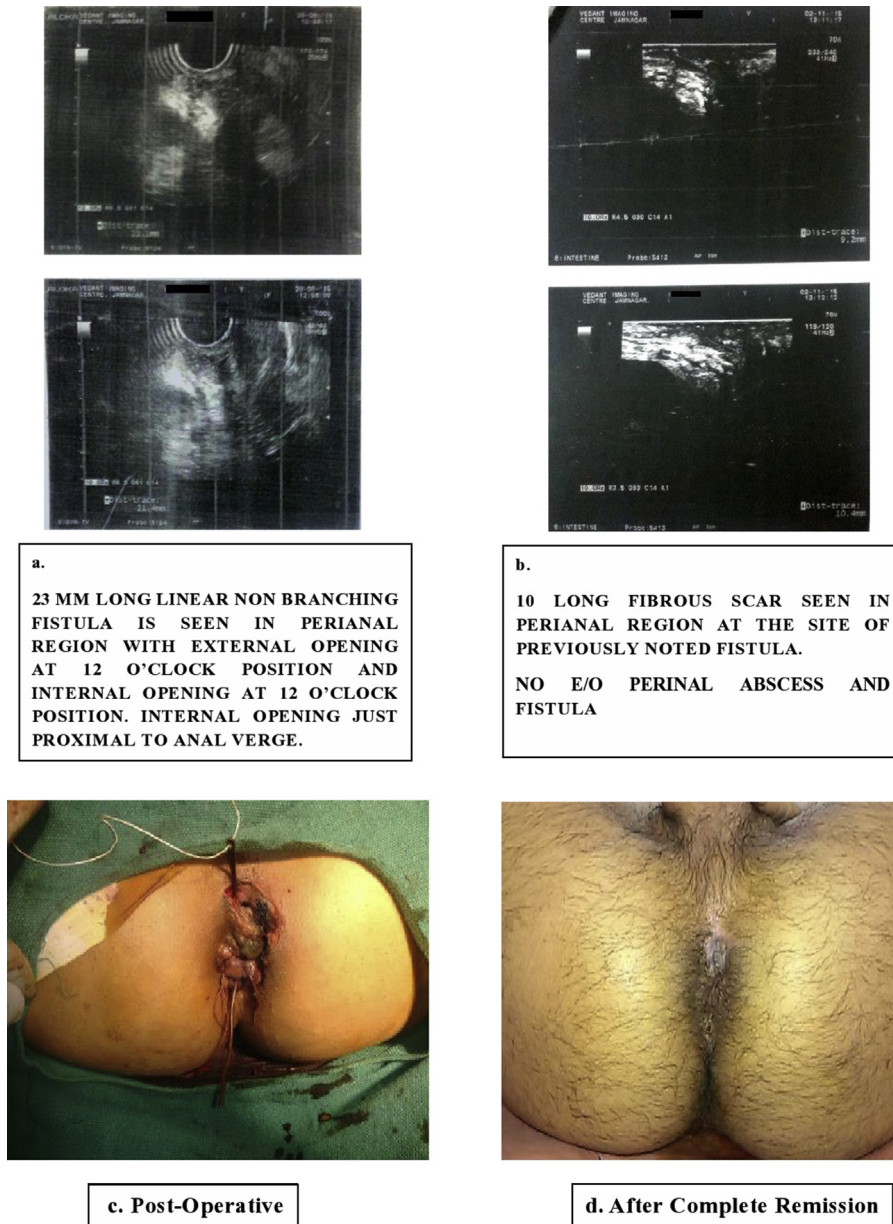


Fig. 3. a: Case 2-Pre-operative TRUS image. b: Case 2-Post-operative TRUS image. c: Case 2-Post-operative picture of *Ksharasutra* Threading. d: Case 2-Picture after complete remission.

O'clock position, approximately 2 cm away from the anal verge was observed. After probing, a tract was revealed which seemed to be connected with internal opening present at 11 O'clock position in anal canal. It was confirmed by TRUS examination (Fig. 6a). Fistulous tract was partially excised and *Ksharasutra* threading was done in rest of the tract (Fig. 6c). The *Ksharasutra* was changed 11 times on weekly interval. The UCTH of fistulous tract was 8.36 days per cm and it was healed completely in about three months (Fig. 6d) and TRUS report revealed absence of fistulous tract except a scar (Fig. 6b).

Case Report 06: A 45 year old male patient visited with complaints of peri-anal swelling, pain and pus discharge on and off since last five years. He was operated for piles five years back. He had no history of any addiction. On examination, one external opening at 11 O'clock position, approximately two and half cm away from the anal verge was observed. After probing the opening, a fistulous tract was revealed which seemed to be connected with

internal opening at 12 O'clock position. It was confirmed by TRUS examination (Fig. 7a). Fistulous tract was partially excised and *Ksharasutra* threading was done in rest of the tract (Fig. 7c). The UCTH of fistulous tract was 6 days per cm. The *Ksharasutra* was changed 06 times on weekly interval. The fistulous tract was completely healed within one and half month (Fig. 7d). Patient got complete relief and post-treatment TRUS report has shown no evidence of fistula except a healthy scar (Fig. 7b).

3. Clinical observation

All patients were from Hindu community, three of them from service sector, two were businessmen and one was housewife. The clinical assessment was done by PR examination. The final assessment was confirmed at the end of the therapy by doing TRUS examination.

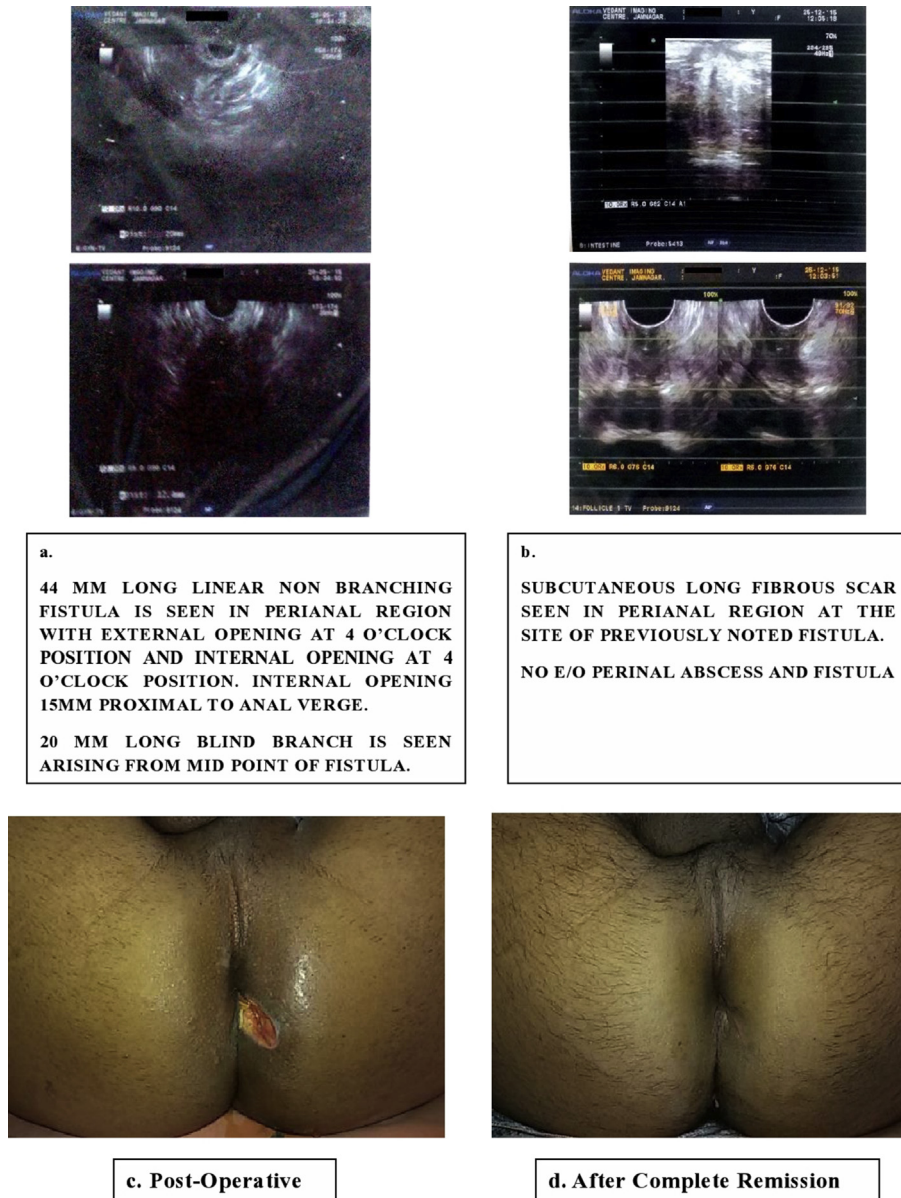


Fig. 4. a: Case 3-Pre-operative TRUS image. b: Case 3-Post-operative TRUS image. c: Case 3-Post-operative picture of *Ksharasutra Threading*. d: Case 3-Picture after complete remission.

On weekly assessment, all patients showed remarkable relief in features of swelling, pain, discharge and itching. There was healthy granulation, epithelisation and contraction of wound observed on every successive weekly assessment at the time of *Ksharasutra* change.

Finally, cut through of *Ksharasutra* followed by complete healing of fistulous tract was observed in all cases. Average UCTH was 7.86 days/cm. All patients underwent TRUS examination in post-treatment period and all 06 patients were reported either normal or with presence of residual healthy scar tissue or fibrous tissue in place of fistulous tract.

4. Discussion

In Ayurvedic classics, Bhagandara has been described as one of the *Ashtamahagada* i.e. eight difficult to cure diseases [12]. The *Ksharasutra* therapy has been in practice since long time with great

success rate with negligible recurrence rate for the management of Bhagandara. The Indian Council of Medical Research (ICMR) has conducted studies on *Ksharasutra* for management of fistula-in-ano and concluded that it is better than conventional fistulectomy/fistulotomy with minimum recurrence rate [13].

The applied *Kshara* on thread helps to slough out unhealthy tissue and facilitates cutting by dissolving the fibrous tissue. *Ksharasutra* helps to drain out contents of the tract. It also has anti-inflammatory and anti-microbial activities by virtue of its alkaline nature [14]. The cutting is presumed by local action of *Kshara* during initial 1–2 days of application followed by healing in rest of the 5–6 days before next change. Therefore, *Ksharasutra* helped to cut the fistulous tract by exerting mechanical pressure over the enclosed tissue and promoted healing side by side [15]. *Snuhi Ksheera* (Latex of *E. nerifolia* Linn.), acts as a binding agent in the *Ksharasutra* and is able to produce debridement of tissue by virtue of its proteolytic enzymes [16]. *Haridra Churna* (powder of

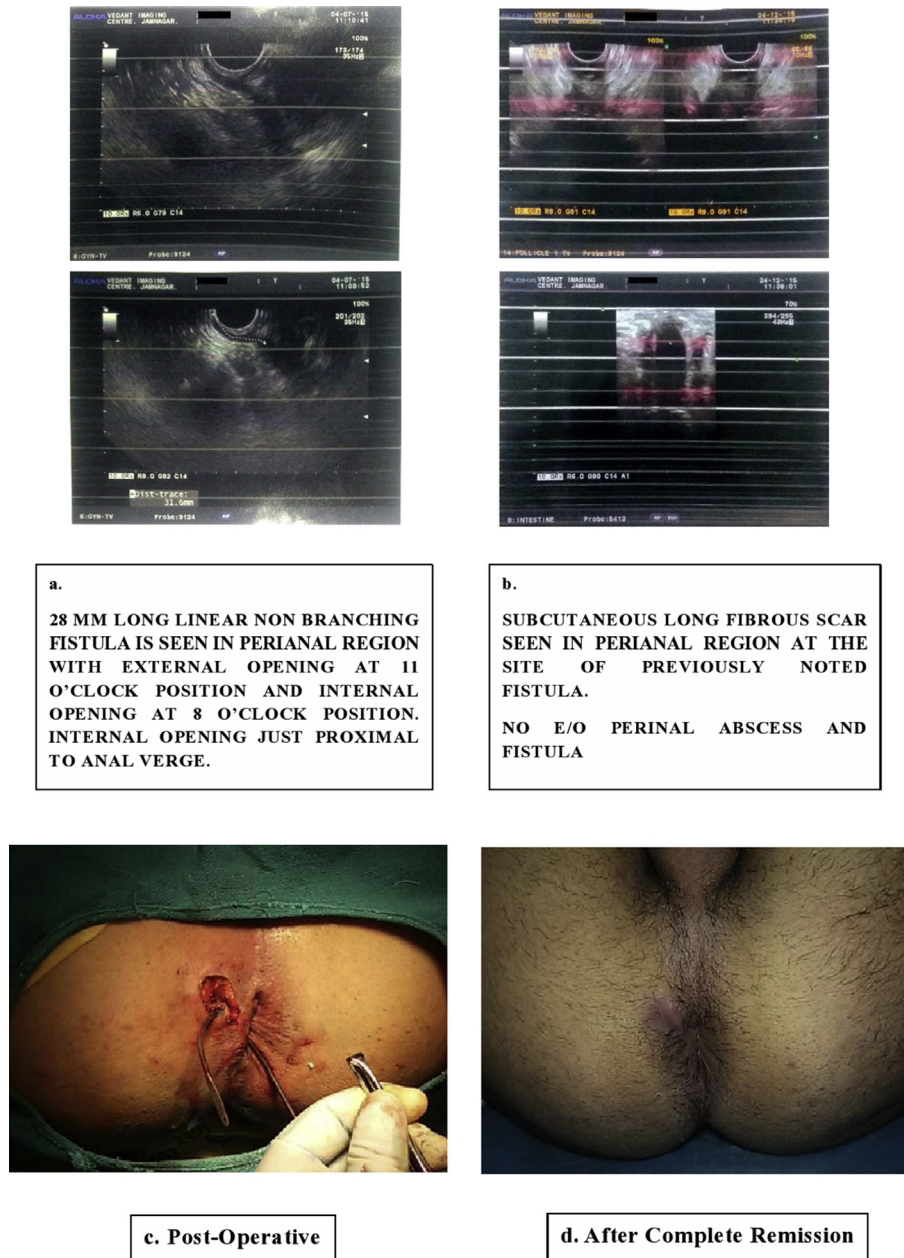


Fig. 5. a: Case 4-Pre-operative TRUS image. b: Case 4-Post-operative TRUS image. c: Case 4-Post-operative picture of *Ksharasutra Threading*. d: Case 4-Picture after complete remission.

C. longa Linn.) helps to reduce excessive *Shotha* (Inflammation) and promotes healing of the tract smoothly [17]. Hence, *Ksharasutra* has combined effect of all three drugs and is said to be unique drug formulation for cutting as well as healing of fistulous tract.

Panchawalkala Kwatha consists of decoction of bark of five trees: *Vata*/Indian Banyan (*Ficus bengalensis* Linn.), *Udumbar*/Indian fig tree (*Ficus glomerata* Roxb.), *Ashwattha* tree (*Ficus religiosa* Linn.), *Plaksha* (*Ficus lacor* Buch.), *Pakura*/Portia tree (*Thespesia populnea* Soland.). It has qualities of *Vrana Prakshalana* (Wound cleaning), *Shodhana* (Purifying), *Ropana* (Healing), *Shothahara* (Anti-inflammatory) and its *Kwatha* (Decoction) also has these properties which helped to keep wound healthy and promote healing uneventfully [18]. *Cow Ghrita* (Clarified butter) is known for an admirable *Sneha Dravya* (oily and fatty substances) due to its

Samskaranuvartana (acts like catalyst to increase the potency of another drug) and *Yogavahi* (synergetic effect) possessions [19]. *Cow Ghrita* has been well emphasised for its wound healing activity due to presence of Vitamin A which accelerates tissue healing, epithelialisation and improvement of skin texture. Presence of Omega 3 and Omega 6 in *Cow Ghrita* also regulate prostaglandin synthesis and hence induce tissue healing [20]. *Jatyaditaila* is also a good *Shodhana* and *Ropana* formulation recommended for the dressing of wounds. Per rectal instillation of *Jatyaditaila* acted as a soothing agent for smooth evacuation of faeces as well as it took care of wound created after partial excision of fistulous tract [21]. *Erandabhrishta Haritaki* is a combination of two ingredients, one is *Erand Taila* (castor oil) and another is *Haritaki* (*Terminalia chebula* Linn.) having properties of *Mridu Virechaka* (laxative) and helps to relieve constipation [22].

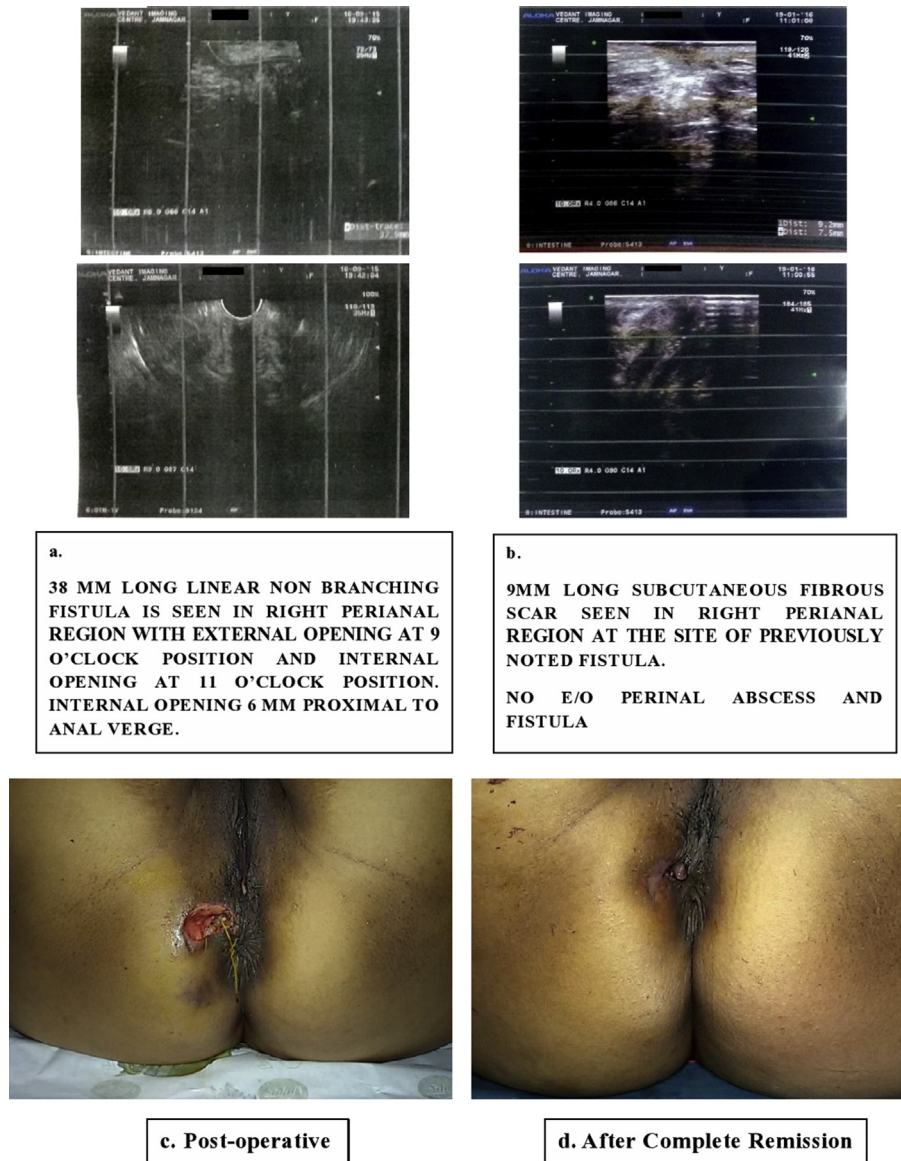


Fig. 6. a: Case 5-Pre-operative TRUS image. b: Case 5-Post-operative TRUS image. c: Case 5-Post-operative picture of *Ksharasutra* Threading. d: Case 5-Picture after complete remission.

Partial excision of the fistulous tract was done in all cases to reduce the length of the tract so that the total required time for complete healing of the tract could also be reduced.

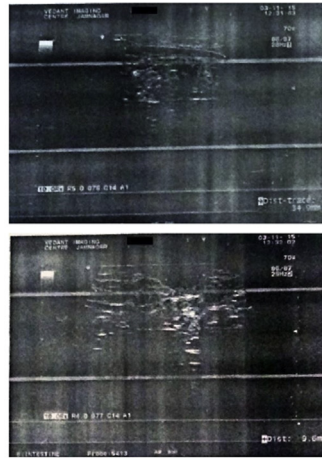
Transrectal Ultra Sonography (TRUS) is a minimally invasive technique performed with portable equipment. It accurately assesses the anal canal and related structures as well as pathologies. It provides critical findings of fistulous tract like multiple branches, calibration or malignant changes, etc. which are helpful for planning the appropriate treatment [10]. This investigation is helpful to improve the accuracy of diagnosis for anorectal diseases in general and particularly fistula-in-ano. It has accuracy to differentiate diagnosis up to 70%. Hence, TRUS examination carried out in this study, before as well as after intervention of *Ksharasutra*, definitely created an evidence to prove the efficacy of *Ksharasutra* in management of Bhagandara/Fistula-in-ano. Now-a-days, in reference to consumer protection act (CPA), it is very essential to maintain the records to face the medico-legal issue, if any, and this TRUS

investigation will definitely be helpful to document the evidence of diagnosis and treating fistula-in-ano. It can be considered as an extra benefit of TRUS which is cost effective and affordable in comparison to MRI.

Therefore, *Ksharasutra* therapy in fistula-in-ano is again proven better than conventional surgical procedures of fistulotomy/fistullectomy because it provided complete cure without any obvious complication or recurrence.

5. Conclusions

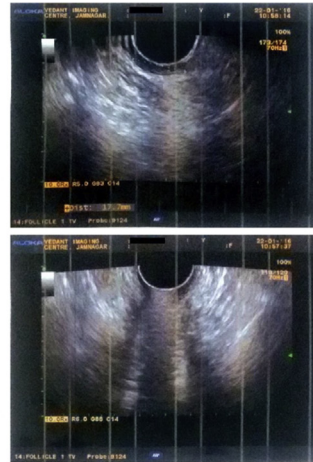
This case series of six patients has shown remarkable effect of *Ksharasutra* application in Bhagandara/fistula-in-ano with complete healing of fistulous tract without any obvious complication. The role of Transrectal Ultra Sonography (TRUS) to create an evidence to prove the effect of *Ksharasutra* therapy in managing the cases of Bhagandara/fistula-in-ano has been suggested.



a.

35 MM LONG LINEAR NON BRANCHING FISTULA IS SEEN IN RIGHT PERIANAL REGION WITH EXTERNAL OPENING AT 11 O'CLOCK POSITION AND INTERNAL OPENING AT 12 O'CLOCK POSITION. INTERNAL OPENING 6 MM PROXIMAL TO ANAL VERGE.

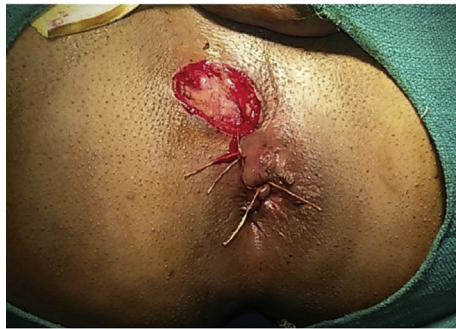UPPER AND LOWER ENDS OF FISULA WIDE IN CALIBER (9MM) AND SHOWS FLUID COLLECTION WITHIN.



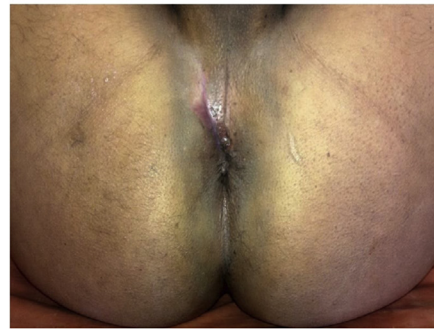
b.

SUBCUTANEOUS LONG FIBROUS SCAR SEEN IN PERIANAL REGION AT THE SITE OF PREVIOUSLY NOTED FISTULA.

NO E/O PERINAL ABSCESS AND FISTULA



c. Post-Operative



d. After Complete Remission

Fig. 7. a: Case 6-Pre-operative TRUS image. b: Case 6-Post-operative TRUS image. c: Case 6-Post-operative picture of *Ksharasutra Threading*. d: Case 6-Picture after complete remission.

Conflict of interest

None declared.

References

- [1] Williams NS, Bulstrode CJK, O'Connell PR, editors. Bailey & Love's short practice of surgery. The anus and anal canal. 26th ed. Boca Raton: CRC Press Taylor & Francis Group; 2013. p. 1259.
- [2] Goligher J, Duthie H, Nixon H. Surgery of the anus rectum and colon. Fistula-in-ano. 5th ed. Delhi: A.I.T.B.S Publishers & distributors; 2002. p. 178.
- [3] Jain SK, Kaza RCM, Pahwa M, Bansal S. Role of cyanoacrylate in the management of low fistula in ano: a prospective study. Int J Colorectal Dis 2008;23(4): 355–8.
- [4] Johnson EK, Gaw JU, Armstrong DN. Efficacy of anal fistula plug vs. fibrin glue in closure of anorectal fistulas. Dis Colon Rectum 2006;49(3):371–6.
- [5] Bhat RP. Ana fistula with foot extension treated by Ksharasutra (medicated seton) therapy: a rare case report. Int J Surg Case Rep 2013;4(7):573–6.
- [6] Shastri A, editor. Commentary Ayurved Tatva Sandipika on Sushruta Samhita of Sushruta Sootra Sthana; Ksharapakavidhi: chapter 11, verse 7. 12th ed. Varanasi: Chowkhamba Sanskrit Sansthan; 2001. p. 46.
- [7] Tripathi B, editor. Commentary Charak-Chandrika on Charaka Samhita of Charaka and Dradhala: Chikitsa Sthana; Shyavthuchikitsa: chapter 12, verse 97 Varanasi. Chowkhamba Sanskrit sansthan; 2009. p. 466.
- [8] Sharma PV, editor. Chakradatta of Chakrapani, Arshachikitsa; chapter 5, verse 148. 1th ed. Varanasi: Chowkhamba Sanskrit sansthan; 2007. p. 87.
- [9] Mishra BS, editor. Commentary Vidyotini on Bhavprakash of Bhavmishra: Madhya Khanda; Arshachikitsa: chapter 5, verse 144. 11th ed. Varanasi: Chowkhamba Sanskrit Bhavan; 2007. p. 66.
- [10] Kim MJ. Transrectal ultrasonography of anorectal diseases: advantages and disadvantages. Ultrasonography 2015;34:19–31.
- [11] Unanimously. In: Ayurvedic pharmacopia of India. Part-II. Ksharsootra (Medicated thread): chapter-51. 1st ed. Delhi: Published by AYUSH, Govt. of India; 2001. p. 209–13. II.
- [12] Shastri A, editor. Commentary Ayurved Tatva Sandipika on Sushruta Samhita of Sushruta Sootra Sthana; Ksharapakavidhi: chapter 33, verse 4. 12th ed. Varanasi: Chowkhamba Sanskrit Sansthan; 2001. p. 163.
- [13] Shukla NK, Narang R, Nair NG, Radhakrishna S, Satyavati GV. Multicentric randomized controlled clinical trial of Ksharasootra (Ayurvedic Medicated

- thread) in the management of Fistula in ano. *Indian J Med Res* 1991;94: 177–85.
- [14] Londonkar M, Reddy VC, Abhay Ku. Potential antibacterial and antifungal activity of *Achyranthes aspera* L. *Recent Res Sci Technol* 2011;3(4):53–7.
- [15] Faujdar HS, Mehta GG, Agarwal RK, Malpani NK. Management of fistula in ano. *J Postgrad Med* 1981;27(3):172–7.
- [16] Rath SK, Nagar L, Sinde A, Gahunge P, Lamo R, Khemani N. Review of source plants of Kshara for Kshara sutra preparation for the management of fistula-in-ano. *IJRAP* 2012;3(3):333–40.
- [17] Kohli K, Ali J, Ansari MJ, Raheman Z. Curcumin: a natural anti-inflammatory agent. *Indian J Pharmacol* 2005;37(3):141–7.
- [18] Meena RK, Dudhamal T, Gupta SK, Mahanta V. Wound healing potential of Pañcavalka formulations in a post-fistulectomy wound. *Anc Sci Life* 2015;35:118–21.
- [19] Tripathi B, editor. *Commentary Charak-Chandrika on Charaka Samhita of Charaka and Dradhbala: Sootra Sthana; Sneha-adhyaya: chapter 13, verse 13* Varanasi. Chowkhamba Sanskrit sanshthan; 2009. p. 264.
- [20] Barve M, Galib Prajapati PK. Shelf-life study of Shatadhauta Ghrita and Pan-chvalkala Siddha Shatadhauta Ghrita w.s.r. to its wound healing activity. PG Thesis. Jamnagar: Department of Rasshastra and Bhaisajya kalpana including Drug research, Gujarat Ayurveda University; 2011.
- [21] Dudhamal Tukaram, Bhuyan Chaturbhuj, Baghel Madhavsingh. Wound healing effect of Jatyadi Taila in the cases of chronic fissure-in-ano treated with Ksharasutra. *AYU* 2012;34(5):22.
- [22] Chunekar KC, Pandey GS, Bhavaprakash Nighantu. *Haritakyadi Varga*. Varanasi: Chaukhamba Bharatiya Academy; Re-print 2006. p. 5.