



Open Access

ORIGINAL ARTICLE

Operational Andrology

# Application and efficacy of reconstructing forked corpus spongiosum in distal/midshaft hypospadias repair

Bin Zhang, Yun-Li Bi, Shuang-Sui Ruan

We reviewed our experience in reconstructing forked corpus spongiosum (FCS) in distal/midshaft hypospadias repair and analyzed the efficacy of this surgical technique. From August 2013 to December 2018, 137 consecutive cases of distal/midshaft hypospadias operated by the same surgeon in Urology Department, Children's Hospital of Fudan University (Shanghai, China), were retrospectively analyzed. Sixty-four patients who underwent routine tubularized incised plate (TIP) or onlay island flap (ONLAY) surgery were included in the nonreconstructing group, and 73 patients who underwent reconstructing FCS during TIP or ONLAY surgery were included as the reconstructing group. Thirty-eight cases underwent TIP, and 26 underwent ONLAY in the nonreconstructing group, with a median follow-up of 44 (range: 30–70) months. Twenty-seven cases underwent TIP, and 46 underwent ONLAY in the reconstructing group, with a median follow-up of 15 (range: 6–27) months. In the nonreconstructing/reconstructing groups, the mean age at the time of surgery was 37.55 (standard deviation [s.d.]: 29.65)/35.23 (s.d.: 31.27) months, the mean operation duration was 91.95 (s.d.: 12.17)/93.84 (s.d.: 14.91) min, the mean neourethral length was 1.88 (s.d.: 0.53)/1.94 (s.d.: 0.53) cm, and the mean glans width was 11.83 (s.d.: 1.32)/11.56 (s.d.: 1.83) mm. Twelve (18.8%)/5 (6.8%) postoperative complications occurred in the nonreconstructing/reconstructing groups. These included fistula (5/2), glans dehiscence (3/0), diverticulum (1/2), residual chordee (3/0), and meatus stenosis (0/1) in each group. There was a significant difference in the overall rate of complications ( $P = 0.035$ ). These results indicate that the technique of reconstructing FCS provides excellent outcomes with fewer complications in distal/midshaft hypospadias repair.

*Asian Journal of Andrology* (2021) 23, 47–51; doi: 10.4103/aja.aja\_42\_20; published online: 28 August 2020

**Keywords:** complications; distal/midshaft hypospadias; forked corpus spongiosum; glans tilt

## INTRODUCTION

Hypospadias is one of the most common genital malformations in children. Surgery is the only way to repair hypospadias. Common complications that require a secondary surgery include fistula, diverticulum, glans dehiscence, meatus stenosis, urethral stricture, and residual chordee. Significant technical advances have allowed us to achieve a relatively high success rate (reportedly higher than 85%) in managing distal/midshaft hypospadias.<sup>1–3</sup> Even so, urethral fistula and glans dehiscence are the most common complications when repairing distal/midshaft hypospadias, especially the coronal fistula, which is more difficult to repair.<sup>4,5</sup> If the surgeon does not pay attention to straightening the penis when degloving, residual chordee will also occur after surgery, leading to catastrophic consequences. Hypospadias surgery remains one of the most challenging and controversial subjects for surgeons in the new century.

Therefore, in the present study, we report that we improved this surgical procedure by reconstructing the forked corpus spongiosum (FCS) to obtain satisfactory results when repairing distal/midshaft hypospadias.

## PATIENTS AND METHODS

### *Patients and study design*

From August 2013 to December 2018, 137 consecutive cases of distal/midshaft hypospadias operated by the same surgeon in Urology Department, Children's Hospital of Fudan University (Shanghai, China), were retrospectively analyzed. Due to the retrospective nature of the study, informed consent was waived, and the Ethics Board of the Children's Hospital of Fudan University approved the study (No. [2019] 208). During the operation, we preserved the urethral plate and chose the surgical method in accordance with the urethral plate width between the FCS. When the urethral plate width was  $\geq 6$  mm, tubularized incised plate (TIP) urethroplasty was performed, whereas when the urethral plate width was  $< 6$  mm, the onlay island flap (ONLAY) urethroplasty was selected. Of the 137 patients, 64 who underwent routine TIP or ONLAY surgery were considered the nonreconstructing group, and 73 patients who underwent reconstructing FCS during TIP or ONLAY surgery were considered the reconstructing group.

Data were collected including demographics, intrinsic parameters of the penis, surgical parameters and subsequent surgical outcomes.

The postoperative complications included any of the following during follow up: fistula, glans dehiscence, diverticulum, meatal stenosis, urethral stricture and residual chordee. Univariate differences between outcomes were analyzed using the Chi-squared test and *t*-test. All statistical calculations were performed using SPSS version 20.0 (IBM Corp., Armonk, NY, USA). All tests were two-sided, and  $P < 0.05$  was considered statistically significant.

### Key steps of reconstructing the FCS

The FCS reconstruction steps in the ONLAY procedure are shown in **Figure 1**. The brief procedures are described as follows. After degloving and carrying out the inner preputial flap, the FCS was cut off along both sides of the middle urethral plate. Next, the glans wings were combined with own corpus spongiosum and dissected along the surface of the corpora cavernosa laterally to at least the 3 o'clock and 9 o'clock positions of the penis. After performing ONLAY urethroplasty and glansplasty, the bilateral corpus spongiosum should be sutured at the midline, thereby covering the surface of the new urethra at the coronal sulcus. Please see details described in previous study.<sup>6</sup>

## RESULTS

### Intraoperative situations

The intraoperative situations of all cases are shown in **Table 1**. In the nonreconstructing group, there were 15 distal and 49 midshaft hypospadias. TIP was performed in 38 cases, and ONLAY was performed in 26 cases. The mean age at the time of surgery in these 64 cases was 37.55 (standard deviation [s.d.]: 29.65) months. The mean

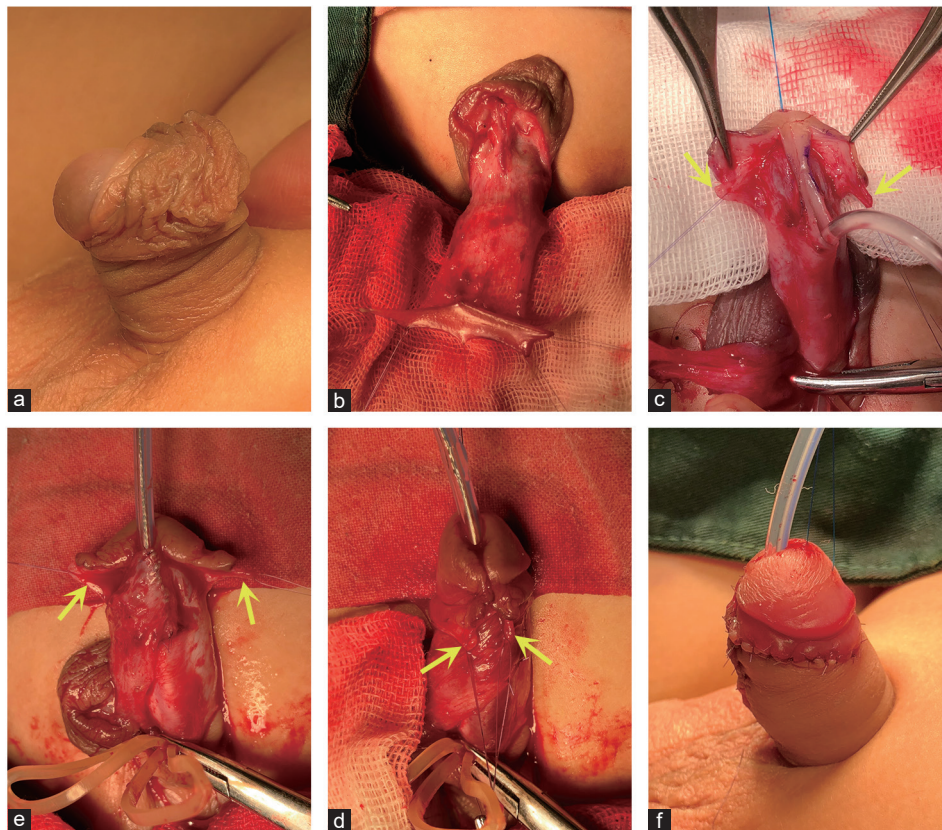
operation duration was 91.95 (s.d.: 12.17) min. The mean neourethral length was 1.88 (s.d.: 0.53) cm. The mean glans width (measured at its widest point) was 11.83 (s.d.: 1.32) mm.

In the reconstructing group, there were 17 distal and 56 midshaft hypospadias. TIP was performed in 27 cases, and ONLAY was performed in 46 cases. The mean age at the time of surgery in these 73 cases was 35.23 (s.d.: 31.27) months. The mean operation duration was 93.84 (s.d.: 14.91) min. The mean neourethral length was 1.94 (s.d.: 0.53) cm. The mean glans width was 11.56 (s.d.: 1.83) mm.

The *P*-values were  $>0.05$  between the two groups for urethral orifice location, the average age at the time of surgery, operation duration, neourethral length, and glans width. The differences were not statistically significant. The *P*-value was  $<0.05$  for the choice of operation method, and the difference was statistically significant.

### Postoperative complications

The postoperative complications of all cases are shown in **Table 2**. The median follow-up was 44 (range: 30–70) months and the total postoperative complication rate was 18.8% (12/64) in the nonreconstructing group; complications included 5 cases (7.8%, all by TIP) of coronal fistula that were repaired after half a year. Three cases (4.7%, 2 by TIP/1 by ONLAY) of glans dehiscence and one case (1.6%, by ONLAY) of mild urethral diverticulum that occurred at more than half a year after surgery were still under observation without further surgery. However, there were three cases (4.7%, 1 by TIP/2 by ONLAY) with residual chordee of approximately 15° after surgery, and no further surgery was performed due to the age of the patient



**Figure 1:** Key steps of reconstructing FCS (the yellow arrow) in the ONLAY procedure. (a) The side view before operation. (b) The inner preputial flap. (c) Dissecting the glans wings with own corpus spongiosum after cutting off the FCS. (d) ONLAY urethroplasty. (e) Suturing the original FCS at the midline to cover the new urethra at the coronal sulcus. (f) The side view afteroperation. FCS: forked corpus spongiosum; ONLAY: onlay island flap.

**Table 1: Intraoperative findings in 137 cases of distal/midshaft hypospadias**

Intraoperative parameters	Nonreconstructing group (n=64)	Reconstructing group (n=73)	P
Urethral orifice location (n), distal/midshaft	15/49	17/56	0.571
Operation method <sup>a</sup> (n), TIP/ONLAY	38/26	27/46	0.010
Age at operation (month), mean±s.d.	37.55±29.65	35.23±31.27	0.659
Operation duration (min), mean±s.d.	91.95±12.17	93.84±14.91	0.540
Neourethral length (cm), mean±s.d.	1.88±0.53	1.94±0.53	0.424
Glans width (mm), mean±s.d.	11.83±1.32	11.56±1.83	0.336

<sup>a</sup>If the width of the urethral plate was ≥6 mm, TIP was performed; whereas if <6 mm, the ONLAY was performed. TIP: tubularized incised plate; ONLAY: onlay island flap; s.d.: standard deviation

**Table 2: Postoperative complications in 137 cases of distal/midshaft hypospadias**

Complications	Nonreconstructing group (n=64)		Reconstructing group (n=73)		P
	n	Incidence rate (%)	n	Incidence rate (%)	
Fistula	5	7.8	2	2.7	0.179
Glans dehiscence	3	4.7	-	-	0.061
Diverticulum	1	1.6	2	2.7	0.639
Residual chordee	3	4.7	-	-	0.061
Meatus stenosis	-	-	1	1.4	0.347
Urethral stricture	-	-	-	-	-
Total	12	18.8	5	6.8	0.035

--: not occurred

and the degree of curvature. No meatus stenosis or urethral stricture was found in this group.

In the reconstructing group, the median follow-up was 15 (range: 6–27) months and the total postoperative complication rate was 6.8% (5/73). Two cases (2.7%, both by ONLAY) of fistula located in the body of the penis were also repaired. There were two cases (2.7%, both by ONLAY) of urethral diverticulum. One was mild, occurred more than half a year after surgery, and was under observation. The other occurred approximately 3 months after surgery, was relatively serious, and was treated with urethroplasty after another 3 months. One case (1.4%, by TIP) showed meatus stenosis, which was relieved after a 1-month period of meatus expansion combined with external mometasone furoate. No case of residual chordee or glans dehiscence occurred in this group and clinical symptoms of urethral stricture was also not observed.

The *P*-value was <0.05 for the overall rate of postoperative complications between the two groups. This difference was statistically significant.

## DISCUSSION

The high incidence of hypospadias, which occurs in 1 in 200–300 live births, means that it affects a large number of patients.<sup>7,8</sup> Although the success rate of hypospadias surgery is increasing with medical technical advances, many patients still require reoperation because of complications. Therefore, we propose a technique to reconstruct the FCS to further improve the prognosis of distal/midshaft hypospadias repair. This is the significance of this retrospective study.

Current guidelines consider the optimal age for hypospadias repair to be somewhere between 6 and 18 months, depending on the severity and the need for multiple procedures.<sup>9</sup> Unfortunately, in our study, the average age of surgery was approximately 3 years, indicating that they were performed relatively late. This was mainly related to the following. First, many areas in China are not advanced. The medical knowledge of the people in these regions is so poor that parents tend to wait to bring their children to the hospital, resulting in late diagnoses. Second, in China, the number of children with hypospadias is large,

and the number of pediatric urologists is far from sufficient. Moreover, to become skilled in performing hypospadias, surgeons require years of specialized training.<sup>10,11</sup>

Currently, more than 400 techniques for hypospadias repair have been described. In general, TIP urethroplasty, which was first described in 1994 by Snodgrass, has gradually become the most common method for distal/midshaft hypospadias repair with preservation of the urethral plate.<sup>12,13</sup> However, Bush *et al.*<sup>14</sup> also reported that glans size was an independent risk factor for urethroplasty complications after TIP hypospadias repair. They described that the outcomes of TIP urethroplasty were good in cases with a glans width ≥14 mm. It seemed that the quality of the urethral plate was no need to consider. Unfortunately, penile dimensions can vary across ethnicities or geographic regions, and penis size in Chinese patients is usually not as large as that in Western patients.<sup>15–18</sup> In our study, the average glans width was less than 12 mm. Accordingly, we may need to choose different surgical methods according to the quality of the urethral plate in order to reduce the occurrence of postoperative complications and obtain good outcomes. The ONLAY technique was recommended by some surgeons, particularly in cases with a small glans and narrow urethral plates, which make tubularization difficult.<sup>19,20</sup> Similarly, a considerable number of cases in our study had a dysplastic urethral plate with a narrowest width of approximately only 1–2 mm. Therefore, based on our experience, we chose the ONLAY technique in cases where the urethral plate width was <6 mm; otherwise, TIP urethroplasty was performed.

We reviewed the literature on the complication rate of hypospadias surgery in developed countries. Wilkinson *et al.*<sup>21</sup> reported that the complication rates in high-volume and low-volume centers in the UK were 17.5% and 25%, respectively. Schneuer *et al.*<sup>22</sup> showed that the overall postoperative complication rate was 13% in Australia. Snodgrass *et al.*<sup>4</sup> summarized 89 urethral complications (12%) that were diagnosed after follow-up of 792 primary hypospadias repair surgeries. Spinoit *et al.*<sup>23</sup> reported and analyzed the long-term outcomes of primary hypospadias repair at a single tertiary care center in Belgium, at which

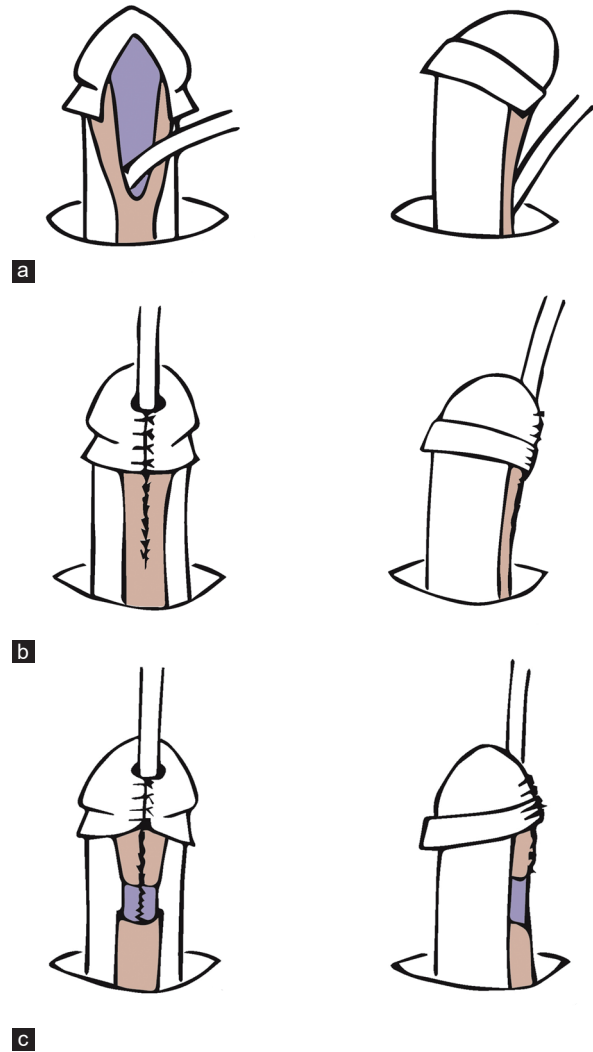
the complication rate was 24.1%. The complication rate in our study was also basically consistent with the literature. Moreover, we found that overall, prognoses were better in the reconstruction group than those in the nonreconstruction group (6.8%/18.8%,  $P = 0.035$ ).

We initially developed a method of reconstructing FCS in distal/midshaft hypospadias because our previous result showed that there were a few more cases of coronal fistula and glans dehiscence occurred after hypospadias repair by TIP or ONLAY. Moreover, re-urethroplasty and re-glansplasty should be performed in these cases. This might frustrate patients and parents because they have to face the same risks as or even higher risks than they faced during the first surgery.<sup>24</sup> A feature of reconstructing the FCS is that the corpus spongiosum on both sides is used to increase the thickness of the two glans wings during dissecting so that the glans can be more completely integrated without any tension during the glansplasty. In addition, the newly matched corpus spongiosum covers the ventral side of the neourethra, providing it with better protective tissue. Because of the reduced tension and enhanced coverage achieved by this procedure, there were no cases of coronal fistula or glans dehiscence in our reconstruction group. This was an encouraging result for us.

However, we also found that one of the 2 cases of diverticula that occurred in the reconstruction group was obvious at 3 months after surgery, and this patient needed to press the ventral side of penis to drain the urine. Therefore, the patient underwent revision of the diverticulum with a Thiersch-Duplay repair procedure after another 3 months. An F8 catheter was intraoperatively passed easily through the distal urethra, indicating that there was no distal urethral stricture. It has been reported that some of the factors that increase the risk of a diverticulum occurring include proximal defects due to the use of poorly tissue-supported flaps and the presence of a distal stricture that causes relative obstruction/higher outlet pressures.<sup>25</sup> With regard for our study, it is possible that we overfused the glans with the reconstructed FCS or that local tissue edema forced the distal urethra in the early postoperative period, resulting in an obvious increase in urinary flow resistance through the distal urethra. This situation should receive more attention when we use this technique in future surgeries.

In distal/midshaft hypospadias, chordee may still remain between the glans and the distal penis after degloving, similar to a glans tilt. Some surgeons do not pay enough attention to the condition of glans tilt, which is not considered a complication, even if it remains postoperatively. Tugtepe *et al.*<sup>26</sup> mentioned in their study that only 9.6% of the patients with distal hypospadias knew that they had a penile chordee preoperatively, and most other patients and their families were not aware of the penile chordee. However, this type of chordee does need to be concerned about whether the degree of tilt will gradually increase during puberty. If reoperation is needed, the penis will need to be repaired in stages, which can be highly inconvenient for patients.<sup>27,28</sup> Unfortunately, in the nonreconstruction group, 3 cases of residual chordee of approximately 15° were recognized during observation and follow-up. The possibility of later reoperation cannot be excluded in these patients.

It has been reported in the literature that spongioplasty can be used to change the angle of the penis head and the penis body to correct glans tilt.<sup>29</sup> However, we think that spongioplasty may sometimes be insufficient to straighten the penis. Two reports published in 2000 by Snodgrass *et al.*<sup>30</sup> and Erol *et al.*<sup>31</sup> both indicated that in hypospadias, the urethral plate was well-organized with extensive blood vessels, glands, and smooth muscle corresponding to an abnormally formed corpus spongiosum. Therefore, reconstructing the FCS instead of



**Figure 2:** Glans tilt correcting. (a) FCS after degloving and glans tilt in the side view. (b) Spongioplasty after urethroplasty and remaining glans tilt in some cases. (c) Reconstructing FCS after urethroplasty and straightening penis completely. FCS: forked corpus spongiosum.

performing spongioplasty could further relieve a poorly developed corpus spongiosum with fibrosis pulling on the glans (**Figure 2**). Moreover, with the good ductility of the original urethral plate, glans tilt can be completely corrected without residual chordee. In our study, no residual chordee was observed after surgery in the reconstructed group, providing good confirmation of this view (**Figure 1a** and **1f**).

The limit of our study is that this is a retrospective study. Due to the small sample size, the choice of operation method ( $P < 0.05$ ) may have influenced the final results of our study. However, we can only choose a more optimal operation method for better prognosis and to reduce postoperative complications which would bias the final results. In the future, we may enroll more patients in our study to expand the data, in order to reduce bias.

Another limitation of our study is that we do not have standardized measures for postoperative voiding function which is an important prognostic indicator. Although no case of clinically symptomatic urethral strictures was observed in our study, we still cannot accurately assess the effect of reconstructing FCS on urine flow. In future, we

would like to collect more data on parameters such as the urine flow rate to improve the assessment of the postoperative voiding function.

## CONCLUSIONS

In our experience during this study, performing reconstruction of the FCS in distal/midshaft hypospadias repair provided excellent outcomes. The overall complication rate was lower than that achieved in routine TIP or ONLAY surgery. Reconstructing FCS significantly reduced the incidences of fistula and glans dehiscence and could be helpful for correcting glans tilt. This technique should therefore be promoted in distal/midshaft hypospadias surgery.

## AUTHOR CONTRIBUTIONS

YLB conceived the study and made critical revisions to the manuscript regarding important intellectual content. BZ designed the study and completed the manuscript writing. SSR contributed to patient recruitment and follow-up. All authors read and approved the final manuscript.

## COMPETING INTERESTS

All authors declared no competing interests.

## ACKNOWLEDGMENTS

We thank the parents of all the participants included in this study.

## REFERENCES

- Rushton HG, Belman AB. The split prepuce in situ onlay hypospadias repair. *J Urol* 1998; 160: 1134–6.
- Perlmutter AE, Morabito R, Tarry WF. Impact of patient age on distal hypospadias repair: a surgical perspective. *Urology* 2006; 68: 648–51.
- Pfistermuller KL, McArdle AJ, Cuckow PM. Meta-analysis of complication rates of the tubularized incised plate (TIP) repair. *J Pediatr Urol* 2015; 11: 54–9.
- Snodgrass W, Villanueva C, Bush NC. Duration of follow-up to diagnose hypospadias urethroplasty complications. *J Pediatr Urol* 2014; 10: 208–11.
- Snodgrass W, Grimsby G, Bush NC. Coronal fistula repair under the glans without reoperative hypospadias glansplasty or urinary diversion. *J Pediatr Urol* 2015; 11: 39.e1–4.
- Zhang B, Bi Y, Ruan S. Reconstructing forked corpus spongiosum to correct glans droop in distal/midshaft hypospadias repair. *J Int Med Res* 2020; 48: 1–9.
- Paulozzi LJ, Erickson JD, Jackson RJ. Hypospadias trends in two US surveillance systems. *Pediatrics* 1997; 100: 831–4.
- Springer A, van den Heijkant M, Baumann S. Worldwide prevalence of hypospadias. *J Pediatr Urol* 2016; 12: 152.e1–7.
- Riedmiller H, Androulakakis P, Beurton D, Kocvara R, Gerharz E, *et al*. EAU guidelines on paediatric urology. *Eur Urol* 2001; 40: 589–99.
- Frimberger D, Campbell J, Kropp BP. Hypospadias outcome in the first 3 years after completing a pediatric urology fellowship. *J Pediatr Urol* 2008; 4: 270–4.
- DeLair SM, Tanaka ST, Yap SA, Kurzrock EA. Training residents in hypospadias repair: variations of involvement. *J Urol* 2008; 179: 1102–6.
- Snodgrass W. Tubularized, incised plate urethroplasty for distal hypospadias. *J Urol* 1994; 151: 464–5.
- Springer A, Krois W, Horcher E. Trends in hypospadias surgery: results of a worldwide survey. *Eur Urol* 2011; 60: 1184–9.
- Bush NC, Villanueva C, Snodgrass W. Glans size is an independent risk factor for urethroplasty complications after hypospadias repair. *J Pediatr Urol* 2015; 11: 355.e1–5.
- Wessells H, Lue TF, McAninch JW. Penile length in the flaccid and erect states: guidelines for penile augmentation. *J Urol* 1996; 56: 995–7.
- Ponchietti R, Mondaini N, Bonafè M, Di Loro F, Biscioni S, *et al*. Penile length and circumference: a study on 3300 young Italian males. *Eur Urol* 2001; 39: 183–6.
- Khan S, Somani B, Lam W, Donat R. Establishing a reference range for penile length in Caucasian British men: a prospective study of 609 men. *BJU Int* 2012; 109: 740–4.
- Chen XB, Li RX, Yang HN, Dai JC. A comprehensive, prospective study of penile dimensions in Chinese men of multiple ethnicities. *Int J Impot Res* 2014; 26: 172–6.
- Shimotakahara A, Nakazawa N, Wada A, Nagata S, Koga H, *et al*. Tubularized incised plate urethroplasty with dorsal inlay graft prevents meatal/neourethral stenosis: a single surgeon's experience. *J Pediatr Surg* 2011; 46: 2370–2.
- Mohajerzadeh L, Mirshemirani A, Rouzrokh M, Sadeghian N, Khaleghnejad-Tabari A, *et al*. Evaluation of onlay island flap technique in shallow urethral plate hypospadias. *Iran J Pediatr* 2016; 26: e660.
- Wilkinson DJ, Green PA, Beglinger S, Myers J, Hudson R, *et al*. Hypospadias surgery in England: higher volume centres have lower complication rates. *J Pediatr Urol* 2017; 13: 481.e1–6.
- Schneuer FJ, Holland AJ, Pereira G, Bower C, Nassar N. Prevalence, repairs and complications of hypospadias: an Australian population-based study. *Arch Dis Child* 2015; 100: 1038–43.
- Spinoit AF, Poelaert F, Groen LA, Van Laecke E, Hoebeke P. Hypospadias repair at a tertiary care center: long-term follow-up is mandatory to determine the real complication rate. *J Urol* 2013; 189: 2276–81.
- Bush NC, Holzer M, Zhang S, Snodgrass W. Age does not impact risk for urethroplasty complications after tubularized incised plate repair of hypospadias in prepubertal boys. *J Pediatr Urol* 2013; 9: 252–6.
- Snyder CL, Evangelidis A, Snyder RP, Ostlie DJ, Gatti JM, *et al*. Management of urethral diverticulum complicating hypospadias repair. *J Pediatr Urol* 2005; 1: 81–3.
- Tugtepe H, Thomas DT, Kandirici A, Yener S, Dagli T. Should we routinely test for chordee in patients with distal hypospadias? *Eur J Pediatr Surg* 2015; 25: 195–8.
- Gill NA, Hameed A. Management of hypospadias cripples with two-staged Bracka's technique. *J Plast Reconstr Aesthet Surg* 2011; 64: 91–6.
- Wu M, Chen F, Xie H, Lv Y, Huang Y, *et al*. Management of failed hypospadias: choosing the right method and achieving optimal results. *Int Urol Nephrol* 2018; 50: 1795–800.
- Dodat H, Landry JL, Szwarc C, Culem S, Murat FJ, *et al*. Spongiosoplasty and separation of the corpora cavernosa for hypospadias repair. *BJU Int* 2003; 91: 528–31.
- Snodgrass W, Patterson K, Plaire JC, Grady R, Mitchell ME. Histology of the urethral plate: implications for hypospadias repair. *J Urol* 2000; 164: 988–9.
- Erol A, Baskin LS, Li YW, Liu WH. Anatomical studies of the urethral plate: why preservation of the urethral plate is important in hypospadias repair. *BJU Int* 2000; 85: 728–34.

This is an open access journal, and articles are distributed under the terms of the Creative Commons Attribution-NonCommercial-ShareAlike 4.0 License, which allows others to remix, tweak, and build upon the work non-commercially, as long as appropriate credit is given and the new creations are licensed under the identical terms.

©The Author(s) (2020)