

# Severe scurvy in an adult male without clear risk factors for nutritional deficiency



William Day, BS,<sup>a</sup> Adelaida Gyurjyan-Bunch, MD,<sup>b</sup> and Abby Van Voorhees, MD<sup>b</sup>  
*Norfolk, Virginia*

**Key words:** ascorbic acid; malnutrition; osteoporosis; petechial rash; scurvy.

## INTRODUCTION

Scurvy is a nutritional disease manifesting with sequelae of collagen defects caused by a deficiency of ascorbic acid. Because ascorbic acid cannot be synthesized endogenously, dietary consumption is crucial. Recent surveys in the United States have found 7.1% of middle-class participants were deficient and 13.7% were depleted, which opposes the common belief that scurvy is chiefly an archaic disease.<sup>1</sup> Patients who are elderly, developmentally delayed, alcoholics, malnourished, or of low socioeconomic status are at particular risk.<sup>2</sup>

Patients typically present with symptoms 1 to 3 months after deficiency of ascorbic acid. Mild decreases in ascorbic acid are associated with nonspecific, constitutional symptoms including fatigue, irritability, and loss of appetite. More significant depletions can result in multiple affected organ systems manifesting as hemorrhagic diastasis, musculoskeletal symptoms, gingival hypertrophy, and the classic cutaneous stigmata of perifollicular hemorrhage, corkscrew hairs, and ecchymoses.<sup>3,4</sup> The wide, stage-dependent spectrum of disease presentation coupled with the low incidence in developed nations make the diagnosis of scurvy often elusive. Despite this complexity, most patients present with some historical risk factor for nutritional deficiency.<sup>2</sup> Here we present the case of an adult male with severe scurvy without clear risk factors, manifesting as severe musculoskeletal pain and subtle skin changes.

## CASE REPORT

A 39-year-old man with a history of asthma and 20-pack-year smoking history was transferred to our

facility for a dermatology consultation regarding a petechial rash on his lower extremities in the setting of a 6-month history of progressively worsening lower extremity pain and joint stiffness. In addition, he began to complain of bruising of his lower extremities and increasing fatigue. He admitted to not consuming enough fruits and vegetables but denied alcohol or recreational drug use. He reported 6 emergency department visits over a 6-month period for evaluation and pain control and was given cyclobenzaprine, naprosyn, oral steroids, and intravenous steroids without improvement. He was admitted after his sixth emergency department visit for intractable pain, and he was subsequently transferred to our facility for an inpatient dermatology evaluation.

In the hospital, he was found to have a microcytic anemia with normal ferritin and low iron, a mild leukocytosis, and normal platelets. His erythrocyte sedimentation rate and C-reactive protein were elevated, but creatinine kinase; complete metabolic panel; antinuclear antibody; rheumatoid factor; anti-neutrophil cytoplasmic antibody; factor VIII, factor IX, factor XI; plasminogen activator inhibitor 1; von Willebrand factor; IgA; HIV; hepatitis panel; and uric acid levels were within normal limits.

Computed tomography of the pelvis showed bilateral hip effusions and concern for avascular necrosis of the femoral heads. Pelvic magnetic resonance imaging showed prominent left femoral head marrow edema extending through the femoral neck to the intertrochanteric line, suggesting a diagnosis of idiopathic transient osteoporosis (Fig 1). A punch biopsy of the patient's right medial thigh was performed by general surgery, the results of which showed noninflammatory purpura with

From the Department of Dermatology,<sup>a</sup> Eastern Virginia Medical School.<sup>a</sup>

Funding sources: None.

Conflicts of interest: None disclosed.

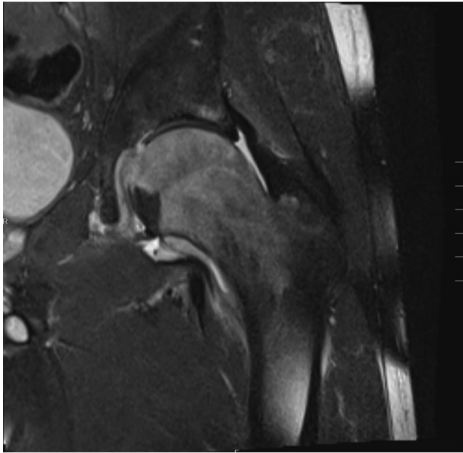
Correspondence to: Abby Van Voorhees, MD, Professor and Chair, Department of Dermatology, Eastern Virginia Medical School, Norfolk, VA 23507. E-mail: [vanvoos@evms.edu](mailto:vanvoos@evms.edu).

JAAD Case Reports 2019;5:309-11.

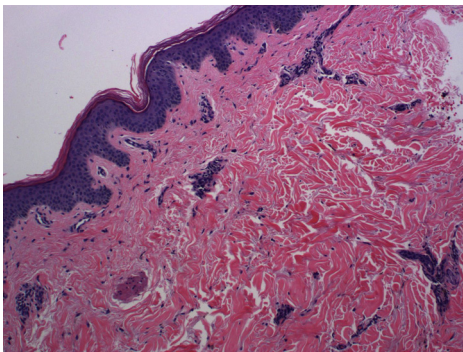
2352-5126

© 2019 by the American Academy of Dermatology, Inc. Published by Elsevier, Inc. This is an open access article under the CC BY-NC-ND license (<http://creativecommons.org/licenses/by-nc-nd/4.0/>).

<https://doi.org/10.1016/j.jidcr.2019.01.031>



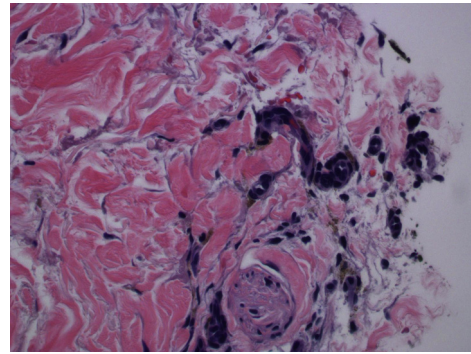
**Fig 1.** T1 magnetic resonance image of the pelvis shows prominent diffuse marrow edema throughout the left femoral head and left side of the neck extending peripherally to the level of the intertrochanteric line.



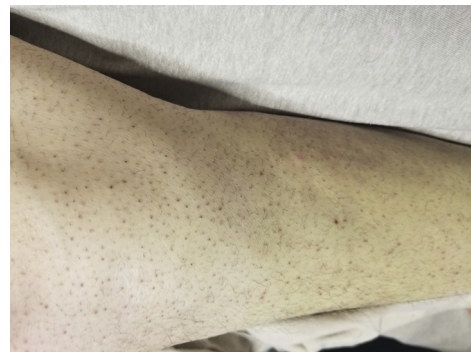
**Fig 2.** Right medial thigh punch biopsy shows noninflammatory purpura. (Hematoxylin-eosin stain; original magnification:  $\times 10$ .)

areas of red cell extravasation and hemosiderin without evidence of microthrombi or vasculitis (Figs 2 and 3).

Once transferred to our facility, he remained in intense pain and was placed on a patient-controlled analgesic pump to achieve adequate control. Physical examination found that the patient was edentulous without gingival hemorrhage or hypertrophy, had perifollicular erythema to the lower extremities with corkscrew hairs (Fig 4), and had a xerotic, discolored right medial ankle. In addition, he exhibited folliculocentric erythematous papules admixed with hyperpigmented macules across his trunk. Given his bone marrow edema, significant joint and musculoskeletal pain, anemia, and cutaneous manifestations, a tentative diagnosis of ascorbic acid deficiency was made. The patient's ascorbic acid level was drawn and noted to be 0.0. A more thorough nutritional workup, including vitamins A,



**Fig 3.** Right medial thigh punch biopsy shows hemosiderin and red blood cell extravasation. (Hematoxylin-eosin stain; original magnification:  $\times 40$ .)



**Fig 4.** Perifollicular erythema and corkscrew hairs noted on the right lower extremity.

D, E, and K; vitamin B complex; vitamin B12; folate; magnesium; selenium; lipid panel; and pre-albumin, was notable for a folate deficiency but otherwise unremarkable. The patient was started on 1000 mg oral ascorbic acid daily for 1 month. Twenty-four hours after treatment, his constitutional symptoms improved, and he was subsequently discharged. After 2 months, although lost to definitive follow-up, the patient has not been seen in our emergency department or another outpatient facility for pain.

## DISCUSSION

Scurvy is an uncommon nutritional disease caused by a dietary lack of ascorbic acid. Ascorbic acid is critical for hydroxylation reactions, particularly hydroxylation of proline residues on collagen fibers. This hydroxylation permits the sharp twisting of the collagen triple helix, thus maintaining stability. In addition, ascorbic acid acts as a reducing agent, which accounts for its varied functions in iron metabolism, toxin removal, and wound healing.<sup>5</sup>

Collagen and ascorbic acid's ubiquity across multiple organ systems accounts for scurvy's wide spectrum of clinical and laboratory presentations.

Our patient initially exhibited musculoskeletal pain related to significant bone marrow edema, which likely is related to collagen's importance in development and maintenance of the bone matrix.<sup>5,6</sup> Further, our patient's microcytic anemia and folate deficiency could, in part, be due to ascorbic acid's importance in heme metabolism and that many foods high in ascorbic acid are also high in folate.<sup>7</sup> His lack of gingival involvement is likely related to his lack of dentition.<sup>8</sup> Our patient's lack of dentition, poor diet, and smoking status likely contributed to his presentation; however, his lack of classic risk factors including alcoholism, low socioeconomic status, and developmental delay made this diagnosis difficult.

As with our patient, constitutional symptoms in patients with scurvy can improve as quickly as 24 hours after treatment. Cutaneous findings, such as ecchymoses and perifollicular erythema can improve within a few days of high-dose ascorbic acid therapy. However, musculoskeletal manifestations of scurvy including defective osteoid matrix, increased bone resorption, and secondary edema can take approximately 2 weeks to show signs of improvement.<sup>6,8</sup>

Scurvy is a nutritional disease that is difficult to diagnose because of its low incidence and myriad clinical manifestations. We report this case to

highlight a rare case of scurvy in an adult male and to call on clinicians to consider nutritional causes such as scurvy in patients with recalcitrant musculoskeletal pain and petechial rash despite a limited risk factor profile.

#### REFERENCES

1. Hampl JS, Taylor CA, Johnston CS. Vitamin C deficiency and depletion in the United States: the Third National Health and Nutrition Examination Survey, 1988 to 1994. *Am J Public Health.* 2004;94:870-875.
2. Doll S, Ricou B. Severe vitamin C deficiency in a critically ill adult: a case report. *Eur J Clin Nutr.* 2013; 67:881-882.
3. Schleicher RL, Carroll MD, Ford ES, Lacher DA. Serum vitamin C and the prevalence of vitamin C deficiency in the United States: 2003-2004 National Health and Nutrition Examination Survey (NHANES). *Am J Clin Nutr.* 2009;90: 1252-1263.
4. Francescone MA, Levitt J. Scurvy masquerading as leukocytoclastic vasculitis: a case report and review of the literature. *Cutis.* 2005;76:261-266.
5. Aghajanian P, Hall S, Wongworawat MD, Mohan S. The roles and mechanisms of actions of vitamin c in bone: new developments. *J Bone Miner Res.* 2015;30:1945-1955.
6. Fain O. Musculoskeletal manifestations of scurvy. *Joint Bone Spine.* 2005;72:124-128.
7. Polat AV, Bekci T, Say F, Bolukbas E, Selcuk MB. Osteoskeletal manifestations of scurvy: MRI and ultrasound findings. *Skeletal Radiol.* 2015;44:1161-1164.
8. Smith A, Di Primio G, Humphrey-Murto S. Scurvy in the developed world. *Cmaj.* 2011;183:E752-E755.