



Effectiveness of micropulse transscleral laser therapy in uncontrolled glaucoma secondary to ciliary body metastasis

Pukkapol Suvannachart^{a,b}, Patcharaporn Jaru-ampornpan^{a,c}, Sune Chansangpetch^a, Anita Manassakorn^a, Visanee Tantisevi^a, Kitiya Ratanawongphaibul^{a,*}

^a Glaucoma Research Unit, Faculty of Medicine, Chulalongkorn University and King Chulalongkorn Memorial Hospital, Thai Red Cross Society, 1873 Rama IV Road, Pathumwan, Bangkok, Thailand

^b Department of Ophthalmology, Suddhavej Hospital, Mahasarakham University, 269 Nakornsawan Road, Muang, Mahasarakham, Thailand

^c Department of Ophthalmology, Queen Savang Vadhana Memorial Hospital, 290 Jerm Jom Phon Road, Si Racha, Chon Buri, Thailand

ARTICLE INFO

Keywords:

Micropulse transscleral laser therapy
Ciliary body metastasis
Glaucoma

ABSTRACT

Purpose: To report a case of ciliary body metastasis with uncontrolled glaucoma that was successfully treated with micropulse transscleral laser therapy (MPTLT).

Observations: A case of a 44-year-old female with uncontrolled glaucoma secondary to ciliary body metastasis from pulmonary adenocarcinoma. Antiglaucoma medications, intravitreal ranibizumab injection and local radiotherapy were ineffective in reducing her intraocular pressure (IOP) and ocular pain. MPTLT using a power setting of 2,000 mW, 31.3% duty cycle, and 140 seconds over 180 degrees demonstrated favorable IOP reduction (from 31 to 8 mmHg) on the first postoperative day without either ocular pain or postoperative complications. IOP remained controlled until she died from hemoperitoneum 18 days after hospital discharge.

Conclusions and importance: MPTLT can be a safe and effective procedure for IOP control in intraocular metastasis patients with uncontrolled glaucoma.

1. Introduction

Secondary glaucoma caused by iridociliary metastases is a relatively rare condition which does not respond well to intraocular pressure (IOP) control using medications.¹⁻⁴ Ciliary body metastasis accounts for approximately 2% of uveal metastasis.⁵ Two-thirds of patients with ciliary body metastasis have secondary ocular hypertension.⁶ The underlying mechanisms of elevated IOP include direct tumor invasion of the anterior chamber angle, anterior segment neovascularization, angle closure from forward movement of lens-iris diaphragm, secondary pigment dispersion, or any combination thereof.^{6,7}

Diode laser transscleral cyclophotocoagulation and laser trabeculoplasty are preferred treatment options for uncontrolled IOP secondary to uveal metastases because incisional glaucoma surgery can lead to extraocular and systemic spreading of the tumors.^{7,8} Several studies reported the efficacy of continuous wave diode laser cyclophotocoagulation (CW-CPC) in this group of patients.^{2,9} Micropulse transscleral laser therapy (MPTLT) is a recent treatment modality for glaucoma approved by the United States Food and Drug Administration

(USFDA) in 2015. MPTLT is different from conventional CW-CPC as the laser power in MPTLT is emitted using an on-and-off mode which protects adjacent tissues from thermal damage and reduces serious complications such as hypotony and phthisis bulbi.^{10,11} The proposed mechanisms of IOP reduction are a diminution of aqueous production and aqueous outflow enhancement of both trabecular and uveoscleral outflows.¹² MPTLT has been used effectively and safely for both refractory glaucoma and for glaucoma patients with good central vision.¹³ The IOP reduction effect can be evidenced after the first postoperative day, while the laser is repeatable if IOP rises thereafter.¹⁴ Recently, MPTLT was successfully used to control IOP in ciliary body melanoma.¹⁵ However, the use of MPTLT has been rarely reported in secondary glaucoma from intraocular metastasis. We report one case of ciliary body metastasis with uncontrolled glaucoma that demonstrated IOP reduction using MPTLT.

2. Case report

A 44-year-old Thai woman presented to the outpatient clinic

* Corresponding author. Department of Ophthalmology, Faculty of Medicine, Chulalongkorn University and King Chulalongkorn Memorial Hospital, 1873 Rama IV Road, Pathumwan, Bangkok, 10330, Thailand.

E-mail address: Kitiya.Ra@chula.ac.th (K. Ratanawongphaibul).

<https://doi.org/10.1016/j.ajoc.2021.101190>

Received 17 May 2021; Received in revised form 28 July 2021; Accepted 6 August 2021

Available online 8 August 2021

2451-9936/© 2021 Published by Elsevier Inc. This is an open access article under the CC BY-NC-ND license (<http://creativecommons.org/licenses/by-nc-nd/4.0/>).

complaining of right eye pain and blurry vision for 2 days. The patient had been diagnosed 8 months earlier with advanced stage pulmonary adenocarcinoma with pleural metastasis and treated with carboplatin and gemcitabine. After the first cycle of chemotherapy, her medications were withheld due to thrombocytopenia. She had a history of acute massive pulmonary embolism and acute left middle cerebral artery infarction treated with recombinant tissue plasminogen activator (rtPA) and continued with enoxaparin.

IOP in the right eye was 59 mmHg using the Goldmann applanation tonometer with visual acuity (VA) of hand motion. Right relative afferent pupillary defect (RAPD) was positive. Slit-lamp biomicroscopy showed conjunctival injection with microcystic edema of the cornea. The anterior chamber was filled by 2.5 mm of hyphema. There were multiple temporal whitish irregular iris masses at 7–10 o'clock associated with peripheral anterior synechiae (PAS) and neovascularization of the iris (Fig. 1A). Posterior synechiae were identified encompassing approximately 300 degrees (from 10 to 8 o'clock in the clockwise direction). Fundus could not be evaluated due to media opacity. Her left eye examination was unremarkable with IOP of 14 mmHg, VA of 20/50, and cup-to-disc ratio (CDR) of 0.3. The ciliary body mass was observed by ultrasound biomicroscopy (UBM) showing heterogeneous hyper-echogenicity with multiple cystic lesions at 7–10 o'clock with PAS and adjacent scleral thickening (Fig. 2).

The iris and ciliary body masses were presumed to be metastatic from pulmonary adenocarcinoma. The patient was diagnosed as having secondary glaucoma due to the tumors. She was admitted and started therapy with topical 0.005% latanoprost, combination of 2% dorzolamide/0.5% timolol maleate, 0.15% brimonidine, 1% prednisolone acetate, oral acetazolamide at 1,000 mg/day and oral glycerin at 1 mg/kg/dose every 6 hours. Anterior chamber paracentesis was performed to investigate for cytology, which showed a negative result for malignancy. Results of magnetic resonance imaging (MRI) of the brain and orbit demonstrated a focal thickening of the anterior sclera in the right eye, involving uvea and ciliary body. No brain lesions were found. After informed consent was obtained, a single intravitreal injection of 0.5 mg ranibizumab was administered to treat neovascularization. Two days after the injection, the iris masses decreased in size and iris neovascularization rapidly regressed and completely disappeared. Palliative local radiotherapy with 30 Gy in 10 fractions was performed to decrease the size of the ciliary body tumor. After 3 days of radiotherapy, fundus examination showed mild optic disc edema and multiple subretinal dome-shaped infiltrations with preretinal hemorrhage.

Even with the use of antiglaucoma medications, the patient's IOP was still in the range of 30–50 mmHg. She continued to feel discomfort and repeated anterior chamber paracenteses were performed to relieve the pain. After 13 days of intravitreal ranibizumab injection and 7 days of local radiotherapy, MPTLT was performed with a power setting of 2,000 mW and a duty cycle of 31.3%. The handheld probe was moved along at 180 degrees covering both the superonasal and inferonasal quadrants to avoid the ciliary body mass over a 140-s period. One day

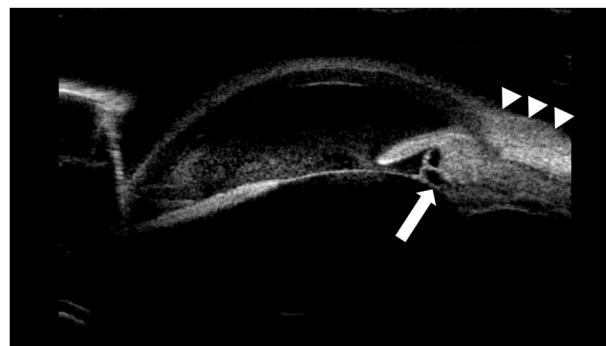


Fig. 2. Ultrasound biomicroscopy showed heterogeneous ciliary body mass (white arrow) in the right eye with hyperechogenicity and multiple cystic lesions at 10 o'clock with peripheral anterior synechiae and adjacent scleral thickening (white arrowhead).

after performing MPTLT, IOP decreased from 31 mmHg preoperatively to 8 mmHg with neither pain nor early ocular complications. Systemic antiglaucoma medications were tapered off and IOP was controlled with 0.15% brimonidine monotherapy within 3 days postoperatively and on the hospital discharge date. Eighteen days after discharging from the hospital, the patient died from hemoperitoneum suspected from liver metastasis.

3. Discussion

MPTLT is an alternative treatment option for IOP control in patients with intraocular metastases. The management of metastatic cancer is generally palliative, depending on the clinical condition of the patients, and aims to relieve symptoms and improve quality of life for their remaining life span.¹⁶ To our knowledge, this is the first case report showing a favorable result of MPTLT in a patient with metastatic adenocarcinoma of lung to ciliary body.

In our case, MPTLT (total energy of 87.64 J over 180 degrees) reduced IOP by approximately 74% (from 31 to 8 mmHg) from the baseline and remained stable for three days without additional systemic medication until hospital discharge. This result was similar to a previous study using MPTLT for IOP reduction in ciliary body melanoma (93.9 J over 270 degrees) which showed an IOP reduction of 63% at 5 months postoperatively.¹⁵ Sanchez et al. also reported that low total energy (100 J or less) generally provided an IOP reduction of approximately 30%.¹² El Harazi et al. demonstrated that CW-CPC decreased IOP from 45 to 20 mmHg (56% reduction) after 2 months postoperatively in a patient with glaucoma secondary to iris metastasis from breast cancer.² Chen et al. also showed that CW-CPC was effective in IOP control in refractory glaucoma secondary to iris melanocytoma for up to 15 months (from 40 to 20 mmHg, 50% reduction).⁹ Even though both MPTLT and CW-CPC

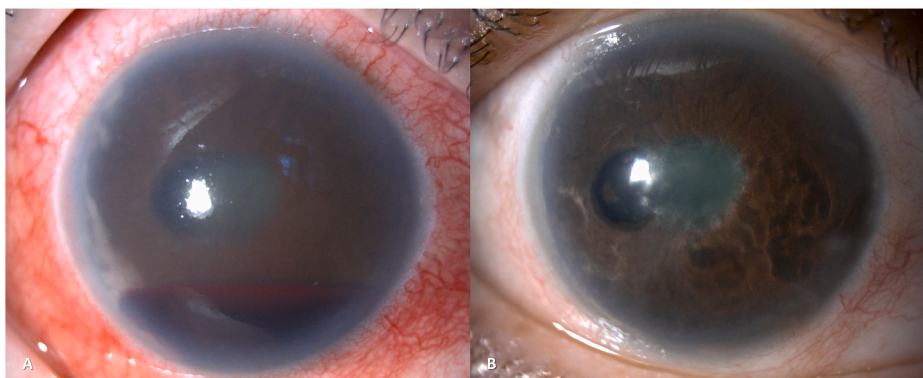


Fig. 1. Slit-lamp examination before receiving treatment. There were multiple temporal whitish irregular iris masses at 7–10 o'clock associated with peripheral anterior synechiae and neovascularization of the iris. The hyphema was also seen in anterior chamber. (A) Slit-lamp examination 16 days after intravitreal ranibizumab injection, 10 days after local radiation, and 3 days after micro-pulse transscleral laser therapy, the iris masses decreased in size and neovascularization of the iris completely disappeared. (B).

are non-invasive repeatable procedures, MPTLT is probably superior to CW-CPC for several reasons. Firstly, the cooling effect of MPTLT has demonstrated significantly fewer serious complications^{10,11} and can be used safely in patients with good visual potential.¹³ Secondly, MPTLT has shown better efficacy, especially in tumor-related patients. This is possibly due to the effect of tumor regression from concurrent treatments such as radiotherapy.¹⁵ Lastly, MPTLT delivers faster IOP reduction than CW-CPC.¹⁴

Anti-vascular endothelial growth factors (VEGF), including ranibizumab and bevacizumab, have been reported to improve IOP control in uveal metastases. Makri et al. found that intravitreal ranibizumab was effective in IOP reduction in neovascular glaucoma and regression of iris metastases with refractory glaucoma.⁴ Intravitreal injection of bevacizumab also demonstrated similar results in patients with iridociliary metastases from various primary sites of cancer including small cell lung cancer.^{3,17} For our patient, we decided to use intravitreal ranibizumab because the patient was previously diagnosed with a pulmonary embolism. Regarding the differences in molecular weight and structure, ranibizumab has been found to be associated with fewer thromboembolic events compared to bevacizumab.¹⁸ Although IOP reduction effect can be achieved using anti-VEGF, some patients still had uncontrolled IOP due to extensive PAS.¹⁷

Local radiation is primarily used to treat radiosensitive metastatic tumors including iridociliary tumors which may also improve IOP control from the regression of the tumors.¹⁹ In our patient, local radiation and intravitreal ranibizumab produced both tumor size reduction and regression of neovascularization. However, these treatment modalities were ineffective in IOP control. The failure of IOP control was possibly related to extensive anterior chamber angle involvement of the tumor. MPTLT was then performed as the patient suffered from painful ocular hypertension.

The prognosis of intraocular metastasis is generally poor with 5-year survival of 13% in patients with primary lung cancer.⁵ The median survival time following intraocular metastasis was approximately 6 months in patients with lung cancer.²⁰ Painful uncontrolled glaucoma can cause deleterious effects on the patient's physical and mental health and overall quality of life as witnessed in our patient. MPTLT provided rapid IOP reduction in our case with alleviation of severe ocular pain. The patient could then be discharged from the hospital to spend the rest of her time with family at home significantly improving her quality of life. Since the patient got worse from complications resulting from advanced stage of the disease and died soon after the procedure, we could not evaluate long-term efficacy and late complications of MPTLT in treating uncontrolled glaucoma secondary to ciliary body metastasis. Based on this case and previous findings, MPTLT should be considered as an alternative treatment option in patients with painful uncontrolled glaucoma due to intraocular metastasis.

4. Conclusion

MPTLT can be a safe and effective procedure for IOP control in intraocular metastasis patients with uncontrolled glaucoma.

Patient consent

Consent to publish this report was not obtained. This report does not contain any personal information that could identify the patient.

Funding

No funding or grant support.

Authorship

All authors attest that they meet the current ICMJE criteria for

Authorship.

Declaration of competing interest

All authors have no financial disclosures.

Acknowledgements

None.

References

- Valent DJ, Augsburger JJ, Corrêa ZM. Embryonal carcinoma of testis metastatic to ciliary body presenting as spontaneous hyphema and painful secondary glaucoma. *Retin Cases Brief Rep.* 2013;7(1):105–107. <https://doi.org/10.1097/ICB.0b013e318275380b>.
- El-Harazi SM, Kellaway J, Feldman RM. Semiconductor diode laser transscleral cyclophotocoagulation in a patient with glaucoma secondary to metastatic tumor to the iris. *J Glaucoma.* 1998;7(5):317–318.
- Nakashima C, Keino H, Watanabe T, Taki W, Okada AA. Intravitreal bevacizumab for iris metastasis of small-cell lung carcinoma with neovascular glaucoma. *Jpn J Ophthalmol.* 2011;55(1):80–81. <https://doi.org/10.1007/s10384-010-0892-z>.
- Makri OE, Psachoulia C, Exarchou A, Georgakopoulos CD. Intravitreal ranibizumab as palliative therapy for iris metastasis complicated with refractory secondary glaucoma. *J Glaucoma.* 2016;25(1):e53–55. <https://doi.org/10.1097/IJG.0000000000000163>.
- Shields CL, Welch RJ, Malik K, et al. Uveal Metastasis: clinical features and survival outcome of 2214 tumors in 1111 patients based on primary tumor origin. *Middle East Afr J Ophthalmol.* 2018;25(2):81–90. https://doi.org/10.4103/meajo.MEAJO_6_18.
- Shields CL, Shields JA, Shields MB, Augsburger JJ. Prevalence and mechanisms of secondary intraocular pressure elevation in eyes with intraocular tumors. *Ophthalmology.* 1987;94(7):839–846. [https://doi.org/10.1016/s0161-6420\(87\)33537-7](https://doi.org/10.1016/s0161-6420(87)33537-7).
- Camp DA, Yadav P, Dalvin LA, Shields CL. Glaucoma secondary to intraocular tumors: mechanisms and management. *Curr Opin Ophthalmol.* 2019;30(2):71–81. <https://doi.org/10.1097/ICU.0000000000000550>.
- Kaliki S, Eagle RC, Grossniklaus HE, Campbell RJ, Shields CL, Shields JA. Inadvertent implantation of aqueous tube shunts in glaucomatous eyes with unrecognized intraocular neoplasms: report of 5 cases. *JAMA Ophthalmol.* 2013;131(7):925–928. <https://doi.org/10.1001/jamaophthalmol.2013.828>.
- Chen M-J, Liu J-L, Li W-Y, Lee F-L, Chou C-K, Hsu W-M. Diode laser transscleral cyclophotocoagulation in the treatment of refractory glaucoma with iris melanocytoma. *J Chin Med Assoc.* 2008;71(10):546–548. [https://doi.org/10.1016/S1726-4901\(08\)70166-7](https://doi.org/10.1016/S1726-4901(08)70166-7).
- Nguyen AT, Maslin J, Noecker RJ. Early results of micropulse transscleral cyclophotocoagulation for the treatment of glaucoma. *Eur J Ophthalmol.* 2020;30(4):700–705. <https://doi.org/10.1177/1120672119839303>.
- Sanchez FG, Lerner F, Sampaolesi J, et al. Efficacy and safety of Micropulse® transscleral cyclophotocoagulation in glaucoma. *Arch Soc Esp Ophthalmol.* 2018;93(12):573–579. <https://doi.org/10.1016/j.oftal.2018.08.003>.
- Sanchez FG, Peirano-Bonomi JC, Grippo TM. Micropulse transscleral cyclophotocoagulation: a hypothesis for the ideal parameters. *Med Hypothesis, Discov Innovation (MEHDI) Ophthalmol.* 2018;7(3):94–100.
- Varikuti VNV, Shah P, Rai O, et al. Outcomes of micropulse transscleral cyclophotocoagulation in eyes with good central vision. *J Glaucoma.* 2019;28(10):901–905. <https://doi.org/10.1097/IJG.0000000000001339>.
- Aquino MCD, Barton K, Tan AMWT, et al. Micropulse versus continuous wave transscleral diode cyclophotocoagulation in refractory glaucoma: a randomized exploratory study. *Clin Exp Ophthalmol.* 2015;43(1):40–46. <https://doi.org/10.1111/ceo.12360>.
- Shukla AG, Vaidya S, Yaghy A, et al. Transscleral cyclophotocoagulation for glaucoma in the setting of uveal melanoma. *Ophthalmol Glaucoma.* 2020. <https://doi.org/10.1016/j.ogla.2020.09.011>. Published online September 18.
- Lampaki S, Kioumis I, Pitsiou G, et al. Lung cancer and eye metastases. *Med Hypothesis, Discov Innovation (MEHDI) Ophthalmol.* 2014;3(2):40–44.
- Hidaka T, Chuman H, Nao-I N. A case report of intravitreal bevacizumab for Iris metastasis of small cell lung carcinoma with neovascular glaucoma. *Case Rep Ophthalmol.* 2018;9(2):401–404. <https://doi.org/10.1159/000492713>.
- Thulliez M, Angoultant D, Le Lez ML, et al. Cardiovascular events and bleeding risk associated with intravitreal anti-vascular endothelial growth factor monoclonal antibodies: systematic review and meta-analysis. *JAMA Ophthalmol.* 2014;132(11):1317–1326. <https://doi.org/10.1001/jamaophthalmol.2014.2333>.
- Groenewald C, Konstantinidis L, Damato B. Effects of radiotherapy on uveal melanomas and adjacent tissues. *Eye.* 2013;27(2):163–171. <https://doi.org/10.1038/eye.2012.249>.
- Freedman MI, Folk JC. Metastatic tumors to the eye and orbit. Patient survival and clinical characteristics. *Arch Ophthalmol.* 1987;105(9):1215–1219. <https://doi.org/10.1001/archophth.1987.01060090073031>.