

Case Report

An unusual case of penetrating eye injury caused by a bird: A case report with review of the pertinent literature



Eman M. Al-Sharif^{a,*}; Abdullah S. Alkharashi^b

Abstract

Penetrating eye injuries caused by bird pecking are uncommon with less than 40 cases reported in the literature. In this article, we present a case of penetrating ocular injury caused by a bird along with pertinent literature review. An otherwise healthy 56-year old man presented to the emergency department complaining of right eye severe pain and decreased vision following trauma caused by a bittern bird. The patient was diagnosed with penetrating ocular injury & he underwent primary repair. On follow up, he was found to have traumatic cataract, which was operated, however, the surgery was complicated with IOL dislocation into the vitreous cavity. The patient was referred to retina service where he underwent pars plana vitrectomy with IOL repositioning in the sulcus. After two months, the patient's uncorrected visual acuity improved from counting fingers at 2 feet to 20/30⁻². This case serves as a reminder that bird pecking is one of the causes of penetrating eye trauma.

Keywords: Penetrating eye injury, Open globe injury, Bird pecking, Bittern bird

© 2019 The Authors. Production and hosting by Elsevier B.V. on behalf of Saudi Ophthalmological Society, King Saud University. This is an open access article under the CC BY-NC-ND license (<http://creativecommons.org/licenses/by-nc-nd/4.0/>).
<https://doi.org/10.1016/j.sjopt.2018.12.007>

Introduction

Penetrating eye injuries caused by pecking of birds are extremely uncommon, with less than 40 cases reported in the literature to date. In this article, we present a case of penetrating ocular injury caused by a little bittern bird along with literature review further elucidating on open globe injuries caused specifically by birds.

Case report

A 56 years old gentleman presented to the emergency department complaining of severe pain, redness and decreased vision in his right eye following trauma which

was surprisingly caused by a little bittern bird. The bird attacked the patient's eye immediately after opening the box that the bird was caged in after being caught by his son earlier that day. His past ocular and medical histories were not significant. The patient was diagnosed with penetrating open globe injury & he underwent primary repair in a specialized hospital the next day. On follow up, his intraocular pressure was high in the operated eye with anterior chamber reaction and he was found to have traumatic cataract with ruptured posterior capsule detected on B-scan ultrasonography. He was managed accordingly with maxitrol, cyclopentolate and diclofenac eye drops for one week. Cataract extraction with anterior vitrectomy and PMMA IOL fixation in the sulcus was performed after one month; however,

Received 8 March 2017; received in revised form 14 December 2018; accepted 31 December 2018; available online 7 January 2019.

Abbreviations: VA, Visual Acuity, M, Male, F, Female, OD, Right Eye, OS, Left Eye, LP, Light Perception, NLP, No Light Perception, CF, Counting Fingers

^a Department of Ophthalmology, College of Medicine, King Saud University, P.O. Box 56227, Riyadh 11554, Saudi Arabia

^b Department of Ophthalmology, College of Medicine, King Saud University, P.O. Box 52607, Riyadh 11573, Saudi Arabia

* Corresponding author.

e-mail address: ealsharif@ksu.edu.sa (E.M. Al-Sharif).

the surgery was complicated with IOL dislocation into the vitreous. Therefore, the patient was referred to retina service in a tertiary center for further management. On examination, visual acuity in the traumatized right eye was counting fingers at 2 feet and intra-ocular pressure was within normal. Slit lamp examination of the same eye showed a paracentral corneal scar along with limbal sutures of cataract extraction [Fig. 1]. The anterior chamber was deep with 2+ cells and the eye was aphakic with the IOL dislocated inferiorly into the vitreous cavity. Fundus examination was within normal except for some peripheral retinal changes. B-scan ultrasonography was performed pre-operatively and it showed an aphakic right eye with 360° residual posterior capsule and IOL dislocation inferiorly at 6 o'clock. Posterior pole exhibited a healthy optic disc, flat retina and no breaks. The patient underwent right eye pars plana vitrectomy with IOL repositioning in the sulcus and 360° prophylactic endolaser under local anesthesia. On two months follow up [Fig. 2], the patient was doing well where his uncorrected visual acuity in the right eye improved to 20/30⁻².

Discussion

Bird pecking is a rare cause of open globe injuries, however, it is suggested that ocular injuries caused by birds are

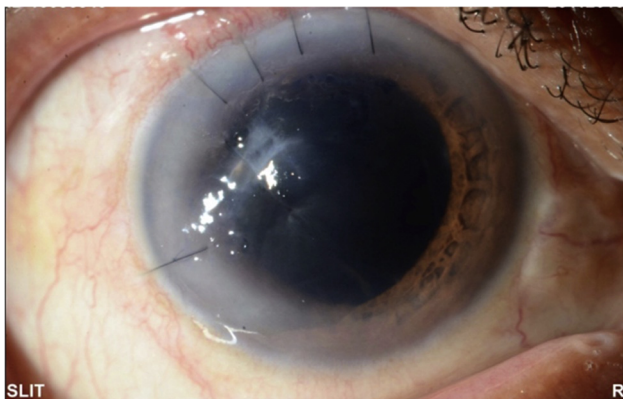


Fig. 1. Colored slit lamp photograph of the right eye showing a paracentral corneal scar secondary to the penetrating trauma.

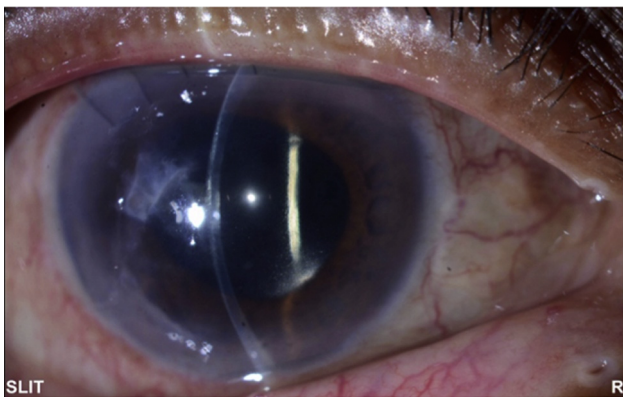


Fig. 2. Colored slit photograph of the right eye on 2 months post-operative follow up showing the paracentral corneal scar and the reflection of the repositioned IOL.

actually underreported because they are perceived as incidental or humorous events.¹ In addition, birds are generally considered to be less unsafe animals as they tend to fly away when sensing danger, but as a matter of fact, some birds may behave aggressively and attack human-beings especially if related to breeding or territoriality.¹⁻³ Birds usually attack humans with either their beaks or claws and these attacks can be provoked or even unprovoked.³

Animal predators intend to harm the prey quickly by targeting its most vulnerable areas. For that reason, the face and the eyes particularly are the birds' favored sites of attack in humans. It is suggested in the literature that the bird's attention is focused on the eye as a result of its target shaped cornea and color contrast compared to the rest of the face.^{3,4} Duke-Elder et al. reported that most human eye bird injuries are caused by owls and roosters.⁵ In addition, Kühl apud Collin reported that these injuries were found to occur more in the spring season and the type of injury varied depending on the type of bird. For example, owls, chickens and cocks usually attack at dusk with their curved beak/claws resulting in severe perforating limbal and scleral injuries with severe damage extending intraocularly and subsequently poor prognosis. In comparison, birds with sharp straight beaks like herons and bitterns are more likely to cause clean central corneal perforating injuries with less intraocular damage and better visual prognosis and outcome.^{6,7} As inferred above, the patient herein our case sustained a clean paracentral perforating corneal injury caused by a bittern bird with good visual outcome [visual acuity: 20/30⁻² on follow up].

We comprehensively reviewed all of the cases of open globe injuries caused by birds that we could retrieve from the English literature. A synopsis of these previously published ocular injuries is presented in Table 1. To the best of our knowledge, our case is one of the few cases of a pecking eye injury caused by a bittern bird with an excellent visual outcome. The age column in Table 1 demonstrates clearly that children between 1-12 years are among the most commonly affected age groups. This is believed to be due to the natural curiosity of children to explore the surroundings, especially living creatures such as animals that appear appealing to them.⁸ This emphasizes the importance of parents supervising their children when being around any kind of bird since all birds are actually dangerous to children and can cause serious sight-threatening eye injuries.³ Although our patient is a middle aged gentleman, it goes without saying that the bird's aggressive behavior here is self-protective and attributed to its imprisonment in a box.

Furthermore, when viewing the table, it comes to our attention immediately that most of patients attacked by birds were males and this is generally consistent with the known predisposition of males to open globe injuries, accounting for 80% of all cases.⁹ It is also noteworthy to mention that some people may be at higher risk of acquiring such injuries because of the nature of their work which puts them in close contact with birds on a daily basis, such as farmers and zoo workers. Thus, it is advisable for them to wear protective goggles or to keep a distance, if possible, when dealing closely with birds.

Poor initial visual acuity at presentation was, overall, associated with less favorable visual outcome on follow up as shown in Table 1. Several complications of penetrating eye injuries caused by bird pecking had been reported in

Table 1. Synopsis of previously reported cases of penetrating eye injuries caused by birds.

Year	Author	Age	Gender	Eye	Bird type	VA		On follow up	Complications
						Initial	Final		
2016	Baskaran et al. ⁸	12	M	OD	Crane beak	6/24	6/12	Traumatic endophthalmitis caused by Beta-hemolytic Streptococci	
2013	Ayanniji et al. ¹⁰	6	M	OS	Domestic hen	LP	2/60	Bulbar atrophy	
2012	Jovanović et al. ¹¹	2	M	OS	Cock's beak	-	-	Traumatic endophthalmitis caused by alpha-hemolytic streptococci	
2006	Lekse et al. ¹²	1	M	OS	rooster	NLP	Un-central, un-sustained, un-maintained	-	
2005	Chaudhry et al. ¹	34	M	OD	Ostrich	NLP	Loss of vision	Isolated traumatic aniridia	
2000	Young et al. ¹³	38	M	OS	Mynah bird	2/200	20/200	Retrolenticular membrane with giant tear and retinal detachment	
1997	Guemes et al. ¹⁴	2	M	OD	Rooster	LP	LP	Retinal detachment and phtthisis	
1996	Kronwith et al. ²	2	F	OD	Rooster (zoo)	-	NLP	-	
1995	Chidambaram et al. ¹⁵	62	F	OD	Hen	-	-	-	
1988	Gray et al. ⁴	2	M	-	Rooster	-	-	-	
1977	Chaddah et al. ¹⁶	2	M	OS	Cock	-	-	-	
1975	Collin et al. ⁷	36	F	OD	Sparrow	CF @ 6 feet	6/24	-	
1875-1970	Kühl et al. ⁶	-	-	-	Owls (10), chicken/cocks (4), blackbirds (2), storks, cranes, herons(5)	-	-	-	

VA: Visual Acuity, M: Male, F: Female, OD: Right Eye, OS: Left Eye, LP: Light Perception, NLP: No Light Perception, CF: Counting Fingers.

literature, namely: lens abscess, retinal detachment, traumatic aniridia, bulbar atrophy/phthisis and post-traumatic endophthalmitis.^{2,5,8,11,12,13} Essex and colleagues stated that the devastating post-traumatic endophthalmitis occurs in 7% of penetrating eye traumas.¹⁷ Factors previously reported to increase the risk of post-traumatic endophthalmitis are delayed primary repair, ruptured lens capsule and dirty wound, with those having two or more of these factors categorized as high risk patients.¹⁷ Through our review of English literature, there were only two cases who developed endophthalmitis after bird pecking; both were caused by gram positive bacteria belonging to the alpha and beta hemolytic streptococcal species.^{8,12} Thus, Baskaran et al. recommended considering intravitreal antibiotics with primary repair and early core vitrectomy in high risk patients after bird beak injuries.⁸

Conclusion

In conclusion, this case serves as a reminder that bird pecking is an important cause and potentially blinding ocular trauma that is less frequent than other causes. Moreover, it also emphasizes that recognizing different mechanisms of injury & vulnerable age groups is important for effective prevention strategies. Children are at highest risk of bird injuries, thus, particular attention should be paid to maintain their safety especially at hazardous places such as farms.

This research did not receive any specific grant from funding agencies in the public, commercial, or not-for-profit sectors.

Conflict of interest

We have no conflict of interest to declare.

References

- Chaudhry IA, Al-Sharif AM, Hamdi M. Severe ocular trauma caused by an ostrich. *Br J Ophthalmol* 2005;**89**(2):250-1.
- Kronwith SD, Hankin DE, Lipkin PH. Ocular injury from a rooster attack. *Clin Pediatr (Phila)* 1996;**35**:219-20.
- Chimdi M, Chuka-Okosa CM. Pecking injury of the eye by a hen: a case-report. *J Coll Med* 2002;**7**(1):33-4.
- Gray R, Thompson J, MacRae D, et al. Pecking injury of the eye. *New Engl J Med* 1988;**319**:1021-2.
- Duke-Elder S, MacFaul P. Perforating wounds of the eye. In: Duke Elder S, editor. *System of ophthalmology*. St. Louis (MO): C.V. Mosby; 1972. p. 324.
- Kühl W. Augenverletzungen durch Vogel [Eye injuries caused by birds]. *Klin Monatsbl Augenheilkd* 1970;**157**:810-5.
- Collin JR. Ocular perforating injury caused by a sparrow. *Br Med J* 1975;**3**(5982):520-1.
- Baskaran P, Ramakrishnan S, Dhoble P, et al. Traumatic endophthalmitis following a crane pecking injury - An unusual mode. *GMS* 2016;**6**:2193-6.
- Koo L, Kapadia MK, Singh RP, et al. Gender differences in etiology and outcome of open globe injuries. *J Trauma* 2005;**59**:175-8.
- Ayanniji AA, Monsudi KF, Danfulani M, et al. Unilateral blindness in a six-year-old boy following penetrating eye injury from a domestic hen peck. *JRSM Short Reports* 2013;**4**(2):9.
- Jovanović M, Bobić-Radovanović A, Vuković D, et al. Unusual eye injuries. *Acta Chir Jugosl* 2012;**59**(1):101-4.
- Lekse Kovach J, Maguluri S, Recchia FM. Subclinical endophthalmitis following a rooster attack. *J AAPOS* 2006;**10**(6):579-80.
- Young AL, Cheng LL, Rao SK, et al. Corneal laceration with total but isolated aniridia caused by a pecking injury. *JCRS* 2000;**26**(9):1419-21.

14. Guemes A, Wright KW, Humayun M, et al. Leukocoria caused by occult penetrating trauma in a child. *Am J Ophthalmol* 1997;124(1):117–9.
15. Chidambaram S. Pecking injury to the eye. *Singapore Med* 1995;36(3):338.
16. Chaddah MR, Aggarwal DC. Pecking injury of the cornea. *Indian J Ophthalmol* 1977;25:9.
17. Essex RW, Yi Q, Charles PG, et al. Post-traumatic endophthalmitis. *Ophthalmology* 2004;111(11):2015–22.