



## Case report

# Morselized bone autograft for high placement of acetabular component closure with hip arthroplasty revision after 3-years screws and cup loosening: A case report

Yunus Abdul Bari <sup>a,\*</sup>, <sup>1</sup>, Mohammad Zaim Chilmi <sup>b</sup>, Huda Fajar Arianto <sup>c</sup>, Bagus Wibowo Soetojo <sup>d</sup>

<sup>a</sup> Department of Orthopedic and Traumatology, Universitas Airlangga Teaching Hospital, Surabaya, East Java, Indonesia

<sup>b</sup> Department of Orthopedic and Traumatology, Dr. Soetomo General Hospital, Surabaya, East Java, Indonesia

<sup>c</sup> Department of Orthopedic and Traumatology, Universitas Airlangga Teaching Hospital, Surabaya, East Java, Indonesia

<sup>d</sup> Department of Orthopedic and Traumatology, Dr. Soetomo General Hospital, Surabaya, East Java, Indonesia

## ARTICLE INFO

## Keywords:

High placement acetabular  
Total hip arthroplasty revision  
Morselized bone autograft  
Case report

## ABSTRACT

**Introduction and importance:** Aseptic loosening in high placement of the acetabular component seriously affects the hip and femoral head loads. Surgery revision is highly recommended with defect closure in previous place. **Case presentation:** A 40-year-old man came with chief complaint of right groin pain and noticeable leg length discrepancy gait. The first hip arthroplasty through pseudo-acetabulum cup was done three years ago after neglected femoral head necrosis due to eight years of unknown hip dislocation in vehicle accident. On hip x-ray there is a screws and cup loosening, without any sign of infection from blood or from soft tissue which undergoes pathological and mold examination. The patient than assessed with periprosthetic aseptic loosening of hip dextra and simple total hip arthroplasty revision using true acetabulum location was done. The pseudo-acetabulum area closed with morselized bone autograft. One weeks after surgery, the wound healed properly. Hence, the patient sent to the rehabilitation.

**Clinical discussion:** Hip arthroplasty revision of aseptic loosening in high placement acetabular component should perform by returning to anatomical acetabular position. Cancellous morselized bone autograft (MBA) was used to closed the defect formed by previous procedure.

**Conclusion:** Revision of hip arthroplasty combined with morselized bone autograft can be considered for high placement acetabular component defect closure to provide better stability and strength in weight loads transfer.

## 1. Introduction

Among every surgical discipline in the United States, one out of 5 leading surgical procedure that the most frequently performed and the most expanding procedure is primary total hip arthroplasty (THA) [1]. Furthermore, many studies said the use of high placement of acetabular component was known as an option technique in patient with several condition undergoing hip arthroplasty [2,3]. However, the large amount of primary THA directly proportional to elevating of revision total hip arthroplasty (rTHA) demand with nearly 100.000 procedure estimated in 2030 [4]. In 2015 until 2018, Australian orthopedic centre analysed that 2–3 % of the total 120.000 patient with primary THA will undergo the revision of THA with the most frequent causes is periprosthetic fracture and loosening [5].

Autologous bone graft in which consist of cancellous, cortical, vascularized bone graft and bone marrow aspirates, known as the primary choice in bone defects or non-union case setting because of its marvelous fusion of osteogenic, osteoconductive and osteoinductive component [6]. The morselized bone graft previously used in hip arthroplasty revision using reamed fresh frozen femoral head allograft to close the acetabular defect, was clinically and radiographically successful in 95 % of the patient [7]. In this present study, we reporting a hip arthroplasty revision for aseptic loosening due to high placement of acetabular component case with local morselized bone autograft for defect closure. This work has been reported in line with SCARE criteria and the consent was obtained from the patient for publication of this report [8].

\* Corresponding author at: Department of Orthopedics, Universitas Airlangga Teaching Hospital, Jalan Dharmahasada Permai, East Java 60155, Indonesia.  
E-mail address: [yunus@fk.unair.ac.id](mailto:yunus@fk.unair.ac.id) (Y.A. Bari).

<sup>1</sup> Jalan Kalikepiting KAV, 125/A-5, Surabaya, East Java Indonesia.

<https://doi.org/10.1016/j.ijscr.2022.107789>

Received 13 September 2022; Received in revised form 20 November 2022; Accepted 20 November 2022

Available online 22 November 2022

2210-2612/© 2022 The Authors. Published by Elsevier Ltd on behalf of IJS Publishing Group Ltd. This is an open access article under the CC BY-NC-ND license (<http://creativecommons.org/licenses/by-nc-nd/4.0/>).

## 2. Presentation of case

A-40 years old Javanese man, came to our polyclinic with major complaint of pain in right groin and become shorter day by day. In 2011, the patient was involved in motorcycle accident, and was diagnosed with right hip dislocation. After closed reduction, patient ordered to take a bed rest for nearly one month and continue with walk training using crutch. There was no doctor visit recorded again until March 2019, the patient back to orthopedic doctor in previous hospital and the doctor decided to do the total right hip arthroplasty. After the procedure, actually the patient still feels the pain, but the Covid-19 come and the patient never come back to the doctor.

The physical examination obviously seen that there is a leg length discrepancy gait, the right leg length is  $\pm 2.5$  cm shorter than the left leg. From the CBC, CRP, Procalcitonin laboratory examination, it appears no sign of ongoing infection. There was no other significant conditions and no history of drugs and smoke. Post first hip arthroplasty pelvic x-ray examination reveal, the procedure was conduct in slightly high placement of acetabular cup (Fig. 1). Latest hip x-ray and 3D CT-Scan found a sign of loosening space around the acetabular cup and femoral stem also true acetabulum space was filled with calcified matters (Fig. 2A, B and C). The patient than diagnosed with periprosthetic aseptic loosening and scheduled for revision of total right hip arthroplasty.

The first surgery by senior orthopedic was taken to take a sample of blood and soft tissue culture from the local site and there was no sign of infection either tuberculosis or mold. In the second surgery, after the old prosthetic implant was removed, the true acetabular location that was closed with a bony structure reamed to create local morselized bone graft. Through this process, revealed that the defect on the true acetabular roof was  $<30\%$ . The new hip prosthetic using the largest titanium stem and acetabular cup that we have, implanted in true acetabular location while the old and pseudo acetabular location was closed with morselized bone graft (Fig. 3A). The wound healed nicely after 1 week's post-surgery, then the patient ordered to rehabilitation for non-weight bearing walk training. Pelvic CT-Scan 3 months after procedure shows bone calcification of the pseudo-acetabular location (Fig. 3B). The patient feels great and can back to the normal activity as before.

## 3. Discussions

Motor vehicle accident with direct axial load through limb are the most frequently posterior hip dislocation causes, in which if this condition not handled properly, it could be a recurrent event with certain complication of avascular necrosis (AVN) of the femoral head in 6

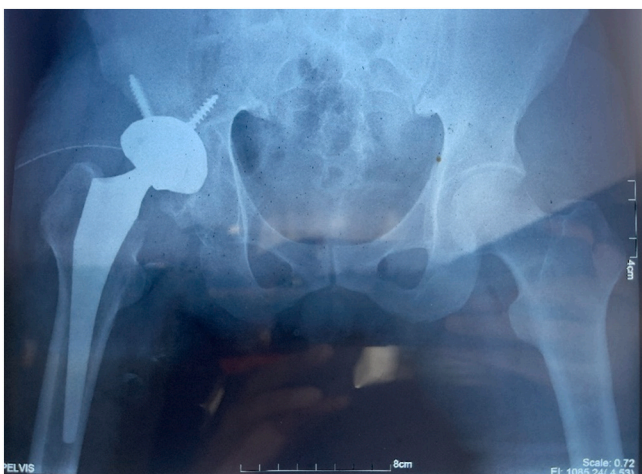


Fig. 1. Pelvic X-Ray after first hip arthroplasty.

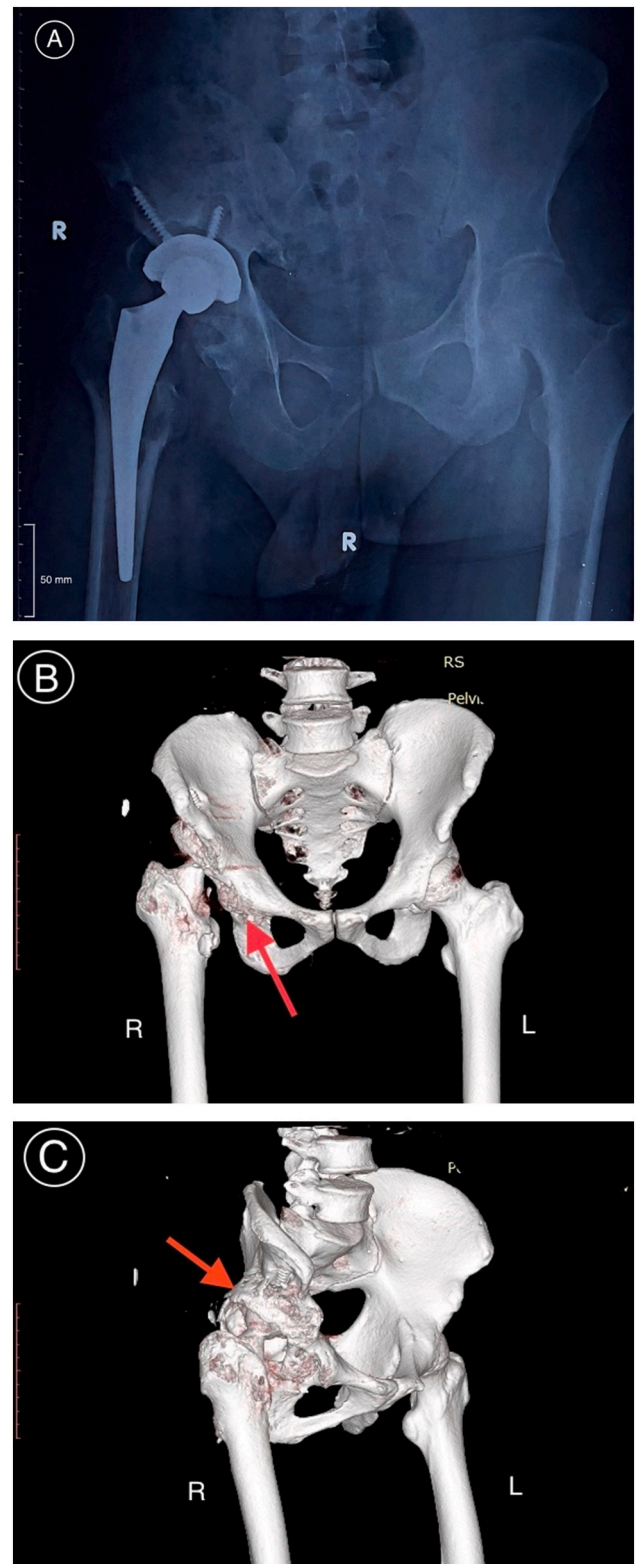
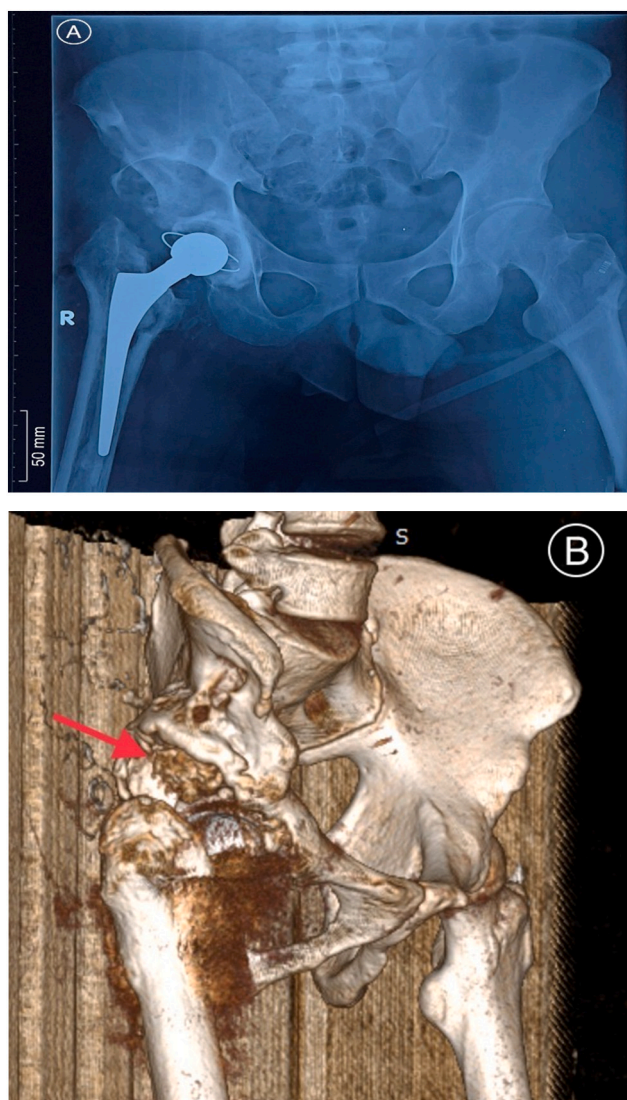


Fig. 2. Recent Pelvic X-Ray (A), with CT-Scan that indicates the bony structure encapsulated the true acetabular (B, C).

months until 2 years after the injury [9]. From our patient, we knew that after the first hip dislocation was treated with closed reduction only and never came back to the doctor. Meanwhile, several studies shows that closed reduction and traction only successful in  $<50\%$  of the adult patient within a limited time, if the reduction was not achieved the AVN



**Fig. 3.** Pelvic X-Ray post THA revision (A), and 3 month follow up CT-Scan shows that the morselized graft was calcified and support the acetabular roof (B).

happens in 100 % of neglected dislocation that has been treated only with traction and reduction, including formation of a fibrous layer in acetabulum [10,11].

According to reports in United Kingdom's, 5 % of the THA was for neck femur fracture, 2 % was for AVN, dysplasia and inflammatory arthritis [12,13]. Main purpose of this procedure was placing cups in the true acetabulum location to achieve the anatomic hip centre, but in some cases such as neglected hip dislocation and hip dysplasia, the true acetabular location quietly hard to find and the option was place the cups at the high hip centre [14]. High hip centre was a controversial technique which is only done in severe acetabulum bony deficiency, where most of the bone left was in superior to the anatomic hip centre that accessible by the surgeons [15]. The usage of this technique normally will alter the anatomic location of the reconstructed acetabulum and will affect the hip function involving muscle through the axial loading forces including the reduction of hip flexion range of movement (ROM) and higher risk of cup dislocation that has been observed by computer simulation study with systematic review [14–16]. The data in our patient from primary THA shows the acetabular cups was placed  $\pm 35$  mm superior to the vertical centre of rotation (COR), it was also mention in a reports from 51 patients undergoing high hip centre

arthroplasty revision with mean height 43 mm above inter-teardrop line compared with 14 mm from normal anatomic centre height and no acetabular component migrated [3]. On the other hand, study in one of our centre involving 20 patient undergoes THA in anatomical location of acetabulum with acetabular defect mention that 3-years follow up in Paprosky Type 3, 75 % of the patient was likely to experience the implant migration [17].

Until now, the controversy still continue with many comparative study reveal two contradictory results especially in congenital dysplasia of the hip, one study will said there is a significant improvement of Harris hip score, no loosening of acetabular and femoral component during 15 years of follow up but the other study said that cup placement  $>15$  mm superior to the approximate anatomical location will lead to increased rate of loosening [18,19]. Aseptic loosening of the primary THA was known for major causes of revision especially in young male with high activity level and early osteoarthritis in cemented or uncemented prosthesis [20,21]. It could happens by three combination of mechanism, unqualified initial fixation, mechanical loss of fixation during time or biological fixation loss due to osteolysis around implant that induced by particulate with a simple three diagnostic component, accurate history and clinical examination including laboratory investigation and imaging [4]. However, this should be prevented by combining good osseointegration for uncemented prosthesis, excellent physical characteristic of the implant, great implant choosing for every patient bone characteristic, and the patient conditions and compliance needs to be optimize [22].

Morselized bone autograft that can be obtained from cortical or cancellous bone, simply known as a very small size bone graft to fill bone defect and promote new bone growth, with their marvellous properties of autologous bone graft [7,23]. Study involving 60 patient comparing usage of cortical and cancellous morselized bone allograft through Harris hip score indicates that cortical morselized bone allograft was slightly better in mechanical function but many studies also reported that in terms of remodelling of the graft, bridging trabeculation was observed slightly more fast (4 weeks) than cortical, and in long term follow-up study (mean 12.3 years) cancellous morselized bone graft had an average 94 % of survival rate [24–26]. According to the mentioned study we use cancellous MBA that reamed from true acetabular bone of the patient to fill the defect created from previous hip arthroplasty, in fact in perioperative we knew that patient only lost  $<20$  % of the acetabular bone stock and the patient was achieved an optimized condition after the revision procedure.

#### 4. Conclusion

The gold standard procedure of the primary THA was placed the acetabular component prosthesis into the anatomical location. However, in some condition it could be placed in the high hip centre with a certain complication such as loosening and the revision THA should be taken. Revision of hip arthroplasty combined with morselized bone autograft can be considered for high placement acetabular component defect closure. Because, this graft could support the acetabular roof and could provide better stability and strength in weight loads transfer in the future. Nevertheless, this patient still needs future follow-up to assess the total active motion, also the assessment of Harris Hip Score.

#### Sources of funding

None.

#### Ethical approval

This study has been approved by the Ethical Committee of Universitas Airlangga Hospital, Surabaya, Indonesia.

**Consent**

The patient consent regarding this study was obtained.

**Registration of research studies**

None.

**Guarantor**

Yunus Abdul Bari

**Provenance and peer review**

Not commissioned, externally peer-reviewed.

**CRedit authorship contribution statement**

All author has been involved in all stage of study concept and writing the paper.

**Declaration of competing interest**

None.

**References**

- [1] A.M. Schwartz, K.X. Farley, G.N. Guild, T.L. Bradbury, Projections and epidemiology of revision hip and knee arthroplasty in the United States to 2030, *J. Arthroplast.* 35 (6) (2020) S79–S85, <https://doi.org/10.1016/j.arth.2020.02.030>.
- [2] K.J. Hendricks, W.H. Harris, High placement of noncemented acetabular components in revision total hip arthroplasty. A concise follow-up, at a minimum of fifteen years, of a previous report, *J. Bone Jt. Surg.* 88 (10) (2006) 2231–2236, <https://doi.org/10.2106/JBJS.E.00247>.
- [3] S.F. Schutzer, W.H. Harris, High placement of porous-coated acetabular components in complex total hip arthroplasty, *J. Arthroplast.* 9 (4) (1994) 359–367, [https://doi.org/10.1016/0883-5403\(94\)90045-0](https://doi.org/10.1016/0883-5403(94)90045-0).
- [4] U. Anil, V. Singh, R. Schwarzkopf, Diagnosis and detection of subtle aseptic loosening in total hip arthroplasty, *J. Arthroplast.* (2022) 1–7, <https://doi.org/10.1016/j.arth.2022.02.060>. Published online.
- [5] W. Hoskins, R. Bingham, M. Lorimer, A. Hatton, N.R. de Steiger, Early rate of revision of total hip arthroplasty related to surgical approach, *J. Bone Jt. Surg.* 90 (10) (2020) 1874–1882, <https://doi.org/10.1111/ans.16149>.
- [6] T.T. Roberts, A.J. Rosenbaum, Bone grafts, bone substitutes and orthobiologics: the bridge between basic science and clinical advancements in fracture healing, *Organogenesis* 8 (4) (2012) 114–124, <https://doi.org/10.4161/org.23306>.
- [7] G. Etienne, H.P. Bezwada, D.S. Hungerford, M.A. Mont, The incorporation of morselized bone grafts in cementless acetabular revisions, *Clin. Orthop. Relat. Res.* (2004) 428. [https://journals.lww.com/clinorthop/Fulltext/2004/11000/The\\_Incorporation\\_of\\_Morselized\\_Bone\\_Grafts\\_in.38.aspx](https://journals.lww.com/clinorthop/Fulltext/2004/11000/The_Incorporation_of_Morselized_Bone_Grafts_in.38.aspx).
- [8] R.A. Agha, T. Franchi, C. Sohrabi, et al., The SCARE 2020 guideline: updating consensus surgical CAse REport (SCARE) guidelines, *Int. J. Surg.* 84 (2020) 226–230, <https://doi.org/10.1016/j.ijsu.2020.10.034>.
- [9] S. Milenkovic, M. Mitkovic, M. Mitkovic, Avascular necrosis of the femoral head after traumatic posterior hip dislocation with and without acetabular fracture, *Eur. J. Trauma Emerg. Surg.* 48 (1) (2022) 613–619, <https://doi.org/10.1007/s00068-020-01495-x>.
- [10] M. Jain, S. Swaroop, D.S. Kumar, Neglected posterior hip dislocation in adults presenting after one year managed successfully with single stage Total hip arthroplasty: a case series, *J. Orthop. Case Rep.* 11 (6) (2021) 84–88, <https://doi.org/10.13107/jocr.2021.v11.i06.2270>.
- [11] R.O.E. Gardner, N. Worku, T.R. Nunn, T.T. Zerfu, M.E. Kassahun, Management of neglected traumatic hip dislocation in children, *J. Pediatr. Orthop.* 40 (7) (2020) e554–e559, <https://doi.org/10.1097/BPO.0000000000001535>.
- [12] M.S. Abdelaal, C. Restrepo, P.F. Sharkey, Global perspectives on arthroplasty of hip and knee joints, *Orthop. Clin. N. Am.* 51 (2) (2020) 169–176, <https://doi.org/10.1016/j.ocl.2019.11.003>.
- [13] R.J. Ferguson, A.J. Palmer, A. Taylor, M.L. Porter, H. Malchau, S. Glyn-Jones, Hip replacement, *Lancet (London, England)* 392 (10158) (2018) 1662–1671, [https://doi.org/10.1016/S0140-6736\(18\)31777-X](https://doi.org/10.1016/S0140-6736(18)31777-X).
- [14] P. Stirling, M.R. Viamont-Guerra, L. Strom, et al., Does cup position at the high hip center or anatomic hip center in THA for developmental dysplasia of the hip result in better Harris hip scores and revision Incidence? A systematic review, *Clin. Orthop. Relat. Res.* 479 (5) (2021) 1119–1130, <https://doi.org/10.1097/CORR.0000000000001618>.
- [15] M. Tanzer, Role and results of the high hip center, *Orthop. Clin. N. Am.* 29 (2) (1998) 241–247, [https://doi.org/10.1016/s0030-5898\(05\)70322-9](https://doi.org/10.1016/s0030-5898(05)70322-9).
- [16] K. Komiyama, Y. Nakashima, M. Hirata, D. Hara, Y. Kohno, Y. Iwamoto, Does high hip center decrease range of motion in total hip arthroplasty? A computer simulation study, *J. Arthroplast.* 31 (10) (2016) 2342–2347, <https://doi.org/10.1016/j.arth.2016.03.014>.
- [17] M.Z. Chilmi, Y.A. Suwandani, D.N. Utomo, J. Andrianus, Clinical and radiological evaluation of post total hip arthroplasty patients with acetabulum defect, *J. Clin. Orthop. Trauma* 10 (2) (2019) 358–363, <https://doi.org/10.1016/j.jcot.2018.05.013>.
- [18] W. Pagnano, A.D. Hanssen, D.G. Lewallen, W.J. Shaughnessy, The effect of superior placement of the acetabular component on the rate of loosening after total hip arthroplasty, *J. Bone Joint Surg. Am.* 78 (7) (1996) 1004–1014, <https://doi.org/10.2106/00004623-199607000-00004>.
- [19] T. Murayama, H. Ohnishi, S. Okabe, et al., 15-year comparison of cementless total hip arthroplasty with anatomical or high cup placement for crowe I to III hip dysplasia, *Orthopedics* 35 (3) (2012) e313–e318, <https://doi.org/10.3928/01477447-20120222-28>.
- [20] J.J. Prokopetz, E. Losina, R.L. Bliss, J. Wright, J.A. Baron, J.N. Katz, Risk factors for revision of primary total hip arthroplasty: a systematic review, *BMC Musculoskelet. Disord.* 13 (2012) 251, <https://doi.org/10.1186/1471-2474-13-251>.
- [21] J.J. Cherman, J.J. Jauregui, S. Banerjee, T. Pierce, M.A. Mont, What host factors affect aseptic loosening after THA and TKA? *Clin. Orthop. Relat. Res.* 473 (8) (2015) 2700–2709, <https://doi.org/10.1007/s11999-015-4220-2>.
- [22] D. Apostu, O. Lucaciu, C. Berce, D. Lucaciu, D. Cosma, Current methods of preventing aseptic loosening and improving osseointegration of titanium implants in cementless total hip arthroplasty: a review, *J. Int Med Res.* 46 (6) (2018) 2104–2119, <https://doi.org/10.1177/0300060517732697>.
- [23] H.C. Pape, A. Evans, P. Kobbe, Autologous bone graft: properties and techniques, *J. Orthop. Trauma* 24 (Suppl 1) (2010) S36–S40, <https://doi.org/10.1097/BOT.0b013e3181ccc4a1>.
- [24] M. Kligman, D.E. Padgett, R. Vered, M. Roffman, Cortical and cancellous morselized allograft in acetabular revision total hip replacement: minimum 5-year follow-up, *J. Arthroplast.* 18 (7) (2003) 907–913, [https://doi.org/10.1016/s0883-5403\(03\)00337-1](https://doi.org/10.1016/s0883-5403(03)00337-1).
- [25] H. Ogawa, Y. Ito, M. Itokazu, et al., Morselized bone grafting for acetabular deficiency in cementless total hip arthroplasty, *Orthopedics* 31 (10) (2008).
- [26] M.L. Welten, B.W. Schreurs, P. Buma, N. Verdonchot, T.J. Slooff, Acetabular reconstruction with impacted morselized cancellous bone autograft and cemented primary total hip arthroplasty: a 10- to 17-year follow-up study, *J. Arthroplast.* 15 (7) (2000) 819–824, <https://doi.org/10.1054/arth.2000.7110>.