

## Postoperative Seroma Deep to Mesh after Laparoscopic Ventral Hernia Repair: Computed Tomography Appearance and Implications for Treatment

Paul D. Scott, Kristi L. Harold, Randall O. Craft, Catherine Celeste Roberts

We report the development of a seroma deep to a mesh prosthesis used for laparoscopic ventral hernia repair (LVHR). Seroma formation anterior to mesh after LVHR is very common; however, the formation of a deep seroma has been rarely reported in the literature and the imaging appearance of a seroma posterior to mesh after LVHR has not been previously described. We present the imaging appearance and our clinical results of aspirating two seromas posterior to mesh after LVHR.

### Introduction

The imaging appearance of a seroma forming posterior to a mesh prosthesis after laparoscopic ventral hernia repair (LVHR) has not been previously reported in the literature. Furthermore, no clinical experience with or guidelines have been published to direct therapy for this type of

seroma. We are aware of two cases of seroma formation deep to prosthetic mesh after LVHR at our institution. Following percutaneous aspiration, both patients developed an infected seroma and ultimately required surgical removal of their mesh.

### Case Report

A 56 year old man presented for evaluation of a ventral hernia six months after undergoing orthotopic liver transplantation. Following the patient's transplantation, his post-operative course had been complicated by an open primary hernia repair without mesh on post-operative day 20 due to early incisional hernia. At the time of this evaluation, the patient was complaining of abdominal pain and was concerned because the incisional hernia had recurred and was expanding. He was seeking surgical consultation for laparoscopic ventral hernia repair.

Physical examination revealed a large ventral hernia that was easily reduced. His chevron incision was well healed. There was no ascites. The remainder of the physical exam

---

Citation: Scott PD, Harold KL, Craft RO, Roberts CC. Postoperative seroma deep to mesh after laparoscopic ventral hernia repair: computed tomography appearance and implications for treatment. *Radiology Case Reports*. [Online] 2008;3:128.

Copyright: © 2008 Paul D. Scott. This is an open-access article distributed under the terms of the Creative Commons Attribution-NonCommercial-NoDerivs 2.5 License, which permits reproduction and distribution, provided the original work is properly cited. Commercial use and derivative works are not permitted.

Abbreviations: CT, computed tomography; LVHR, laparoscopic ventral hernia repair; MRSA, methicillin-resistant staphylococcus aureus; PTFE, polytetrafluoroethylene

Paul D. Scott (Email: [scott.paul@mayo.edu](mailto:scott.paul@mayo.edu)), Kristi L. Harold (Email: [harold.kristi@mayo.edu](mailto:harold.kristi@mayo.edu)) and Randall O. Craft (Email: [craft.randall@mayo.edu](mailto:craft.randall@mayo.edu)) are in the Department of Surgery, Mayo Clinic, 13400 East Shea Boulevard, Scottsdale, AZ 85259, United States.

Catherine Celeste Roberts. (Email: [roberts.catherine@mayo.edu](mailto:roberts.catherine@mayo.edu)), is in the Department of Radiology, Mayo Clinic, 5777 E. Mayo Boulevard, Phoenix, AZ 85054, United States.

Published: January 13, 2008

DOI: 10.2484/rcr.3i1.128

## Postoperative Seroma Deep to Mesh after Laparoscopic Ventral Hernia Repair: Computed Tomography Appearance and Implications for Treatment

was within normal limits.

The patient elected to undergo a laparoscopic ventral hernia repair with mesh. A 31 X 26 cm polytetrafluoroethylene (PTFE) mesh was used to cover a 21 X 16 cm defect. This provided a 5 cm overlap beyond the edges of the fascial defect. The mesh was secured using number one GORE-TEX® suture (W.L. Gore and Associates, Inc., Flagstaff, Arizona, USA) in a transabdominal fashion spaced 5 cm circumferentially around the edge of the mesh. Spiral tacks (Protack®, United States Surgical Corporation, Norwalk, CT, USA) were then spaced 1 cm circumferentially around the edge of the mesh. The patient was discharged home on post-operative day five without complication.

On post-operative day 86, the patient returned to clinic with complaints of redness and a bulge in the area of the hernia repair. A CT of his abdomen was obtained that demonstrated a 22 X 8 cm fluid collection posterior to the mesh hernia repair (Figure 1).

Without imaging guidance, the seroma was percutaneously aspirated using sterile technique producing 240 ml of straw colored fluid. This fluid was cultured and was sterile. Subsequently, the patient returned 20 days later with palpable reaccumulation of fluid. Additionally, the patient had developed purulent drainage in the left lateral portion of his chevron incision. The area of purulence was incised, drained and sent for culture. The seroma was again percutaneously drained, this time under ultrasound guidance, and the fluid was sent for culture. Due to the posterior location of the seroma, the mesh had to be traversed during each drainage procedure. The cultures returned positive for methicillin resistant staphylococcus aureus (MRSA). The patient was started on oral linezolid. After 5 days of antibiotic therapy, the patient again required aspiration of his seroma, which again cultured MRSA.

The patient was informed that he would need operative drainage and debridement of the seroma as well as removal of his mesh. When the mesh was incised intraoperatively, a large brownish colored fluid collection consistent with an infected seroma was drained (Figure 2A). A gram stain of the fluid confirmed gram positive cocci. The PTFE mesh was removed and the seroma cavity was thoroughly irrigated. The posterior wall of the seroma cavity consisted of thick granulation tissue (Figure 2B). Two pieces of 12 X 8 cm AlloDerm® collagen mesh (LifeCell Corp., Branchburg, New Jersey, USA), were used to repair the remaining ventral hernia. A drain was left in the seroma cavity which was removed two weeks after the operation. The patient had no further complications.

A different 60 year old male hepatic transplant patient had a similar clinical course with formation of a deep

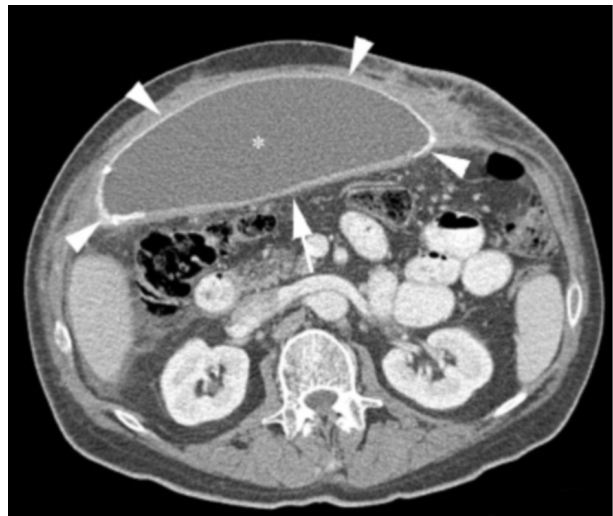


Figure 1. Axial enhanced CT through the mid abdomen demonstrating a low density seroma (\*) deep to mesh (arrowheads). Note that the posterior wall of the seroma consists of enhancing granulation tissue (arrow) that is lower density than the mesh overall but has a subjectively similar density in some regions, particularly near the midline.

seroma (Figure 3), percutaneous aspiration of sterile fluid, development of infection and operative removal of mesh. The physicians who aspirated the seromas were different in each case.

This retrospective review was performed with IRB approval.

### Discussion

Incisional hernias are one of the most frequently encountered problems following open abdominal surgery, with a reported incidence of 11 to 20% following laparotomy [1-2]. Currently, there appears to be an evolution in the operative management of this common clinical dilemma. Laparoscopic repair with prosthetic mesh is rapidly becoming the gold standard for treatment of incisional hernias, with large series reporting recurrence rates of 4.7% [3], compared to 16.5% for open repair after 9 years of follow-up [4]. Laparoscopic ventral hernia repair has also been shown to have fewer postoperative wound complications, overall complications and shorter length of stay than open ventral hernia repair [5]. Further, a growing body of literature has demonstrated the safety of this technique in young, elderly and obese patient populations, adding to the emerging popularity of this technique [6-8].

## Postoperative Seroma Deep to Mesh after Laparoscopic Ventral Hernia Repair: Computed Tomography Appearance and Implications for Treatment

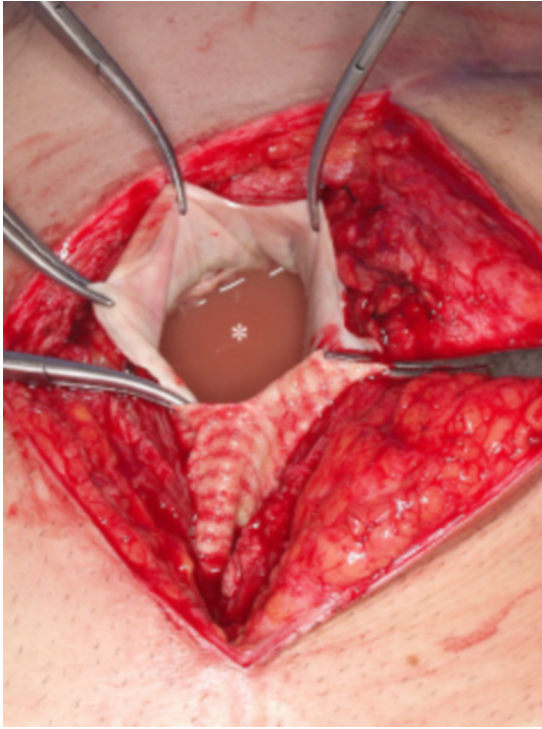


Figure 2A. Intraoperative photograph showing the incised PTFE mesh (held with clamps) and the infected seroma (\*) deep to the mesh.

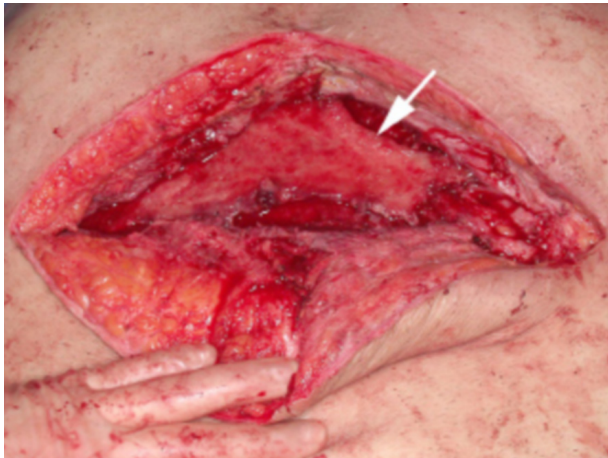

Figure 2B. Intraoperative photograph after mesh removal and drainage of the infected seroma reveals the posterior wall of the seroma consisting of thick granulation tissue (arrow).

The technique of laparoscopic ventral hernia repair leaves a potential space between the mesh and overlying skin that can easily fill with fluid. Studies have demonstrated seromas anterior to the mesh in up to 100% [4, 9-10]. Seroma formation deep to a mesh prosthesis after LVHR is very uncommon, reported by Heniford et al as occurring in 3/819 patients (0.36%) [4]. The vast majority of seromas resolve by 8 weeks postoperatively, with only 2.6% of patients experiencing a persistent seroma [4]. While the majority of seromas do not require any intervention, some require aspiration if they become painful or infected. Infected mesh often needs to be operatively removed, thus resulting in increased morbidity for the patient [11]. Successful nonoperative management of infected mesh has been reported [12].

To our knowledge, no previous radiologic description of a seroma forming deep to a ventral hernia mesh prosthesis has been illustrated in the literature. The imaging appearance on CT is relatively straightforward, being that of a fluid density collection located deep to prosthetic mesh. The only potentially confusing characteristic is that the relatively dense mesh (seen along the superficial border of the seroma in both cases) can, in some areas, appear to

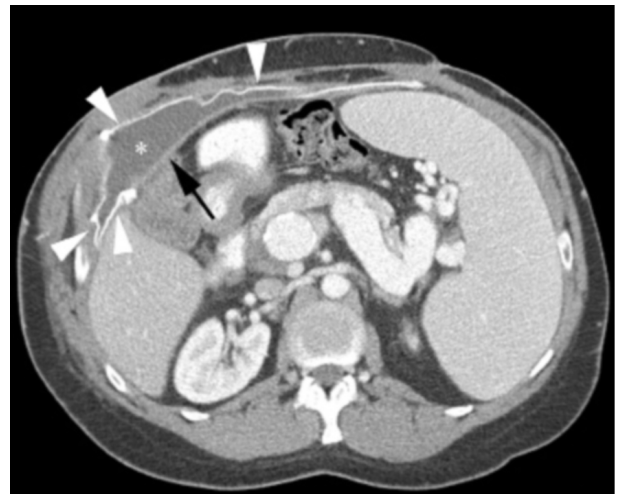

Figure 3. Companion case. Enhanced axial CT through the upper abdomen in a different patient with a seroma (\*) deep to hernia repair mesh (arrowheads) and an enhancing wall of granulation tissue (arrow) between the seroma and abdominal cavity. Additional findings of splenomegaly with prominent varices and portosystemic shunts in the splenic hilum and peripancreatic region are sequelae of portal venous hypertension prior to hepatic transplantation.

## Postoperative Seroma Deep to Mesh after Laparoscopic Ventral Hernia Repair: Computed Tomography Appearance and Implications for Treatment

be of similar density to the avidly enhancing granulation tissue (seen along the deep border of the seroma in both cases). To those unfamiliar with deep seromas or with the operative procedure of using a single layer of mesh, the seroma could appear to lie between two layers of mesh, especially since the mesh can undercut the periphery of deep seromas.

Percutaneous drainage of superficial seromas is a common procedure at our institution. The development of two infections from drainage of deep seromas subjectively reflects a disproportionately high complication rate compared with drainage of seromas anterior to mesh. While these infections may be due to random technical factors, we share our experience to raise the questions of whether these uncommon seromas could indicate an adjacent developing deep infection or whether they may have some other feature that predisposes these deep seromas to a higher risk of infection from percutaneous intervention.

### Conclusion

Although most patients will develop an uncomplicated seroma anterior to mesh after laparoscopic ventral hernia repair, the formation of seroma posterior to mesh is relatively uncommon. From experience at our institution, we suggest that patients with the deep subtype of mesh-associated seromas may warrant closer clinical follow up, as the consequences of mesh infection carry higher morbidity rates for the patient.

### References

1. Mudge M, Hughes LE. Incisional hernia: a 10 year prospective study of incidence and attitudes. *Br J Surg*. 1985 Jan;72(1):70-1. [PubMed]
2. van 't Riet M, Steyerberg EW, Nellensteyn J, Bonjer HJ, Jeekel J. Meta-analysis of techniques for closure of midline abdominal incisions. *Br J Surg*. 2002 Nov;89(11):1350-6. [PubMed]
3. Cobb WS, Kercher KW, Matthews BD, Burns JM, Tinkham NH, Sing RF, Heniford BT. Laparoscopic ventral hernia repair: a single center experience. *Hernia*. 2006 Jun;10(3):236-42. [PubMed]
4. Heniford BT, Park A, Ramshaw BJ, Voeller G. Laparoscopic repair of ventral hernias: nine years' experience with 850 consecutive hernias. *Ann Surg*. 2003 Sep;238(3):391-9. [PubMed]
5. Pierce RA, Spittler JA, Frisella MM, Matthews BD, Brunt LM. Pooled data analysis of laparoscopic vs. open ventral hernia repair: 14 years of patient data accrual. *Surg Endosc*. 2007 Mar;21(3):378-86. [PubMed]
6. Tessier DJ, Swain JM, Harold KL. Safety of laparoscopic ventral hernia repair in older adults. *Hernia*. 2006 Mar;10(1):53-7. [PubMed]
7. Eid GM, Prince JM, Mattar SG, Hamad G, Ikramuddin S, Schauer PR. Medium-term follow-up confirms the safety and durability of laparoscopic ventral hernia repair with PTFE. *Surgery*. 2003 Oct;134(4):599-603; discussion 603-4. [PubMed]
8. Novitsky YW, Cobb WS, Kercher KW, Matthews BD, Sing RF, Heniford BT. Laparoscopic ventral hernia repair in obese patients: a new standard of care. *Arch Surg*. 2006 Jan;141(1):57-61. [PubMed]
9. LeBlanc KA. The critical technical aspects of laparoscopic repair of ventral and incisional hernias. *Am Surg*. 2001 Aug;67(8):809-12. [PubMed]
10. Susmallian S, Gewurtz G, Ezri T, Charuzi I. Seroma after laparoscopic repair of hernia with PTFE patch: is it really a complication? *Hernia*. 2001 Sep;5(3):139-41. [PubMed]
11. Jones JW, Jurkovich GJ. Polypropylene mesh closure of infected abdominal wounds. *Am Surg*. 1989;55:73-6. [PubMed]
12. Paton BL, Novitsky YW, Zerey M, Sing RF, Kercher KW, Heniford BT. Management of infections of polytetrafluoroethylene-based mesh. *Surg Infect*. 2007 Jun;8(3):337-41. [PubMed]