


Case Report

Open pelvic fracture with bilateral common iliac arteriovenous injury successfully treated with hemicorporectomy following damage control interventional radiology in a hybrid emergency room

Takeshi Omura,^{1,2}  Yasuyuki Omichi,³ and Hirofumi Kosaka³

¹Emergency Surgery and Trauma Center, ²Department of Surgery, and ³Department of Orthopedic Surgery, Tokushima Prefectural Central Hospital, Tokushima, Japan

Background: In severe pelvic fracture, keys of successful treatment are early hemostasis and timely definitive care. We present a case in which the patient was treated by fast and reliable hemostasis and subsequent comprehensive hemicorporectomy.

Case Presentation: We describe the case of a 47-year-old man with severe pelvic trauma. He received early intervention by the helicopter emergency medical service, which included rapid transarterial embolization as damage control interventional radiology in the hybrid emergency room, and hemicorporectomy as a multidisciplinary approach. This series of treatments saved his life and he was discharged home.

Conclusion: Hemicorporectomy could be the only treatment option in patients with severe pelvic injury when there are no reconstruction options. To the best of our knowledge, this is the first case of severe open pelvic fractures with blood vessel damage, successfully treated by initial hemostasis using the helicopter emergency medical service, hybrid emergency room system, and following hemicorporectomy as a definitive care.

Key words: Helicopter emergency medical service, hemorrhagic shock, hemostasis, transcatheter arterial embolization, trauma pan scan

INTRODUCTION

HEMICORPECTOMY OR TRANSLUMBAR amputation requires resection of the pelvis and lower extremities, transection of the aorta, inferior vena cava, spinal cord, and urinary tract and digestive tract changes. It is mainly used for malignancy and intractable osteomyelitis in patients with spinal cord injury.^{1,2} However, thus far, only three reports are present where hemicorporectomy was undertaken for trauma. The first case was reported by Baker *et al.*, who described a successful case with a follow-up of 9 months,³ the second was reported by Richardson *et al.*, who described a patient with late mortality at 44 days after

the initial trauma due to massive pulmonary bleeding secondary to *Aspergillus* infection,⁴ and the third was reported by Warr *et al.*, who described a successful case with a follow-up of 6 months.²

The hybrid emergency room (HER), which has improved the survival rates of patients, was developed in Japan. This novel trauma care system allows clinicians to undertake life-saving procedures for severely injured patients, including whole-body computed tomography (CT) examination, damage control surgery, and transcatheter arterial embolization (TAE) by interventional radiology (IVR) on the same table in the same IVR-CT room without transferring the patient. Reportedly, this approach shortens the time to hemostasis and is significantly associated with decreased mortality from factors such as exsanguination.⁵ Herein, we report the case of a patient with severe open pelvic fractures and blood vessel damage who was treated with fast and reliable hemostasis followed by comprehensive hemicorporectomy.

Corresponding: Takeshi Omura, MD, Tokushima Prefectural Central Hospital, 1-10-3, Kuramoto-cho, Tokushima 770-8539, Japan. E-mail: omu@tph.gr.jp

Received 1 Jan, 2020; accepted 5 Sep, 2020

Funding information

No funding information provided.

CASE REPORT

A HEALTHY 47-year-old man sustained a crush injury to his lower body from a wood processing machine in a furniture-manufacturing plant. A helicopter emergency medical service (HEMS), which is an air ambulance with a physician, popularly called as “Doctor Helicopter System” in Japan, was requested by the on-site rescue team. When the HEMS arrived (37 min after injury), the patient’s left hip and right thigh were still trapped under the machine (Fig. 1). He was confused and sweating severely but only a small amount of external hemorrhage was noted. Before he was released from compression, he received a drip infusion. Thirteen minutes after HEMS arrival (50 min after injury), the man was freed; however, wound rebleeding occurred and the patient quickly became pale and fainted. His carotid artery was barely palpable. The HEMS team carried out intubation and pelvic wrapping. The patient was in shock during HEMS transport with a systolic blood pressure of 77 mmHg and a heart rate of 140 b.p.m. Before he arrived at the HER, the trauma call and the massive transfusion protocol were activated and resuscitation equipment, including a thoracotomy set and resuscitative endovascular balloon occlusion of the aorta (REBOA), were prepared.

The patient was brought to the HER within 81 min of the initial trauma, with 1000 mL crystalloid infusion during transport. His airway and breathing were maintained. A large wound in his right lumbar region and massive bleeding from the perineum to the left thigh were observed (Fig. 2, left). We started transfusion therapy, accessed the external iliac artery line for REBOA, packed the wound, and blocked the exposed right external iliac artery with a Nelaton catheter tourniquet; however, it was difficult to control bleeding from multiple sources. Sixteen minutes after arrival, the patient was in cardiac arrest and cardiopulmonary resuscitation was started. He recovered after 2 min. The REBOA was inserted belatedly from the left external iliac artery and the patient’s cardiodynamics evened out slightly after balloon inflation (22 min after arrival).

Under REBOA control, angiography was carried out; it showed that the bilateral internal and external iliac arteries were damaged (Video S1). The patient was unstable and coagulopathic, and TAE with N-butyl-2-cyanoacrylate (NBCA), as damage control IVR (DCIR) was started within 54 min after the patient’s arrival to prioritize saving his life. Although TAE with NBCA (ratio of NBCA : lipiodol was 1:4) was carried out at the right internal iliac artery at first under REBOA control, extravasation was still seen. A radiologist carried out TAE at the right common iliac artery (ratio was 1:2) and the left internal iliac artery, which was

effective as the distal flow was blocked (Video S2). Contrast-enhanced CT was undertaken on the same table after TAE and showed no severe injury except to the pelvis and bilateral lower extremities (Fig. 2, right).

Hemodynamic instability continued even after TAE of both external iliac arteries. Venous bleeding from the pelvis and bilateral lower extremities was observed and considered the cause of the patient’s unstable status. Moreover, severe damage was observed on bilateral lower extremities. Therefore, bilateral hip transection and pelvic external fixation were carried out in the operating room, as the HER lacked instruments for orthopedic surgery. Intraoperatively, rectal avulsion, near-total penectomy, a urethral defect, and bilateral testicular avulsion were observed and treated by temporary closure of the rectum, penectomy, and orchiectomy. The operative time was 4 h and 47 min and blood loss was 2238 mL. Although the operation was unexpectedly long, the patient’s hemodynamics improved during the amputation (Fig. 3, time series of vital signs). Postoperatively, his Injury Severity Scale score was 51 and survival probability was 7.4%.

Daily washing and necrotic muscle and bone fragment debridement were carried out on postoperative days (PODs) 1, 2, 3, 4, and 6, but infection control was not achieved. The patient had sepsis from extensive necrosis of the pelvic bone and surrounding muscle, and he did not have enough healthy skin to close the wound (Fig. 4). This concern necessitated pelvic resection on POD 6. To cover the stump with healthy skin, the separation level was planned at L3/4. Using a “back-to-front” approach has been shown to reduce bleeding¹ and was adopted for this case. The operation was undertaken on day 11 from admission. Skin perfusion was evaluated using i.v. indocyanine green fluorescence. Using imaging, a transverse incision was made in the back while assessing the blood flow of the skin. The L3 lumbar pedicle was removed, and the dura was exposed, ligated, and cut at the L3/4 level (Fig. 5, upper left). The patient was moved to the supine position, and the large vessel was processed (Fig. 5, upper right). The aorta and inferior vena cava were cut after mobilizing them from the vertebral bodies while processing the branches. Next, the lumbar spine was cut using a chisel. Abdominal surgery was then carried out (Fig. 5, lower) which included a colostomy and reconstruction of the urinary tract (reconstructed simple ureterostomy). The abdomen was closed by combining the rectus abdominis and the psoas major. The operative time was 11 h and 42 min, with 3832 mL blood loss.

During the postoperative course, paralytic ileus was observed on POD 1 and recovered spontaneously. Wound dehiscence appeared on POD 16, but was relieved by daily

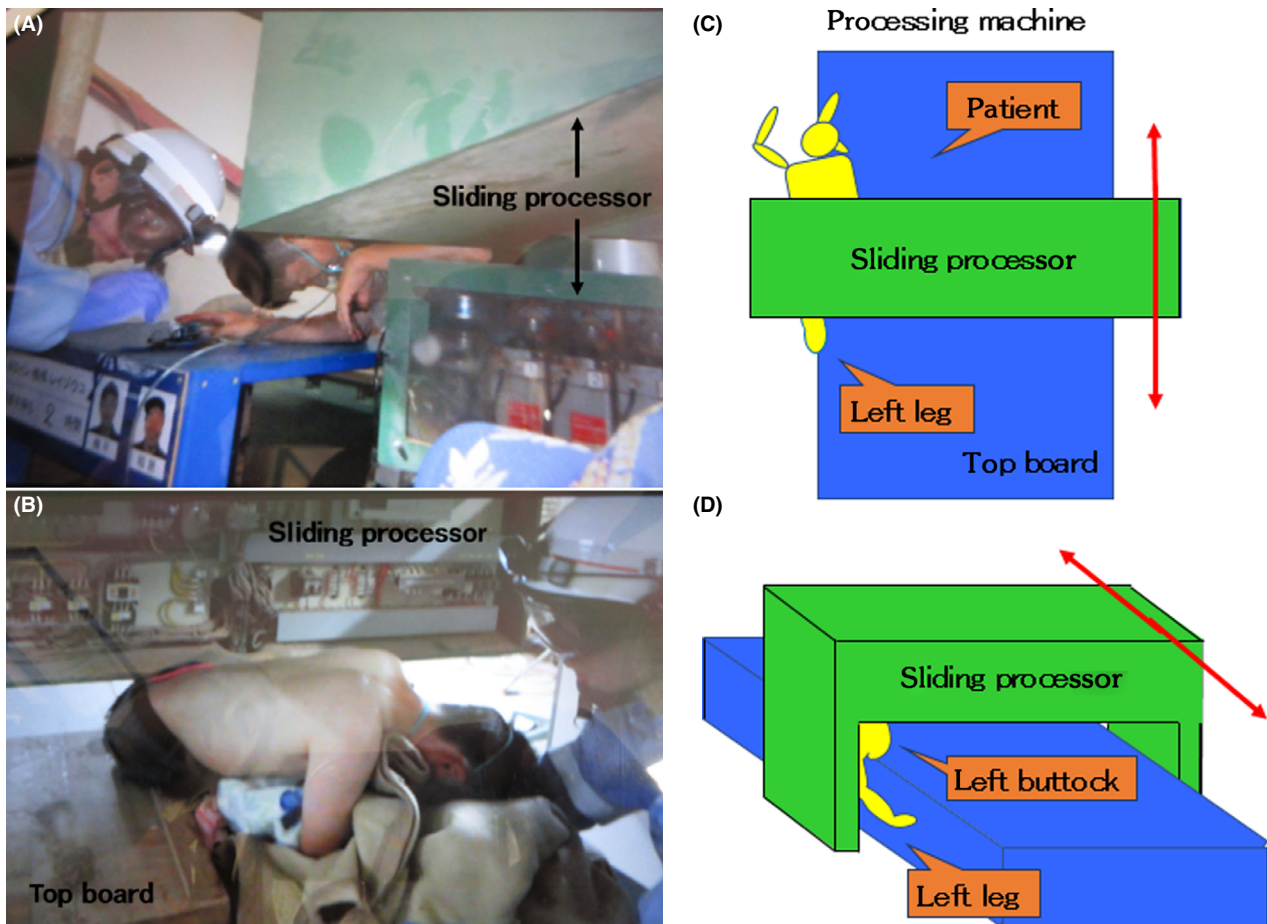


Fig. 1. Photographs and illustrations of the workplace accident in which a 47-year-old man suffered severe pelvic trauma. A, B, Photographs of the accident scene, showing the patient's left hip and right thigh trapped by the wood processing machine. C, Illustration showing a top view of the accident scene. D, Illustration showing the patient's left foot trapped by the machine. The processing machine can slide on the table.

washing. On POD 75, the patient was granted transfer to another hospital for rehabilitation and on POD 120, he was transferred. Videos S3 and S4 showed successful functional outcome before discharge. The patient returned home and was healthy at the 17-month follow-up.

DISCUSSION

THE MORTALITY RATE from open pelvic fracture has decreased recently and is currently approximately 18%. Mortality is most commonly due to uncontrolled acute hemorrhage and/or subacute sepsis secondary to contamination around fracture through an open wound.⁶ That is, these two issues must be addressed to save the patient. To address the first factor, prompt and reliable hemostasis was achieved by not only HEMS transportation, but also DCIR using NBCA

in HER (started within 1 h from admission) and subsequent hip amputation. Regarding the second factor, source control of life-threatening sepsis, hemicorporectomy was successfully undertaken at an appropriate timing by multidisciplinary approach, before it became irreversible. However, we have learned many lessons at each stage in this case. First, aortic cross-clamping could not be undertaken at the rescue site because the patient was trapped in a sitting position, where resuscitative thoracotomy was difficult to perform. Additionally, the HEMS did not have equipment for cross-clamping or REBOA. For future emergencies, HEMS has now been fully equipped with them. Second, inserting REBOA took approximately 22 min in HER. Although REBOA might be preferred to cross-clamping for patients with a pelvic fracture and severe hemorrhagic shock,⁷ earlier emergency thoracotomy might prevent the patient from

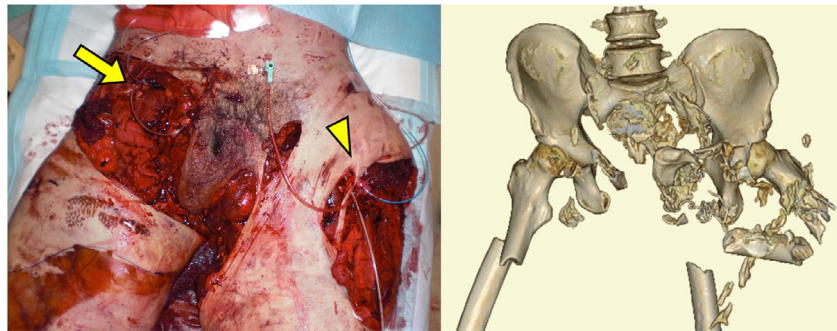


Fig. 2. Severe pelvic trauma in a 47-year-old man. Left panel, A deep tear is seen from the right lumbar region to the left thigh, through the groin and perineal area. Arrow, exposed right external iliac artery with a Nelaton catheter tourniquet; arrowhead, exposed left external iliac artery with an arterial access. Right panel, 3-D computed tomography image shows multiple pelvic fractures and bilateral femur fracture.

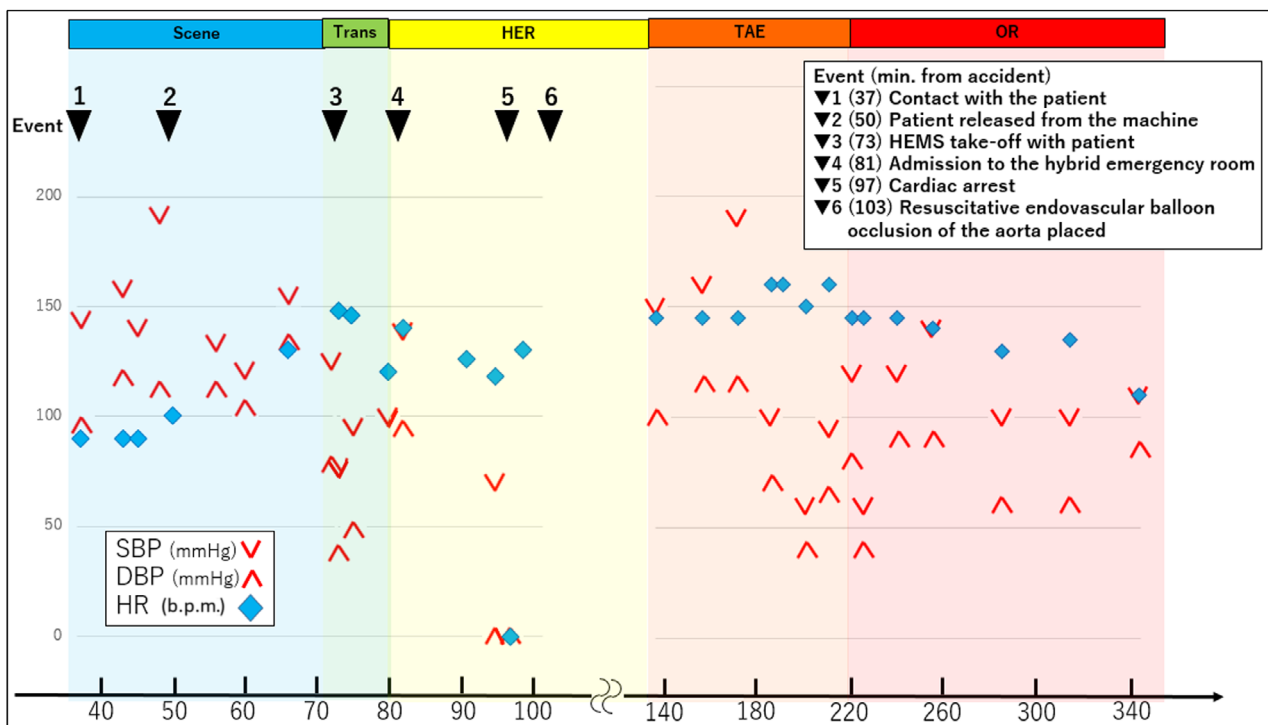


Fig. 3. Clinical course timeline from the accident causing severe pelvic trauma in a 47-year-old man. Numbered events with arrowheads are indicated with the legends in the white box. DBP, diastolic blood pressure; HEMS, helicopter emergency medical service; HER, hybrid emergency room; HR, heart rate; OR, operating room; SBP, systolic blood pressure; TAE, transcatheter arterial embolization; Trans, transportation.

cardiac arrest. On arrival at the hospital, we thought that it would be difficult to save both his feet due to the severe damage. In the treatment process, we decided to give up on salvaging them. This is a reason why NBCA was used as

permanent embolus during DCIR. This could be carried out more easily in the HER, instead of a surgical approach to the bilateral iliac artery. That is the third point we learned, that led to survival. Before undertaking hemicorporectomy, we

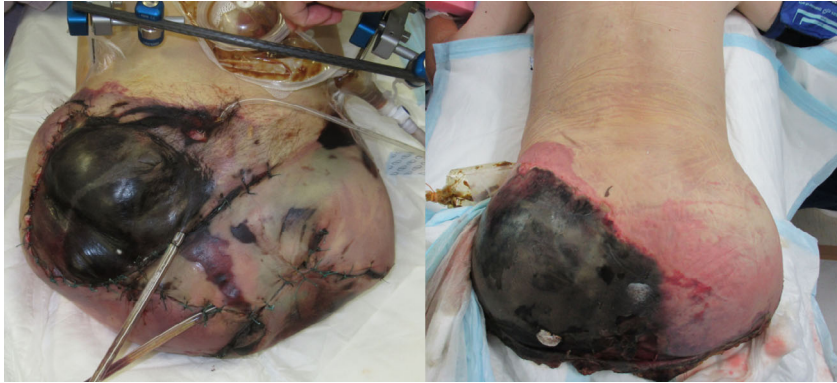

Fig. 4. Severe pelvic trauma in a 47-year-old man. Except for part of the right buttock, the pelvic bone and surrounding muscles were totally necrotic.

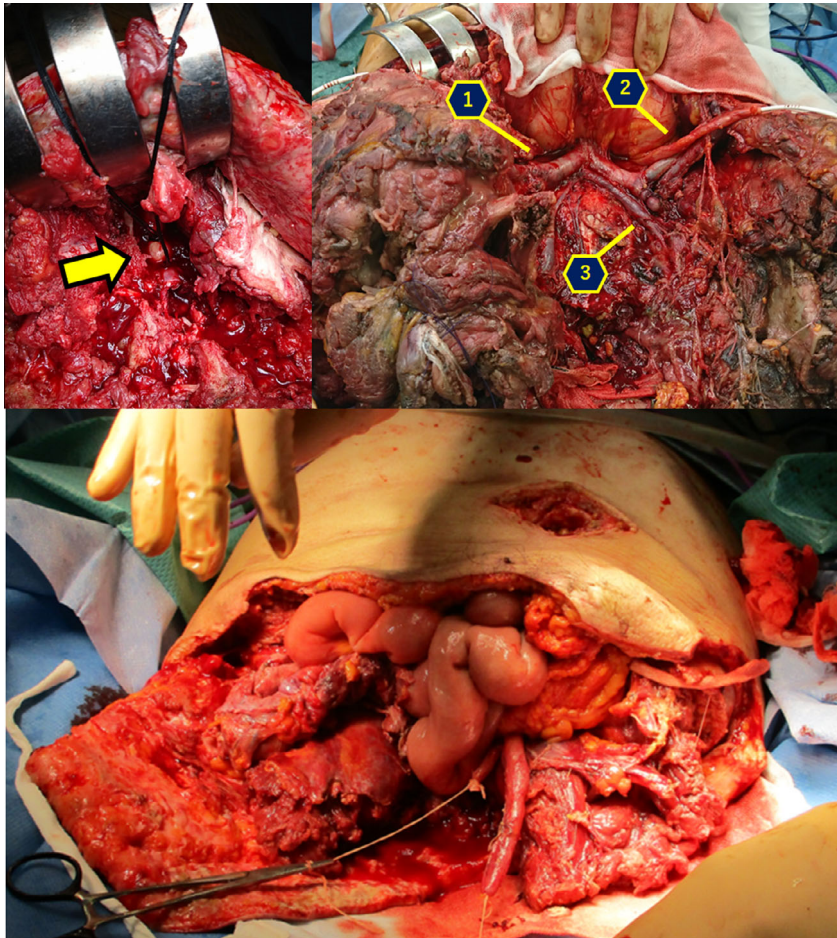


Fig. 5. Photographs of surgical intervention in a 47-year-old man with severe pelvic trauma. Top left panel, Intraoperative photograph taken with the patient in the prone position. The lumbar pedicle is removed and the dura is exposed, ligated, and then cut (arrow). Top right panel, Large vessels are exposed when the necrotic pelvic muscles are mobilized. 1, right common iliac artery; 2, left ureter; 3, left common iliac vein. Bottom panel, Photograph after pelvic resection.

discussed other therapeutic options at a preoperative meeting attended by all involved surgeons with multiple specialties. Despite repeated debridement of the extensive necrosis of the pelvic bone and surrounding muscles, the patient was septic and infection control could not be achieved for 1 week. Although there was an opinion to continue debridement, complete removal of necrotic tissue to recover from sepsis would not be possible. Fortunately our team had one orthopedic surgeon, who had experience with performing hemicorporectomy for a trauma patient. We finally concluded that there was no other option than hemicorporectomy.

Although other cases of hemicorporectomy for trauma have been reported, this is the first case describing post-traumatic TAE. Indications of this procedure are expanding for trauma; hence, the number of patients suffering from ischemic complications after TAE is estimated to increase. As presented herein, thorough preparation for surgery, in order to make the most of limited area of residual skin for covering the stump, would be required in some of those cases.

CONCLUSIONS

HEMICORPECTOMY MIGHT BE the only treatment option in patients with severe pelvic injury when there are no reconstruction options. In the present case, severe open pelvic fractures with blood vessel damage could be treated by undertaking fast and reliable hemostasis first, and then comprehensive hemicorporectomy.

ACKNOWLEDGMENTS

WE WOULD LIKE to thank Dr. Miharu Arase and Editage for language editing.

DISCLOSURES

Approval of the research protocol: N/A.

Informed consent: Informed consent for publication was obtained from the patient.

Registry and the registration no. of the study/trial: N/A.

Animal studies: N/A.

Conflict of interest: None.

REFERENCES

- 1 Barnett CC Jr, Ahmad J, Janis JE, Lemmon JA, Morrill KC, McClelland RN. Hemicorporectomy: back to front. *Am. J. Surg.* 2008; 196: 1000–2.
- 2 Warr SP, Jaramillo PM, Franco ST, Valderrama-Molina CO, Franco AC. Hemicorporectomy as a life-saving strategy for severe pelvic ring crush injury: a case report. *Eur. J. Orthop. Surg. Traumatol.* 2018; 28: 735–9.
- 3 Baker TC, Berkowitz T, Lord GB, Hankins HV. Hemicorporectomy. *Br. J. Surg.* 1970; 57: 471–6.
- 4 Richardson LE 2nd, Toon B, Rankin R. Initial survival following massive crush injury, leg avulsion, and hemicorporectomy. *Prehosp. Emerg. Care* 1999; 3: 364–6.
- 5 The founding members of the Japanese Association for Hybrid Emergency Room System (JA-HERS). The hybrid emergency room system: a novel trauma evaluation and care system created in Japan. *Acute. Med. Surg.* 2019;6: 247–251. <https://doi.org/10.1002/ams2.412>.
- 6 Grotz MRW, Allami MK, Harwod P, *et al.* Open pelvic fractures: epidemiology, current concepts of management and outcome. *Injury* 2005; 36: 1–13.
- 7 Biffi WL, Fox CJ, Moore EE. The role of REBOA in the control of exsanguinating torso hemorrhage. *J. Trauma. Acute Care Surg.* 2015; 78: 1054–8.

SUPPORTING INFORMATION

Additional Supporting Information may be found in the online version of this article at the publisher's web-site:

Video S1. Angiography showed blockage of the right external iliac artery and the torn internal iliac artery.

Video S2. Bilateral common iliac arterial flow could not be confirmed in angiography after transcatheter arterial embolization.

Video S3. The patient can move his wheelchair using his hands.

Video S4. The patient can lift his body using both hands.