

Post-operative Vesicoenterocutaneous Fistula with Multiple Intestinal Knotting: A Case Report

Abstract

Herein is a case of a 51-year-old farmer who presented to our facility with initial leakage of urine but later urine mixed with faeces from the lower abdomen after two previous abdominal surgeries. He had an open transvesical prostatectomy due to benign prostate enlargement complicated by leakage of urine from lower abdominal wall scar. A repeat surgical intervention to correct the urine leakage was followed by recurrence of urine leakage and later by leakage of feculent urine from the lower anterior abdominal wall. At our facility, he had exploratory laparotomy with manual unknotting of ileal loops, fistula tracts excision, resection, and end-to-end ileoileal anastomosis. The bladder wall was repaired with suprapubic cystostomy. Although the finding of asymptomatic multiple small bowel knotting was incidental in the index case, its timely management averted a sitting timed bomb that may lead to a diagnostic dilemma with catastrophic consequences.

Keywords: Intestinal knotting, post-operative, vesicoenterocutaneous fistula

Introduction

Fistula is defined as an abnormal communication between two epithelialized surfaces.^[1] Depending on the aetiology, it can involve virtually all organ systems in the body. It can be internal or external when abnormal communication involves two internal organs or an internal organ and exterior, respectively.^[1] While vesicoenteric fistula is an internal fistula, vesicocutaneous and enterocutaneous are external fistulae. The vesicocutaneous fistula is the abnormal communication between bladder mucosa and the skin. Vesicoenteric fistula is also a rare abnormal communication between the bladder and intestinal mucosa. In contrast, enterocutaneous fistula which is an abnormal communication between the intestinal tract and the skin is a fairly common complication of abdominal surgery. Fistulae are described as complex when they have multiple tracts or when associated with abscess collection among other things.

Fistulae have been found to occur in a wide variety of circumstances, namely, but not limited to: post-operative,^[2-4] post-radiation therapy,^[5,6] and in a background of malignant neoplasm.^[7,8] Over 80–90% of enterocutaneous fistulae arise as a consequence of iatrogenic complications of abdominal surgical

interventions.^[9] Spontaneous manifestation of fistulae may be an ominous sign of an underlying malignant neoplastic origin.^[9] The clinical presentations of fistulas may be straightforward or at times bizarre, especially when complex or complicated resulting in diagnostic and therapeutic difficulty. The treatment can be non-operative or operative.^[8] The treatment principles involve establishing the diagnosis and giving attention to fluid and electrolyte correction, control of sepsis, nutritional rehabilitation, as well as treatment of underlying aetiology.^[1] Irrespective of the type and nature of the fistula, associated conditions such as local abscess formation, presence of the foreign body, underlying malignancy, radiation exposure, presence of intestinal or urinary obstruction, epithelialization of the fistula tract, short fistula tract of <2 cm may make the management of fistulas quite challenging.^[1,9]

In contrast, intestinal knotting refers to the twisting of the bowel segment about itself.^[10] It has been reported to present commonly with clinical features of bowel obstruction. Asymptomatic presentation is an uncommon character and could be an incidental finding in patients who had undergone previous abdominal surgery. A clinical scenario whereby complex fistula coexists with multiple asymptomatic intestinal knotting is

**Abdullahi Khalid,
Ahmed Mohammed
Umar, Abdullah
Abdulwahab-Ahmed,
Abubakar Sadiq
Muhammad,
Ngwobia Peter
Agwu,
Ismaila A. Mungadi**

*Tetfund Centre of Excellence
in Urology and Nephrology,
Institute of Urology and
Nephrology, Usmanu Danfodiyo
University and Usmanu
Danfodiyo University Teaching
Hospital, Sokoto, Nigeria*

Received: 29-Mar-2022

Accepted: 12-Apr-2022

Published: 22-Jun-2022

Address for correspondence:

*Dr. Abdullahi Khalid,
Tetfund Centre of Excellence
in Urology and Nephrology,
Institute of Urology and
Nephrology, Usmanu Danfodiyo
University and Usmanu
Danfodiyo University Teaching
Hospital, Sokoto, Nigeria.
E-mail: kalabduka@gmail.com*

Access this article online

Website:

www.jwacs-jcoac.org

DOI: 10.4103/jwas.jwas_78_22

Quick Response Code:



How to cite this article: Khalid A, Umar AM, Abdulwahab-Ahmed A, Muhammad AS, Agwu NP, Mungadi IA. Post-operative vesicoenterocutaneous fistula with multiple intestinal knotting: A case report. *J West Afr Coll Surg* 2021;11:33-7.

This is an open access journal, and articles are distributed under the terms of the Creative Commons Attribution-NonCommercial-ShareAlike 4.0 License, which allows others to remix, tweak, and build upon the work non-commercially, as long as appropriate credit is given and the new creations are licensed under the identical terms.

For reprints contact: reprints@medknow.com

rarely encountered and documented in the literature. Multiple asymptomatic intestinal knotting coexisting with post-operative intestinal and urinary fistulae to the best of our knowledge has not been reported at the time of our literature search. Therefore, our objective is to report and share our experience in the management of this rare clinical entity, which is capable of posing catastrophic consequences to the patient's survival.

Case Presentation

A 51-year-old male farmer was referred from a secondary healthcare facility to our hospital 7 weeks following open transvesical prostatectomy with a 3-week history of leakage of urine from the lower anterior abdominal wall. He had repeat surgical intervention on the 4th week post-prostatectomy to correct the urine leakage but only to develop recurrent leakage of feculent urine later from the suprapubic cystostomy (SPC) catheter as well as from the suprapubic wound scar. There was a high-grade fever associated with chills, rigor, and vomiting but no constipation or abdominal swelling. There was history of failed attempt to pass the urethral catheter at the prostatectomy. There was no remarkable medical history of note.

Physical examination revealed acutely ill-looking and anxious patient, with offensive odour, febrile (temperature 38.2°C), dehydrated but not pale. The respiratory rate was 20 cycles per minute but tachycardic (pulse rate 96 beats per min) with a blood pressure of 110/80 mmHg. There were multiple cutaneous fistulous openings over the suprapubic region adjacent to a transverse prostatectomy scar and a superiorly placed wider cutaneous fistulous opening with epithelialized tract discharging feculent materials and tender surroundings. The suprapubic catheter was *in situ*, unkempt, blocked, and arising at the margin of the wider cutaneous fistulous opening.

The laboratory investigations showed a leucocytosis of $27.9 \times 10^3/\mu\text{L}$, haemoglobin 11 g/dL, and platelet count of $319 \times 10^3/\mu\text{L}$. The serum electrolytes, urea, and creatinine were within the normal range. The prostate-specific antigen was 9.5 ng/mL. Urine culture showed *Pseudomonas aeruginosa*. The patient did not have the histology report of the prostatectomy specimen

from the referring hospital, so he had a prostate biopsy at our facility. The histology was reported as nodular hyperplasia. There were no remarkable abdominal ultrasound scan findings. The combined retrograde urethrogram (RUG) and voiding cystourethrogram demonstrated complete bulbomembranous urethral stricture. There was an opacified tortuous tubular structure seen posterosuperior to the urinary bladder and centrally located with valvulae conniventes suggestive of small bowel loops, raising suspicion of vesicoenteric fistula.

He was initially resuscitated with intravenous normal saline, broad-spectrum antibiotics, and bladder irrigation using 100 mL of 10% povidone-iodine per litre of normal saline. After resuscitation and treatment of sepsis, he had exploratory laparotomy on the 4th week after presentation in our facility. There were findings of multiple suprapubic cutaneous fistulous openings communicating with bladder (vesicocutaneous fistula) and the wider cutaneous opening with a short epithelialized tract of 1.5 cm in length connected to the ileal bowel segment (enterocutaneous fistula), as shown in Figure 1A. The vesicoenteric fistulous tract was noted connecting the ileum and bladder dome [Figure 1B and C]. The ileal bowel segment was also adhered to the inner abdominal wall [Figure 2A]. The ileal loop attachment points were resected, and end-to-end ileal anastomosis was effected [Figure 2B and C]. There was an incidental finding of viable multiple ileal bowel loop knots as shown in Figure 3A–C.

The multiple ileal bowel loop knots were manually unknotted. The bladder wall was repaired and an SPC left. He did well post-operatively and was discharged home on SPC 14 days after the laparotomy as well as follow-up at the clinic. He was counselled for a urethroplasty subsequently.

Discussion

The term vesicoenterocutaneous fistula in this report describes a case of a patient with a constellation of multiple fistulous connections involving the bladder and skin and bowel. All these were found in the index case. Despite the constellation of these fistulous connections, there was no associated abscess

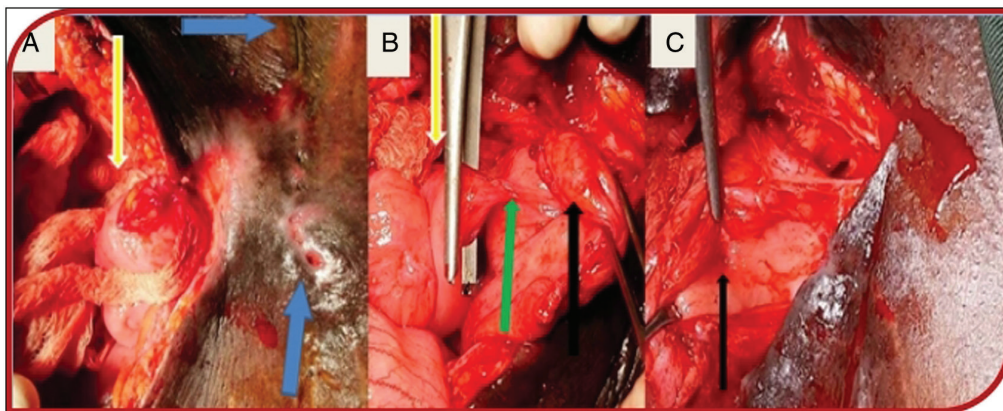


Figure 1: (A) Vesicocutaneous and enterocutaneous fistulae (blue arrows: previous surgery transverse suprapubic scar and multiple cutaneous openings of vesicocutaneous fistulae; yellow arrow: ileal segment and epithelialized enterocutaneous fistula tract). (B) Vesicoenteric fistula (yellow arrow: ileal segment; green arrow: vesicoenteric fistulous tract; black arrow: bladder). (C) Vesicoenteric fistula opening into bladder cavity (black arrow)

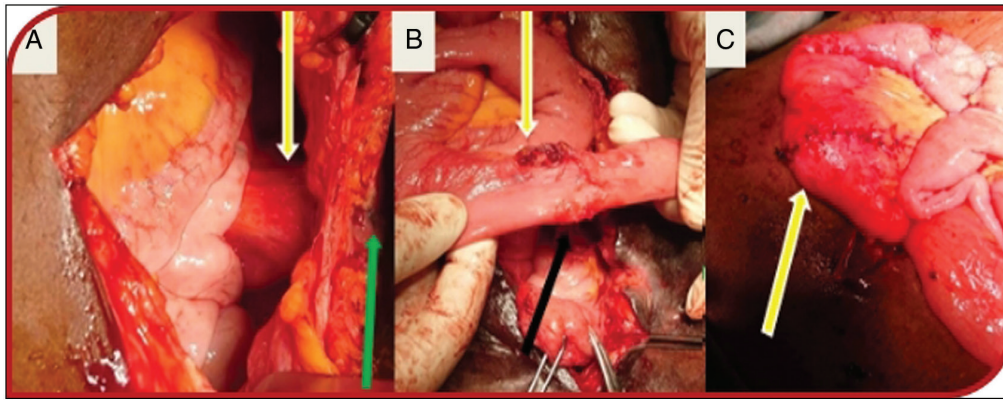


Figure 2: (A) Enterocutaneous fistula (yellow arrows: adherent ileal segment to the inner abdominal wall and green arrow: cutaneous opening). (B) Cutaneous and bladder ileal attachment sites (yellow and black arrows, respectively). (C) Resected ileal segment with end-to-end anastomosis (yellow arrow)

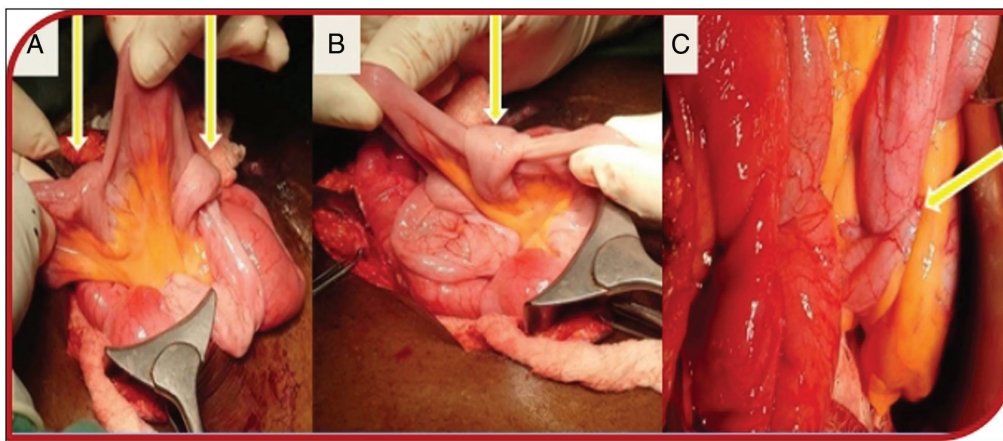


Figure 3: (A–C) Multiple intestinal knots showing viable bowel (yellow arrows)

or features to suggest peritonitis. This type of the fistula is best described as a complex fistula. They are difficult to treat, and non-operative management is oftentimes not suitable in this scenario. For this reason, operative management is considered early after control of sepsis and proper resuscitation. Hence, a satisfactory outcome was observed in the patient. Notwithstanding, a study has reported successful conservative management of complex vesicocutaneous fistula.^[11]

Patients with fistula suffer a myriad of complications which broadly include infective and non-infective complications such as fluid and electrolyte derangement and even psychological challenges. At the presentation, the index patient was found to be in a state of despair probably from the leakage of faeces and urine from the anterior abdominal wall and the thought of futile attempt at repair from the referring healthcare facility. External fistulas as seen in our index patient can be psychosocially traumatizing, particularly when the effluent is urine or faeces due to the associated offending odour and stigmatization of the patient. Other complications seen in this patient include dehydration and sepsis as evidenced at the presentation of this patient with fever, tachycardia, leucocytosis, and positive urine culture. Dehydration and sepsis can be significant causes of morbidity and mortality in patients with abdominal fistula. The mortality from sepsis and attending malnutrition has been

reported to be as high as 6–33%.^[12] Urosepsis was evident in the patient at presentation from the faecal contamination of the bladder. The ascending infection from the bladder can lead to acute kidney injury. Hence, adherence to the principle of management of fistula is key in resolving these complications. The patient had antibiotic therapy, rehydration, bladder irrigation with an antiseptic solution, and liberal enteral nutrition to address these problems.

The frequency of developing lower urinary tract symptoms due to benign prostate enlargement increases with age and peaked at the age group 60–69 in our environment.^[13] The index case was 51 years. The histology was not available for the prostatectomy specimen. The urethral stricture as opposed to benign prostate enlargement may be the main factor responsible for his lower urinary tract symptoms for which he presented to the referral secondary health facility where he had probably unindicated surgery for his complaint. Benign prostate enlargement coexistence with urethral stricture is a well-known pathology. In addition, the facilities for proper evaluation of this patient's disease may not be available at the referring health facility. A thorough clinical evaluation of the patient in addition to a high index of suspicion is needed to avoid missing the diagnosis of this combined pathology. Treatment of stricture coexisting with benign prostate enlargement depends on some stricture

characteristics. This includes stricture location, length, nature (partial or complete), and degree of spongiofibrosis, among other considerations. This is important as it helps proper treatment planning and can avert complications seen in the index case.

The majority of enterocutaneous fistulas which the index case had among other things results commonly from iatrogenic complications of abdominal surgical interventions.^[9] The aetiology of fistula here is post-operative which buttresses further what has already been documented in the literature. It is not unlikely that the vesicoenteric and enterocutaneous fistulae were iatrogenic in origin. It is noteworthy that causes of vesicocutaneous fistula are numerous and reported causes range from post-traumatic, bladder calculus, radiotherapy, post-operative, and bladder malignancy.^[2-6,14-16] Other possible aetiologies of vesicoenteric or enterovesical fistula are benign conditions such as Meckel's diverticulum and Crohn's disease.^[17,18]

The treatment of fistula can be non-operative or operative.^[8] In uncomplicated fistulas or simple fistula, non-operative management is often advocated when indicated because of the associated chance of spontaneous resolution.^[1] Operative treatment is advocated in complex or complicated fistula after initial resuscitation as the case here. The other reasons why this option of treatment was appropriate here include findings of short epithelialized enterocutaneous fistulous tract of 1.5 cm and urinary tract obstruction from the urethral stricture for which he had urinary diversion with SPC. Other associated conditions such as local abscess formation, presence of a foreign body, underlying malignancy, and radiation exposure which can negatively hamper patient outcome were absent in this patient.

The multiple intestinal knotting was an incidental intraoperative finding in this patient. The aetiology of multiple intestinal knotting in the index patient may be related to earlier surgical interventions he had, as evidenced intraoperatively by the adhesive ileal loop to the inner surface of anterior abdominal wall as shown in Figure 2A. This can serve as a torque that may have resulted in the multiple bowel knotting. It is reported to present commonly with clinical features of bowel obstruction. However, it is pertinent to note that its asymptomatic presentation is rare but found in the index patient. This patient's situation might have been more clouded if the bowel knots were symptomatic. This can also narrow his chances of survival. The plausible explanations for the asymptomatic presentation may include the recent development of the bowel knots about the time of surgical decision and intervention and mild degrees of knotting among other things.

Conclusion

The constellation of post-operative vesicocutaneous, vesicoenteric, and enterocutaneous fistula is rare but possible as is reported here. It is even rarer to encounter these types of fistulae to be associated with intestinal knotting. The operative

management of vesicoenterocutaneous fistula is rewarding and associated with good outcomes where strict attention is paid to the principles of management of fistula. Proper clinical evaluation and avoidance of unnecessary surgical intervention is important in preventing such surgical catastrophes in a patient.

Acknowledgement

We sincerely thank the Urology Ward Nurses and other hospital healthcare staff for their committed care and support enjoyed by the patient while on admission.

Financial support and sponsorship

Nil.

Conflicts of interest

There are no conflicts of interest.

Authors' contribution

We all provided care for the patient or reviewed the case. AK and AMU produced the initial draft of this manuscript. AAA, MAS, and ANP did additional literature search, revised, and added their inputs to the initial draft. MIA revised the final draft with additional inputs. All authors approved the final version. Written consent for publication was obtained from the patient and the hospital Research and Ethics Committee.

References

- Whang EE, Ashley SW, Zinner MJ. Small intestine. In: Brunicaardi FC, Andersen DK, Billiar TR, Dunn DL, HunterJG, Pollock RE, editors. *Schwartz's Manual of Surgery*. 8th ed. New York, USA: McGraw-Hill; 2006. p. 702-31.
- Singh S, Kumar M, Patodia M, Sankhwar SN, Bansal A. Vesicocutaneous fistula originating from bladder diverticulum as an unusual delayed complication after open prostatectomy. *Int J Med Res* 2015;1:40-2.
- Lee TH, Oh JY, Jung JY, Kim MH, Oh YL, Lee CJ, *et al.* Vesicocutaneous fistula: An unusual complication of total hysterectomy. *J Women Med* 2009;2:92-4.
- Tatar B, Erdemoğlu E, Soyupek S, Yalçın Y, Erdemoğlu E. Vesicocutaneous fistula after cesarean section—A curious complication: Case report and review. *Turk J Obstet Gynecol* 2016;13:46-9.
- Lau KO, Cheng C. A Case report—Delayed vesicocutaneous fistula after radiation therapy for advanced vulvar cancer. *Ann Acad Med* 1998;27:705-6.
- Hong JH. Very late onset of radiation-induced complicated vesicocutaneous fistula. *Korean J Urol Oncol* 2015;13:101-4.
- Demirtas A, Ersekerci E, Sahin N, Caniklioglu M, Akcan, A. Vesicointestinal, vesicocutaneous fistula and tubal invasion secondary to bladder adenocarcinoma: A case report. *Erciyes Med J* 2008;30:044-7.
- Shaydakov ME, Pastorino A, Tuma F. Enterovesical fistula. [Updated September 12, 2020]. In: StatPearls [Internet]. Treasure Island, FL: StatPearls Publishing; 2020. Available from: <https://www.ncbi.nlm.nih.gov/books/NBK532936/>.
- Merrill T, Dayton MD. Surgical complication. In: Townsend CM, Beauchamp RD, Evers BM, Mattox KL, editors. *Sabiston Textbook of Surgery*. 17th ed. New York, USA: Elsevier Saunders; 2004. p. 297-332.

10. Beg MY, Bains L, Lal P, Maranna H, Kumar N P. Small bowel knots. *Ann R Coll Surg Engl* 2020;102:571-6.
11. Assaker R, El Hasbani G, Amoateng D, Vargas J, Nepal P, Armm M. Complex vesicocutaneous fistula: Successful conservative management. *Urol Case Rep* 2021;38:101741.
12. Lloyd DA, Gabe SM, Windsor AC. Nutrition and management of enterocutaneous fistula. *Br J Surg* 2006;93:1045-55.
13. Nwafor CC, Keshinro OS, Abudu EK. A histopathological study of prostate lesions in Lagos, Nigeria: A private practice experience. *Niger Med J* 2015;56:338-43.
14. Francisca KK, Palinrungi MA, Syahrir S, Syarif FM. Bladder stones associated with vesicovaginal fistula: A case report. *Int J Surg Case Rep* 2020;75:122-5.
15. Yddoussalah O, Sumba H. [Post traumatic vesicocutaneous fistula]. *Pan Afr Med J* 2017;28:147.
16. Kang YJ, Park DJ, Kim S, Kim SW, Lee KS, Choi NG, *et al.* Vesicoenteric fistula due to bladder squamous cell carcinoma. *Korean J Urol* 2014;55:496-8.
17. Bouassida M, Mighri MM, Trigui K, Chtourou MF, Sassi S, Feidi B, *et al.* Meckel's diverticulum: An exceptional cause of vesicoenteric fistula: Case report and literature review. *Pan Afr Med J* 2013;15:9.
18. Cullis P, Mullassery D, Baillie C, Corbett H. Crohn's disease presenting as enterovesical fistula. *BMJ Case Rep* 2013;2013:bcr2013201899. doi: 10.1136/bcr-2013-201899. <https://pubmed.ncbi.nlm.nih.gov/24248323/>.