

# Lymphatic Dissemination and Axillary Web Syndrome in Primary Cutaneous Tuberculosis Secondary to Needlestick Injury

Alexandre E. Malek,<sup>1,2</sup> Caroline E. Fife,<sup>3,4</sup> John C. Rasmussen,<sup>5</sup> Ron J. Karni,<sup>6</sup> John R. Morrow,<sup>5</sup> Audrey Wanger,<sup>7</sup> Eva M. Sevick-Muraca,<sup>5</sup> and Luis Ostrosky-Zeichner<sup>1,2</sup>

<sup>1</sup>Department of Internal Medicine, Division of Infectious Diseases, McGovern Medical School, University of Texas Health Science Center at Houston, Houston, Texas, USA, <sup>2</sup>Department of Infectious Diseases, Infection Control and Employee Health, University of Texas MD Anderson Cancer Center, Houston, Texas, USA, <sup>3</sup>Department of Geriatrics, Baylor College of Medicine, Houston, Texas, USA, <sup>4</sup>CHI St Luke's Hospital, The Woodlands, Texas, USA, <sup>5</sup>Center for Molecular Imaging, Brown Foundation Institute for Molecular Medicine, McGovern Medical School, University of Texas Health Science Center at Houston, Houston, Texas, USA, <sup>6</sup>Department of Otorhinolaryngology, McGovern Medical School, University of Texas Health Science Center at Houston, Houston, Texas, USA, and <sup>7</sup>Department of Microbiology and Molecular Genetics, McGovern School of Medicine, University of Texas Health Science Center at Houston, Houston, Texas, USA

Cutaneous tuberculosis secondary to skin inoculation of *Mycobacterium tuberculosis* is uncommon but it can occur in the health care settings. Herein, we report an unusual case of primary cutaneous tuberculosis of the thumb following a needlestick injury. The infection progressed with a necrotic granuloma, lymphatic dysfunction as visualized by near-infrared fluorescence lymphatic imaging, and the development of an axillary web syndrome.

**Keywords.** axillary web syndrome; dermal backflow; lymphatic dissemination; cutaneous tuberculosis; needlestick injury; near-infrared fluorescence imaging.

Tuberculosis (TB) is a mycobacterial infection that arises secondary to infection by *Mycobacterium tuberculosis* (*Mtb*). Pulmonary TB remains a major cause of morbidity and mortality worldwide. An estimated 10.0 million people were diagnosed with pulmonary TB in 2019, and 1.2 million TB-related deaths were reported among human immunodeficiency virus (HIV)-negative patients (208 000 additional deaths were reported in people living with HIV) [1]. Approximately 20% of all TB cases present as extrapulmonary infections. Diagnosis of extrapulmonary TB infections often are delayed, and such

infections often have higher recurrence rates than pulmonary TB. In extrapulmonary TB, granulomatous lesions are most commonly found in lymph nodes (LNs) [2].

Cutaneous TB is an uncommon clinical manifestation, comprising 1%–2% of all extrapulmonary TB cases, and was first documented in 1826 when Laennec reported his own “prosector’s wart” [3]. The clinical findings vary and may include inflammatory papules, verrucous plaques, suppurative nodules, or chronic ulcers. TB dissemination through hematogenous spread is often invoked as the cause of multiorgan infection while lymphatic dissemination may explain lymphatic system involvement [4]. At the present time, direct evidence for dissemination through lymphatic vessels is lacking. Recent animal studies suggest that the lymphatic system is involved in both disseminating as well as harboring latent TB. Lymphatic endothelial cells (LECs) that line lymphatic vessels and LNs provide a preferential niche for *Mtb* [5]. The intracellular uptake of *Mtb* is dependent upon mannose receptors that are mainly expressed on the surface of LECs and once inside LECs, the mycobacteria can escape phagocytosis [6]. Herein, we report a rare presentation of primary cutaneous TB of the thumb following a needlestick injury, complicated by axillary lymphadenitis, lymphatic dysfunction, and axillary web syndrome (AWS). This case report further evidences the role of the lymphatics in dissemination of the disease.

## CASE REPORT

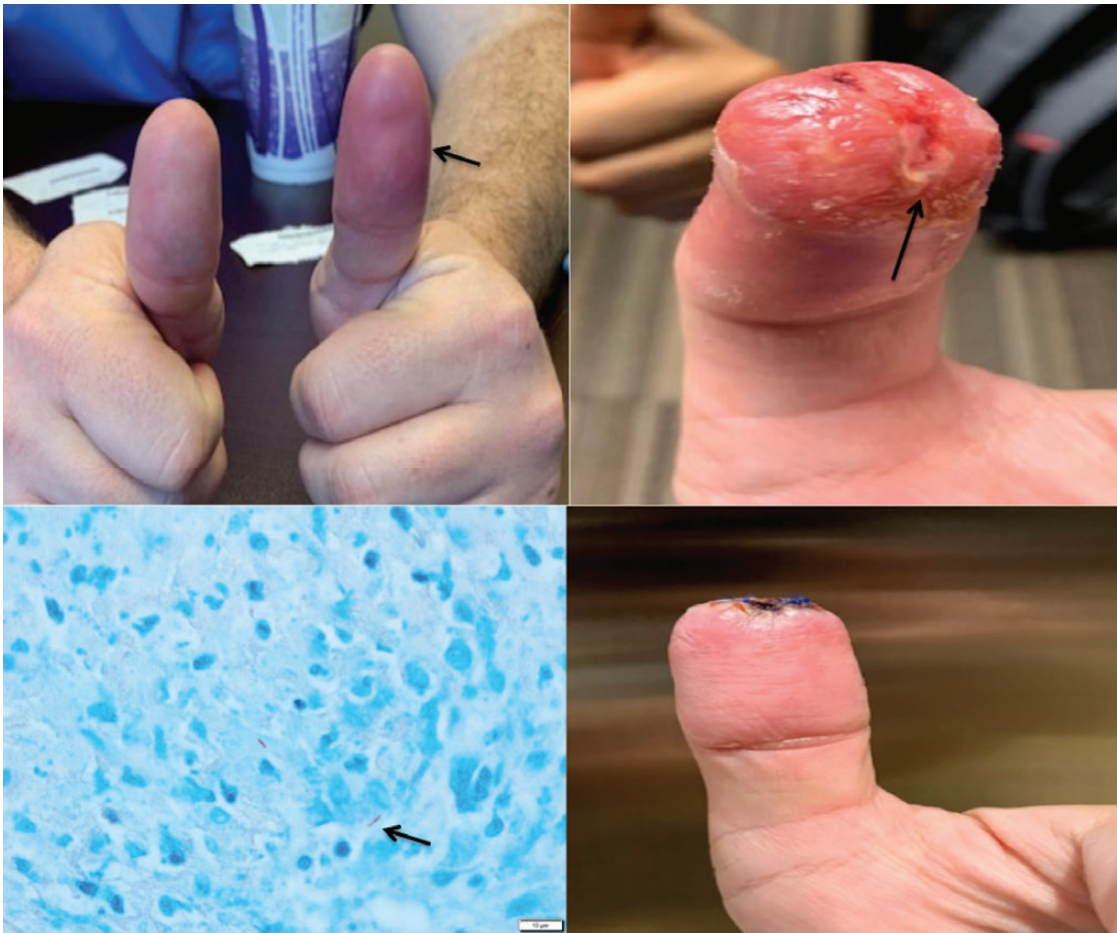A 42-year-old male physician with autoimmune thyroiditis on levothyroxine presented with a 3-week history of left thumb swelling, pain, and erythema. He was in his usual state of health until 3 weeks prior when he sustained a superficial needlestick injury to his left thumb while performing a needle biopsy of a neck LN in a patient. Ten days after the needlestick, he noticed redness, edema, and pain in his thumb (Figure 1). Following the initial diagnosis of skin and soft tissue infection with possible felon, the infection was drained through incision and a course of oral clindamycin was prescribed. The subject had no improvement and 3 weeks after injury, began having night sweats and chills without documented fever. Physical examination was noteworthy for a suppurative, chancre-like lesion on the distal thumb (Figure 1). Empiric treatment was initiated for skin and soft tissue infection with cefepime 1 g every 8 hours and vancomycin 15 mg/kg every 12 hours. Laboratory testing revealed an elevated C-reactive protein level of 14.2 mg/L and a white blood cell count of 11 700 cells/μL with 77.6% neutrophils. HIV type 1/2 and hepatitis viral panels were previously performed in compliance to the institution policy on post-needlestick precautions and were negative. Chest radiograph was normal,

Received 14 January 2021; editorial decision 24 March 2021; accepted 25 March 2021.

Correspondence: Alexandre E. Malek, MD, Department of Infectious Diseases, Infection Control and Employee Health, The University of Texas MD Anderson Cancer Center, Houston, Texas, 1515 Holcombe Blvd, Houston, TX 77030, USA (alex.e.malek@gmail.com).

### Open Forum Infectious Diseases® 2021

© The Author(s) 2021. Published by Oxford University Press on behalf of Infectious Diseases Society of America. This is an Open Access article distributed under the terms of the Creative Commons Attribution-NonCommercial-NoDerivs licence (<http://creativecommons.org/licenses/by-nc-nd/4.0/>), which permits non-commercial reproduction and distribution of the work, in any medium, provided the original work is not altered or transformed in any way, and that the work is properly cited. For commercial re-use, please contact journals.permissions@oup.com DOI: 10.1093/ofid/ofab160



**Figure 1.** Top left: Redness and edema of the left distal thumb (arrow) at 10 days after needlestick injury. Top right: Suppurative and chancre-like lesion on the distal thumb (arrow) at 21 days after needlestick injury. Bottom left: Histologic section of skin biopsy demonstrating acid-fast bacilli on Kinyoun staining (arrow). Bottom right: Improvement of the skin lesion 1 week after antituberculosis therapy.

but further testing showed a positive T-spot. Magnetic resonance imaging of the left hand (conducted 22 days after the needlestick) was consistent with osteomyelitis of the distal phalanx of the thumb. Since there was worsening of the lesion, the patient underwent an excisional debridement with a bone biopsy that revealed a necrotizing granulomatous inflammation and acid-fast bacilli on histopathological examination (Figure 1). The tissue culture yielded *Mtb*. Of interest, the putative source (patient zero) had a polymerase chain reaction (PCR)-positive result for *Mtb* in the LN biopsy. Our patient had negative induced sputum cultures for *Mtb* and a 4-drug regimen was started (daily isoniazid 300 mg, rifampin 600 mg, ethambutol 800 mg, and pyrazinamide 1500 mg). The isolate was found to be susceptible to rifampin, ethambutol, and isoniazid using the automated MGIT system (Becton Dickinson). The skin lesions improved within 1 week of anti-TB therapy (Figure 1). The patient returned to work afterward and gained normal thumb functions, except for mild numbness at the tip. However, 4 weeks after starting the anti-TB medications (7 weeks after inoculation), he noted left axillary swelling and severe pain, with

a cord-like structure along the medial aspect of the upper extremity from approximately the wrist to a palpable mass in the axilla. Clinical examination and ultrasound showed an enlargement of axillary LN consistent with lymphadenitis. Because lymphatic dysfunction is attributed to the cause of AWS after LN dissection, and because we have previously used investigational near-infrared fluorescence lymphatic imaging (NIRF-LI) to evaluate lymphatic (dys)function following LN dissection [7, 8], we sought to observe whether the distal lymphatics draining the site of the infection and draining into the axilla were functional. Subsequently at 8 weeks after the needlestick injury, the patient underwent NIRF-LI under a University of Texas Health Science Center at Houston Institutional Review Board-approved protocol (US Food and Drug Administration investigational new drug/investigational device exemption 102 827) with 7 off-label, intradermal injections of 25 µg of indocyanine green (ICG) in .1 cc of saline, administered on the affected left thumb as well as on the dorsal and volar aspect of both wrists [9, 10]. Because the distal injections in the affected arm did not drain to the cord-like structure and mass, 2 additional

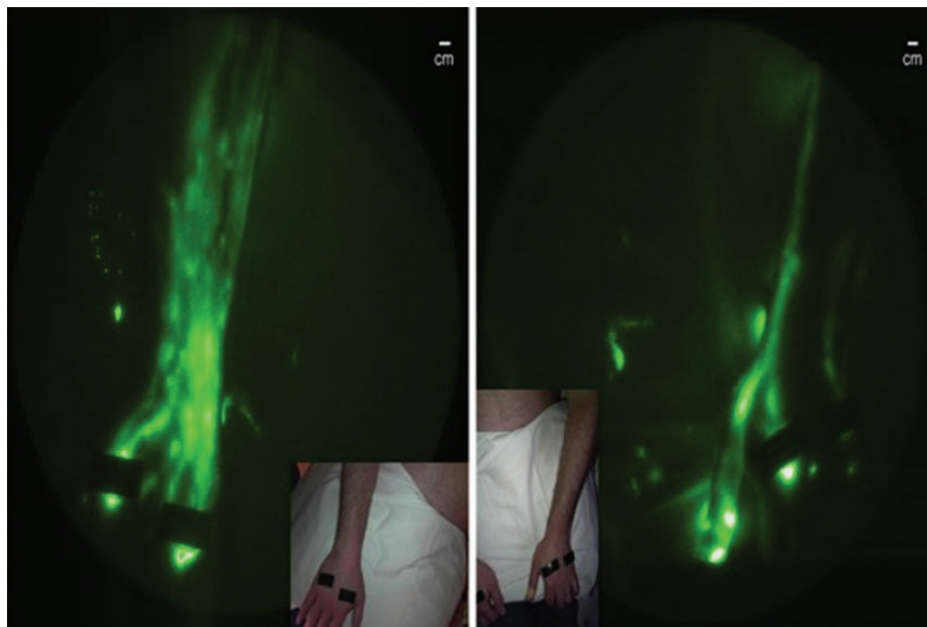
intra-dermal injections were made in the dorsal wrist and dorsal upper arm in an attempt to image the lymphatic cord and suspected fibrotic lymph node. Injections in the unaffected contralateral hand drained to numerous lymphatic vessels and LN that exhibited greater lymphatic trafficking than the affected hand (Figure 2; Supplementary Materials, Movies A and B). Lymphatic drainage from the affected thumb was relatively sparse and occurred via a comparatively dilated lymphatic vessel. There was no clinically apparent limb or thumb edema and no difference in the volume of the affected arm when compared to the unaffected arm by girth measurements. In contrast to the unaffected arm, the lymphatics visualized on the dorsal and volar aspects of the affected arm appeared dysfunctional and exhibited “dermal backflow” consistent with impaired lymphatic drainage (Figure 3), although drainage to the axillary LN was observed on the affected side (Figure 3). Palpation of the prominent lymphatic cord during NIRF-LI showed an absence of ICG drainage within the cord, nor did the enlarged and fibrotic axillary LN take up ICG-laden lymph, findings consistent with the diagnosis of AWS. Additional ultrasound-guided fine needle biopsy of the fibrotic LN was performed (at 6 weeks of anti-TB therapy), with histopathological examination showing acute inflammation and necrosis consistent with *Mtb* infection. No other diagnostics, imaging, or pathology were performed. PCR testing was positive for *Mtb*, but culture was negative. The patient had initially reduced shoulder motion at the time of AWS diagnosis, but never lost mobility in his upper extremity. Three months after commencing anti-TB

therapy, the patient had complete resolution of both the lymphadenopathy and the AWS. No follow-up lymphatic imaging was conducted. The patient was treated with anti-TB medications for a total of 6 months.

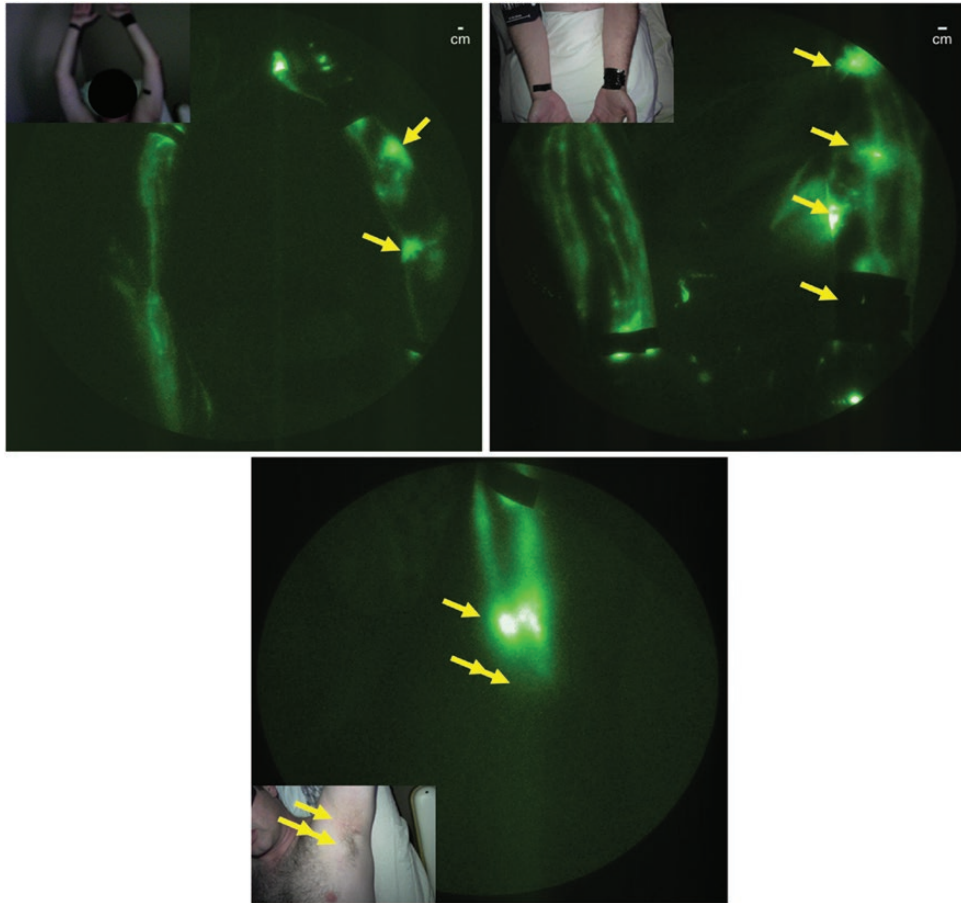
## DISCUSSION

Both the pulmonary tissue and the epidermis are rich in lymphatic capillaries. The pulmonary lymphatic vessels drain into bronchopulmonary and tracheobronchial LNs and from there drain into the internal jugular and subclavian veins for hematological spread. Likewise, lymphatic capillaries drain the epidermis through regional lymphatic basins before emptying into the hemovascular system [2]. Hence, pulmonary and cutaneous TB share the common pathway of the lymphatic vasculature as a conduit toward hematological spread.

Preclinical studies have shown that LECs serve as an essential niche for *Mtb* infection in the lymphatic system [5]. The host’s innate immune responses initiate granuloma formation through macrophage uptake of mycobacteria and subsequent recruitment of inflammatory cells. A delay in the recruitment of activated T and B cells results in mature inflammatory granulomas that act initially to eliminate or control *Mycobacterium* growth, but may promote *Mtb* sequestration and immune tolerance (Supplementary Materials, Schema) and may be responsible for residual disease [11]. Studies in guinea pigs revealed that lymphatic vessels serve as the earliest sites of infection and eventually develop granulomas in pulmonary LNs [12]. In



**Figure 2.** Left: Near-infrared fluorescence lymphatic imaging (NIRF-LI), with inset color image, of lymphatic drainage from the intradermal injection sites on the dorsum of the right (unaffected) hand. Right: NIRF-LI, with inset color image, of lymphatic drainage from the intradermal injection sites on the thumb and dorsum of the left (affected) hand showing fewer indocyanine green-laden lymphatic vessels draining the affected hand. Injection sites are covered with bandages and black vinyl tape. NIRF-LI images are presented in pseudo color and have been adjusted for brightness and contrast to enhance visualization of the full 16-bit image depth information.



**Figure 3.** Top left: Near-infrared fluorescence lymphatic imaging (NIRF-LI), with inset color image, of lymphatic drainage from the intradermal injection sites on the hands and wrists on the medial aspect of the upper and lower arms (hands positioned over patient's head). Areas of dermal lymphatic backflow, consistent with impaired lymphatic drainage, are identified by the arrows. Top right: NIRF-LI, with inset color image, of lymphatic drainage from the intradermal injection sites on the wrists showing fewer indocyanine green (ICG)-laden lymphatic vessels draining the affected hand as well as areas of dermal lymphatic backflow (arrows). Bottom: NIRF-LI, with inset color image, of lymphatic drainage into axillary lymph nodes (single arrow) on the affected side. The double arrow indicates the location of the enlarged and fibrotic lymph node with no uptake of ICG-laden lymph. Injection sites are covered with bandages and black vinyl tape. NIRF-LI images are presented in pseudo color and have been adjusted for brightness and contrast to enhance visualization of the full 16-bit image depth information.

humans, direct evidence for lymphatic dissemination through the lymphatic vasculature remains missing.

The lymphatic vasculature is a unidirectional system that pumps lymph, carrying antigens and antigen-presenting immune cells, from the lymphatics that surround all organ surfaces to regional LN basins [13]. In TB, *Mtb*-infected monocytes are delivered through the initial lymphatics to the downstream regional LNs where a local adaptive immune response occurs. These infected cells cross-present antigen and generate antigen-specific, activated T and B cells. Under proinflammatory conditions (ie, in the presence of tumor necrosis factor- $\alpha$ , interleukin 1 $\beta$ , or interleukin 6), lymphatic pumping can be arrested [12], but unlike the blood system, stasis does not generally result in lymph thrombosis, since the capacity for fibrin generation is limited in lymph [13, 14]. Impairment of lymphatic pumping or blockage results in reverse flow, a phenomenon typically

observed on the skin with NIRF-LI as dermal backflow [15]. If left untreated, impaired lymphatic return results in irreversible lymphedema and/or immune dysfunction. Lymphedema is a common morbidity associated with cancer treatment involving LN dissection and radiation; AWS is also a comorbidity of LN dissection, although not necessarily associated with lymphedema [16]. AWS refers to a taut, ropelike structure that develops along the medial arm and is highly restrictive of arm movement. Moskovitz and colleagues were first to demonstrate that the pathogenesis of AWS involves the lymphatics. Since then, AWS has been presumed to be an afferent, thrombosed lymphatic vessel, although the cause of thrombosis within the lymphatics remains unknown [16, 17].

The dissemination of *Mtb* from the digit to the axilla in our patient appears to have occurred through the lymphatic vasculature, as confirmed through pathological examination

of the draining LN. The tuberculosis chancre associated with regional adenopathy is analogous to the tuberculous Ghon complex in pulmonary infection. At the time of imaging, the status of the infection was improving, but an inflammatory response may have been present as evidenced by impaired lymphatic function. While there was no clinically apparent lymphedema or measurable change in arm volume, visible dermal backflow was observed similarly to our previously reported findings in breast cancer survivors diagnosed with cancer-related lymphedema and in head and neck patients following LN dissection and radiation treatment [7, 8]. We hypothesize that the impaired lymphatic pumping in our patient, caused by proinflammatory conditions or lymphatic blockage, results in dermal backflow. The blockage may well be a thrombosed lymphatic vessel and/or LN that harbored infection. The lack of ICG uptake into the cord or the fibrosed LN, as visualized by NIRF-LI, is consistent with a thrombosed lymphatic vessel and the diagnosis of AWS.

AWS predominantly develops as a postoperative complication around 8 weeks following axillary LN dissection in breast cancer patients and has a cumulative incidence of 36.2% at 2 years after cancer treatment [18, 19]. Of interest, Rashtak and colleagues described the first non-cancer-related report of AWS following axillary furunculosis. Factor XIIIa staining did not indicate fibrin thrombosis within the lymphatic vessels, and the site of *Staphylococcus aureus* infection was proximal to the cord formation but within the same draining lymphatic watershed [20]. A few cases of AWS have been associated with metastatic cancer to regional LNs and related to strenuous exercise [21]. As in our case, a subject with AWS unrelated to cancer or cancer surgery may require further testing to determine the underlying etiology as it may be related to infection. In terms of management, physical therapy and exercise are the mainly endorsed options, but infection control should be considered [22]. In our case, the pathogenesis of AWS or cause of lymphovascular thrombosis remains unclear. It is well known that neutrophils migrate to granulomas, the afferent lymph vessels, and LNs in response to bacterial infections and chronic inflammation [23, 24]. Essential to the destruction of microorganisms, dying neutrophils release DNA to form neutrophil extracellular traps (NETs) in a process called NETosis that can cause vascular thrombosis [23, 24]. While systemic neutrophil levels were elevated in our subject, it remains to be fully investigated whether NETosis occurs in the lymphatics and may be responsible for thrombosis and AWS. To our knowledge, ours is the first report of AWS in the presentation of TB infection and is consistent with the biology of *Mtb* sequestration in LECs, neutrophil recruitment, granuloma initiation, and residual disease. In summary, the lymphatic vasculature and draining LNs may play an important role in the progression of TB as well as refractory, residual disease. Herein, we describe a clinical case of cutaneous TB wherein lymphatic involvement could be visualized

in a manner not possible in other cases of pulmonary or other extrapulmonary TB.

### Supplementary Data

Supplementary materials are available at *Open Forum Infectious Diseases* online. Consisting of data provided by the authors to benefit the reader, the posted materials are not copyedited and are the sole responsibility of the authors, so questions or comments should be addressed to the corresponding author.

Supplemental Movie A. Movie of active lymphatic trafficking in the unaffected, right lateral arm.

Supplemental Movie B. Movie of sluggish lymphatic trafficking in the left, affected thumb and lateral arm.

Supplemental Schema. Overview of phases of tuberculosis (TB) infection and the pathophysiology of granuloma formation in the lymph nodes (LN) and the role of lymphatic endothelial cells (LECs).

### Notes

**Acknowledgments.** The patient's written consent was obtained.

**Author contributions.** A. E. M., R. J. K., and L. O. Z. initiated the idea and were involved in patient treatment. C. E. F., J. C. R., and R. M. conducted lymphatic imaging. E. M. S.-M., C. E. F., and J. C. R. interpreted results. All authors contributed to all sections relevant to their experience and helped finalize the text and content.

**Financial support.** C. E. F., J. C. R., and E. M. S.-M. are listed as inventors on patents associated with near-infrared fluorescence lymphatic imaging and may receive future financial benefit from its commercialization. C. E. F., J. C. R., E. M. S.-M., and the University of Texas Health Science Center at Houston have research-related financial interests in Lymphatic Science, Inc.

**Potential conflicts of interest.** All authors: No reported conflicts of interest.

All authors have submitted the ICMJE Form for Disclosure of Potential Conflicts of Interest. Conflicts that the editors consider relevant to the content of the manuscript have been disclosed.

### References

1. World Health Organization. Global tuberculosis report 2020. Available at: <http://apps.who.int/bookorders>. Accessed 3 January 2021.
2. Ling P, Flynn J. Understanding latent tuberculosis: a moving target. *J Immunol* **2010**; 185:15–22.
3. van Zyl L, du Plessis J, Viljoen J. Cutaneous tuberculosis overview and current treatment regimens. *Tuberculosis (Edinb)* **2015**; 95:629–38.
4. Collu C, Fois A, Crivelli P, et al. A case-report of a pulmonary tuberculosis with lymphadenopathy mimicking a lymphoma. *Int J Infect Dis* **2018**; 70:38–41.
5. Lerner TR, de Souza Carvalho-Wodarz C, Repnik U, et al. Lymphatic endothelial cells are a replicative niche for *Mycobacterium tuberculosis*. *J Clin Invest* **2016**; 126:1093–108.
6. Schlesinger LS. Macrophage phagocytosis of virulent but not attenuated strains of *Mycobacterium tuberculosis* is mediated by mannose receptors in addition to complement receptors. *J Immunol* **1993**; 150:2920–30.
7. Aldrich MB, Rasmussen JC, Fife CE, Shaitelman SF, Sevcik-Muraca EM. The development and treatment of lymphatic dysfunction in cancer patients and survivors. *Cancers* **2020**; 12:2280.
8. Rasmussen JC, Tan IC, Naqvi S, et al. Longitudinal monitoring of the head and neck lymphatics in response to surgery and radiation. *Head Neck* **2017**; 39:1177–88.
9. Rasmussen JC, Kwon S, Sevcik-Muraca EM, Cormier JN. The role of lymphatics in cancer as assessed by near-infrared fluorescence imaging. *Ann Biomed Eng* **2012**; 40:408–21.
10. Rasmussen JC, Tan IC, Marshall MV, et al. Human lymphatic architecture and dynamic transport imaged using near-infrared fluorescence. *Transl Oncol* **2010**; 3:362–72.
11. Ramakrishnan L. Revisiting the role of the granuloma in tuberculosis. *Nat Rev Immunol* **2012**; 12:352–66.
12. Basaraba RJ, Smith EE, Shanley CA, Orme IM. Pulmonary lymphatics are primary sites of *Mycobacterium tuberculosis* infection in guinea pigs infected by aerosol. *Infect Immun* **2006**; 74:5397–401.
13. Lippi G, Favalaro EJ, Cervellini G. Hemostatic properties of the lymph: relationships with occlusion and thrombosis. *Semin Thromb Hemost* **2012**; 38:213–21.

14. Aldrich MB, Sevick-Muraca EM. Cytokines are systemic effectors of lymphatic function in acute inflammation. *Cytokine* **2013**; 64:362–9.
15. Rasmussen JC, Tan IC, Marshall MV, et al. Lymphatic imaging in humans with near-infrared fluorescence. *Curr Opin Biotechnol* **2009**; 20:74–82.
16. Johansson K, Chong H, Ciornei CD, et al. Axillary web syndrome: evidence for lymphatic origin with thrombosis. *Lymphat Res Biol* **2020**; 18:329–32.
17. Moskovitz AH, Anderson BO, Yeung RS, et al. Axillary web syndrome after axillary dissection. *Am J Surg* **2001**; 181:434–9.
18. Mullen LA, Harvey SC. Review of axillary web syndrome: what the radiologist should know. *Eur J Radiol* **2019**; 113:66–73.
19. O’Toole J, Miller CL, Specht MC, et al. Cording following treatment for breast cancer. *Breast Cancer Res Treat* **2013**; 140:105–11.
20. Rashtak S, Gamble GL, Gibson LE, Pittelkow MR. From furuncle to axillary web syndrome: shedding light on histopathology and pathogenesis. *Dermatology* **2012**; 224:110–4.
21. Koehler LA, Hunter DW. Lymphspiration: the axillary web and its lymphatic origin. *Lymphology* **2016**; 49:185–91.
22. Gideon HB, Phuah J, Junecko BA, Mattila JT. Neutrophils express pro- and anti-inflammatory cytokines in granulomas from *Mycobacterium tuberculosis*-infected cynomolgus macaques. *Mucosal Immunol* **2019**; 12:1370–81.
23. Desai J, Mulay SR, Nakazawa D, Anders HJ. Matters of life and death. How neutrophils die or survive along NET release and is “NETosis”=necroptosis? *Cell Mol Life Sci* **2016**; 73:2211–9.
24. Fuchs TA, Brill A, Duerschmied D, et al. Extracellular DNA traps promote thrombosis. *Proc Natl Acad Sci U S A* **2010**; 107:15880–5.