

# A Case of Urinary Tract Infection Caused by Multidrug Resistant *Streptococcus mitis/oralis*

Baohu Zhang<sup>1,\*</sup>, Jie Zhou<sup>1,\*</sup>, Guancong Xie<sup>2,\*</sup>, Li Zhang<sup>1</sup>, Yang Zhang<sup>1</sup>, Kangli Xu<sup>1</sup>, Tianyuan Feng<sup>1</sup>, Shucai Yang<sup>1</sup>

<sup>1</sup>Department of Clinical Laboratory, Pingshan General Hospital, Southern Medical University (Pingshan District People's Hospital of Shenzhen), Shenzhen, Guangdong, People's Republic of China; <sup>2</sup>Department of Cardiovascular Medicine, Pingshan General Hospital, Southern Medical University (Pingshan District People's Hospital of Shenzhen), Shenzhen, Guangdong, People's Republic of China

\*These authors contributed equally to this work

Correspondence: Shucai Yang; Tianyuan Feng, Email [shucaiyang@link.cuhk.edu.hk](mailto:shucaiyang@link.cuhk.edu.hk); [psyfty@sina.com](mailto:psyfty@sina.com)

**Abstract:** *S. mitis/oralis* has been previously reported in isolated cases of bacterial endocarditis and liver abscesses. Its presence in urine is generally considered a contaminant. A 66-year-old male patient was admitted to the hospital due to recurrent chest tightness and four-year history of exertional dyspnea. On the second day of admission, the patient presented with urgent and frequent urination, as well as dysuria. Both initial and subsequent urine cultures showed *S. mitis/oralis* infection, with polymorphonuclear leukocyte phagocytosis observed in the second sample. MALDI-TOF results confirmed the isolated strain as *S. mitis/oralis*. Drug susceptibility testing revealed multidrug resistance to penicillin, ceftriaxone, cefepime, levofloxacin, ofloxacin, and tetracycline, but sensitivity to quinupristin/dalfopristin, vancomycin, and linezolid. The clinician then prescribed vancomycin for anti-infective treatment, which proved effective. Keywords: *S. mitis/oralis*, UTI, MDR, phagocytosis

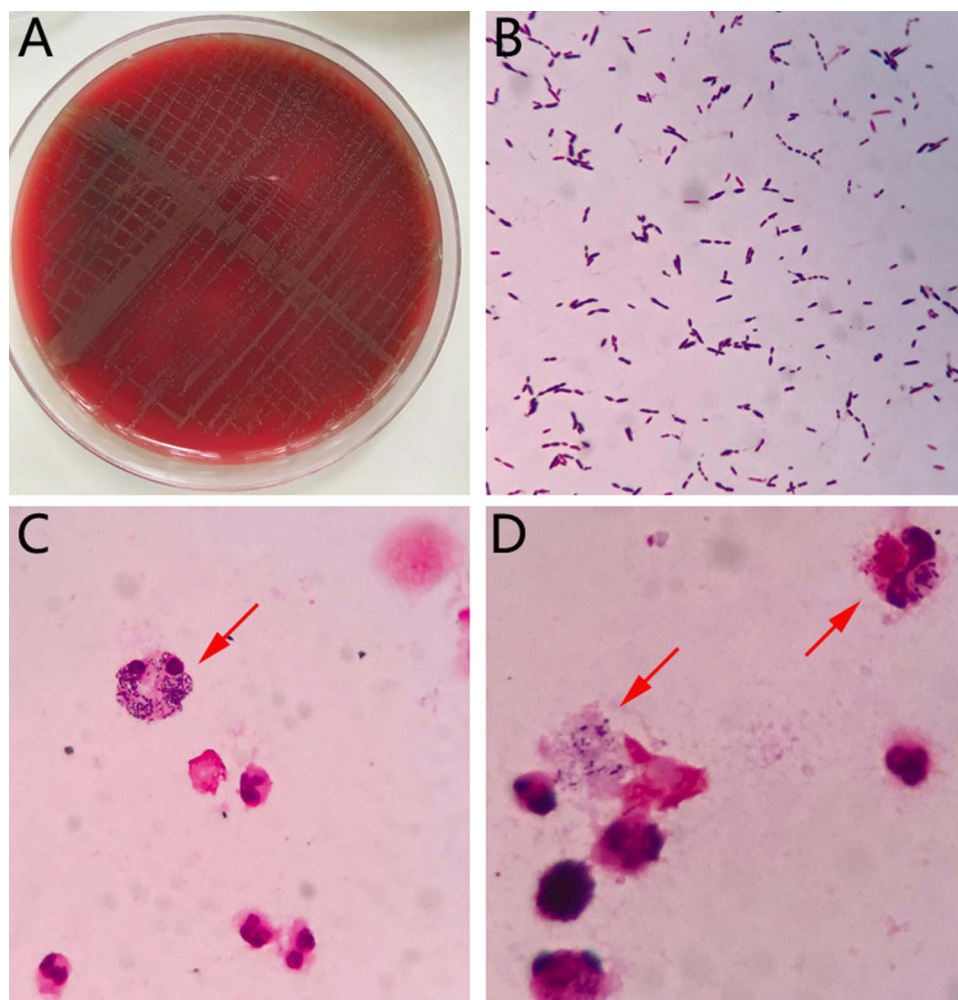
**Keywords:** *Streptococcus mitis/oralis*, UKI, multidrug resistant, phagocytosis

## Introduction

*S. mitis/oralis* belongs to the family of viridans group streptococci (VGS), commonly found in the oral cavity, digestive tract and female reproductive tract, which are typically considered normal flora and are not generally pathogenic. The isolation of *S. mitis/oralis* in urine is usually attributed to commensal or contaminating bacteria, resulting in limited studies on urinary tract infections (UTIs) caused by this bacterium.<sup>1,2</sup> Here, we report a case of UTI complicated by *S. mitis/oralis* in a patient with hydronephrosis.

## Case Report

A 66-year-old male patient was admitted to the hospital due to recurrent chest tightness and four-year history of exertional dyspnea. Medical treatment involving coronary artery dilation alleviated these symptoms. On the second day of admission, the patient presented with urgent and frequent urination, as well as dysuria. The patient was instructed to provide a clean mid-stream urine sample for routine examination and culture. Urinalysis revealed leukocyte esterase 3+, occult blood 1+, urine protein 1+, and a white blood cell count exceeding 30/HP. On the third day, Gram staining of the urine culture revealed positive cocci chains (Figure 1A and B). MALDI-TOF results identified the colonies as *S. mitis/oralis*. Although *S. mitis/oralis* is generally considered a contaminant when isolated from urine samples in clinical practice, additional tests were conducted to determine whether the bacterium was a pathogen or contaminant in this case. The patient provided another urine sample for re-examination. Upon centrifugation and sediment Gram staining, a high number of polymorphonuclear leukocytes and positive cocci chains were observed (Figure 1C and D). Interestingly, polymorphonuclear leukocyte phagocytosis was also detected, indicating *S. mitis/oralis* as the causative agent of the UTI. MALDI-TOF results further confirmed the presence of *S. mitis/oralis*. Drug susceptibility tests were performed using the E-Test and K-B susceptibility



**Figure 1** (A) Culture of the first urine specimen on blood plate; (B) Gram stain result of the first cultured strain; (C and D) phenomenon of polymorphonuclear Leukocyte phagocytosis under microscope. Red arrow point to the phenomenon of polymorphonuclear Leukocyte phagocytosis.

test, which revealed multidrug resistance (MDR) to penicillin, ceftriaxone, cefepime, levofloxacin, ofloxacin, and tetracycline, but sensitivity to quinupristin/dalfopristin, vancomycin and linezolid. Based on the patient's condition, the clinician prescribed vancomycin 1.0g every 12 hours for three days as an anti-infective treatment. Three days later, a subsequent urine culture was negative, and the patient was discharged.

## Discussion

Infections caused by *S. mitis/oralis* were primarily associated with infective endocarditis,<sup>3,4</sup> but recent case reports have documented sepsis, liver abscesses, and endophthalmitis caused by this bacterium.<sup>5–7</sup> Common urinary tract infection (UTI) pathogens include *Escherichia coli*, *Klebsiella pneumoniae*, *Proteus mirabilis*, *Enterococcus faecalis*, *Staphylococcus saprophyticus*, and some of them demonstrate multidrug resistance.<sup>8–10</sup> *S. mitis/oralis* is not a typical cause of UTIs, and when isolated from urine cultures, the white blood cell count is usually normal, suggesting contamination from the digestive or reproductive tracts.

In this case, microscopic examination of the patient's urine samples revealed numerous streptococci and white blood cells, with bacterial phagocytosis by white blood cells also observed. Two urine cultures tested positive for *S. mitis/oralis*, confirming a UTI caused by this bacterium. Further investigation revealed that the patient had alcoholic liver disease and diabetes, both of which can compromise the immune system. A stool test also detected *Strongyloides stercoralis*, suggesting a possible weakened immune system. The patient had a history of bilateral multiple kidney stones,

bilateral hydronephrosis, urinary retention, and benign prostatic hyperplasia. The patient developed obstructive hydro-nephrosis at the bladder outlet during this episode. The combination of a weakened immune system and urinary obstruction likely contributed to the *S. mitis/oralis* infection in this case.

*S. mitis/oralis* demonstrated resistance to penicillin, cephalosporins, quinolones and tetracyclines, indicating multi-drug resistance. Initial treatment with piperacillin-tazobactam did not improve urinary symptoms. Subsequent treatment with vancomycin led to significant improvement, further confirming *S. mitis/oralis* as the UTI-causing pathogen.

There have been previous case reports of *S. mitis/oralis* causing urinary tract infections. One such case involved an 11-year-old child who was a kidney transplant recipient and had been continuously on immunosuppressive drugs post-transplantation.<sup>11</sup> Another patient was a 55-year-old woman with diabetes and a urethral protrusion.<sup>12</sup> These cases suggest that *S. mitis/oralis* can cause urinary tract infections when the patient's immune function is suppressed or compromised. Unlike the above two cases, we not only used an increase of white blood cells in routine urine tests and the presence of a large number of bacteria in urine cultures to diagnose urinary tract infections, but we also used the phenomenon of phagocytosis by leukocytes under the microscope, which provided direct evidence that the urinary tract infection was indeed caused by *S. mitis/oralis*. The phagocytosis by leukocytes refers to the process where white blood cells (leukocytes) ingest harmful microorganisms or foreign particles, a key mechanism in the immune response against infections. This process allows the immune system to effectively destroy or neutralize potential pathogens.<sup>13–15</sup>

In conclusion, *S. mitis/oralis* should not be dismissed as a contaminant when isolated from urine cultures. Urinalysis results must be considered, and additional urine samples should be collected to observe potential bacterial phagocytosis by white blood cells. Given *S. mitis/oralis*' multi-drug resistance, clinicians should select antibiotics based on drug sensitivity test results.

## Data Sharing Statement

The datasets used and analyzed during the current study are available from the corresponding author Dr. Shucai Yang on reasonable request.

## Ethics Statement

Human Ethics approval was obtained from the Pingshan General Hospital of Southern Medical University Committee and the study was performed in accordance with the 1964 Declaration of Helsinki. Informed consent for publication of the personal information and clinical data have been obtained from the patient.

## Acknowledgment

We thank Wengrong Kang and Juan Zhang for their technical assistance.

## Funding

This study was supported by grants from the National Natural Science Foundation of China (No.82272986 to SY), the Natural Science Foundation of Guangdong Province, China (No.2023A1515010230 to SY), the Science and Technology Foundation of Shenzhen (No.JCYJ20220531094805012 to SY), the Project of Educational Commission of the Guangdong Province of China (No.2022KTSCX022 to JZ), and the National Key R&D Program of China (No.2020YFC2006400 to TF).

## Disclosure

The authors report no conflicts of interest in this work.

## References

1. Mores CR, Price TK, Wolff B, et al. Genomic relatedness and clinical significance of *Streptococcus mitis* strains isolated from the urogenital tract of sexual partners. *Microbial Genom.* 2021;7(3). doi:10.1099/mgen.0.000535
2. Nelson DE, Van Der Pol B, Dong Q, et al. Characteristic male urine microbiomes associate with asymptomatic sexually transmitted infection. *PLoS One.* 2010;5(11):e14116. doi:10.1371/journal.pone.0014116
3. Amorgianos D, Chen HM, Walker N. *Streptococcus mitis* infective endocarditis in a patient with ventricular septal defect and orthodontic appliances. *BMJ Case Rep.* 2022;15(3):e248349. doi:10.1136/bcr-2021-248349

4. Byrd VS, Nemeth AS. A case of infective endocarditis and spinal epidural abscess caused by streptococcus mitis bacteremia. *Case Rep Infect Dis.* 2017;2017:7289032. doi:10.1155/2017/7289032
5. Chaemsaihong P, Lertrut W, Kamlungkuea T, et al. Maternal septicemia caused by Streptococcus mitis: a possible link between intra-amniotic infection and periodontitis. Case report and literature review. *BMC Infect Dis.* 2022;22(1):562. doi:10.1186/s12879-022-07530-z
6. Chung JK, Lee SJ. Streptococcus mitis/oralis endophthalmitis management without phakic intraocular lens removal in patient with iris-fixated phakic intraocular lens implantation. *BMC Ophthalmol.* 2014;14:92. doi:10.1186/1471-2415-14-92
7. Sarthy J, DiBardino D. Pyogenic liver abscess caused by Streptococcus mitis. *Lancet Infect Dis.* 2013;13(9):822. doi:10.1016/S1473-3099(13)70166-X
8. Flores-Mireles AL, Walker JN, Caparon M, Hultgren SJ. Urinary tract infections: epidemiology, mechanisms of infection and treatment options. *Nat Rev Microbiol.* 2015;13(5):269–284. doi:10.1038/nrmicro3432
9. Haindongo EH, Funtua B, Singu B, et al. Antimicrobial resistance among bacteria isolated from urinary tract infections in females in Namibia, 2016–2017. *Antimicrob Resist Infect Control.* 2022;11(1):33. doi:10.1186/s13756-022-01066-2
10. Sokhn ES, Salami A, El Roz A, Salloum L, Bahmad HF, Ghssein G. Antimicrobial susceptibilities and laboratory profiles of Escherichia coli, Klebsiella pneumoniae, and proteus mirabilis isolates as agents of urinary tract infection in Lebanon: paving the way for better diagnostics. *Med Sci.* 2020;8(3):32. doi:10.3390/medsci8030032
11. Ong G, Barr JG, Savage M. Streptococcus mitis: urinary tract infection in a renal transplant patient. *J Infect.* 1998;37(1):91–92. doi:10.1016/S0163-4453(98)91421-9
12. Swain B, Otta S. Streptococcus mitis: an unusual causative agent for urinary tract infection. *J Lab Physicians.* 2013;5(2):144–145. doi:10.4103/0974-2727.119876
13. Underhill DM, Goodridge HS. Information processing during phagocytosis. *Nat Rev Immunol.* 2012;12(7):492–502. doi:10.1038/nri3244
14. Flannagan RS, Jaumouille V, Grinstein S. The cell biology of phagocytosis. *Annu Rev Pathol.* 2012;7:61–98. doi:10.1146/annurev-pathol-011811-132445
15. Rosales C, Uribe-Querol E. Phagocytosis: a fundamental process in immunity. *Biomed Res Int.* 2017;2017:9042851. doi:10.1155/2017/9042851

## Infection and Drug Resistance

Dovepress

### Publish your work in this journal

Infection and Drug Resistance is an international, peer-reviewed open-access journal that focuses on the optimal treatment of infection (bacterial, fungal and viral) and the development and institution of preventive strategies to minimize the development and spread of resistance. The journal is specifically concerned with the epidemiology of antibiotic resistance and the mechanisms of resistance development and diffusion in both hospitals and the community. The manuscript management system is completely online and includes a very quick and fair peer-review system, which is all easy to use. Visit <http://www.dovepress.com/testimonials.php> to read real quotes from published authors.

Submit your manuscript here: <https://www.dovepress.com/infection-and-drug-resistance-journal>