Primary anastomosis closure after endoscopic ultrasound-directed transgastric intervention

Authors
YongYan Cui[1], Jose Antonio Almario[2], Michael Bejjani[3], Mouen A. Khashab[3], Shayan Irani[4]

Institutions
1 Gastroenterology, Virginia Mason Medical Center, Seattle, United States
2 Gastroenterology, Johns Hopkins Medicine, Baltimore, United States
3 Gastroenterology and Hepatology, Johns Hopkins Hospital, Baltimore, United States
4 Gastroenterology and Hepatology, Virginia Mason Medical Center, Seattle, United States

Keywords
Endoscopic ultrasonography, Intervention EUS, Pancreatobiliary (ERCP/PTCD), Stones

received 9.11.2023
accepted after revision 14.2.2024

Bibliography
Endosc Int Open 2024; 12: E526–E531
DOI 10.1055/a-2272-0927
ISSN 2364-3722

Georg Thieme Verlag KG, Rüdigerstraße 14, 70469 Stuttgart, Germany

Corresponding author
Dr. YongYan Cui, Virginia Mason Medical Center, Gastroenterology, Seattle, United States
yycui90@gmail.com
yoc9034@nyp.org

ABSTRACT

Background and study aims Endoscopic ultrasound-directed transgastric intervention (EDGI) is a technique that creates an anastomosis between the gastric pouch or jejunum to the excluded stomach in Roux-en-Y gastric bypass (RYGB) anatomy to allow access to the pancreaticobiliary system. Thus far, management of anastomosis closure at the time of lumen-apposing metal stent (LAMS) removal has varied widely. This study aimed to assess the efficacy of primary closure at the time of LAMS removal using a through-the-scope (TTS) tack-based suture system.

Patients and methods This was a two-center retrospective study of RYGB patients who underwent single-stage EDGI using a 20-mm LAMS and subsequent primary anastomosis closure with the X-tack system at the time of stent removal. Patient demographics, procedure details, clinical outcomes, and imaging findings are reported.

Results Nineteen patients (median age 63 years, 84% female) underwent single-stage EDGI with a median follow-up of 31.5 months. Adverse events occurred in two patients (11%) who had abdominal pain requiring hospitalization. The median LAMS dwell time was 32 days (range 16–86). All patients (100%) who underwent follow-up studies after LAMS removal had confirmed anastomosis closure (n = 18). Most patients had documented weight loss at the time of LAMS removal and at last follow-up (68%, n = 13).

Conclusions Single-stage EDGI is an effective approach to managing RYGB patients with pancreaticobiliary pathology. Thus far, endoscopic TTS tack-based suturing appears to have a high success rate in anastomosis closure after LAMS removal and should be considered as a primary method for preventing chronic fistulae.

Introduction

Endoscopic management of pancreaticobiliary and foregut diseases can be challenging in patients with Roux-en-Y gastric bypass (RYGB) anatomy. For years, performing endoscopic retrograde cholangiopancreatography (ERCP) in RYGB patients was centered around enteroscopy-assisted ERCP (EA-ERCP) and laparoscopy-assisted ERCP (LA-ERCP). In 2014, endoscopic ultrasound (EUS)-directed transgastric ERCP (EDGE) was introduced as an alternative that would allow easier access to the excluded stomach, proximal small bowel, and pancreaticobiliary system [1]. The EDGE procedure involves using a lumen-apposing met-

al stent (LAMS) to create an anastomosis between the gastric pouch or proximal jejunum to the excluded stomach; thereafter, ERCP is performed through the anastomosis. Studies have reported high rates of technical success with EDGE as well as decreased procedure time, hospital length of stay, and total cost when compared with EA-ERCP and LA-ERCP [2, 3, 4, 5].

In the last few years, EUS-directed transgastric intervention (EDGI) has expanded beyond ERCP to include diagnostic and therapeutic EUS procedures [6, 7]. Despite the benefits of EDGI as compared with enteroscopy- and laparoscopy-assisted endoscopic procedures, concerns remain about complications such as intraprocedural stent dislodgment and post-LAMS removal fistulae. Same-session EDGI (SS-EDGI) has previously been considered a higher risk for intraprocedural stent dislodgment when compared with dual-session EDGI. However, studies have demonstrated that stent dislodgment during SS-EDGI can be mitigated by using a 20-mm LAMS and by securing the LAMS in place with sutures [8, 9]. Although stent migration may be minimized by taking these measures, the risk of post-LAMS removal fistulae remains a clinical issue, especially in those with longer LAMS dwell time [10, 11, 12]. A recent meta-analysis reported a 17% pooled rate of failure of fistula closure after LAMS removal and a separate prospective study reported a persistent fistula rate of 41% [2, 10]. Of note, these studies had different management styles for anastomoses after LAMS removal including spontaneous closure, suturing, argon plasma coagulation (APC) of the edges, over-the-scope clips (OTSCs), and through-the-scope (TTS) clips. As such, there has been wide variation in clinical management of gastro-gastric (GG) and jejuno-gastric (JG) anastomoses after stent removal. In our experience, endoscopic suturing with TTS tack-based suturing is an effective method in closing challenging gastrointestinal tract defects, with the benefits of being less time intensive and more accessible in tight spaces than the OverStitch Endoscopic Suturing System (Boston Scientific, Massachusetts, United States). This study aimed to assess the efficacy of primary closure at LAMS removal in preventing chronic fistulae, using a TTS tack-based suturing system – the X-tack Endoscopic HeliX Tacking System (Boston Scientific, Massachusetts, United States).

Patients and methods

Study design

This was a two-center, retrospective, cohort study involving patients with RYGB anatomy who underwent same-session EDGI with a 20-mm electrocautery-enhanced LAMS (AXIOS Stent and Delivery System; Boston Scientific, Massachusetts, United States) between December 2020 and June 2023. Patients were included if TTS tack-based suturing was used for closure of the GG or JG anastomosis at the time of LAMS removal. Endoscopists at both high-volume tertiary care centers were proficient with EDGI, having performed more than 40 cases previously. The study was approved by the Institutional Review Boards at both institutions.

Procedure design

All procedures were performed under general anesthesia following endotracheal intubation and one dose of prophylactic antibiotics. A linear echoendoscope was used to identify the excluded stomach from either the gastric pouch or the proximal jejunal Roux limb. After achieving an optimal position – one with the best ultrasound view of the excluded stomach and with the best orientation under fluoroscopy to accommodate a straight duodenoscope or echoendoscope – Doppler imaging was used to confirm absence of intervening vessels before a 19-gauge fine-needle aspiration needle was used to puncture the excluded stomach. Under fluoroscopic and EUS guidance, contrast was injected to confirm needle placement in the excluded stomach prior to distending the stomach with saline. A 20 mm × 10 mm electrocautery-enhanced LAMS was then used to puncture the distended stomach using a freehand approach. Once the excluded stomach was accessed, the distal phalange of the stent was deployed under EUS guidance before the proximal phalange was deployed into the gastric pouch or proximal jejunum (▶ **Fig. 1**) The LAMS was then dilated with a 15 to 18 CRE balloon to 18 mm. Using the TTS tack-based suturing system, two sutures were then used to secure the proximal phalange of the stent to the mucosa of the gastric pouch or jejunum. After the stent was secured, a duodenoscope or echoendoscope was then advanced through the LAMS into the excluded stomach and duodenum to perform the intended pancreaticobiliary or foregut endotherapy. Following EDGI, patients were kept on a clear liquid diet until the following morning, when they would resume their regular diet. Patients were kept on a proton pump inhibitor (PPI) while the LAMS remained in place.

LAMS removal

The timing of LAMS removal was dependent on whether serial endoscopic sessions, such as ERCPs, were required. If only a single procedure was required, LAMS removal was planned for 4

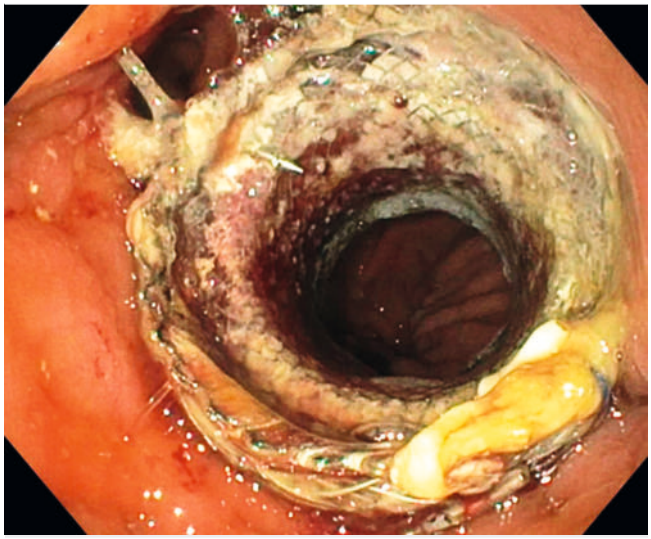

▶ **Fig. 1** Gastrogastrostomy with lumen-apposing metal stent (LAMS) in place.

weeks after the initial procedure. If serial procedures were required, then the LAMS was left in place until the final procedure. LAMS dwell time was defined as the number of days between LAMS placement and removal. During LAMS removal, either APC or endoscopic scissors were used to disrupt the sutures before the stent was removed with a rat-toothed forceps or snare. Following LAMS removal, endoscopists could choose whether to apply APC to the tract before prophylactically suturing the anastomosis closed with the TTS tack-based suturing system (▶ **Fig. 2** and ▶ **Fig. 3**). Follow-up studies with upper gastrointestinal endoscopy (with contrast injection under fluoroscopy), upper gastrointestinal series (UGIS), computed tomography (CT) scan with oral contrast, or magnetic resonance (MR) enterography were used to confirm fistula closure typically at 4 to 8 weeks after stent removal and then again at 1 year after stent removal. Closure was defined by absence of contrast leakage into the excluded stomach. Patients remained on PPI after stent removal until confirmation of fistula closure.

Study outcomes and definitions

The primary outcome of this study was the rate of persistent fistulae as determined by either endoscopy, UGIS, CT scan, or MR enterography at least 1 month after stent removal. Secondary outcomes of the study included technical success of SS-EDGI, procedure duration (as measured by time from scope insertion to time of scope removal), stent dwell time, post-procedure weight change, and peri-procedure adverse events (AEs0 including rate of stent dislodgment. Technical success of SS-EDGI was defined as the placement of an EUS-gastrogastrostomy or jejunogastrostomy via a 20-mm LAMS that was endoscopically secured in place with sutures, followed by performance of ERCP or EUS via the LAMS. AEs were assessed via chart review and graded according to the American Society of Gastrointestinal Endoscopy lexicon [13]. Results were reported as mean with standard deviation (SD), median, and percentage for categorical variables.

Results

Patient and procedure characteristics

Nineteen patients (median; age 63 years, 84% female) with RYGB anatomy underwent SS-EDGI with subsequent stent removal. The mean interval from the RYGB surgery to the time of SS-EDGI was 16.3 ± 7.4 years. Access to the excluded stomach was obtained by gastrogastrostomy in 13 patients (68%) and by jejunogastrostomy in six patients (32%). The median procedure time was 55 minutes (range; 38 to 79 minutes). Technical success was achieved in all (100%) cases. AEs occurred in two patients (11%) who had abdominal pain that required hospitalization. There were no instances of intraprocedural stent dislodgment (▶ **Table 1**).

LAMS removal and fistula closure

Patients had a median LAMS dwell time of 32 days. While most patients (89%) had a LAMS dwell time between 4 and 6 weeks, two patients had dwell times of 16 and 86 days due either to personal schedules that interfered with the 4-week time frame for removal or being lost to follow up. There were no instances of stent migration prior to LAMS removal. At the time of LAMS removal, all patients underwent closure of the anastomosis – 10 patients had APC applied to the rim of the fistula prior to TTS tack-based suturing and nine patients had TTS tack-based suturing alone. Eighteen patients (95%) underwent follow-up studies at least 4 weeks after LAMS removal to assess fistula closure; one patient was lost to follow-up. All patients (100%, n = 18) had confirmed fistula closure at the time of their studies. Notably, seven patients had either initial or repeat imaging more than 9 months after LAMS removal demonstrating no fistula. There were no AEs related to LAMS removal or fistula closure. Median follow-up from the time of the first procedure was 31.5 months (▶ **Table 2**).

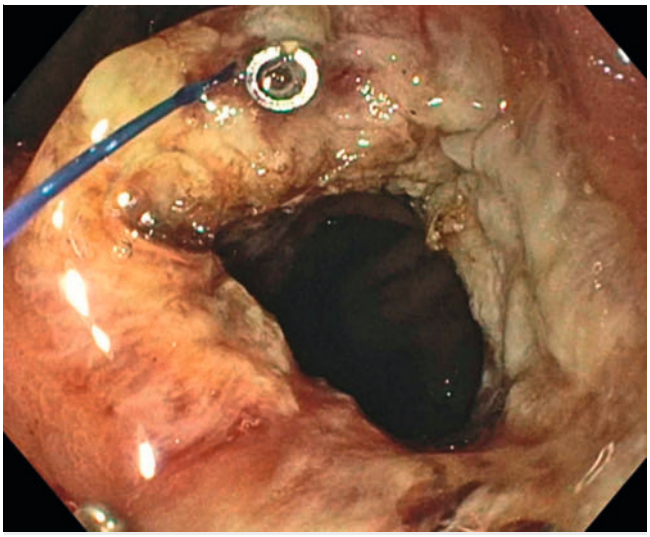

▶ **Fig. 2** Patent gastrogastrostomy anastomosis after LAMS removal with the start of X-tack suturing.

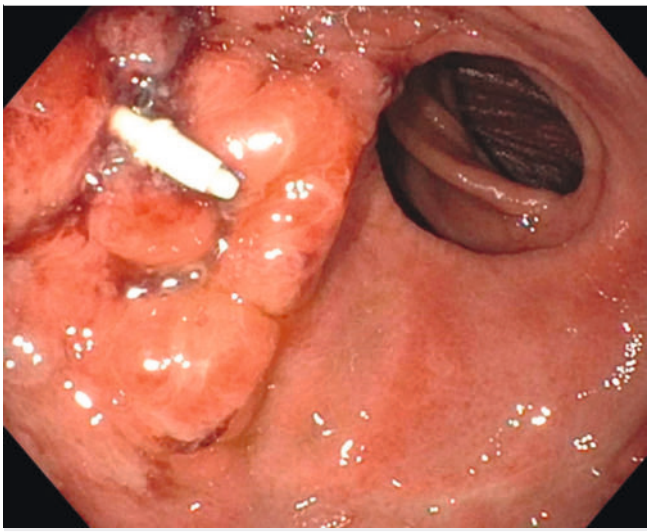

▶ **Fig. 3** Gastrogastrostomy anastomosis sutured closed with X-tack suturing system.

▶ **Table 1** Demographics and EDGI procedure data (n = 19).

Age (years), mean ± SD	63.2 ± 11.2
Gender	
▪ Male	3 (16%)
▪ Female	16 (84%)
ASA: Grade II	8 (42%)
ASA: Grade III	11 (58%)
Time from RYGB to EDGI procedure (years), mean ± SD	16.3 ± 7.4
▪ Median	17.0
▪ Range	1 to 28
Procedure duration (min), mean ± SD	56.8 ± 10.0
▪ Median	55.0
LAMS location	
▪ Gastrogastrostomy	13 (68%)
▪ Jejunogastrostomy	6 (32%)
Technical success, n (%)	19 (100%)
Adverse events, n (%)	
▪ Intra-procedure stent dislodgment	0 (0%)
▪ Pain	2 (10%)
▪ Bleeding	0 (0%)
▪ Infection	0 (0%)
▪ Perforation	0 (0%)
▪ Pancreatitis	0 (0%)

EDGI, endoscopic ultrasound-directed transgastric intervention; ASA, American Society of Anesthesiologists; RYGB, Roux-en-Y gastric bypass; SD, standard deviation; LAMS, lumen-apposing metal stent.

▶ **Table 2** LAMS removal and follow-up data.

LAMS dwell time (days), median (n = 19)	32
Total follow-up after initial EDGI (months), mean ± SD	30.0 ± 21.8
Median	31.5
Spontaneous stent migration prior to LAMS removal	0 (0%)
Post-LAMS removal follow-up study performed* (n = 18)	
▪ No evidence of fistula	18 (100%)
▪ Fistula present	0 (0%)
Weight lost (lb)	
▪ Pre-procedure to time of LAMS removal, mean ± SD (n = 19)	3.3 ± 5.3
▪ Median	2.5
▪ Pre-procedure to time of last follow-up, mean ± SD (n = 19)	5.5 ± 9.2
▪ Median	3.7

* Post-LAMS removal follow-up studies performed include upper endoscopy, upper gastrointestinal series, CT scan with contrast, or MR enterography. LAMS, lumen-apposing metal stent; EDGI, endoscopic ultrasound-directed transgastric intervention; SD, standard deviation; CT, computed tomography; MR, magnetic resonance.

Peri-procedural weight

Peri-procedural weights were available for all patients. At the time of LAMS removal and at last follow-up, 13 patients (68%) had documented weight loss compared with their pre-procedure weight. Average weight change at the time of LAMS removal was a loss of 3.3 ± 5.3 kg (range; gain of 2.7 kg to loss of 15.8 kg). Average weight change at the time of last follow-up was a loss of 5.5 ± 9.2 kg (range; gain of 7.1 kg to loss of 23.6 kg) (▶ **Table 2**).

Discussion

Since its introduction in 2014, EDGI has been increasingly practiced for management of pancreaticobiliary diseases in patients with RYGB anatomy. While dual-session EDGIs have often been considered safer in terms of intraprocedural stent dislodgment, previous studies have suggested that SS-EDGI can be performed safely. In a retrospective cohort study involving nine medical centers, 128 SS-EDGIs were performed and 11 intraprocedural stent dislodgments were reported [8]. Of the dislodgments, none of the stents were sutured in place and 15-mm LAMS were found to have a five times risk ratio of stent dislodgment when compared with 20-mm LAMS ($P = 0.033$). Our institutions have adopted use of 20-mm LAMS and stent suturing as standard practice and have previously validated the efficacy and safety of SS-EDGI. In 2022, we reported a case series of 37 RYGB patients who underwent SS-EDGI with 100% technical success and no episodes of intraprocedural stent dislodgment or delayed stent migration [9]. Our current study further validates these findings because we report 100% technical success with no episodes of stent dislodgment. AEs were minimal and included two patients with abdominal pain requiring hospitalization. Furthermore, patients did not show a trend toward weight gain and, in fact, had a tendency toward weight loss while the LAMS was in place and after stent removal.

While we have demonstrated favorable short-term outcomes of SS-EDGI, long-term outcomes related to persistent fistulae remain a concern. Persistent fistulae pose a risk for potential weight gain and for development of acid-related complications including gastroesophageal reflux disease, marginal ulcers, and bleeding [10, 11, 14]. Our prior study reported a 25% rate of persistent fistulae after stent removal [9]. This finding is consistent with a meta-analysis assessing the safety of EDGE, which included nine studies that reported a pooled fistula closure rate of 17% (95% confidence interval; 9%–27%) [2]. Given these high rates, preventing the development of persistent fistulae is critical. Two recent studies reported on risk factors predictive of persistent fistulae after LAMS removal. Kedia et al re-

ported a multicenter, retrospective, cohort study including 172 patients who underwent EDGE. Of these patients, 62 were evaluated for fistula closure and 19 (31%) were found to have persistent fistulae. The only variable significantly associated with development of persistent fistulae was the total number of days the LAMS was in place (85.5 days vs 0.973 days, $P=0.0044$) [12]. In Ghandour et al's multicenter retrospective case-control study, 25 patients found to have persistent fistulae were compared with 50 patients without evidence of fistulae. A longer LAMS dwell time was similarly found to be a significant predictor of persistent fistulae with an odds ratio of 4.5 ($P=-0.01$) and with a 9.5% increased risk for every additional week the LAMS was left in place. Neither study found that APC or primary closure of the fistulae at the time of stent removal was protective against the development of persistent fistulae. However, it is important to recognize that the studies may have been underpowered to find a statistical significance when comparing the two groups. Furthermore, in both studies, endoscopic closure of the fistulae was left at the discretion of the endoscopist and included different methods (endoscopic suturing, endoscopic tacking, and/or OTSCs) [11, 12]. In Kedia et al's study, endoscopic closure methods were not specified [12]. In contrast, in Ghandour et al.'s study, there was wide variability with seven different combinations of closure mechanisms employed for those who developed persistent fistulae [11].

Because of lack of experience with and lack of standardization of primary endoscopic closure after LAMS removal, our study sought to assess the efficacy of TTS tack-based suturing to prevent persistent fistulae. The TTS tack-based suturing system was introduced in late 2020 for closure of large endoscopic defects, fistula, perforations, and leaks. Although literature regarding its use has been limited, it has been demonstrated as a safe, efficient, and cost-effective tool for closure of defects that have been challenging for traditional endoscopic suturing, TTS clips, and OTSCs [15, 16]. We chose to use TTS tack-based suturing because of its ease of use, particularly in small lumen diameters, and its cost advantage over the OverStitch. Although this initial experience is small, the results have been favorable in demonstrating that primary endoscopic closure of GG and JG anastomoses at the time of LAMS removal is effective, because all 18 of our patients who underwent follow-up imaging had no evidence of fistulae. Notably, seven patients had durable fistula closures because they underwent imaging more than 9 months after LAMS removal without evidence of fistula.

Our study demonstrates promising short-term outcomes for SS-EDGI and prevention of persistent fistulae. However, a few points should be emphasized about our practice. First, we maintain patients on a PPI until fistula closure is confirmed to reduce the risk of acid-related AEs. Second, we instruct patients to adhere to a post-RYGB diet while the LAMS remains in place and even after LAMS removal – progressing gradually from a liquid diet for the first few days after LAMS removal followed by 2 weeks of six small meals a day to minimize stretching the gastric pouch, which theoretically allows for improved chances of fistula closure. This likely accounts for our experience of patients losing weight both during LAMS dwell time and after stent removal, because it reinforces a post-RYGB diet that patients might have stopped complying with prior to EDGI. Lastly, we recommend follow-up studies 1 month and 1 year after LAMS removal to ensure durability of the fistula closure. In our study, because some initial procedures occurred around the time of the COVID pandemic and because, as tertiary referral centers, it was harder to maintain close contact, there were challenges in follow-up. However, we ultimately were able to obtain follow-up studies in most patients.

There were several limitations to our study. First, as a retrospective study, it is inherently prone to confounding and bias. In addition, APC was used at the discretion of the endoscopist and was not studied separately. Future prospective studies comparing TTS tack-based suturing alone versus with APC can be helpful in delineating the best method of primary endoscopic closure. Moreover, because endoscopic closure of chronic fistulae is historically challenging with suboptimal outcomes, further studies are needed to evaluate the efficacy of TTS tack-based suturing for fistula closure. In terms of follow-up, although seven patients had repeat imaging studies more than 9 months after LAMS removal, more longitudinal data are needed to confirm long-term durability of fistula closure. Lastly, our sample size was small (n = 19) and procedures were performed at high-volume tertiary referral centers with experienced endoscopists. Further larger studies will be needed to validate the generalizability of our results to community practice.

Conclusions

SS-EDGI is safe and effective for managing pancreaticobiliary diseases in patients with RYGB anatomy. Short-term risk of stent dislodgment may be mitigated with use of a larger 20-mm LAMS and by suturing the stent in place. In addition, short-term LAMS placement is not associated with risk of weight gain, because it can potentially be reduced by encouraging adherence to a post-RYGB diet. Lastly, long-term AEs associated with persistent fistulae can be mitigated with primary endoscopic closure of the GG and JG anastomosis with TTS tack-based suturing at the time of LAMS removal. Larger studies will be needed to validate these findings.

Conflict of Interest

Mouen Khashab: Boston Scientific (consultant), Olympus (Consultant), Medtronic (Consultant), Pentax (Consultant), GI Supply (Consultant), UpToDate (Receives royalties), Elsevier (Receives royalties) Shayan Irani: Boston Scientific (consultant), ConMed (consultant), GORE (consultant) The remaining authors have no conflict of interest to declare.

References

[1] Kedia P, Sharaiha RZ, Kumta NA et al. Internal EUS-directed transgastric ERCP (EDGE): game over. Gastroenterology 2014; 147: 566–568 doi:10.1053/j.gastro.2014.05.045

[2] Deliwala SS, Mohan BP, Yarra P et al. Efficacy & safety of EUS-directed transgastric endoscopic retrograde cholangiopancreatography (EDGE) in Roux-en-Y gastric bypass anatomy: a systematic review &

meta-analysis. Surg Endosc 2023; 37: 4144–4158 doi:10.1007/s00464-023-09926-7

[3] Prakash S, Elmunzer BJ, Forster EM et al. Endoscopic ultrasound- directed transgastric ERCP (EDGE): a systematic review describing the outcomes, adverse events, and knowledge gaps. Endoscopy 2022; 54: 52–61 doi:10.1055/a-1376-2394

[4] James HJ, James TW, Wheeler SB et al. Cost-effectiveness of endoscopic ultrasound-directed transgastric ERCP compared with device-assisted and laparoscopic-assisted ERCP in patients with Roux-en-Y anatomy. Endoscopy 2019; 51: 1051–1058

[5] Wang TJ, Cortes P, Jirapinyo P et al. A comparison of clinical outcomes and cost utility among laparoscopy, enteroscopy, and temporary gastric access-assisted ERCP in patients with Roux-en-Y gastric bypass anatomy. Surg Endosc 2021; 35: 4469–4477

[6] Krafft MR, Hsueh W, James TW et al. The EDGI new take on EDGE: EUS-directed transgastric intervention (EDGI), other than ERCP, for Roux-en-Y gastric bypass anatomy: a multicenter study. Endosc Int Open 2019; 7: E1231–E1240

[7] Podboy A, Nissen NN, Lo SK. Single-session EUS-directed transgastric endoscopic retrograde cholangiopancreatography (EDGE) and EUS-guided gallbladder drainage is safe and feasible. VideoGIE 2021; 6: 509–511 doi:10.1016/j.vgie.2021.08.005

[8] Shinn B, Boortalary T, Raijman I et al. Maximizing success in single-session EUS-directed transgastric ERCP: a retrospective cohort study to identify predictive factors of stent migration. Gastrointest Endosc 2021; 94: 727–732 doi:10.1016/j.gie.2021.04.022

[9] Keane MG, Higa JT, La Selva D et al. Suturing a 20-mm lumen-apposing metal stent allows for safe same-session EUS-directed transgastric intervention in patients with Roux-en-Y gastric bypass anatomy: a multicenter study (with video). Gastrointest Endosc 2022; 97: 291–299

[10] Krafft MR, Lorenze A, Croglio MP et al. „Innocent as a LAMS“: Does spontaneous fistula closure (secondary intention), after EUS-directed transgastric ERCP (EDGE) via 20-mm lumen-apposing metal stent, confer an increased risk of persistent fistula and unintentional weight gain? Digest Dis Sci 2021; 67: 2337–2346

[11] Ghandour B, Keane MG, Shinn B et al. Factors predictive of persistent fistulas in EUS-directed transgastric ERCP: a multicenter matched case-control study. Gastrointest Endosc 2022; 97: 260–267 doi:10.1016/j.gie.2022.09.028

[12] Kedia P, Shah-Khan S, Tyberg A et al. Endoscopic ultrasound-directed transgastric ERCP (EDGE): A multicenter US study on long-term follow-up and fistula closure. Endosc Int Open 2023; 11: E529–E537 doi:10.1055/a-2057-5984

[13] Cotton PB, Eisen GM, Aabakken L et al. A lexicon for endoscopic adverse events: report of an ASGE workshop. Gastrointest Endosc 2009; 71: 446–454 doi:10.1016/j.gie.2009.10.027

[14] Ichkhanian Y, Runge T, Jovani M et al. Management of adverse events of EUS-directed transgastric ERCP procedure. VideoGIE 2020; 5: 260–263 doi:10.1016/j.vgie.2020.02.005

[15] Mahmoud T, Wong Kee Song LM, Stavropoulos SN et al. Initial multicenter experience using a novel endoscopic tack and suture system for challenging GI defect closure and stent fixation (with video). Gastrointest Endosc 2021; 95: 373–382

[16] Zhang LY, Bejjani M, Ghandour B et al. Endoscopic through-the-scope suturing. VideoGIE 2021; 7: 46–51