JOURNAL OF NEUROSURGERY:
Case Lessons

J Neurosurg Case Lessons 5(19): CASE2381, 2023
DOI: 10.3171/CASE2381

Trigeminal neuralgia caused by a persistent primitive trigeminal artery: preoperative three-dimensional multifusion imaging and computational fluid dynamics analysis. Illustrative case

Toru Satoh, MD, PhD,[1] Takao Yasuhara, MD, PhD,[2] Michiari Umakoshi, MD, PhD,[2] and Isao Date, MD, PhD[3]

[1]Department of Neurological Surgery, Ryofukai Satoh Neurosurgical Hospital, Hiroshima, Japan; [2]Department of Neurological Surgery, Okayama University Postgraduate Medical School, Okayama, Japan; and [3]Okayama Rosai Hospital, Okayama, Japan

BACKGROUND Trigeminal neuralgia (TN) is caused by trigeminal nerve compression by colliding vessels. Preoperative three-dimensional (3D) multifusion images are useful for surgical simulations. Moreover, computational fluid dynamics (CFD) analysis of colliding vessels may be useful for hemodynamic evaluation at the site of neurovascular contact (NVC).

OBSERVATIONS A 71-year-old woman had TN due to compression of the trigeminal nerve by the superior cerebellar artery (SCA) fused with the persistent primitive trigeminal artery (PTA). Preoperative 3D multifusion simulation images of silent magnetic resonance (MR) angiography and MR cisternography depicted the NVC, including the trigeminal nerve, SCA, and PTA. CFD analysis revealed the hemodynamic condition of the NVC, including the SCA and PTA. The wall shear stress magnitude (WSSm) at the NVC showed a local elevation due to flow confluence from the SCA and PTA. High WSSm was observed in the NVC.

LESSONS Preoperative simulation images of MR angiography and MR cisternography may depict the NVC. CFD analysis can provide the hemodynamic condition at the NVC.

https://thejns.org/doi/abs/10.3171/CASE2381

KEYWORDS computational fluid dynamics; neurovascular contact; persistent primitive trigeminal artery; trigeminal neuralgia; wall shear stress

Trigeminal neuralgia (TN) is mainly caused by compression of the trigeminal nerve by blood vessels at the site of neurovascular contact (NVC).[1] However, the detailed mechanism of its onset is unknown. The superior cerebellar artery (SCA), anterior inferior cerebellar artery, and basilar artery and veins are responsible for this condition. TN caused by the persistent primitive trigeminal artery (PTA) and its variants is extremely rare, accounting for 0.2%–0.6% of TN cases.[2,3] Herein, we describe a case of TN in which the PTA trunk was fused with the SCA, compressing the trigeminal nerve. The PTA fused with the SCA has not been previously reported, nor has it caused TN. Preoperative three-dimensional (3D) multifusion simulation images were created using silent magnetic resonance (MR) angiography and MR cisternography. Furthermore, a computational fluid dynamics (CFD) analysis of PTA and SCA was performed for hemodynamic evaluation.

Illustrative Case

A 71-year-old woman presented with severe left lower jaw pain for the past 6 months. She was treated with carbamazepine, which was ineffective. Neuroimaging was performed using silent MR angiography and MR cisternography. Preoperative 3D multifusion simulation images[4,5] revealed that the SCA had fused with the PTA, compressing the trigeminal nerve (Fig. 1A). While under general anesthesia, the patient was placed in the left lateral decubitus position, and microvascular decompression (MVD) was performed with continuous monitoring of the auditory brainstem response. Surgical findings revealed that the SCA was in contact with the trigeminal nerve and strongly compressed the nerve adjacent to the site where the PTA merged (Fig. 1B). The PTA was transpositioned to the pyramidal dura mater with TachoSil Tissue Sealing sheet (CSL Behring K.K.) (Fig. 1C).[6] The SCA was transpositioned

ABBREVIATIONS CFD = computational fluid dynamics; MR = magnetic resonance; MVD = microvascular decompression; NVC = neurovascular contact; PTA = persistent primitive trigeminal artery; SCA = superior cerebellar artery; TN = trigeminal neuralgia; WSS = wall shear stress; WSSm = magnitude of WSS.

INCLUDE WHEN CITING Published May 8, 2023; DOI: 10.3171/CASE2381.
SUBMITTED February 10, 2023. **ACCEPTED** April 4, 2023.
© 2023 The authors, CC BY-NC-ND 4.0 (http://creativecommons.org/licenses/by-nc-nd/4.0/)

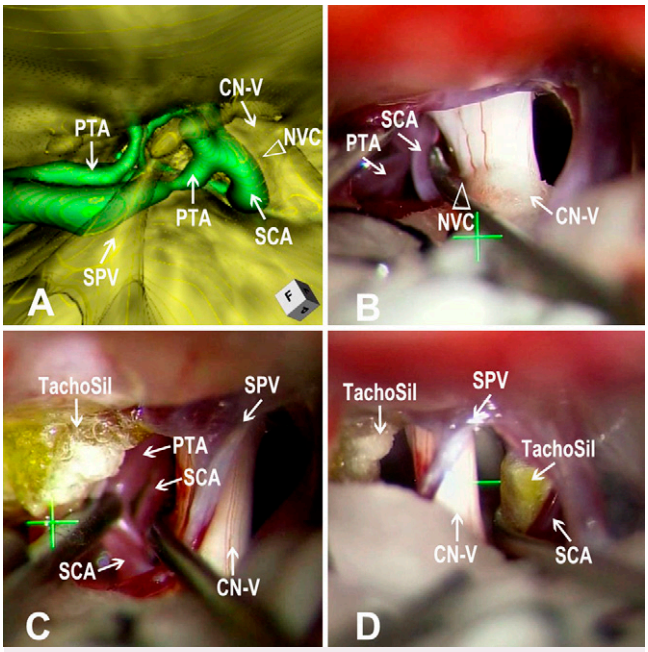

FIG. 1. Preoperative simulation image and operative photographs. **A:** 3D multifusion image of silent MR angiography and MR cisternography showing the running course of the PTA joined with the SCA and compression of the trigeminal nerve at the NVC. **B:** Operative photograph showing the NVC by the SCA fused with the PTA. **C:** Operative photograph showing PTA transposition to the pyramidal dura mater with the TachoSil. **D:** Operative photograph showing the transpositioned SCA attached to the arachnoid surrounding the vein with the TachoSil. CN-V = cranial nerve V; SPV = superior petrosal vein.

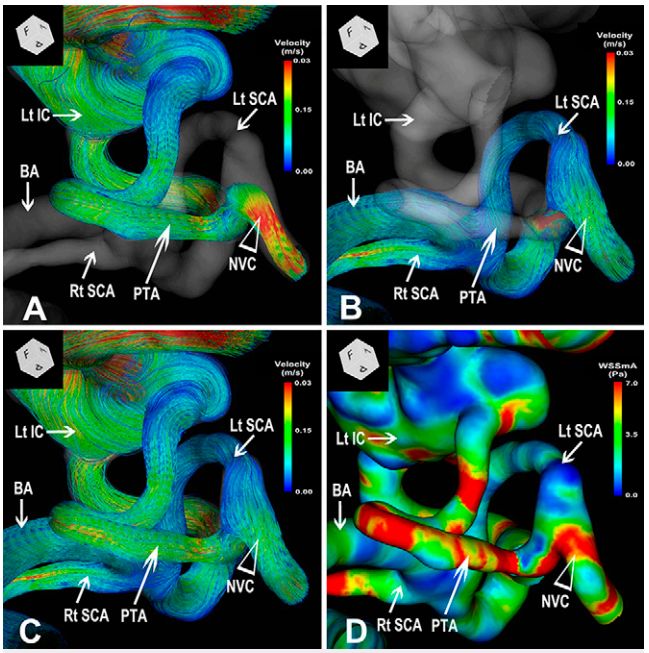

FIG. 2. CFD analysis of the PTA and SCA. **A:** Streamlines originating from the internal carotid artery (IC) system showing a relatively high-flow velocity from the PTA through the confluence to the SCA, beyond the NVC. The *arrowhead* indicates the SCA at the NVC, depicting the high-flow velocity in the red zone. Arrows indicate CN-V = cranial nerve V; SPV = superior petrosal vein. **B:** Streamlines originating from the basilar artery (BA) system showing a relatively low-velocity flow through the SCA merged with the PTA. The *arrowhead* indicates the SCA at the NVC, depicting the relatively low-velocity flow of the green zone. **C:** Streamlines originating from both the IC and BA systems showing flow through the PTA and SCA. The *arrowhead* indicates the SCA in the NVC. **D:** The average of WSSm (WSSmA) showing areas of high WSSm beyond the NVC. The *arrowhead* indicates the SCA in the NVC, depicting a red-to-yellow zone.

and attached to the arachnoid surrounding the vein with TachoSil (Fig. 1D), and the nerve was completely freed (Video 1). Immediately postoperatively, her neuralgia was completely relieved, with no recurrence for 3 years.

VIDEO 1. Clip showing the TachoSil technique for transposition of offending vessels. Click here to view.

CFD analysis of the PTA and SCA was performed at the NVC site. Streamlines originating from the internal carotid artery system showed a relatively high-flow velocity flowing from the PTA through the confluence to the SCA, beyond the NVC (Fig. 2A). Conversely, the basilar artery system showed slower flow, and the SCA merged with the PTA (Fig. 2B). Streamlines originating from both the internal carotid and basilar artery systems depicted flow through the PTA and SCA (Fig. 2C). The NVC site coincided with the area where the flow from the SCA and PTA merged, and the flow in this area showed strong acceleration due to the confluence of the flows. Consequently, the magnitude of wall shear stress (WSS) increased locally. In the present case, high wall shear stress magnitude (WSSm) was observed at the NVC on the SCA immediately after confluence (Fig. 2D).

Discussion

Observations

In terms of the running configuration, three types of PTA are known.[2,3] The typical type of PTA branches from the cavernous sinus of the internal carotid artery, pierces the dura mater of the clivus or via Meckel's cave, reaches the posterior fossa, and connects with the basilar artery. A PTA variant perfuses the cerebellum directly without communicating with the basilar artery. Additionally, an intermediate type of PTA communicates with the basilar artery and perfuses the cerebellar cortical arteries.

The present case involved an aneurysmal bulge immediately after the branching of the cavernous sinus of the left internal carotid artery, extending from Meckel's cave to the posterior cranial fossa, and branching small arteries to the cerebellar cortex. It merges with the main trunk of the SCA, which normally branches from the basilar artery. Preoperative 3D multifusion simulation images depict the running course of the PTA and SCA with the trigeminal nerve. To our knowledge, this is the first report of a PTA fused directly with an SCA that normally branched from the basilar artery. Additionally, the SCA and PTA complex colliding with the trigeminal nerve and causing TN has not been reported.

Recently, CFD analyses have demonstrated the hemodynamic features of the responsible colliding vessels at the NVC.[7–9] CFD has several parameters, among which WSS is the most commonly used. WSS is the frictional force acting on the vascular wall in the tangential direction of the flow. The WSS has both the strength and

vector directions of the WSS. WSSm expresses the intensity of WSS (Pa), which varies depending on the flow rate. The flow velocity increased up to the constricted part of the blood vessels. WSSm increases owing to accelerated flow before constriction. However, after the constricted part, WSSm decreased. At the curvature of the blood vessels, eccentricity of the flow added to the above phenomena. WSSm increased in the outer bay, and conversely, WSSm decreased in the inner bay.

The strength of the flow acting tangential to the lumen wall is represented by the WSSm. WSSm depends on the flow velocity inside the lumen related to blood flow. A trigeminal nerve that is strongly compressed by the colliding artery at the NVC site undergoes morphological change such as depression and flattening. In the NVC, both nerve and artery have a limited range of motion and the blood vessel may present possible hemodynamic features of constriction associated with oppression and immobility.[7] The flow velocity is accelerated up to the constricted part of the vessel, and WSSm is increased. As a result, the high WSSm area in the constricted blood vessel is considered to be the area of the NVC. By hemodynamic analysis of the colliding artery, we can estimate the compression part at the NVC from the velocity and density of the blood flow.

In the present case, comparing the NVC determined by simulated 3D multifusion images and operative photographs, WSS at the NVC was analyzed by the corresponding CFD images. The anterograde SCA branched from the basilar artery, ran in parallel with the trigeminal nerve, and merged with the PTA. In the SCA immediately after the confluence, fast and dense streamlines with increased WSSm were observed on the outer wall of the SCA, especially on the outer side of the wall due to eccentric flow of the outer bay, where it contacted the trigeminal nerve. Surgical findings confirmed that the trigeminal nerve was compressed at this part of the SCA immediately after the confluence. Specific hemodynamics were exhibited in the colliding SCA at the NVC due to the confluence of the PTA and SCA. High WSSm was observed in the SCA beyond the NVC.

Lessons

Preoperatively, 3D multifusion simulation images can depict anatomical structures of the NVC, comprising the trigeminal nerve, colliding SCA, and merged PTA. In addition to the morphological evaluation of the NVC, CFD analysis may reveal the hemodynamic condition of the colliding artery at the NVC and may help therapeutic strategies of MVD for TN.

Acknowledgments

We thank Ms. Megumi Sasaki and Mr. Yudai Abe, radiological technicians, and Ms. Kana Murakami, laboratory technologist at Ryofukai Satoh Neurosurgical Hospital, for conducting the MR examinations. We thank Editage for English-language editing.

References

1. Jannetta PJ. Observations on the etiology of trigeminal neuralgia, hemifacial spasm, acoustic nerve dysfunction and glossopharyngeal neuralgia. Definitive microsurgical treatment and results in 117 patients. *Neurochirurgia (Stuttg).* 1977;20(5):145–154.
2. Morita A, Fukushima T, Miyazaki S, Shimizu T, Atsuchi M. Tic douloureux caused by primitive trigeminal artery or its variant. *J Neurosurg.* 1989;70(3):415–419.
3. Yamaguchi D, Asayama B, Noro S, Seo Y, Honjo K, Nakamura H. Trigeminal neuralgia associated with primitive trigeminal artery intermediate type: case report. *Jpn J Neurosurg.* 2022;31: 524–529.
4. Satoh T, Onoda K, Date I. Fusion imaging of three-dimensional magnetic resonance cisternograms and angiograms for the assessment of microvascular decompression in patients with hemifacial spasms. *J Neurosurg.* 2007;106(1):82–89.
5. Satoh T, Onoda K, Date I. Preoperative simulation for microvascular decompression in patients with idiopathic trigeminal neuralgia: visualization with three-dimensional magnetic resonance cisternogram and angiogram fusion imaging. *Neurosurgery.* 2007;60(1): 104–114.
6. Ichikawa T, Agari T, Kurozumi K, Msruo T, Satoh T, Date I. "Double-stick tape'' technique for transposition of an offending vessel in microvascular decompression: technical case report. *Neurosurgery.* 2011;68(Suppl 2):onsE377–onsE382.
7. Satoh T, Yagi T, Onoda K, et al. Hemodynamic features of offending vessels at neurovascular contact in patients with trigeminal neuralgia and hemifacial spasm. *J Neurosurg.* 2018;130:1–7.
8. Yamada K, Tanaka Y, Sumita K, Nemoto S, Maehara T. Computational fluid dynamics analysis of the offending artery at sites of neurovascular compression in trigeminal neuralgia using preoperative MRI data. *Neurol Med Chir (Tokyo).* 2019;59(11):415–422.
9. Tominaga K, Endo H, Sugiyama SI, Osawa SI, Niizuma K, Tominaga T. Computational hemodynamic analysis of the offending vertebral artery at the site of neurovascular contact in a case of hemifacial spasm associated with subclavian steal syndrome: illustrative case. *J Neurosurg Case Lessons*. 2021;2(12):1–4.

Disclosures

The authors report no conflict of interest concerning the materials or methods used in this study or the findings specified in this paper.

Author Contributions

Conception and design: Satoh. Acquisition of data: Satoh, Umakoshi, Date. Analysis and interpretation of data: Satoh, Date. Drafting of the article: Satoh. Critically revising the article: Satoh, Date. Reviewed submitted version of the manuscript: Satoh, Yasuhara, Date. Approved the final version of the manuscript on behalf of all authors: Satoh. Statistical analysis: Satoh. Administrative/technical/material support: Satoh. Study supervision: Date.

Supplemental Information

Video

Video 1. https://vimeo.com/816223403.

Correspondence

Toru Satoh: Ryofukai Satoh Neurosurgical Hospital, Fukuyama-City, Hiroshima, Japan. ucsfbtrc@urban.ne.jp.