

[CASE REPORT]

Autoimmune Pulmonary Alveolar Proteinosis during the Treatment of Idiopathic Inflammatory Myopathy

Naoki Shijubou^{1,2}, Takeyuki Sawai^{1,2}, Taku Hatakeyama^{1,2}, Satoru Munakata³,
Masami Yamazoe¹ and Hirofumi Chiba²

Abstract:

Approximately 50% of idiopathic inflammatory myopathies (IIMs) are associated with interstitial lung disease (ILD). Typically, IIM-ILD manifests as nonspecific interstitial pneumonia. We herein report a rare case of a 78-year-old man with autoimmune pulmonary alveolar proteinosis (PAP) that developed during IIM treatment. The diagnosis of autoimmune PAP was based on detecting anti-granulocyte-macrophage colony-stimulating factor antibodies. We postulated that PAP may have been induced by IIM treatment with prednisolone. Our case suggests that the possibility of autoimmune PAP should be considered in patients with lung lesions during the clinical course of IIM.

Key words: autoimmune pulmonary alveolar proteinosis, idiopathic inflammatory myopathies, anti-macrophage colony-stimulating factor antibodies

(Intern Med 62: 445-448, 2023)

(DOI: 10.2169/internalmedicine.9558-22)

Introduction

Pulmonary alveolar proteinosis (PAP) is a rare disease characterized by the accumulation of pulmonary surfactants, consisting of proteins and phospholipids, in the alveoli. It is caused by alveolar macrophage dysfunction, which impairs gas exchange (1).

Approximately 90% of PAPs are autoimmune-mediated (2), with the remaining 10% attributed to conditions secondary to hematological diseases, toxic inhalation, or hereditary causes. These hereditary causes may result from genetic mutations in surfactant proteins or granulocyte-macrophage colony-stimulating factor (GM-CSF) receptors.

Anti-GM-CSF antibodies are found in patients with autoimmune PAP and have been shown to inhibit GM-CSF signaling (1). This results in dysfunctional alveolar macrophages, as well as the accumulation of lung surfactants in the alveoli. Although autoimmune PAP is associated with presence of autoantibodies, it has only been rarely linked to other autoimmune diseases (1.7% of cases) (3).

Idiopathic inflammatory myopathy (IIM), commonly re-

ferred to as myositis, is a heterogeneous group of diseases that are clinically characterized by chronic muscle weakness and inflammatory cell infiltration in muscle tissue (4). IIM is also often complicated by disorders of the skin, lung, heart, joints, and gastrointestinal tract. Approximately 50% of patients with IIM have interstitial lung diseases (ILDs) (5). IIM-ILD is classified based on pathohistological findings and/or its clinical course (5). It typically manifests as nonspecific interstitial pneumonia (NSIP) that is usually chronic and progressive. Since IIM-ILD can be fatal, prompt administration of appropriate treatment is critical.

We herein report a rare case of IIM-ILD that presented as an autoimmune PAP, as opposed to NSIP, in which progressive dyspnea on exertion was observed during the treatment of IIM.

Case Report

In December 2020, a 78-year-old man became aware of pain in both upper arms and had difficulty raising them. In January 2021, he visited his local physician and was referred to the Department of Neurology at our hospital with

¹Department of Respiratory Medicine, Hakodate Municipal Hospital, Japan, ²Department of Respiratory Medicine and Allergology, Sapporo Medical University School of Medicine, Japan and ³Department of Pathology, Hakodate Municipal Hospital, Japan

Received: February 9, 2022; Accepted: June 6, 2022; Advance Publication by J-STAGE: July 14, 2022

Correspondence to Dr. Naoki Shijubou, shjibou.1229@gmail.com

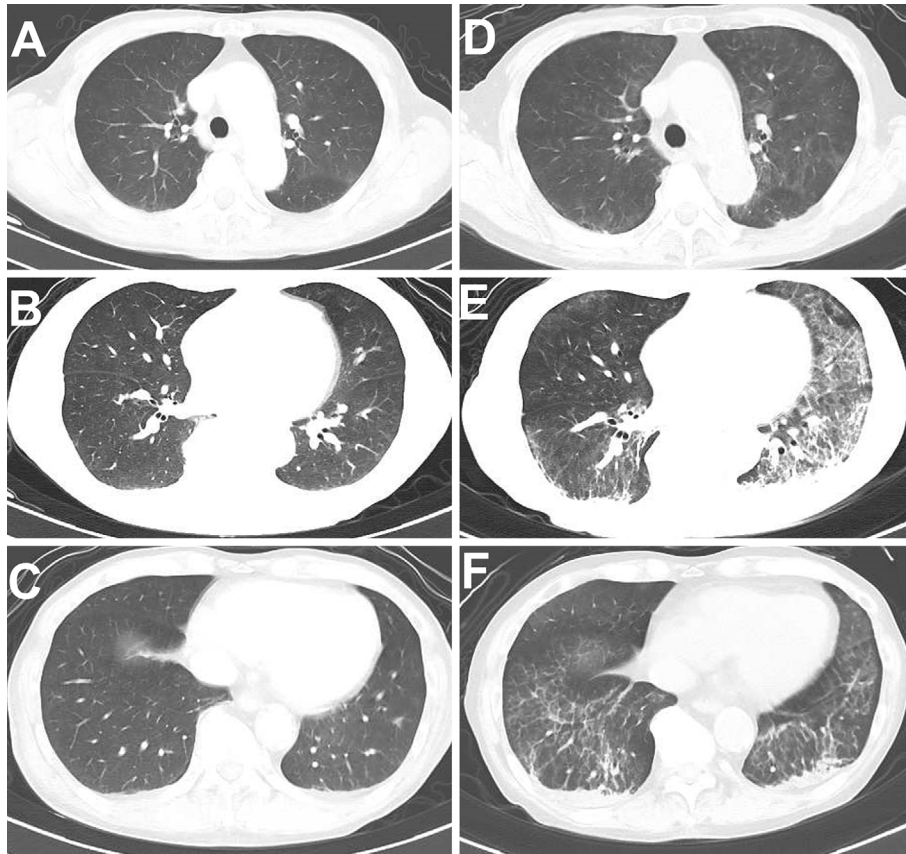


Figure 1. (A-C) Chest CT image obtained at the time of the idiopathic inflammatory myopathy diagnosis (January 2021). (D-F) Chest CT image obtained on admission (September 2021). CT: computed tomography

suspected myositis. At the time of his visit to our neurology department, he had a facial rash, myalgia, edema, and proximal predominant muscle weakness in the extremities. No pulmonary lesions were observed (Fig. 1A). He was diagnosed with IIM (definite, subgroup: dermatomyositis) based on the following clinical and laboratory findings: heliotrope rash; proximal muscle weakness; and elevated serum levels of creatine kinase, lactate dehydrogenase, aspartate aminotransferase, and alanine aminotransferase. However, autoantibodies related to IIMs, such as anti-melanoma differentiation-associated gene 5 antibody and anti-aminoacyl-tRNA synthetase (ARS) antibody, were negative.

His signs and symptoms improved after the administration of methylprednisolone pulse therapy (1,000 mg/day for 3 days), high-dose immunoglobulin therapy (5,000 mg/day for 5 days), and tacrolimus therapy (2 mg/day). After completion of methylprednisolone pulse therapy, the dose of prednisolone was initially reduced to 30 mg/day, followed by a further reduction of 5 mg/day for 2 weeks. Once the dose was reduced to 10 mg/day, it was subsequently gradually reduced by 1 mg/day every month. The dose of tacrolimus was adjusted based on its whole-blood concentration (5-10 ng/mL).

In August 2021, the patient was evaluated by a neurologist. The patient's IIM symptoms were assessed as stable with the administration of prednisolone (8 mg/day) and

tacrolimus (2 mg/day). However, he experienced dyspnea on exertion for 2 weeks in September 2021 and was subsequently referred to our department for chest radiography, which showed decreased permeability of the bilateral lower lung fields. He had a smoking history of 400 pack-years. However, he had no history of dust exposure or gas inhalation.

Chest computed tomography showed infiltrative and frosted shadows in the bilateral lower lobes. Therefore, the patient was admitted to the hospital for a further evaluation (Fig. 1B). No abnormalities were noted during auscultation of the lungs.

Blood test results showed elevated levels of lactate dehydrogenase (322 U/L), Krebs von den Lungen-6 (3,170 U/mL), surfactant protein A (576 ng/mL), and surfactant protein D (219 ng/mL). Antinuclear antibody levels were elevated 80-fold. However, other collagen-related autoantibodies (myeloperoxidase-anti-neutrophil cytoplasmic antibody, proteinase-3-anti-neutrophil cytoplasmic antibody, anti-Sjögren's syndrome A and B antibodies, anti-scleroderma antibody, anti-ARS antibody) were negative. An arterial blood gas analysis showed a PaO₂ of 73 mmHg on room air. Pulmonary function tests could not be performed due to dyspnea.

Bronchoalveolar lavage (BAL) was performed for the left B4 bronchus on the day of admission. Saline (150 mL) was

injected, and the BAL fluid recovery rate was 33% with a milky appearance (Fig. 2). The lymphocyte ratio was increased. Furthermore, the following cell fractions were observed: histiocytes (68.4%), neutrophils (8.4%), lymphocytes (22.8%), and eosinophils (0.4%). Bacterial cultures of the BAL fluid were negative. A cytological examination showed periodic acid-Schiff stain-positive granular and structureless material, with no signs of malignancy (Fig. 3). An enzyme-linked immunosorbent assay indicated that the patient's serum was positive for anti-GM-CSF antibodies [20 µg/mL, normal range <1.7 µg/mL; measured by SRL (Headquarters: Shinjuku Mitsui Building 2-1-1 Nishishinjuku, Shinjuku-ku, Tokyo 163-0409)].

Given the above, the patient was diagnosed with autoimmune PAP, as opposed to NSIP. He was subsequently followed up with a decreasing dose of prednisolone (reduced by 1 mg every month). No worsening of PAP (prednisolone 5 mg daily) was observed at the last follow-up in December 2021.

The patient provided his written informed consent for the publication of these findings.

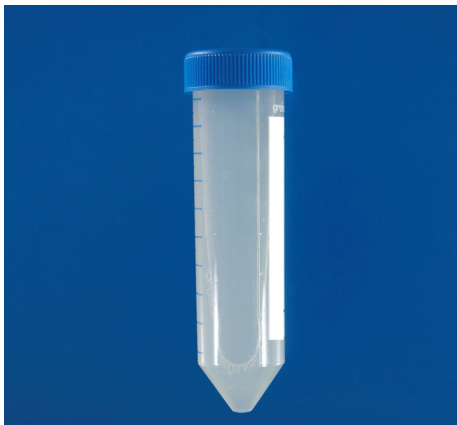

Figure 2. Image showing the “milky” appearance of the bronchoalveolar lavage fluid performed for the left B4 bronchus.

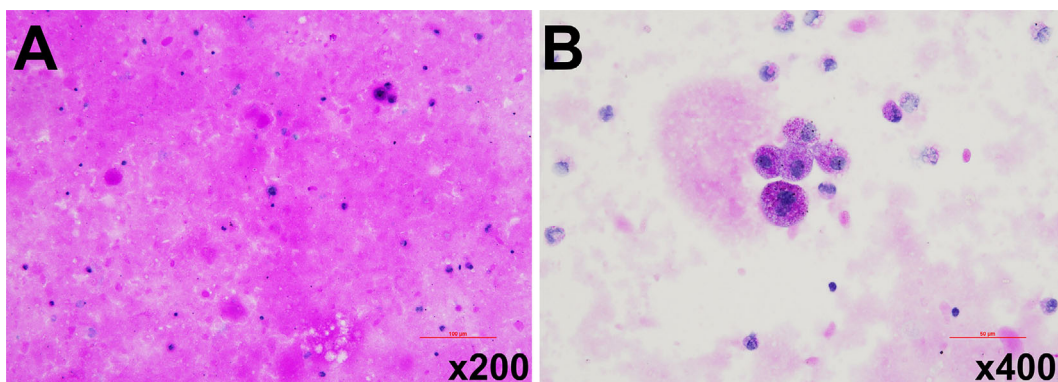


Figure 3. A cytological examination of the bronchoalveolar lavage fluid. (A) Granular material with strong positive periodic acid-Schiff staining (the magnification used is 200×, scale bar 100 µm). (B) Foamy macrophages (periodic acid-Schiff staining, the magnification used is 400×, scale bar 50 µm).

Discussion

We encountered a case of autoimmune PAP that developed during IIM treatment. Since autoimmune PAP can be exacerbated by increasing steroid doses, its treatment differs from that of NSIP. The possibility of autoimmune PAP should be considered in lung lesions that develop during the clinical course of IIM.

Approximately, 50% of patients with IIM develop ILD (5). IIM-ILD typically manifests as NSIP, for which the main treatment is a combination of glucocorticoids (GC) and immunosuppressive agents. If NSIP develops or is exacerbated during combination therapy with GC and calcineurin inhibitors, the dose of GC is increased, or additional immunosuppressive agents are considered (6). A misdiagnosis of IIM-ILD as NSIP in the present case would have led us to increase the dose of GC. This would have resulted in PAP exacerbation via increased phospholipid production and a decreased monocyte function (7). In a study of GC administration in patients with autoimmune PAP, GC administration increased the severity of autoimmune PAP and risk of infection (8).

Anti-GM-CSF antibodies are considered the dominant factor in PAP pathogenesis (3). Previous studies have indicated that the pathophysiology of secondary PAP (without anti-GM-CSF antibodies) may be related to decreases in the number of alveolar macrophages or an impaired alveolar macrophage function (3, 9). PAP in the present case may have been due not only to the presence of anti-GM-CSF antibodies but also to increased phospholipid production (due to IIM treatment with prednisolone) and an impaired monocyte function (7).

If IIM-ILD manifests as PAP and the patient's condition progressively worsens, the dose of prednisolone should be reduced. A previous randomized controlled trial conducted among patients with refractory IIM reported that prednisolone doses could be reduced after rituximab treatment; similar results were observed in abatacept (10). Rituximab and

abatacept may be considered as alternative treatment options when prednisolone dose reduction is needed. Rituximab therapy for autoimmune PAP has been reported to be well tolerated, safe, and effective, and might be considered as an effective treatment of autoimmune PAP, not only when prednisolone dose reduction is necessary (11).

Despite the rarity of the association between autoimmune PAP and other autoimmune diseases, the present case demonstrates that prednisolone administration for the treatment of other autoimmune diseases may lead to PAP development.

The authors state that they have no Conflict of Interest (COI).

References

1. Trapnell BC, Nakata K, Bonella F, et al. Pulmonary alveolar proteinosis. *Nat Rev Dis Primers* **5**: 16, 2019.
2. Jouneau S, Ménard C, Lederlin M. Pulmonary alveolar proteinosis. *Respirology* **25**: 816-826, 2020.
3. Borie R, Danel C, Debray MP, et al. Pulmonary alveolar proteinosis. *Eur Respir Rev* **20**: 98-107, 2011.
4. Lundberg IE, Miller FW, Tjärnlund A, Bottai M. Diagnosis and classification of idiopathic inflammatory myopathies. *J Intern Med* **280**: 39-51, 2016.
5. Kawasumi H, Gono T, Kawaguchi Y, Yamanaka H. Recent treatment of interstitial lung disease with idiopathic inflammatory myopathies. *Clin Med Insights Circ Respir Pulm Med* **9**: 9-17, 2015.
6. Lega JC, Reynaud Q, Belot A, Fabien N, Durieu I, Cottin V. Idiopathic inflammatory myopathies and the lung. *Eur Respir Rev* **24**: 216-238, 2015.
7. Cordonnier C, Fleury-Feith J, Escudier E, Atassi K, Bernaudin JF. Secondary alveolar proteinosis is a reversible cause of respiratory failure in leukemic patients. *Am J Respir Crit Care Med* **149**: 788-794, 1994.
8. Akasaka K, Tanaka T, Kitamura N, et al. Outcome of corticosteroid administration in autoimmune pulmonary alveolar proteinosis: a retrospective cohort study. *BMC Pulm Med* **15**: 88, 2015.
9. Dirksen U, Hattenhorst U, Schneider P, et al. Defective expression of granulocyte-macrophage colony-stimulating factor/interleukin-3/interleukin-5 receptor common beta chain in children with acute myeloid leukemia associated with respiratory failure. *Blood* **92**: 1097-1103, 1998.
10. Sasaki H, Kohsaka H. Current diagnosis and treatment of polymyositis and dermatomyositis. *Mod Rheumatol* **28**: 913-921, 2018.
11. Kavuru MS, Malur A, Marshall I, et al. An open-label trial of rituximab therapy in pulmonary alveolar proteinosis. *Eur Respir J* **38**: 1361-1367, 2011.

The Internal Medicine is an Open Access journal distributed under the Creative Commons Attribution-NonCommercial-NoDerivatives 4.0 International License. To view the details of this license, please visit (<https://creativecommons.org/licenses/by-nc-nd/4.0/>).