



The Protective Effects of Citrulline on Testicular Injury Induced by Torsion and Detorsion in Adult Male Rats: An Experimental Study

Vida Motamed Nia ^{1†}, Nastaran Rezaei ^{1†}, Mohammad Shokati Sayyad ¹, Mohammad Seyedabadi ¹, Fereshteh Talebpour Amiri ², Fatemeh Shaki ^{1*}

1- Department of Toxicology and Pharmacology, Faculty of Pharmacy, Mazandaran University of Medical Sciences, Sari, Iran

2- Department of Anatomy, Faculty of Medicine, Molecular and Cell Biology Research Center, Mazandaran University of Medical Sciences, Sari, Iran

† The first and the second authors have had equal contribution to this manuscript

Abstract

Background: Testicular torsion is a critical urological emergency that can lead to testicular ischemia and significant tissue damage. Citrulline, a supplement known for enhancing cellular metabolism and mitigating oxidative stress and inflammation, has been explored for its protective effects against testicular injury resulting from torsion and detorsion in rat models.

Methods: This study involved 42 Wistar rats, divided into six groups: Sham, torsion/detorsion (T/D), and four groups receiving varying doses of Citrulline (300, 600, 900 mg/kg) and vitamin E (20 mg/kg). A surgical procedure was performed to induce torsion by rotating the left testicle for 4 hr, followed by reperfusion. Daily oral administration of the supplements continued for one week post-surgery. Assessments included oxidative stress markers, apoptosis, inflammation, pathology, and sperm parameters. Statistical analysis was conducted using GraphPad Prism.

Results: Citrulline administration at doses of 600 and 900 mg/kg significantly reduced malondialdehyde (MDA) and reactive oxygen species (ROS) levels. Additionally, it increased glutathione (GSH) levels and decreased protein carbonyl levels at the 900 mg/kg dose. The expression of interleukin-6 (IL-6) decreased at 900 mg/kg, tumor necrosis factor-alpha (TNF- α) levels dropped at 600 and 900 mg/kg, and the pro-apoptotic factor Bax was reduced at all doses. Sperm analysis showed improved sperm count and motility at the 900 mg/kg dose. Histological examination revealed significant positive effects of Citrulline on testicular tissue.

Conclusion: Citrulline effectively lowers oxidative stress, inflammation, while enhancing sperm quality and pathological outcomes. These results indicate that Citrulline has potential as a therapeutic agent for testicular torsion.

Keywords: Citrulline, Inflammation, Torsion, Oxidative stress, Testis.

To cite this article: Motamed Nia V, Rezaei N, Shokati Sayyad M, Seyedabadi M, Talebpour Amiri F, Shaki F. The Protective Effects of Citrulline on Testicular Injury Induced By Torsion and Detorsion in Adult Male Rats: An Experimental Study. *J Reprod Infertil.* 2024; 25(3):201-210. <https://doi.org/10.18502/jri.v25i3.17014>.

* Corresponding Author:
Fatemeh Shaki, Department
of Toxicology and
Pharmacology, Faculty of
Pharmacy, Mazandaran
University of Medical
Sciences, Sari, Iran
E-mail:
fshaki.tox@gmail.com

Received: 5, Mar. 2024
Accepted: 18, May 2024

Introduction

Male infertility accounts for 30% of cases of couples' infertility, making it a global public health concern. The causes of male infertility can be multifactorial, involving several factors that may occur independently or in combination, often as part of complex syndromes (1). The tes-

ticular torsion is a urological syndrome primarily caused by twisting of the spermatic cord (2). It is a condition that primarily affects young men, mainly occurring before or during puberty, and is also detected in young adults. The estimated annual incidence is 4.5 cases per 100,000 men (3).

The primary pathophysiological event in testicular torsion is ischemia, followed by reperfusion. Therefore, torsion and detorsion of the testis is an ischemia/reperfusion injury (IRI) to the testis. The torsion and detorsion of the testis cause morphological and biochemical changes in tissues. This damage is associated with excessive production of ROS and reactive nitrogen species (RNS), which is a common mechanism of injury in other organs, such as the brain, heart, and kidneys (1).

Testicular torsion leads to production of pro-inflammatory cytokines, neutrophil adhesion, lipid peroxidation, anoxia, and apoptosis, which pose a significant risk for subsequent infertility (4). Testicular torsion causes a long-term decrease in sperm motility and a decrease in the total number of sperm. The decrease in the quality of semen may be caused by ischemic damage and subsequent reperfusion injury (5, 6). Excessive production of ROS after torsion and detorsion of the testis can damage testicular spermatogenesis by reducing TRF2 expression (7). Unilateral testicular torsion culminates in a significant increase in the level of malondialdehyde, increased apoptosis, and a significant decrease in the activity of superoxide dismutase and glutathione peroxidase in the testes (8). Biochemical analysis has shown that IR injury following testicular torsion significantly decreases testicular glutathione peroxidase (GPx) enzyme activity, serum testosterone level, while testicular myeloperoxidase activity (MPO) has increased (9). During the torsion stage, the activities of glutathione-s-transferase (GST), catalase (CAT), and paraoxonase (PON) of kidney tissue were significantly elevated (10). The most common signs and symptoms of this condition include redness, swelling of the testicle, extreme testicular pain, nausea, and vomiting (11, 12). Several important factors have been indicated in the prevention of testicular injury after ischemia-reperfusion. A wide range of chemicals and drugs have been successfully tested in animal models to reduce the dangerous effects of ischemia-reperfusion on testicular torsion (13). The use of natural compounds may protect against harmful oxidative stress and inflammatory responses (14). Citrulline is a non-essential amino acid that is produced from ornithine and carbamoyl phosphate in one of the central reactions in the urea cycle. It is used as a dietary supplement and is claimed to increase energy levels and improve the immune system. Citrulline has been prescribed for a long time in the treatment of genetic disorders of the urea cycle. Re-

cent studies show that Citrulline may be useful for controlling nitric oxide (NO) production. Recent studies have shown that citrulline can serve as a potentially useful marker for small intestine function in a wide range of pathologies (15, 16). Citrulline improves cellular metabolic activity, reduces ROS production, limits lipid peroxidation, and reduces cell death as well as interleukin-8 secretion. Likewise, it reduces levels of inflammatory markers of TNF- α and TLR4 and increases the expression of claudin-1 protein (17, 18). Given the prevalence of testicular torsion, the pathophysiological role of ischemia-reperfusion, and the involvement of oxidative stress, inflammation, and apoptosis in this condition, the current study investigated the effect of Citrulline on testicular tissue toxicity caused by testicular torsion/detorsion in rats.

Methods

Animals: This study was conducted in 2023 at Mazandaran University of Medical Sciences. In this study, Wistar albino adult male rats aged 9-10 weeks and weighing 200-225 g were included. The rats were housed under standard conditions in a room with a 12-hr dark-light cycle, temperature of $22\pm 2^{\circ}\text{C}$, and free access to food and water. The study was conducted using a total of 42 adult male rats, divided into 6 groups, each comprising 7 animals:

Group 1: Sham (neutral control): Surgical incision was performed, but torsion was not induced, and no medication was given.

Group 2: Torsion/detorsion (T/D): The torsion model was induced, but no medication was given.

Group 3: T/D +300 Citrulline: The torsion model was induced, and animals received 300 mg/kg of Citrulline, orally after the surgery.

Group 4: T/D +600 Citrulline: The torsion model was induced and animals received 600 mg/kg of Citrulline, orally after surgery.

Group 5: T/D +900 Citrulline: The torsion model was induced and animals received 900 mg/kg of Citrulline, orally after the surgery.

Group 6: Positive control: The torsion model was induced and animals received 20 mg/kg of Vitamin E after the surgery.

The selection of doses was done based on previous studies investigating the effects of Citrulline in animals.

Surgical procedure: The animals were first anesthetized with ketamine at a dose of 87 mg/kg and xylazine at a dose of 13 mg/kg intraperitoneally

under sterile conditions. The abdominal area was first disinfected with a 10% povidone-iodine solution. The animals then underwent testicular torsion/detorsion surgery under complete anesthesia. A vertical incision of approximately 3 cm was made in the tunica albuginea area along the midline of the genital region. The left testicle was then released from the epididymo-testicular intermembrane space and gently removed by applying slight pressure on the sides of the testicle. To induce ischemia, the left testicle was rotated 720 degrees counterclockwise along the inguinal canal and placed back inside the scrotum. The testicle was then loosely sutured with 0.4 silk thread until it remained in an ischemia state for 4 hr. In the reperfusion stage, the sutures were opened, and the testicle was twisted back in the opposite direction to its original position. The testicle was then placed back inside the scrotum in its normal anatomical position, and the gubernaculum was sutured. During the ischemic period, the tissue was examined every ten minutes to monitor rotation status. Immediately after the surgery, drugs were administered daily via oral gavage for one week (19). In the Sham group, only the abdominal cavity was opened and then closed. In other groups, the right testicle was also removed at the same time.

Sperm analysis: After separating the end part of the epididymis and placing it in a Petri dish containing 1 ml of RPMI 1640 culture medium, the epididymis was cut into small pieces. The Petri dish was then placed in an incubator at 37°C for 10 min to allow the sperm to fully dissociate from the epididymal tubules and enter the culture medium. Next, the evaluation of various sperm parameters including the count, motility, and morphology was done (20, 21). To investigate the sperm motility, the liquid obtained from the epididymis was diluted with 2 ml Tris buffer and placed on a neobar slide. The motionless sperm were counted, then the sample was fixed, and sperm motility was examined according to the following formula:

$$\text{Sperm motility} = (\text{Total number of sperm} - \text{number of immotile sperm}) \times 100$$

To examine sperm morphology, the number of abnormally shaped sperm was counted among 300 cells on each slide, and the results were expressed as a percentage. Sperm were divided into 5 groups based on their appearance, which are as follows: (1) normal, (2) no tail, (3) abnormal head with

normal tail, (4) abnormal tail with normal head, and (5) abnormal morphology with both head and tail defects (20).

To determine the number of sperm, Yokoi et al.'s method was applied. In this way, the obtained sample was diluted and the number of sperm was counted in four large squares and finally, the number of them was reported as $\times 10^6 \text{ ml}$ (21). For the pathological examination of the testicular tissue, the samples taken from the tissue were kept in Bouin fixative solution, in dehydrated alcohol and in paraffin. For quantitative and qualitative evaluation of testicular tissue, a histopathological was performed (22, 23). The histopathological findings were evaluated by considering the status of spermatogenic cells in the seminiferous tubule epithelium (24).

Gene expression: After anesthetizing the animals, 300 mg of testicular tissue was washed with manitol serum and placed inside microtubes containing RNA Shield solution and was kept in a freezer at -80°C until RNA extraction. RNA extraction from the tissues was performed using the column RNA extraction kit (Denazist Co, Iran). The extracted RNA samples were used for cDNA synthesis, and this process was done with the help of a specific cDNA synthesis kit (Pars Tous Biotech, Iran). Using the reverse transcriptase enzyme, cDNA was synthesized from the mRNA of the desired gene according to the kit protocol, and all steps of cDNA synthesis were performed on ice.

Real time-PCR: The primers for the studied genes (TNF- α , IL-6, Bcl2, Bax, β -actin) were designed using the Primer-Blast tool on the NCBI website and were purchased from Pishgam Company, Iran. The sequence of these primers can be seen in table 1. The β -actin gene was used as a reference. In this study, after reaching the suitable binding temperature of the desired primers, quantitative determination of target gene expression was performed using RealQ Plus 2x Master mix green (Zist Virayesh, Iran) and Rotor-gene 6000 (Qia-gene, Germany). In this study, the changes in gene expression were evaluated relative to the expression of β -actin gene. Gene expression was measured by calculating ΔCT , $\Delta\Delta\text{CT}$, and finally plotting the results as $2^{-\Delta\Delta\text{CT}}$ to determine gene expression changes across the samples.

Glutathione levels: One milliliter of testicle tissue homogenate was taken, and 0.25 ml of 20% trichloroacetic acid was added to it. After vortexing,

Table 1. Temperature program and primers used for investigating inflammation and apoptosis using real time-PCR

Genes	Primer	Thermal condition
TNF- α	F: TCAGCCTCTTCTCATTCTGCT R: GCCATTGAACTGATGAGAGGGA	95°C, 5 min 40 cycles (95°C, 20 s; 63°C, 20 s; 72°C, 20 s) 72°C, 5 min
IL-6	F: TATACCACTTCACAAGTCGGAGG R: GAATTGCCATTGCACAACTCTTT	95°C, 5 min 40 cycles (95°C, 20 s; 63°C, 20 s; 72°C, 20 s) 72°C, 5 min
Bcl2	F: CTGTGGATGACTGAGTACCTGA R: AGCCAGGAGAAATCAAACAGAGG	95°C, 5 min 40 cycles (95°C, 20 s; 63°C, 20 s; 72°C, 20 s) 72°C, 5 min
Bax	F: CCAAGAAGCTGAGCGAGTGT R: TGTCCAGCCCATGATGGTTC	95°C, 5 min 40 cycles (95°C, 20 s; 63°C, 20 s; 72°C, 20 s) 72°C, 5 min
β -actin	F: TTCTACAATGAGCTGCGTGTGG R: GGTGTTGAAGGTCTCAAACATGA	Tubes were incubated under the same thermal condition as the genes of interest

the mixture was centrifuged at 1000 \times g for 20 min. Then, 1 ml of the clear supernatant solution was taken and 2 ml of 0.3 M disodium hydrogen phosphate and 0.3 ml of 0.4% DTNB were added. After vortexing, the mixture was incubated for 15 min until the reaction was complete. Finally, the absorbance rate was read at a wavelength of 412 nm (25).

ROS levels: ROS level was measured using DCFH-DA reagent. After determining the protein content, 20 μ l of DCFH-DA were added to 2000 microliters of the sample and was kept at 4°C for 15 min. Next, the fluorescence intensity was measured using a fluorimeter device, with an excitation wavelength of 485 and an emission wavelength of 525 nm (26).

Protein carbonyl levels: The amount of protein carbonyl was measured using a 4,4-dinitrophenylhydrazine (DNPH) reagent. After determination of the protein content, 500 μ l of trichloroacetic acid (20% w/v) were added to 250 μ l of the sample and were kept at 4°C for 15 min. Then, the precipitated proteins were centrifuged at 6500 \times g for 10 min and the supernatant solution was discarded. The bottom sediment was completely dispersed in 500 μ l of 0.1 M NaOH and 500 microliters of 10 mM DNPH dissolved in 2 M HCl was added to the samples. Then, the samples were incubated for 30 min at room temperature and away from light. After that, 500 μ l of 20% (w/v) trichloroacetic acid was added. The protein precipitate was collected by centrifugation at 6500 \times g for 10 min and the supernatant was discarded. The bottom sediment was mixed with 1 ml of a 1:1 (v/v) solution of ethanol and ethyl acetate, and then

centrifuged again at 6500 \times g for 10 min to discard the supernatant. The final protein precipitate was dispersed in 200 μ l of 6 M guanidine hydrochloride solution. The amount of protein carbonyl was evaluated by reading the absorbance rate at 365 nm with an absorption coefficient of 22,000 M⁻¹cm⁻¹ which was expressed as nmol of DNPH per mg of protein (27).

Lipid peroxidation levels: The level of MDA, an index of lipid peroxidation, was measured using the thiobarbituric acid reactive substance (TBARS) test. In short, the process involved adding 0.2 ml of testicular suspension, 200 μ l of phosphoric acid, and 25 μ l of TBA reagent, and then mixing well. This mixture was then incubated in a water bath at 95°C for 30 min. After cooling, 0.45 ml of n-butanol was added, and the solution was centrifuged. The supernatant solution was separated for measurement at 532 nm wavelength, and the amount of TBARS was calculated using a standard curve.

Statistical analysis: The statistical data obtained from this research was reported as mean \pm standard deviation and was evaluated by Prism version 8 using one-way analysis of variance. Moreover, Tukey's post-hoc test was used to compare the differences between groups and the significance level was defined as $p < 0.05$.

Ethical considerations: Male Wistar rat weighing between 200-225 gr were obtained from the Laboratory of Animals Researches Center at Mazandaran University of Medical Sciences in Sari, Iran. The ethical protocols established by the Committee of Animal Experimentation of Mazandaran University of Medical Sciences were

followed throughout the experiment with an ethical code of IR.MAZUMS.AEC.1402.056. The rats were housed in an environment maintained at $22\pm 2^{\circ}\text{C}$, with access to proper food and water and a 12:12 hr light cycle. The minimum number of rats required for testing was used, and proper anesthesia procedures were ensured during any experimentally painful procedures.

Results

In examining the sperm count across the studied groups, the sperm count in the T/D group was significantly lower compared to the Sham group ($p<0.001$). Among the treatment groups, a gradual increase in sperm count was observed. In the group treated with of 900 mg/kg of Citrulline, this increase in sperm count was significant compared to T/D group ($p>0.05$). Also, in the examination of the percentage of sperm motility among the studied groups, a significant decrease in motility was observed in the T/D group compared to the Sham ($p<0.001$). Among the treatment groups, a gradual increase in sperm motility was observed. In the group treated with 900 mg/kg of Citrulline, this increase was significant compared to T/D group ($p<0.01$). The use of Citrulline at the dose of 900 mg/kg was the most effective in increasing both sperm count and sperm motility (Table 2).

Finally, in the examination of the percentage of sperm morphology, a significant increase in abnormal morphology was observed in the T/D group compared to the Sham group ($p<0.01$). Among the treatment groups, despite the decrease observed in the percentage of abnormal sperm morphology, this decrease was not statistically significant (Table 2).

As demonstrated in table 2, in the T/D group, a significant decrease in the level of glutathione was observed compared to the Sham group ($p<0.001$). In the Citrulline treatment group, the decrease in abnormal sperm morphology was only significant at the 900 mg/kg dose ($p<0.01$). The increase was not significant in other groups. The amount of ROS in the T/D group was significantly increased compared to the Sham group ($p<0.001$). However, a significant decrease in ROS levels was observed in the 900 mg/kg and 600 mg/kg Citrulline treatment groups ($p<0.001$) compared to the T/D group. A significant decrease in ROS was also observed in the vitamin E group ($p<0.01$). As shown in table 2, there was a significant increase in the levels of MDA and protein carbonyl in the T/D group, compared to the Sham group ($p<0.001$). A gradual decrease in these markers was observed in the treatment groups. The decrease was significant in the 600 mg/kg Citrulline group for MDA ($p<0.05$) and in the 900 mg/kg Citrulline group for both MDA ($p<0.001$) and protein carbonyl ($p<0.001$). In the positive control group (vitamin E), there was a significant decrease in these markers compared to the T/D group ($p<0.01$).

Figure 1 shows the histopathological findings of testicular tissue in all groups. In the Sham group, the thickness of the epithelium was completely normal and the primary and secondary spermatogenic cells (spermatocytes and spermatids) were in normal condition. The lumen of the seminiferous tubule was small and abundant with spermatozoa. In the group that underwent torsion/detorsion surgery, the thickness of the epithelium was completely decreased. The dissociation between

Table 2. The effect of T/D and Citrulline on sperm analysis and oxidative stress parameters

	Sham	T/D	T/D+Cit300	T/D+Cit600	T/D+Cit900	T/D+vitE
Sperm count ($10^6/ml$)	69.67 \pm 3.2	37.67 \pm 4.16 **	42.33 \pm 6.1	50.67 \pm 2.5	55.33 \pm 4.5 ^s	45.33 \pm 8
Motility (%)	80.67 \pm 7	58 \pm 2.64 **	61 \pm 2	70 \pm 4.58	76.67 \pm 4.2 ^{ss}	63.67 \pm 5
Abnormal morphology (%)	18.67 \pm 2	36.33 \pm 4.2 *	35.6 \pm 6.5	30.13 \pm 4.8	24.67 \pm 2.5	29.67 \pm 5.6
Ros (fluorescence intensity)	18.35 \pm 2.8	70.12 \pm 8 **	56.39 \pm 16	37.14 \pm 4.8 ^{sss}	29.9 \pm 7.2 ^{sss}	51.83 \pm 10.1 ^{ss}
Protein carbonyl (mM)	0.4 \pm 0.11	0.98 \pm 0.17 **	0.96 \pm 0.15	0.84 \pm 0.04	0.59 \pm 0.08 ^{ss}	0.67 \pm 0.07 ^{ss}
MDA (μM)	4.66 \pm 1.6	20.66 \pm 1.2 **	18.58 \pm 1.18	16.43 \pm 2.7 ^s	9.42 \pm 0.44 ^{sss}	15.17 \pm 4.2 ^{ss}
GSH (μM)	81.59 \pm 13.5	32.2 \pm 7.2 **	40.52 \pm 13.5	54.82 \pm 20.8	69.34 \pm 13.4 ^{ss}	47.5 \pm 13.55

Sperm analysis and oxidative stress factors including ROS, protein carbonyl, MDA, and GSH were evaluated in the following groups: Sham, torsion/detorsion (T/D), torsion/detorsion with different doses of Citrulline (T/D+Cit), and torsion/detorsion plus vitamin E (T/D+vitE). Data are expressed as mean \pm SD

* Significantly different from Sham group ($p<0.01$)

** Significantly different from Sham group ($p<0.01$)

^s Significantly different from T/D group ($p<0.05$)

^{ss} Significantly different from T/D group ($p<0.01$)

^{sss} Significantly different from T/D group ($p<0.001$)

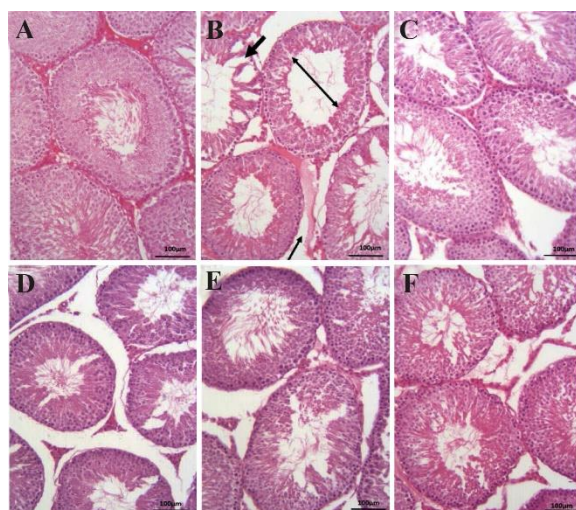


Figure 1. H&E-stained histology of testis showing (A) Sham group, (B) torsion/detorsion (T/D) group, (C) vitamin E group (20 mg/kg), (D) torsion/detorsion (T/D) group with a therapeutic dose of 300 mg/kg (T/D+Cit300), (E) torsion/detorsion (T/D) group with a therapeutic dose of 600 mg/kg (T/D+Cit600), and (F) torsion/detorsion (T/D) group with a therapeutic dose of 900 mg/kg (T/D+Cit900). Thick black arrow: loss of integrity; Thin black arrow: edema - increased distance between seminiferous tubules; Black double-headed arrow: diameter of seminiferous tubule. Magnification: 20x and scale bar: 100 μ m

the epithelial cells was observed in some of the seminiferous tubules. Edema was also evident among the seminiferous tubules. The administration of Citrulline at doses of 300 mg/kg, 600 mg/kg, and 900 mg/kg had a healing effect on the tissue damage caused by torsion/detorsion in the testes. However, this healing effect was completely evident at the dose of 900 mg/kg of Citrulline. The healing effect of vitamin E on the damage

caused by torsion/detorsion was also observed in histopathological findings.

As shown in table 3, the investigation of TNF- α , IL-6, and Bax gene expression among the studied groups revealed a significant increase in the inflammatory cytokines TNF- α , IL-6, and Bax gene expression in the T/D group compared to the Sham group ($p < 0.01$). Among the treatment groups, there was a significant decrease in TNF- α inflammatory gene expression in the patient group treated with two doses of 600 and 900 mg/kg of Citrulline, compared to the T/D group ($p < 0.01$). For IL-6, the decrease was significant only with a dose of 900 mg/kg ($p < 0.05$). The Bax gene expression showed a significant decrease in the vitamin E group and with 300, 600, and 900 mg/kg doses of Citrulline, compared to the T/D group. However, the increase in Bcl2 factor in the T/D group was not statistically significant when compared to the Sham group.

Discussion

The testicular torsion is a medical emergency that necessitates prompt diagnosis and intervention. Currently, surgery is the only available treatment and should be done as soon as possible. Despite successful surgery, loss of spermatogenesis and a significant increase in basal cell apoptosis may occur due to increased testicular oxidative stress with reperfusion. Reperfusion injury, caused by the production of toxic free radicals, can be prevented by the use of antioxidants, such as Citrulline, which has been shown to protect against lipid peroxidation and lipoprotein oxidation in circulation and reduce protein carbonylation in muscles and the brain (28). The most sig-

Table 3. The effect of T/D and Citrulline on expression of inflammatory and apoptosis factors in testicular tissue of male rats

	Sham	T/D	T/D+Cit300	T/D+Cit600	T/D+cit900	T/D+vitE
IL 6	1.22 \pm 0.71	14.77 \pm 2.36 *	15.28 \pm 1.6	8.79 \pm 4.2	4.9 \pm 3.3 \$	8.22 \pm 3.8
TNF- α	1.13 \pm 0.23	8.37 \pm 2.8 *	6.74 \pm 1.2	1.44 \pm 1 \$\$	1.51 \pm 0.78 \$\$	4.72 \pm 2.7
Bax	1.05 \pm 0.25	7.7 \pm 2.2 **	2.76 \pm 1.35 \$\$	1.54 \pm 0.22 \$\$\$	1.54 \pm 0.3 \$\$\$	2.6 \pm 0.74 \$\$
Bcl2	1 \pm 0.04	1.38 \pm 0.66	1.77 \pm 0.9	3.88 \pm 2.3	2.43 \pm 0.76	2.34 \pm 1.1

Gene expression of inflammatory factors (TNF- α and IL-6) and apoptosis factors (BAX and Bcl2) were evaluated in the following groups: Sham, T/D, T/D with different doses of Citrulline (T/D+Cit), and T/D plus vitE (T/D+vitE). Data are expressed as mean \pm SD

* Significantly different from Sham group ($p < 0.01$)

** Significantly different from Sham group ($p < 0.01$)

\$ Significantly different from T/D group ($p < 0.05$)

\$\$ Significantly different from T/D group ($p < 0.01$)

\$\$\$ Significantly different from T/D group ($p < 0.001$)

nificant outcome of testicular torsion/detorsion is the increase of ROS levels inside the testicular tissue. ROS is continuously produced in oxidation-reduction reactions within the cell, primarily in the mitochondria during cellular respiration (16).

ROS is composed of free radicals and peroxide, which are highly reactive molecules containing one or more free electrons. These radicals can attack vital macromolecules such as proteins, DNA, and cell membranes, leading to oxidative damage and toxicity in different tissues (29). Malondialdehydes are considered one of the main markers of membrane lipid oxidation, which were also evaluated in the present study (30). The use of antioxidants, particularly glutathione, plays a crucial role in neutralizing free radicals and preventing oxidative damage to the body's macromolecules (31). However, excessive production of free radicals can lead to depletion of cell glutathione reserves and induce damage to body tissues. Studies have shown that Citrulline, an antioxidant, can increase superoxide dismutase (SOD) activities and decrease MDA and NO levels. In the present study, testicular torsion/detorsion in adult male rats increased oxidative stress, lipid peroxidation, and decreased antioxidant activity, which were likely caused by the increase in ROS levels in the testicular tissue. The results of this study demonstrate the protective effects of Citrulline on testicular damage caused by torsion/detorsion in rats (32). Moreover, significant findings regarding the impact of testicular torsion/detorsion on oxidative stress, lipid peroxidation, and antioxidant activity in adult male rats were obtained in the current study. The study indicated that these detrimental effects following testicular torsion/detorsion were likely attributed to the increase of ROS in the testicular tissue. Notably, a study by Liu et al. in 2013 demonstrated that oral administration of L-citrulline at varying doses significantly decreased blood urea nitrogen (BUN), creatinine, MDA, and increased SOD and GSH levels compared to the control group (33). Furthermore, a study conducted by Zhou et al. in 2018 highlighted the ability of Citrulline to enhance the antioxidant capacity of the heart while reducing the level of MDA, indicating its potential protective effects against oxidative damage (34).

In the present study, after the induction of torsion/detorsion, a notable decrease in the serum concentration of GSH enzymes and an increase in the serum levels of MDA, protein carbonyl, and

ROS were observed. Research has shown that the extent and duration of torsion and detorsion significantly impact the damage to testicular tissue, leading to excessive production of active oxygen and oxidative stress (35). This oxidative stress can result in irreversible degenerative responses, apoptosis, or necrosis in living cells. Mitochondria play a crucial role in initiating the intrinsic pathway of apoptosis in cells, with the production of ROS activating the mitochondrial pathway of apoptosis (36). The balance between pro-apoptotic and anti-apoptotic factors, such as Bcl2 and Bax proteins, regulates the process of cell apoptosis (37). Notably, Citrulline has shown promise in protecting against cell death induced by pyroptosis and apoptosis through the Nrf2 signaling pathway, as demonstrated in a study by Xue et al. in 2022 (38). Additionally, recent study in 2023 has highlighted the potential of L-citrulline to increase the Bcl2 factor in serum, acting as an anti-apoptotic agent (39). The study conducted by Doğan and İpek in 2020 demonstrated that Ganoderma, an antioxidant, reduced MDA levels and increased Bcl2 in testicular torsion/detorsion syndrome, leading to apoptotic effects (40). Additionally, vitamin E has been shown to inhibit antioxidant potential, prevent oxidative damage on testes and epididymides, and restore sperm motility (41). In the present study, the group receiving vitamin E exhibited decreased oxidative stress by reducing oxidant factors including MDA, PC, and ROS, while increasing antioxidant factors of GSH. Morphological observations of testicular tissue in the torsion/detorsion group revealed degenerated or degenerating germ cells in the germinal epithelium, separation of germ cells from the basement membrane, edema, and congestion of blood vessels in the interstitial tissue. However, there was no significant presence of inflammatory cells. In the torsion/detorsion group, the number of cells and the diameter of seminiferous tubules were significantly decreased. In contrast, groups treated with Citrulline showed improved morphology compared to the control group. These improvements included the presence of intact germ cell lines, such as spermatogonia, primary and secondary spermatocytes, and round spermatids. Higher doses of Citrulline resulted in significant increases in sperm count and sperm motility. The study by Zhang et al. shown that testicular torsion can lead to testicular damage and changes in semen quality and sperm count (42).

Studies have reported low sperm count and poor sperm viability in more than 50% of patients with testicular torsion, as well as unusual changes in sperm morphology and decreased sperm count in 15 to 66% of patients with unilateral testicular torsion (43-46). One study showed that IL-6 expression has increased after testicular torsion, whereas IL-10 expression has decreased (47, 48). In addition, two other studies have shown that oral administration of Citrulline can reduce the expression of the TNF- α gene and help to attenuate inflammation and intestinal damage (49, 50).

The results of the present study demonstrated the protective effects of Citrulline on testicular tissue. These included reducing damage to testicular tissue, increasing sperm count, increasing sperm motility, improving sperm morphology, and reducing the expression level of inflammatory genes. The use of 900 mg/kg Citrulline dose improved damage caused by the disease and had a positive effect on seminiferous tubules, reducing destruction due to oxidative stress. The study also showed an increase in the number of sperm in groups receiving Citrulline compared to the T/D group, indicating the positive effect of Citrulline in improving sperm count after testicular torsion. The protective effect of Citrulline includes reducing the expression level of IL-6 and TNF- α inflammatory genes, with higher doses showing more improvement. Citrulline supplementation has been reported to improve serum levels of TNF- α , indicating a possible reduction in inflammation.

Conclusion

The study in rats demonstrated that Citrulline administration mitigated the negative effects of torsion/detorsion on testicular tissue by reducing oxidative stress and inflammation. Increasing Citrulline doses notably improved sperm count, motility, and seminiferous tubule quality. The study concluded that a 900 mg/kg dose of Citrulline was the most effective in reducing oxidative stress and ameliorating the damage caused by testicular torsion/detorsion. These findings suggest that Citrulline has the potential to protect against testicular damage by enhancing antioxidant defenses and reducing inflammation. Future research could explore optimal dosing of Citrulline in humans, investigate its interactions with other treatments, and delve into the mechanisms by which Citrulline improves sperm motility and reduces oxida-

tive stress, in order to develop novel therapeutic strategies for the treatment of testicular torsion.

Acknowledgement

The data provided in this study were extracted from a part of MSc thesis of Nastaran Rezaei and Vida Motamed Nia and supported by a grant from the research council of Mazandaran University of Medical Sciences, Sari, Iran.

Conflict of Interest

The authors declare no conflicts of interest.

References

1. Magalhães JA, Ribeiro LS, Rego JPA, de Andrade CR. Current markers for infertility in men. *JBRA Assist Reprod.* 2021;25(4):592-600.
2. Dokmeci D. Testicular torsion, oxidative stress and the role of antioxidant therapy. *Folia Med (Plovdiv).* 2006;48(3-4):16-21.
3. Tavasli B, Köseoğlu H, Çevik H. Segmental ischemia in testicular torsion. *Proc (Bayl Univ Med Cent).* 2016;29(1):59-9.
4. Shimizu S, Tsounapi P, Dimitriadis F, Higashi Y, Shimizu T, Saito M. Testicular torsion-detorsion and potential therapeutic treatments: a possible role for ischemic postconditioning. *Int J Urol.* 2016;23(6):454-63.
5. Jacobsen FM, Rudlang TM, Fode M, Østergren PB, Sønksen J, Ohl DA, et al. The impact of testicular torsion on testicular function. *World J Mens Health.* 2020;38(3):298-307.
6. Fouad AA, Qutub HO, Jresat I. Dose-dependent protective effect of baicalin against testicular torsion-detorsion in rats. *Andrologia.* 2017;49(1).
7. Wei SM, Yan ZZ, Zhou J. Involvement of reactive oxygen species and TATA box-binding protein-related factor 2 in testicular torsion/detorsion-induced injury. *Urology.* 2013;81(2):466.e9-14.
8. Meštrović J, Drmić-Hofman I, Pogorelić Z, Vilović K, Šupe-Domić D, Šešelja-Perišin A, et al. Beneficial effect of nifedipine on testicular torsion-detorsion injury in rats. *Urology.* 2014;84(5):1194-8.
9. Mohamed DI, Abou-Bakr DA, Ezzat SF, El-Kareem HFA, Nahas HHA, Saad HA, et al. Vitamin D3 prevents the deleterious effects of testicular torsion on testis by targeting miRNA-145 and ADAM17: in silico and in vivo study. *Pharmaceuticals (Basel).* 2021;14(12):1222.
10. Ozdemirkan A, Kurtipek AC, Kucuk A, Ozdemir C, Yesil S, Sezen SC, et al. Effect of cerium oxide on kidney and lung tissue in rats with testicular torsion/detorsion. *Biomed Res Int.* 2022;2022:3176455.

11. Lavallee ME, Cash J. Testicular torsion: evaluation and management. *Curr Sports Med Rep*. 2005;4(2):102-4.
12. Ringdahl E, Teague L. Testicular torsion. *Am Fam Physician*. 2006;74(10):1739-43.
13. Burud IAS, Alsagof SMI, Ganesin R, Selvam ST, Zakaria NAB, Tata MD. Correlation of ultrasonography and surgical outcome in patients with testicular torsion. *Pan Afr Med J*. 2020;36:45.
14. Karaguzel E, Kadihasanoglu M, Kutlu O. Mechanisms of testicular torsion and potential protective agents. *Nat Rev Urol*. 2014;11(7):391-9.
15. Ahmed MA, Ahmed AA, El Morsy EM. Acetyl-11-keto- β -boswellic acid prevents testicular torsion/detorsion injury in rats by modulating 5-LOX/LTB4 and p38-MAPK/JNK/Bax/Caspase-3 pathways. *Life Sci*. 2020;260:118472.
16. Curis E, Nicolis I, Moinard C, Osowska S, Zerrouk N, Bénazeth S, et al. Almost all about citrulline in mammals. *Amino Acids*. 2005;29(3):177-205.
17. Hassel C, Couchet M, Jacquemot N, Blavignac C, Loï C, Moinard C, et al. Citrulline protects human retinal pigment epithelium from hydrogen peroxide and iron/ascorbate induced damages. *J Cell Mol Med*. 2022;26(10):2808-18.
18. Jegatheesan P, Beutheu S, Freese K, Waligora-Dupriet AJ, Nubret E, Butel MJ, et al. Preventive effects of citrulline on western diet-induced non-alcoholic fatty liver disease in rats. *Br J Nutr*. 2016;116(2):191-203.
19. Abbasi S, Azin S, Fani M, Soltani M, Abtahi-Eivary H, Moghimian M. The effect of *Origanum vulgare* on histological damage, oxidative stress and sperm parameters following induction of ischemia/reperfusion in adult testicular rat. *Sci J Kurdistan Univ Med Sci*. 2022;27(2):1-14.
20. Kuriyama K, Kitamura T, Yokoi R, Hayashi M, Kobayashi K, Kuroda J, et al. Evaluation of testicular toxicity and sperm morphology in rats treated with methyl methanesulphonate (MMS). *J Reprod Dev*. 2005;51(5):657-67.
21. Yokoi K, Uthus EO, Nielsen FH. Nickel deficiency diminishes sperm quantity and movement in rats. *Biol Trace Element Res*. 2003;93(1-3):141-54.
22. Habibi E, Arab-Nozari M, Elahi P, Ghasemi M, Shaki F. Modulatory effects of *Viola odorata* flower and leaf extracts upon oxidative stress-related damage in an experimental model of ethanol-induced hepatotoxicity. *Appl Physiol Nutr Metab*. 2019;44(5):521-7.
23. Souza ÁdPBd, Oliveira MMRd, Andrade RRd, Amorim RFBd, Bocca AL, Borin MdF. The in vivo effect of L-arginine on skin elasticity in mice. *Brazilian J Pharm Sci*. 2017;53(3):e00045.
24. Karimi Sh, Hosseinimehr SJ, Mohammadi HR, Khalatbary AR, Amiri FT. *Zataria multiflora* ameliorates cisplatin-induced testicular damage via suppression of oxidative stress and apoptosis in a mice model. *Iran J Basic Med Sci*. 2018;21(6):607-14.
25. Rousar T, Kucera O, Lotkova H, Cervinkova Z. Assessment of reduced glutathione: comparison of an optimized fluorometric assay with enzymatic recycling method. *Anal Biochem*. 2012;423(2):236-40.
26. Hayashi I, Morishita Y, Imai K, Nakamura M, Nakachi K, Hayashi T. High-throughput spectrophotometric assay of reactive oxygen species in serum. *Mutat Res*. 2007;631(1):55-61.
27. Dalle-Donne I, Rossi R, Giustarini D, Milzani A, Colombo R. Protein carbonyl groups as biomarkers of oxidative stress. *Clin Chim Acta*. 2003;329(1-2):23-38.
28. Zorov DB, Juhaszova M, Sollott SJ. Mitochondrial reactive oxygen species (ROS) and ROS-induced ROS release. *Physiol Rev*. 2014;94(3):909-50.
29. Moazamian R, Polhemus A, Connaughton H, Fraser B, Whiting S, Gharagozloo P, et al. Oxidative stress and human spermatozoa: diagnostic and functional significance of aldehydes generated as a result of lipid peroxidation. *Mol Hum Reprod*. 2015;21(6):502-15.
30. Tremellen K. Oxidative stress and male infertility--a clinical perspective. *Hum Reprod Update*. 2008;14(3):243-58.
31. Chow CK. Interrelationships of cellular antioxidant defense systems. In: *Cellular antioxidant defense mechanisms*. US: CRC Press; 2019. p. 217-38.
32. Cai B, Luo Yl, Wang SJ, Wei WY, Zhang XH, Huang W, et al. Does citrulline have protective effects on liver injury in septic rats? *Biomed Res Int*. 2016;2016:1469590.
33. Liu Y, Fu X, Gou L, Li S, Lan N, Zheng Y, et al. L-citrulline protects against glycerol-induced acute renal failure in rats. *Renal Fail*. 2013;35(3):367-73.
34. Zhou JQ, Xu X, Zhen WW, Luo YL, Cai B, Zhang S. Protective effect of citrulline on the hearts of rats with sepsis induced by cecal ligation and puncture. *Biomed Res Int*. 2018;2018:2574501.
35. Elshaari F, Elfagih R, Sherif D, Barassi I. Testicular torsion-detorsion-histological and biochemical changes in rat testis. *J Cytol Histol*. 2012;3(01):1000316.
36. Ahmed MA, Ahmed AA, El Morsy EM. Acetyl-11-keto- β -boswellic acid prevents testicular torsion/detorsion injury in rats by modulating 5-LOX/LTB4 and p38-MAPK/JNK/Bax/Caspase-3 pathways. *Life Sci*. 2020;260:118472.

37. Kasper M, Roehlecke C, Witt M, Fehrenbach H, Hofer A, Miyata T, et al. Induction of apoptosis by glyoxal in human embryonic lung epithelial cell line L132. *Am J Respir Cell Mol Biol.* 2000;23(4): 485-91.
38. Xue Y, Zhang Y, Chen L, Wang Y, Lv Z, Yang LQ, et al. Citrulline protects against LPS-induced acute lung injury by inhibiting ROS/NLRP3-dependent pyroptosis and apoptosis via the Nrf2 signaling pathway. *Exp Ther Med.* 2022;24(4):632.
39. Saad AE, Zoghroban HS, Ghanem HB, El-Guindy DM, Younis SS. The effects of L-citrulline adjunctive treatment of *Toxoplasma gondii* RH strain infection in a mouse model. *Acta Trop.* 2023;239: 106830.
40. Doğan G, İpek H. The protective effect of *Ganoderma lucidum* on testicular torsion/detorsion-induced ischemia-reperfusion (I/R) injury. *Acta Cir Bras.* 2020;35(1): e202000103.
41. Niki E. Lipid oxidation that is, and is not, inhibited by vitamin E: Consideration about physiological functions of vitamin E. *Free Radical Biol Med.* 2021;176:1-1.
42. Zhang X, Zhang J, Cai Z, Wang X, Lu W, Li H. Effect of unilateral testicular torsion at different ages on male fertility. *J Int Med Res.* 2020;48(4): 0300060520918792.
43. Gielchinsky I, Suraqui E, Hidas G, Zuaite M, Landau EH, Simon A, et al. Pregnancy rates after testicular torsion. *J Urol.* 2016;196(3):852-5.
44. Sun J, Liu GH, Zhao HT, Shi CR. Long-term influence of prepubertal testicular torsion on spermatogenesis. *Urol Int.* 2006;77(3):275-8.
45. Abdelzaher WY, Mostafa-Hedeab G, Sayed Abo-Bakr Ali AH, Fawzy MA, Ahmed AF, Bahaa El-deen MA, et al. Idebenone regulates sirt1/Nrf2/TNF- α pathway with inhibition of oxidative stress, inflammation, and apoptosis in testicular torsion/detorsion in juvenile rats. *Hum Exp Toxicol.* 2022; 41:09603271221102515.
46. Yapanoglu T, Ozkaya F, Yilmaz AH, Mammadov R, Cimen FK, Hirik E, et al. Effect of etoricoxib on experimental oxidative testicular ischemia-reperfusion damage in rats induced with torsion-detorsion. *Korean J Physiol Pharmacol.* 2017;21(5):457-64.
47. Liu H, Shi M, Li X, Lu W, Zhang M, Zhang T, et al. Adipose mesenchymal stromal cell-derived exosomes prevent testicular torsion injury via activating PI3K/AKT and MAPK/ERK1/2 pathways. *Oxid Med Cell Longev.* 2022;2022:8065771.
48. Flores-Ramírez AG, Tovar-Villegas VI, Maharaj A, Garay-Sevilla ME, Figueroa A. Effects of L-citrulline supplementation and aerobic training on vascular function in individuals with obesity across the lifespan. *Nutrients.* 2021;13(9):2991.
49. Xu X, Wu C, Jia G, Zhao H, Chen X, Wang J. Citrulline: Modulation on protein synthesis, intestinal homeostasis and antioxidant status. *Int J Nutr Sci.* 2019;4(2):1033.
50. Ho SW, El-Nezami H, Corke H, Ho CS, Shah NP. L-citrulline enriched fermented milk with *Lactobacillus helveticus* attenuates dextran sulfate sodium (DSS) induced colitis in mice. *J Nutr Biochem.* 2022;99:108858.