

Received: 2021.04.27

Accepted: 2021.07.07

Available online: 2021.07.14

Published: 2021.08.25

Desmoplastic Neurotropic Melanoma Presenting as Pilonidal Sinus: A Rare Clinical Association

Authors' Contribution:

Study Design A
Data Collection B
Statistical Analysis C
Data Interpretation D
Manuscript Preparation E
Literature Search F
Funds Collection G

EF 1 **Ori Berger**
AB 2 **Igor Lerner**
A 2 **Gilbert Ohana**
DE 3 **Igor Sinelnikov**
ADE 1 **Ran Talisman**

1 Plastic Surgery Unit, Barzilai University Hospital Medical Center, Ashkelon, Israel
2 Department of General Surgery, Barzilai University Hospital Medical Center, Ashkelon, Israel
3 Department of Pathology, Barzilai University Hospital Medical Center, Ashkelon, Israel

Corresponding Author: Ori Berger, e-mail: betheori@gmail.com

Conflict of interest: None declared

Patient: Male, 31-year-old
Final Diagnosis: Melanoma
Symptoms: Coccydynia
Medication: —
Clinical Procedure: —
Specialty: Pathology • Plastic Surgery • Surgery

Objective: Rare coexistence of disease or pathology

Background: Pilonidal Sinus (PNS) is a small cutaneous orifice in the intergluteal region; symptoms include pain and swelling. Disparately, desmoplastic neurotropic melanoma (DNM) accounts for 1% of all melanomas and mostly occurs in the head and neck region. Because its appearance is generally benign, it typically comes to surgical attention only at an advanced stage or after recurrence. A perineural involvement occurs in 30-40% of the cases and is accompanied by symptoms such as paresthesia, paresis, and/or paralysis. To the best of our knowledge, the association between PNS and DNM has not been described in the literature before. Here, we present a patient with PNS that was diagnosed with DNM.

Case Report: A 31-year-old healthy man presented with coccydynia and sacral cyst that had been present for about a year. While the initial diagnosis was of a PNS, after excision and biopsy, the pathology changed to PNS with DNM. The patient underwent a work-up for distant metastasis, which was negative. Wide local excision (WLE) with sentinel lymph node biopsy (SLNB) was also performed.

Conclusions: Due to the malignant potential of PNS, we support the routine of pathological examination of excised specimens. Once DNM is diagnosed, work-up for distant metastasis and further treatment with WLE as well as SLNB are recommended. The current report describes an association between PNS and DNM. While coccydynia may have been caused by the PNS or the melanoma, the presence of the PNS helped with an earlier diagnosis of the melanoma. Further research on the possible causative relationship between the conditions is required.

Keywords: Colorectal Surgery • Melanoma • Pilonidal Sinus • Surgery, PlasticFull-text PDF: <https://www.amjcaserep.com/abstract/index/idArt/932922>


1204



—



1



15



Background

In the current paper we present a patient with pilonidal sinus (PNS) that was eventually diagnosed with desmoplastic neurotropic melanoma (DNM). To the best of our knowledge, this association has not been previously described in the literature.

PNS is a small cutaneous orifice in the intergluteal region, with hair follicles inside the tract [1]. The condition is usually diagnosed in young adults. Patients commonly report having sacrococcygeal pain, swelling, and redness [2]. Treatment often involves surgical repair, either minor or radical [3]. The pathology of the excised tissue usually shows an inflamed tissue and hair shafts [2].

DNM accounts for 1% of all melanomas and usually affects males in the 7th decade of life. In 75%, the condition occurs in the head and neck regions [4]. The appearance of DNM is generally benign, with nonpigmented scars or morphea [4-7]. The patients typically come to surgical attention at an advanced stage or after recurrence [4,5]. Perineural involvement occurs in 30-40% of desmoplastic melanomas, and is accompanied by symptoms such as paresthesia, itching, burning, paresis, and/or paralysis [5,7].

Case Report

A 31-year-old otherwise healthy man reported having coccydynia for the last year. A physical examination revealed a typical sacral pilonidal cyst, which seemed to contain hair and granulations. The patient underwent surgery using the trephine technique, with an uneventful and quick recovery.

The specimen was sent for routine histopathological examination. Pathology contained pilonidal sinus tract with fragments of cellular, mostly spindle cell, melanin laden tumor, and an infiltrate growth pattern of invasion. A marked perineural invasion was noted, as well as extensive areas showing spindle cells with elongated nuclei among collagen bundles. Infiltration involved the subcutaneous fat but not the epidermis-dermis junction. One mitotic figure was identified in 20/HPF count. Nuclear grooves and inclusions were also detected (Figure 1). In immuno-profiling, the tumor cells were positive for S100, HMB45, MART1, and chromogranin, and Ki67 was 2% positive. The findings supported the diagnosis of DNM, and a work-up for distant metastasis including PET-CT scan was performed and was negative.

Wide local excision (WLE) of the lesion and bilateral inguinal SLNB were performed. The excised tumor showed

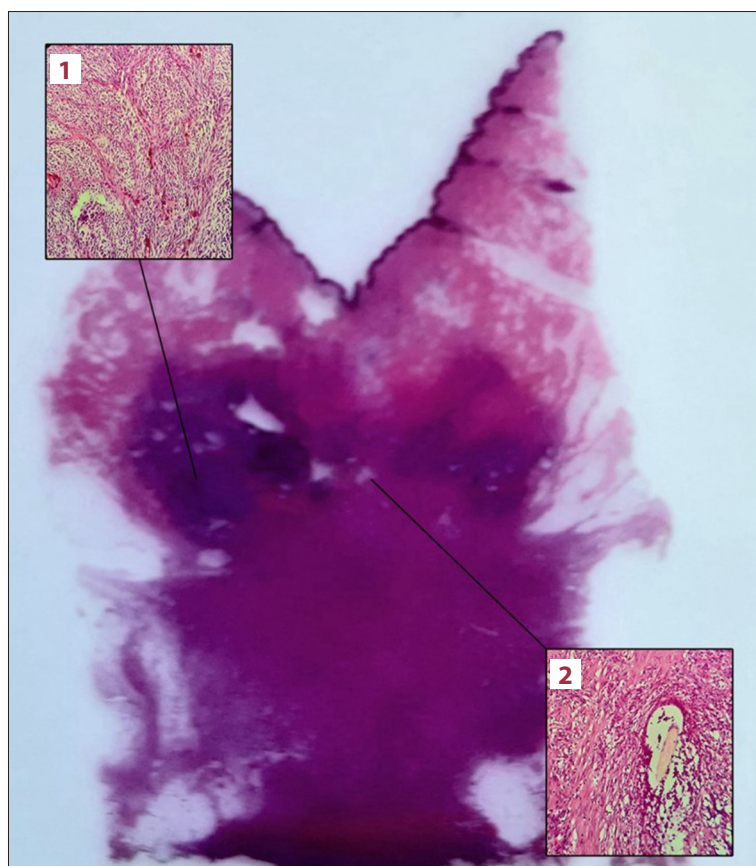


Figure 1. A histologic specimen (H&E, 40x) of the excised pilonidal sinus. **1.** Poorly circumscribed desmoplastic melanoma showing fascicular pattern of spindle cells with desmoplastic stroma. **2.** A hair follicle.

predominantly spindle cells (more than 90%) with neurotropism present. Breslow stage IV with a maximum tumor thickness of 8 mm and no ulceration or microsatellites was found, together with a mitotic rate of 1 mitosis per mm². The tumor invaded the subcutis (Clark level V), without any lympho-vascular invasion. The tumor regression involved was found to be less than 75% of the lesion. No metastasis was found in the sentinel lymph nodes that were involved in the histologic section and immuno-stains examinations.

The patient required adjuvant treatment due to stage II disease and his young age, but was lost to follow-up.

Discussion

Pilonidal sinus (PNS) is a benign condition mostly affecting young adults. The main indication for surgical treatment is the improvement of quality of life. Various surgical treatments have been suggested, aiming to lower the recurrence rate, simplify the procedure, and shorten the recovery period as much as possible [2,8]. The patient underwent the trephine technique, a minor surgical procedure in which the center of the PNS in its tracts are cored out with minimal rims of tissue, not exceeding 1-2 mm [9]. This procedure is associated with a short recovery period and reasonable recurrence rate compared to other, more radical techniques [9].

Desmoplastic neurotropic melanoma (DNM) is more locally aggressive but has a better prognosis and lower sentinel lymph node involvement than other variants [4]. However, the neurotropism has no effect on survivability or recurrency [5]. In this condition, a local disease control is of particular importance [4], as recurrence and metastasis rates are higher than in other types and may be related to inadequate excision margins [4,5]. Clear excision margins are 1 cm wide and may be difficult to achieve due to the tumor often being detected in a late stage (Clark level 4), amorphous lesion borders, tumor thickness of more than 4 mm, or due to a head and neck predilection [4-7]. Specifically, the head and neck regions are difficult to treat surgically due to the presence of important anatomical structures which limit extensive resection, varied lymphatic drainage patterns, and basins which challenge the use of SLNB [6]. While the sacral area is close to other anatomical structures, it offers more space for clear excision margins. Once DNM was diagnosed without signs of distant disease, wide local excision with SNLB was performed and clear surgical margins were achieved.

Although malignant melanoma and DNM do not have sacral predilection [3,10,11], melanoma is a great mimicker and can arise in any location and present itself as other pathologies. Evidence of this trait can be found in previous reports of

melanoma clinically masquerading as acute cholecystitis [12], central nervous system illness, or lesion [13]. Although malignancies found in pilonidal sinuses are rare, with an estimated incidence of 0.1% of all PNS cases, about 88% of them were squamous cell carcinoma [10]. Malignant degeneration is triggered by chronic or recurrent inflammation several years previously and induces the carcinomatous transformation of squamous cells [10].

The pathology report concluded that pilonidal cyst and melanoma were present concurrently. It is not clear whether there is any causative connection between the conditions or not; the patient endured his condition for a year before his operation, too short a time-window for malignancy to develop due to the PNS [10]. We assume that the presence of PNS helped with earlier diagnosis of the melanoma that hid inside of it. Thus, it is helpful to routinely send specimens for pathology when cleaning out pilonidal sinuses, as there is a possibility, although rare, of malignancies. Moreover, further research is needed to clarify if there is a possible causative relationship between the pilonidal sinus and the desmoplastic neurotropic melanoma.

The main concern expressed by patients is coccydynia, and the differential diagnosis can be divided to nociceptive, neuropathic, or visceral [14]. Etiologies are numerous, including pilonidal disease, inadequate habitus, infections, and malignancies [14,15]. Neurotropic melanoma is known to cause neuropathic pain of the head and neck regions [7]. Thus, the coccydynia that our patient had could have been neurotropic (caused by DNM), visceral (caused by PNS), or both. It is difficult to determine the source of the patient's pain.

Conclusion

The case described here shows an association between PNS and DNM for the first time. Although presenting coccydynia may have been neuropathically caused by the DNM, this could not be determined by this case alone. Either way, the presence of PNS helped with earlier diagnosis of the melanoma that hid inside of it due to the malignant potential of PNSs, which compels a routine pathological examination of all excised specimens. While PNS containing DNM is shown to be within the realm of possibilities, further research is required to clarify a possible cause-and-effect relationship between the conditions.

Referring to treatment of DNM, without any signs of distant disease on pre-surgical work-up, we recommend the common surgical approach of wide local excision and SLNB.

Conflict of Interest

None declared.

Declaration of Figures Authenticity

All figures submitted have been created by the authors who confirm that the images are original with no duplication and have not been previously published in whole or in part.

References:

1. Chintapatla S, Safarani N, Kumar S, Haboubi N. Sacrococcygeal pilonidal sinus: Historical review, pathological insight and surgical options. *Tech Coloproctol.* 2003;7(1):3-8
2. da Silva JH. Pilonidal cyst. *Dis Colon Rectum.* 2000;43(8):1146-56
3. Stauffer VK, Luedi MM, Kauf P, et al. Common surgical procedures in pilonidal sinus disease: A meta-analysis, merged data analysis, and comprehensive study on recurrence. *Sci Rep.* 2018;8(1):1-28
4. Chen JY, Hruby G, Scolyer RA, et al. Desmoplastic neurotropic melanoma: A clinicopathologic analysis of 128 cases. *Cancer.* 2008;113(10):2770-78
5. Varey AH, Goumas C, Hong AM, et al. Neurotropic melanoma: An analysis of the clinicopathological features, management strategies and survival outcomes for 671 patients treated at a tertiary referral center. *Mod Pathol.* 2017;30(11):1538-50
6. Larson DL, Larson JD. Head and neck melanoma. *Clin Plast Surg.* 2010;37(1):73-77
7. Newlin HE, Morris CG, Amdur RJ, Mendenhall WM. Neurotropic melanoma of the head and neck with clinical perineural invasion. *Am J Clin Oncol.* 2005;28(4):399-402
8. Bascom J. Pilonidal sinus. *Current Therapy in Colon and Rectal Surgery.* 1990;1:1-8
9. Gips M, Melki Y, Salem L, et al. Minimal surgery for pilonidal disease using trephines: Description of a new technique and long-term outcomes in 1,358 patients. *Dis Colon Rectum.* 2008;51(11):1656-63
10. Parpoudi SN, Kyziridis DS, Patridas DC, et al. Is histological examination necessary when excising a pilonidal cyst? *Am J Case Rep.* 2015;16:164-68
11. Chen LL, Jaimes N, Barker CA, et al. Desmoplastic melanoma: A review. *J Am Acad Dermatol.* 2013;68(5):825-33
12. Riva G, Villanova M, Eccher A, et al. Metastatic malignant melanoma to the gallbladder. Case report and review of the literature. *Pathologica.* 2018;110(1):68-71
13. Girolami I, Cima L, Ghimenton C, et al. NRAS Q61K mutated diffuse leptomeningeal melanomatosis in an adult patient with a brief review of the so-called "forme fruste" of neurocutaneous melanosis. *Brain Tumor Pathol.* 2018;35(4):217-23
14. Patijn J, Janssen M, Hayek S, et al. Coccygodynia. *Pain Practice.* 2010;10(6):554-59
15. Fogel GR, Cunningham III PY, Esses SI. Coccygodynia: Evaluation and management. *J Am Acad Orthop Surg.* 2004;12(1):49-54