

CASE REPORT

Successful treatment of type I endoleak of common iliac artery with balloon expandable stent (Palmaz XL stent) during endovascular aneurysm repair

Jong Hyuk Ahn, Jang Yong Kim, Yong Sun Jeon¹, Soon Gu Cho¹, Jay K. Park², Ki Jong Lee¹, Kee Chun Hong

Departments of Surgery, ¹Radiology and ²International Healthcare Center, Inha University School of Medicine, Incheon, Korea

Type 1 endoleak of common iliac artery (type I_b endoleak) should be treated during endovascular aneurysm repair (EVAR). An 86-year-old female was diagnosed with abdominal aortic aneurysm measuring 6.6 cm in diameter and right internal iliac artery aneurysm measuring 4.0 cm in diameter. She underwent EVAR after right internal iliac artery embolization. There was type I_b endoleak, which was repaired by balloon-expandable stent, Palmaz XL stent (Cordis). We report successful treatment of type I_b endoleak with Palmaz XL stent, which may be considered as an alternative option for type I_b endoleak after EVAR.

Key Words: Abdominal aortic aneurysm, Endovascular procedure, Endoleak

INTRODUCTION

Four to six percent of patients after endovascular aneurysm repair (EVAR) develop type I endoleak that leaks at either the proximal or distal sealing zone. Type I endoleak of the distal sealing zone (type I_b endoleak) should be treated during or after EVAR [1-3]. If endoleak is expected before EVAR, embolization of the internal iliac artery with limb extension to the external iliac artery, bypass or transposition of the internal iliac artery to the external iliac artery, or iliac bifurcated endograft has been used before or during EVAR. At least, one internal iliac artery should be saved during treatment [2]. We report type I_b endoleak,

which was found and successfully treated with a Palmaz XL stent (Cordis, Miami lakes, FL, USA) during EVAR from our experience.

CASE REPORT

An 86-year-old woman presented with vague abdominal pain. She had been bed ridden for 5 years due to lumbar compression fractures. Though she had no history of ischemic heart disease, a Thallium scan showed reversible ischemia. Computed tomography (CT) revealed aneurysms in the abdominal aorta and right internal iliac artery

Received June 14, 2011, Revised July 29, 2011, Accepted August 29, 2011

Correspondence to: Kee Chun Hong
Department of Surgery, Inha University Hospital, Inha University School of Medicine, 7-206 Sinheung-dong 3-ga, Jung-gu, Incheon 400-711, Korea
Tel: +82-32-890-2738, Fax: +82-32-890-3097, E-mail: keechong@inha.ac.kr

© Journal of the Korean Surgical Society is an Open Access Journal. All articles are distributed under the terms of the Creative Commons Attribution Non-Commercial License (<http://creativecommons.org/licenses/by-nc/3.0/>) which permits unrestricted non-commercial use, distribution, and reproduction in any medium, provided the original work is properly cited.

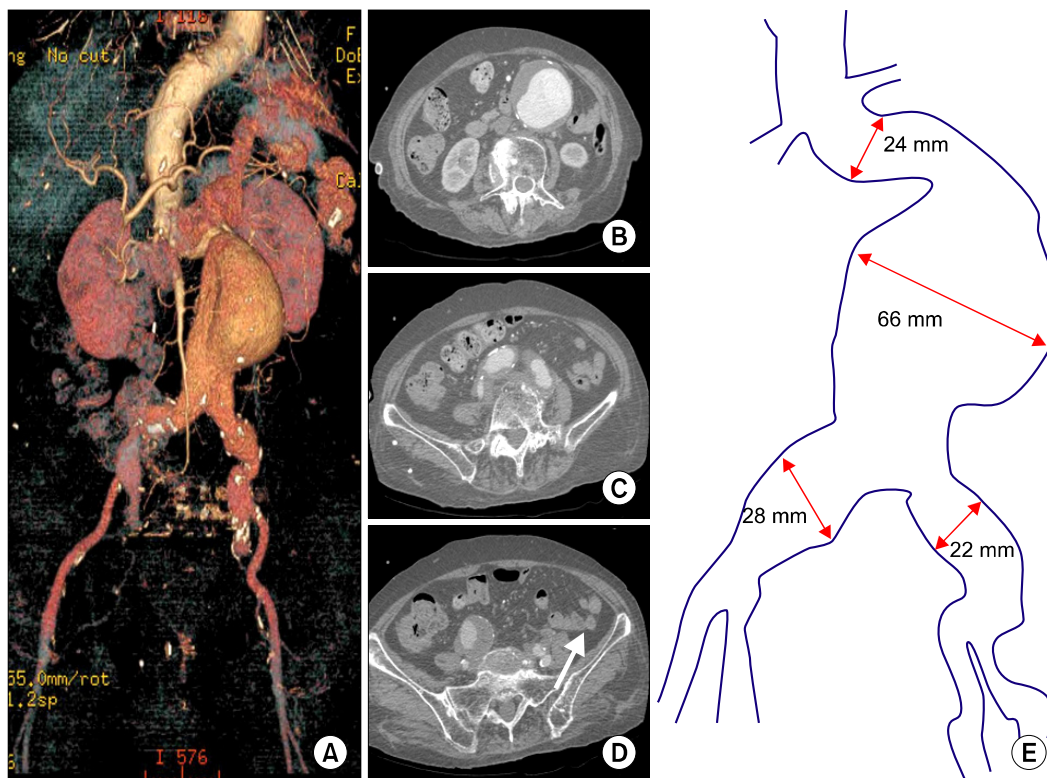


Fig. 1. Preoperative computed tomography of abdominal aortic aneurysm (AAA) revealed aortic neck was 24 mm in diameter, 20 mm in length and 80 degrees in angulation (A). Aortic aneurysm was 66 × 74 mm in diameter (B). Right common iliac artery was 24 mm and left common iliac artery was 22 mm in diameter (C). There was an aneurysm in right internal iliac artery, which was 40 mm in diameter (D, arrow). Fig. 1E shows diagram of AAA.

measuring 66 mm and 40 mm in diameter (Fig. 1B, D). CT showed that the aortic neck was 24 mm in diameter, 20 mm in length and angulated by 80 degrees (Fig. 1A). The right iliac artery was aneurysmal measuring 24 mm in diameter and the left common iliac artery was 22 mm in diameter (Fig. 1C). There was thrombus in the abdominal aortic aneurysm. The patient underwent embolization of the right internal iliac artery with 22 mm Amplatzer vascular plug (AGA Medical, Plymouth, MN, USA) to control type II endoleak from the right internal iliac artery. EVAR was performed one week later. Under general anesthesia, both femoral arteries were exposed by cutdown technique. Three Zenith endografts (Cook Medical, Bloomington, IN, USA) were deployed: 28 mm of the main body through the right side, 24 mm left of the contralateral limb in the left common iliac artery, and 10 mm right of the ipsilateral limb extending to the right external iliac artery. The angiogram after EVAR showed persistent type I_b endoleak in the

left common iliac artery even after touch ballooning with Coda balloon (Cook Medical) (Fig. 2A). Balloon-expandable stent, Palmaz XL was deployed (Fig. 2B) and the type I_b endoleak in the left common iliac artery (Fig. 2C) was under control. The Palmaz XL stent was manually mounted with 16 mm Maxi Balloon (Cordis). After deployment of the Palmaz XL stent, it was ballooned again with a Coda balloon. Follow-up angiogram after completion showed no endoleak. The patient was discharged without complications. Follow-up CT in 1 month showed no endoleak (Fig. 3).

DISCUSSION

When type I_b endoleak is expected before EVAR because of the iliac artery pathology, additional stent graft cuff deployment, embolization of the internal iliac artery

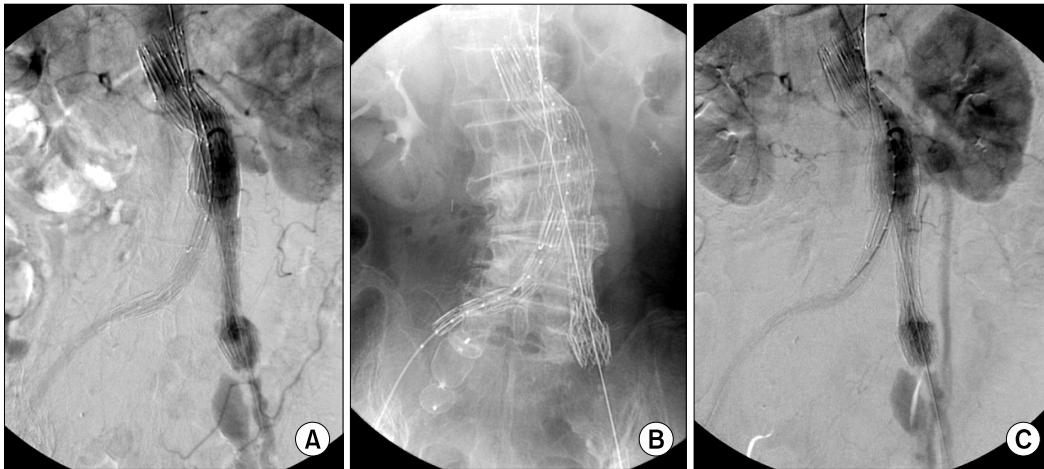


Fig. 2. (A) Angiography showed type I endoleak in left common iliac artery. (B) Palmaz XL stent was deployed in left common iliac artery. (C) Completion angiography showed disappearance of type I endoleak after Palmaz XL stent insertion.

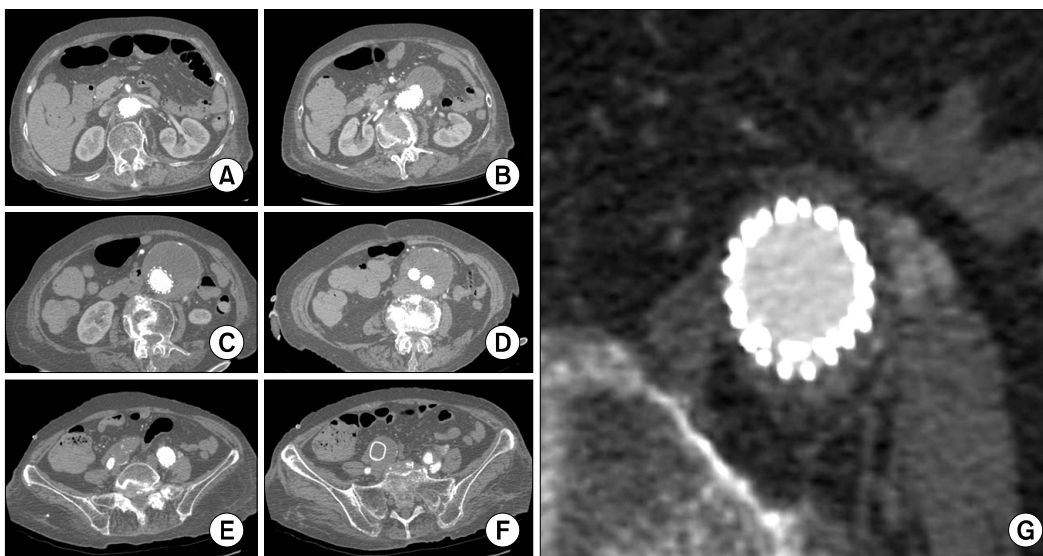


Fig. 3. There was no endoleak found in aortic neck (A, B), aneurysm (C, D) and iliac arteries (E, F) on computed tomography scan in 1 month after endovascular aneurysm repair. Left common iliac artery was sealed by endograft and Palmaz XL stent (E). Right internal iliac artery was occluded by Amplatzer vascular plug (F). Endograft and Palmaz XL stent in left common iliac artery were magnified (G).

with limb extension to the external iliac artery, transposition or bypass of the internal iliac artery to the external iliac artery, or iliac bifurcated endograft may be considered as good alternatives [1,2]. However, treatment modality for type I_b endoleak after EVAR is especially limited, or patients with high risk and those who already have had embolization of the contralateral internal iliac artery.

Type I_b endoleak found at the time of the initial implantation can be managed either by balloon dilatation or

placing an additional endograft across leaking graft junctions, or may require extension of endograft distally in order to obtain a complete seal [3,4]. The balloon angioplasty did not seal the endoleak, and we think that the cause of this endoleak was inadequate radial force of an endograft limb in the left common iliac artery. Flare type stent can be another option, but at the time of this case that stent was not available in Korea. So, we used Palmaz XL balloon-expandable stent, which has strong radial force and provides

a stronger and more persistent seal.

Arthurs et al. [5] recently reported that aortic neck reinforcement with Palmaz XL stent was still effective in long-term follow-up when used for type I_a endoleak of aortic neck. Malposition of a hand-mounted balloon-expandable stent during deployment is not an unusual complication [6,7]. To prevent malposition and increase the accuracy of stent deployment, the following techniques can be beneficial [6,7]. First, the sheath provides a means to control the sequence of the balloon expansion, and consequently, stent deployment. The portion of the balloon-stent apparatus expanding against the overlying sheath also sandwiches the stent between the two providing additional stability. Second, the off-centered loading of the stent onto the balloon leaves a larger portion of the proximal (cranial) balloon exposed when the sheath is partially drawn back. This allows for full expansion of only the proximal portion of the balloon, which prevents proximal stent migration. Again, the distal (caudal) sheath prevents any distal stent migration.

Other methods to reduce maldeployment include using a shorter stent and pre-expanding the proximal and distal end of the balloon prior to placement within the sheath. The partially inflated ends trap the stent and reduce the tendency for one end to unevenly inflate causing “watermelon seeding.” The drawbacks of this method include compromised stent length and possible difficulty in inserting the partially deployed balloon and stent past the proximal valve of the sheath [8].

This stent is the hand-mounted balloon-expandable stent, which requires experience in use. And it costs 920,000 Won (Korean currency) in Korea which means additional cost. But, recent data shows long-term stability after deployment during EVAR [5] and this seems to expand indications of EVAR in clinical practices with good results.

In conclusion, we think that Palmaz XL balloon-expandable stent provides strong radial force and a more persistent seal and can be an alternative option to achieve tight sealing and control of type I_b endoleak.

CONFLICTS OF INTEREST

No potential conflict of interest relevant to this article was reported.

REFERENCES

1. Park KM, Kim JY, Jung JE, Jeon YS, Cho SG, Choe YM, et al. Clinical experience of endoleak after endovascular aortic aneurysm repair. *J Korean Surg Soc* 2010;78:231-7.
2. Lin PH, Chen AY, Vij A. Hypogastric artery preservation during endovascular aortic aneurysm repair: is it important? *Semin Vasc Surg* 2009;22:193-200.
3. Karch LA, Henretta JP, Hodgson KJ, Mattos MA, Ramsey DE, McLafferty RB, et al. Algorithm for the diagnosis and treatment of endoleaks. *Am J Surg* 1999;178:225-31.
4. Beregi JP, Prat A, Willoteaux S, Vasseur MA, Boularand V, Desmoucelle F. Covered stents in the treatment of peripheral arterial aneurysms: procedural results and midterm follow-up. *Cardiovasc Intervent Radiol* 1999;22:13-9.
5. Arthurs ZM, Lyden SP, Rajani RR, Eagleton MJ, Clair DG. Long-term outcomes of Palmaz stent placement for intraoperative type Ia endoleak during endovascular aneurysm repair. *Ann Vasc Surg* 2011;25:120-6.
6. Gabelmann A, Krämer SC, Tomczak R, Görlich J. Percutaneous techniques for managing maldeployed or migrated stents. *J Endovasc Ther* 2001;8:291-302.
7. Slonim SM, Dake MD, Razavi MK, Kee ST, Samuels SL, Rhee JS, et al. Management of misplaced or migrated endovascular stents. *J Vasc Interv Radiol* 1999;10:851-9.
8. Koseoglu K, Parildar M, Oran I, Memis A. Treatment of type I endoleak in an iliac aneurysm with balloon expandable Palmaz stent. *Int J Angiol* 2003;12:193-5.