

Original Article

Effects of dexamethasone on hepatic macrophages in normal livers and thioacetamide-induced acute liver lesions in rats

Noa Hada^{1†}, Mizuki Kuramochi^{1†}, Takeshi Izawa¹, Mitsuru Kuwamura¹, and Jyoji Yamate^{1*}

¹ Veterinary Pathology, Osaka Prefecture University, 1-58 Rinku-Ourai-Kita, Izumisano City, Osaka 598-8531, Japan

Abstract: Resident and infiltrative macrophages play important roles in the development of pathological lesions. M1/M2 macrophage polarization with respective CD68 and CD163 expression remains unclear in chemically induced liver injury. This study was aimed at investigating the influence of macrophages on normal and chemically induced liver injury. For this, dexamethasone (DX), an immunosuppressive drug, was administered in normal rats and thioacetamide (TAA)-treated rats. Liver samples were collected and analyzed with immunohistochemical methods. Repeated injections of DX (0.5 or 1.0 mg/kg BW) for 3, 7 and 11 days reduced the number of CD163 positive hepatic resident macrophages (Kupffer cells) in normal livers, while increasing AST and ALT levels. In TAA (300 mg/kg BW)-treated rats injected with DX (0.5 mg/kg BW) pretreatment, the number of M1 and M2 macrophages showed a significant decrease compared with that of TAA-treated rats without DX treatment. Additionally, reparative fibrosis resulting from hepatocyte injury induced by TAA injection was suppressed by DX pretreatment. Our data suggested that macrophages could influence not only normal hepatic homeostasis (reflected by AST and ALT levels) but also chemically induced hepatic lesion development (reduced reparative fibrosis). (DOI: 10.1293/tox.2020-0016; J Toxicol Pathol 2020; 33: 237–246)

Key words: dexamethasone, M1 macrophage, M2 macrophage, thioacetamide

Introduction

Generally, macrophages including blood monocyte-derived macrophages, tissue resident macrophages (histiocytes/Kupffer cells) and antigen-presenting macrophages (dendritic cells) play important roles in tissue homeostasis and pathological lesion development. We previously showed that administration with empty liposome, which can be ingested by macrophages, activates Kupffer cells in rats; interestingly, the treated rats showed decreased values of serum hepatic deviation enzymes, although there were no observable changes in histological structures¹. Kupffer cells may be responsible for liver homeostasis. In pathological settings, macrophages expressing CD68, regarded as M1 type macrophages, have functions for enhancing tissue injury/inflammation by releasing inflammatory cytokines and for increasing phagocytic activity of necrotic cell debris^{2–4}. In contrast, M2 macrophages expressing CD163, which is one of the scavenger receptors, show anti-inflammatory actions

and participate in reparative fibrosis by producing fibrogenic factors^{3, 5}. After tissue injury, M1 macrophages appear in the early stages, and thereafter, M2 macrophages act as healing cells in the late stages; this phenomenon is regarded as M1/M2 macrophage polarization in the pathological process. Interestingly, after depletion of M1/M2 macrophages by pre-treatment with clodronate liposomes, thioacetamide (TAA)-induced liver lesions were aggravated, showing prolonged coagulation necrosis in the early stages and dystrophic calcification in the late stages. The aggravated lesions might have resulted from decreased functions of phagocytic clearance of necrotic cells by M1 macrophages and from reparative fibrogenesis by M2 macrophages³.

Dexamethasone (DX), a synthetic steroid, has been used as an anti-inflammatory drug in collagen diseases, interstitial pneumonia, and viral hepatitis. Anti-fibrotic effects of DX are also well-known^{6–8}. To find out the influence of hepatic macrophages, we investigated the effects of DX on liver homeostasis in normal livers and TAA-induced liver lesions in rats, focusing on macrophage appearance of M1/M2 types.

Materials and Methods

Animal experiments

Animals were housed in an animal room at a controlled temperature of 21 ± 3°C with a 12-h light-dark cycle; they were provided a standard diet (MF; Oriental Yeast Co., Ltd., Osaka, Japan) and tap water *ad libitum*. The animal experi-

Received: 11 March 2020, Accepted: 7 July 2020

Published online in J-STAGE: 31 July 2020

*Corresponding author: J Yamate

(e-mail: yamate@vet.osakafu-u.ac.jp)

†These authors contributed equally to this work.

©2020 The Japanese Society of Toxicologic Pathology

This is an open-access article distributed under the terms of the Creative Commons Attribution Non-Commercial No Derivatives

(by-nc-nd) License. (CC-BY-NC-ND 4.0: <https://creativecommons.org/licenses/by-nc-nd/4.0/>).



ments were conducted under the institutional guidelines approved by the Ethical Committee for Animal Care at Osaka Prefecture University.

DX treatment to normal rats (Experiment 1)

Six week-old male F344/DuCrj rats (Charles River Japan, Yokohama, Japan) were injected intraperitoneally with DX (dissolved dexamethasone A, Zenoaq, Fukushima, Japan) at doses of 0.5 and 1.0 mg/kg body weight every day until 3, 7 and 11 days ($n=4$ at each point in each dose); some rats were subjected to a 4-day withdrawal after an 11-day treatment with DX. Control rats ($n=4$) were injected with an equal volume of saline. All rats were euthanized by deep isoflurane anesthesia, and blood (from the abdominal artery) and liver samples were collected. Serum aspartate transaminase (AST) and alanine transaminase (ALT) values were measured by Hitachi automatic analysis machine (Hitachi 7070, Hitachi High-Technologies, Tokyo, Japan).

TAA-induced rat liver injury (Experiment 2)

Six week-old male F344/DuCrj rats were divided into the following 3 groups: I) continuous DX pre-treatment for 3 days (0.5 mg/kg body weight, every day, intraperitoneally) followed by TAA injection (300 mg/kg body weight, once, intraperitoneally) on day 3 after the initial injection of DX (DX+TAA group), II) saline injection instead of DX treatment followed by TAA injection in the same manner (TAA group), and III) saline injection without TAA injection (control group). All rats were euthanized by deep isoflurane anesthesia, and blood (from the abdominal artery) and liver samples were collected. Samples were collected on days 1, 3, 5 and 7 after TAA injection ($n=4$ at each point in each group). AST and ALT values were measured by the same method as mentioned above.

Histopathology and immunohistochemistry

The liver samples were fixed in 10% neutral buffered formalin or Zamboni solution (0.21% picric acid, 2% paraformaldehyde, 130 mM phosphate buffer; pH 7.4), routinely processed and embedded in paraffin. Deparaffinized sections, cut 3 μm thick, were stained with hematoxylin and eosin (HE) for histopathologic examination.

Formalin-fixed sections were used for immunohistochemistry for CD68 (clone ED1; 1:750; Merk Millipore, MA, USA) and MIF (macrophage migration inhibitory factor; 1:500; gifted from Dr. Shin Sato, Aomori University of Health and Welfare). Zamboni-fixed sections were used for immunohistochemistry for CD163 (clone ED2; 1:200; Serotec, Kidlington, UK). For antigen retrieval, CD68 and MIF were each microwaved for 5 min in 0.01 M citrate buffer (pH 6.0), and CD163 was treated with 0.1% trypsin treatment for 15 min at room temperature. The sections were incubated with each primary antibody for 1 h at room temperature, followed by 1-hour incubation with peroxidase-conjugated secondary antibody (Histofine Simple Stain MAX-PO; Nichirei, Tokyo, Japan). Positive reactions were detected with 3, 3'-diaminobenzidine (Nichirei). Sections were coun-

terstained lightly with hematoxylin.

The number of positive cells around the central vein of the hepatic lobule were counted in five different areas from four different rats using a WinRoof software (Mitani Corp., Fukui, Japan). Data are expressed as the number of positive cells per unit area (cells/ mm^2).

Evaluation of fibrosis

Fibrosis was evaluated with azan-Mallory-stained sections. The area of fibrosis around the central vein was measured in five different areas using a WinRoof software (Mitani Corp., Fukui, Japan). Data are expressed as the percentage of fibrosis area per unit area (0.01 mm^2).

Reverse transcription polymerase chain reaction (RT-PCR)

The liver samples were lysed in Trizol ReagentTM (Invitrogen Corp., Carlsbad, CA, USA) and total RNA was extracted according to the manufacturer's instruction. Reverse-transcription was performed with 2 μg of total RNA using Super Script Preamplification SystemTM (Invitrogen). PCR was performed with Taq DNA polymerase (Takara Shuzo Co. Ltd., Kyoto, Japan). The primers of TNF- α were designed as follows: sense (5'-TGTCTACT-GAACTTCGGGGTG-3') and antisense (5'-GAGGCT-GACTTTCTCTGGTA-3'). First, samples were incubated in 95°C for 2 min for pre-denature, followed by 40 cycles of denature (95°C for 30 min), annealing (60°C for 30 min) and extension (72°C for 60 s per 1 kbp). PCR products were electrophoresed, and the bands were measured with NIH Image 1.61 (Bethesda, MD, USA).

Statistics

Data are represented as mean \pm standard error (SE). Statistical analyses were performed using Dunnett's test or Tukey-Kramer's test. Significance was accepted at $P < 0.05$.

Results

Experiment 1

DX treatment results in increased hepatic deviation enzymes without affecting histological structures: The rats treated with DX at doses of 0.5 and 1.0 mg/kg showed decreased body weights through all experimental periods (approximately 38% in both doses to controls on day 11). No histopathological abnormalities were seen in the livers (Fig. 1A) of control rats or DX-treated rats at both doses (Fig. 1B–D). As compared with the control, the values of AST and ALT significantly increased on day 11 at 0.5 mg/kg DX and on days 7 and 11 at 1.0 mg/kg; after a 4-day withdrawal period, these levels recovered close to control levels (Fig. 1E).

The number of macrophages significantly decreases with DX treatment: In the control livers, CD68-positive macrophages were very small in number (less than 1 per mm^2); therefore, statistically significant evaluation could not be done in rats treated with 0.5 and 1.0 mg/kg DX (data

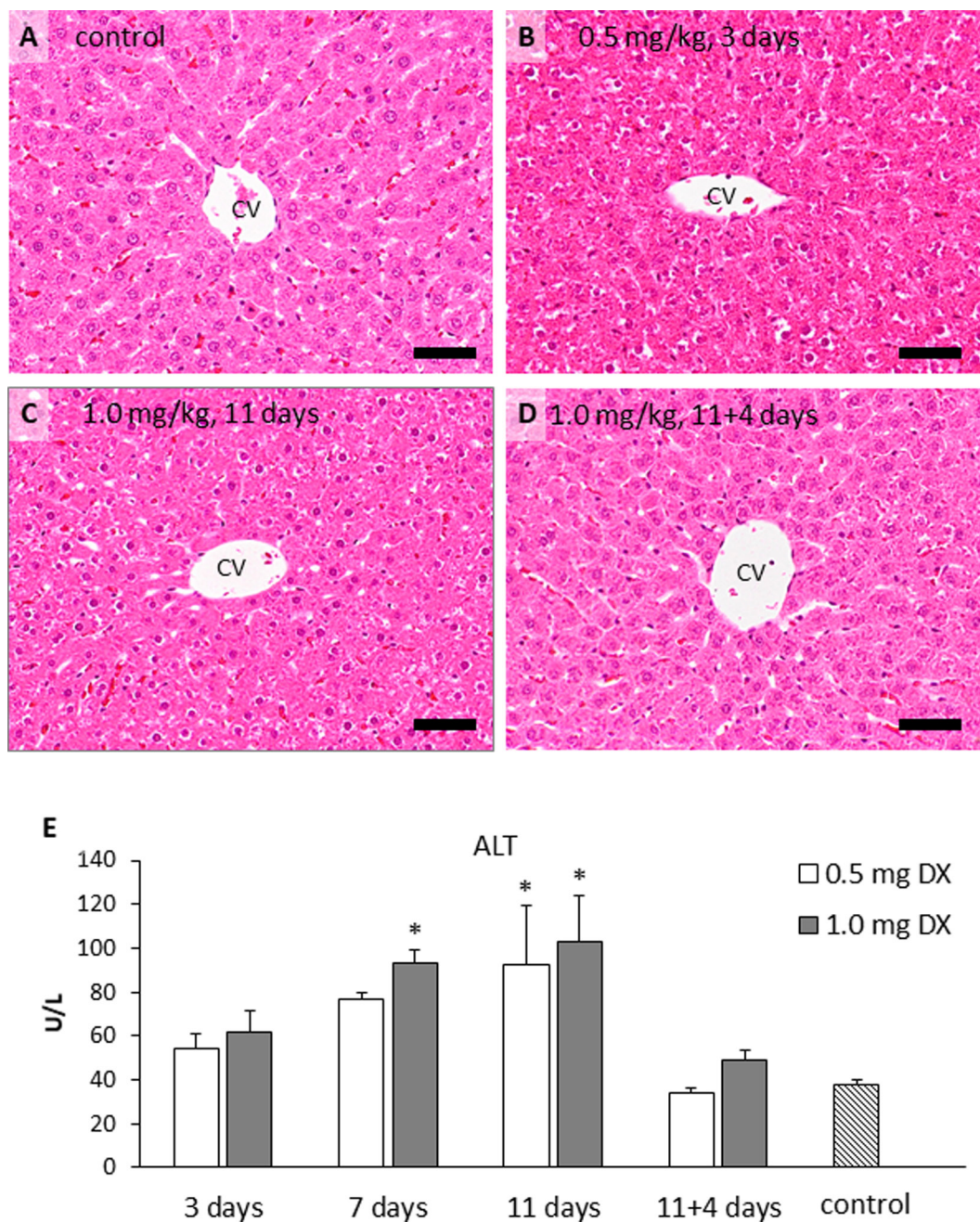


Fig. 1. Histopathology of control liver and dexamethasone (DX)-treated livers at 0.5 and 1.0 mg/kg body weight. (A) Livers of control and (B, C) continuous treatments of 0.5 or 1.0 mg/kg DX do not show any histopathological changes. (D) Four-day withdrawal after 11-day continuous DX treatment does not cause histopathological changes in the liver. (E) The level of alanine transaminase (ALT) gradually increases in rats after 3, 7 and 11-day DX treatment, compared with control. Four-day withdrawal after 11-day DX treatment results in recovery of these levels close to controls. Liver samples were stained with hematoxylin and eosin. CV, central vein; bar = 100 μ m; *, $P < 0.05$, vs. control; Dunnett's test.

not shown).

In the control livers, CD163-positive macrophages were seen along the sinusoids (Fig. 2A), indicating Kupffer cells³. The number of CD163-positive macrophages significantly decreased on days 3, 7 (Fig. 2B) and 11 at 0.5 and 1.0 mg/kg; it tended to recover partly after the 4-day withdrawal period following the 11-day treatment (Fig. 2C).

Hepatic expression of TNF- α mRNA was not detected either in the control or the 11-day DX-treated livers; interestingly, increased TNF- α expression was seen after the 4-day withdrawal (Fig. 3).

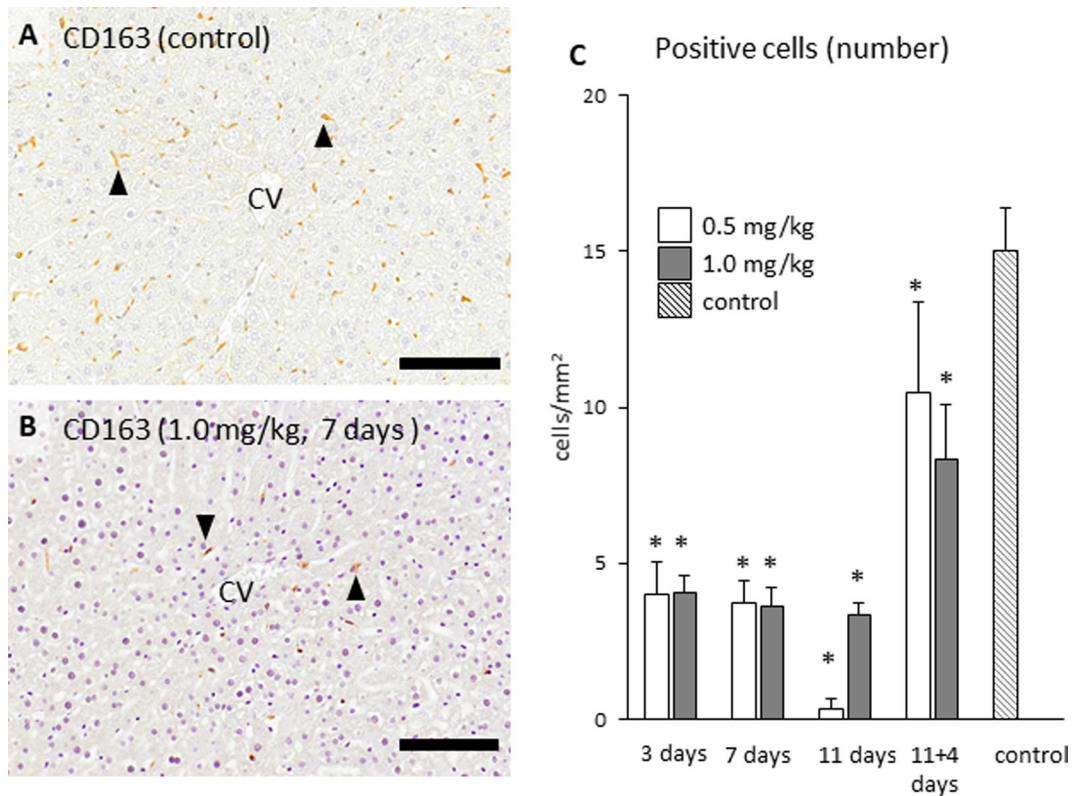


Fig. 2. Immunohistochemical analysis for CD163 as a marker of M2 macrophage. (A) CD163-positive cells (arrowheads) are seen along the sinusoids in controls, indicative of liver resident macrophages (Kupffer cells). (B) CD163-positive cells (arrowheads) are obviously decreased after DX treatment. (C) The number of CD163-positive macrophages significantly decreases in rats after 3, 7 and 11-day DX treatment. The number tends to recover after 4-day withdrawal of DX treatment. CV, central vein; bar = 50 μ m. $P < 0.05$; *, vs. control; Dunnett's test.

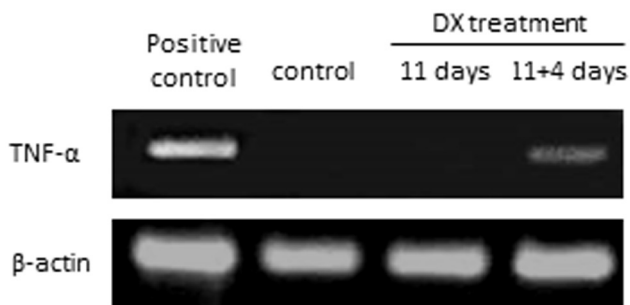


Fig. 3. Polymerase chain reaction for TNF- α mRNA using livers of control, 11-day DX of 0.5 mg/kg, and 4-day withdrawal after 0.5 mg/kg DX, as well as positive control of TAA-injected rat. TNF- α expression is not seen in control and 11-day DX treatment; however, it appears during 4-day withdrawal after continuous injection of 0.5 mg/kg DX.

Experiment 2

Histopathology of TAA-induced rat liver injury under DX influence: A dose of 0.5 mg/kg DX was used in this experiment, because the suppression of CD163-positive macrophages was similar between doses of 0.5 and 1.0 mg/kg.

Histologically, in TAA group, coagulation necrosis was observed in the affected centrilobular areas on days 1 and 3; on day 3, inflammatory cells, including mainly mononuclear cells, were seen in the affected areas (Fig. 4A and B). Such hepatic lesions almost recovered on days 5 and 7 with reparative fibrosis (Fig. 4C and D), although degenerative hepatocytes were still seen in the affected area on day 5 (Fig. 4C). In DX + TAA group, coagulation necrosis was seen in the affected centrilobular area on day 1 (Fig. 4E), as seen on day 1 in TAA group; interestingly, inflammatory cells were rarely seen on day 3 (Fig. 4F), and there were no histopathological lesions on days 5 or 7 (Fig. 4G and H).

Compared with controls, the values of AST and ALT on day 1 in both TAA and DX + TAA groups were significantly increased. These values returned to control levels on day 3 onwards, indicating acute hepatic injury and subsequent recovery by TAA treatment (Fig. 4J and K). There were, however, no significant changes between the TAA and DX + TAA groups.

Reparative fibrosis is attenuated by DX treatment: Collagen deposition in the normal liver was very slight (Fig. 5A). In TAA group, the collagen deposition, stained blue with the azan-Mallory method, increased in the affected centrilobular areas on days 3, 5 (Fig. 5B) and 7, indicating reparative fibrosis after the tissue injury. In DX + TAA group, collagen

deposition was similar to that in control (Fig. 5C). Thus, the collagen deposition in TAA group on days 3, 5, and 7 was much greater than that in the control and DX + TAA group (Fig. 5D). Additionally, in TAA group, degenerative hepato-

with the level being the greatest on days 1 and 3, indicating inflammatory response after the tissue injury by TAA injection (Fig. 6A, B and E). In DX + TAA group, the number of CD68-positive cells increased significantly on day 1

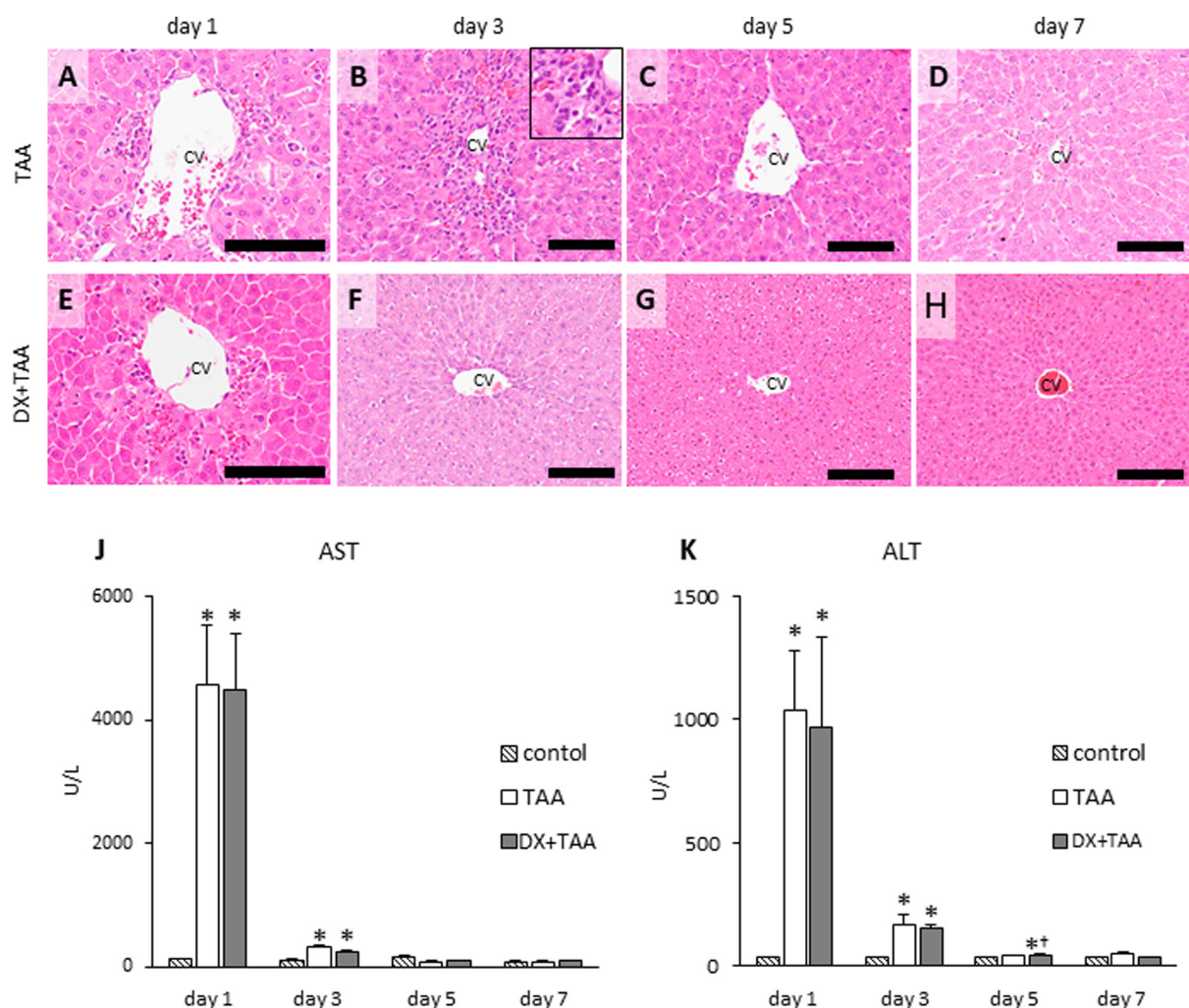


Fig. 4. Histopathology of thioacetamide-treated livers (TAA; 300 mg/kg BW) and DX pre-treated (3-day continuous DX treatment) livers followed by TAA injection: (A-D) saline injection instead of DX treatment, followed by TAA injection in liver samples (TAA group) and (E-H) DX pre-treated TAA-injected liver samples (DX + TAA group). In TAA group, (A) coagulation necrosis is seen in the centrilobular area on day 1; (B) inflammatory cells, including macrophages, are seen in the centrilobular area on day 3 (inset: high magnification); (C, D) the lesion is almost recovered on days 5 and 7, although degenerative hepatocytes are still seen on day 5. In DX + TAA group, (E) coagulation necrosis is also seen on day 1; (F) inflammatory macrophages are rarely seen in the centrilobular area on day 3; (G, H) the lesion is recovered on days 5 and 7. (J, K) The levels of hepatic deviation enzymes, such as aspartate transaminase (AST) and alanine transaminase (ALT), increase on day 1 in both TAA and DX + TAA groups; these levels begin to decrease from day 3. Liver samples were stained with hematoxylin and eosin. CV, central vein; bar = 100 μ m. $P < 0.05$; *, vs. control; Dunnett's test.

cytes were still observed on day 5 (Fig. 4C) with reparative fibrosis, whereas such degenerative changes were not seen in hepatocytes in DX + TAA group on day 5 (Fig. 4G).

Macrophage infiltration in TAA-induced liver lesion is suppressed by DX treatment: In TAA group, the number of CD68-positive cells (M1 macrophages) significantly increased on days 1, 3, 5, and 7 as compared with controls,

(Fig. 6C and E); however, there was no significant change on days 3 (Fig. 6D and E), 5 or 7. The number of CD68-positive cells in DX + TAA group was significantly less than that in TAA group on days 1, 3, 5 and 7 (Fig. 6E). Collectively, CD68-positive infiltrating macrophages, which should increase after TAA injection, were markedly suppressed by DX treatment in DX + TAA group.

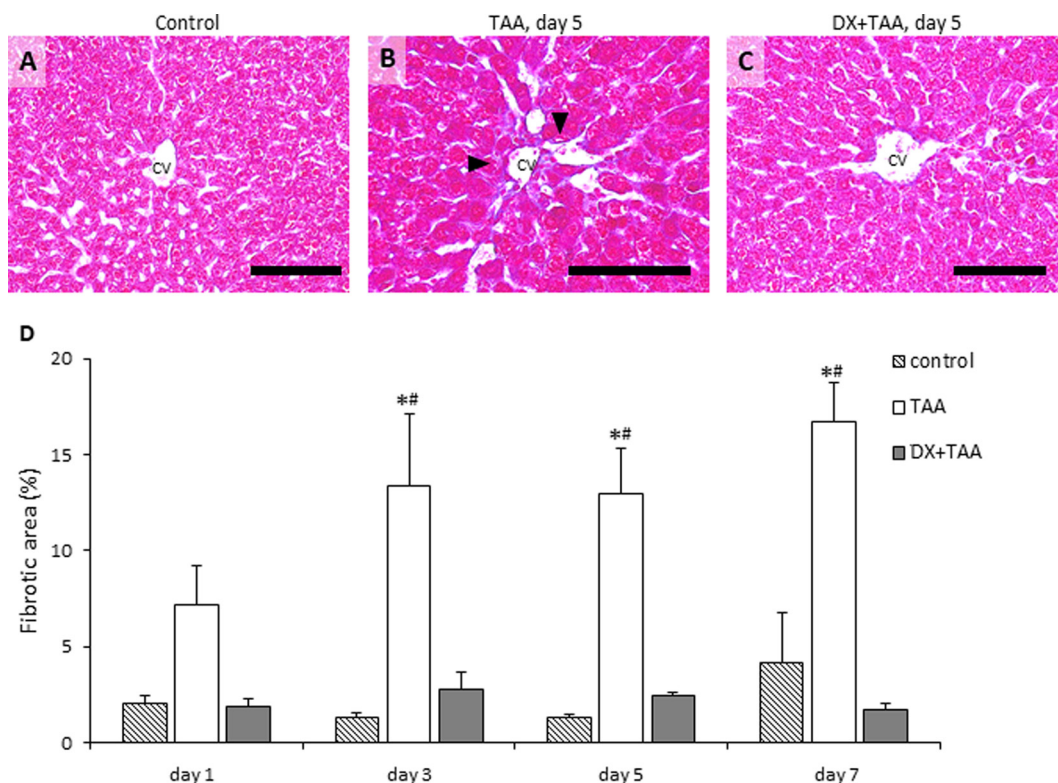


Fig. 5. Evaluation for collagen deposition for fibrosis with the azan-Mallory method. (A) Collagen deposition is not seen in the control liver. (B) In TAA group, along with degenerative hepatocytes, collagen deposition is observed in the centrilobular area (arrowheads) on day 5 as reparative fibrosis. (C) In DX + TAA group, the degree of collagen deposition on day 5 is lesser compared with that in TAA group. (D) The degree of collagen deposition is notably suppressed in DX + TAA groups compared with that in TAA groups. CV, central vein; bar = 100 μ m. $P < 0.05$; *, vs. control; #, vs. DX+TAA; Tukey-Kramer's test.

On day 1, CD163-positive cells (M2 macrophages) showed a significant decrease in TAA and DX + TAA groups (Fig. 7A, C and E), as compared with control, indicating the suppression of M2 macrophages in TAA group and DX + TAA group with DX treatment. In contrast, the number of CD163-positive cells significantly increased on day 3 in TAA group (Fig. 7B and E) compared with that of the control, indicating M2 macrophage reaction upon TAA injection; however, they decreased significantly in the DX + TAA group (Fig. 7D and E). The number of CD163-positive cells did not show any significant change between these groups on days 5 and 7. The DX treatment clearly suppressed CD163-positive M2 macrophages on days 1 and 3 in DX + TAA group. In conclusion, the appearance of M1 and M2 macrophages in TAA-induced lesions was suppressed by DX pretreatment.

MIF expression in TAA-induced liver lesions under DX treatment: Macrophage-migration inhibitory factor (MIF) is a regulator molecule known to accumulate macrophages in lesions and progress inflammation^{9,10}. To compare distributions of MIF between TAA and DX + TAA groups, immunohistochemistry for MIF was evaluated. In TAA group, affected hepatocytes in the centrilobular area on day 1 showed a strong positive reaction to MIF (Fig. 8A); the reactivity quickly decreased on days 3, 5 and 7. On the

contrary, in DX + TAA group, some hepatocytes reacted to MIF in the affected centrilobular area (Fig. 8B) and thereafter, MIF-positive cells were rarely seen on days 3, 5 and 7, as seen in the control livers without any positive cells to MIF.

Discussion

In hepatotoxicity, chemicals injure hepatocytes directly or indirectly via reactive metabolites converted by metabolic enzymes such as cytochrome P450¹¹⁻¹³. The cause of hepatotoxicity by TAA is its reactive metabolites, TAA-sulfoxide, TAA-S, and S-dioxide produced by CYP2E1 which is abundant in the centrilobular area in the liver^{14, 15}. These metabolites covalently bind to and modify cellular lipids or proteins, resulting in centrilobular hepatocellular necrosis^{16, 17}. Besides the direct role of these chemicals themselves, macrophages may also influence chemical-induced liver lesions by modifying the balance between inflammation and anti-inflammation. M1/M2 macrophages may be useful in evaluating hepatotoxicity³. In fact, in TAA-induced rat liver lesions, CD68-positive M1 macrophages for tissue injury/inflammation appear in the early stages, and thereafter, CD163-positive M2 macrophages are recruited for anti-inflammatory action and reparative fibrosis in the late stages³.

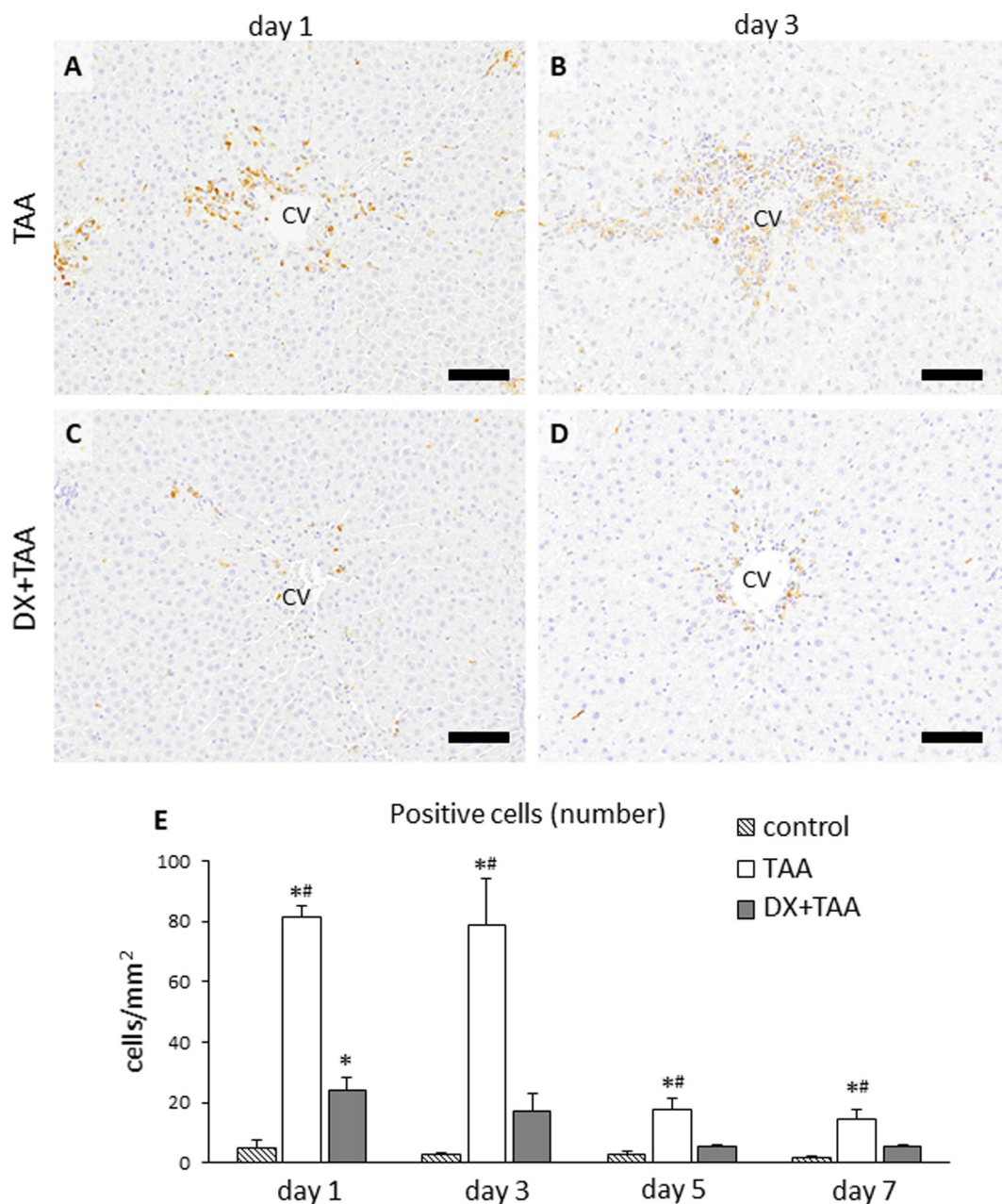


Fig. 6. Immunohistochemical analysis for CD68 for M1 macrophages in liver samples. (A) In TAA group, CD68-positive macrophages appear in the centrilobular area on day 1; (B) CD68-positive macrophages are still seen on day 3. (C, D) in DX + TAA group, CD68-positive macrophages are decreased in the centrilobular area compared with those in TAA group on days 1 and 3. (E) The numbers of CD68-positive cells in DX + TAA group are temporarily increased on day 1 compared with control group; however, they are statistically less than that in TAA group on each examination day. CV, central vein; bar = 100 μ m. $P < 0.05$; *, vs. control; #, vs. DX+TAA; Tukey-Kramer's test.

Anti-inflammatory effects of DX used in this study are due to the suppression of arachidonic cascade and down-regulation of eicosanoids production, affecting functions of inflammatory cells^{18–20}. It has been reported that DX affects macrophages by inhibiting transcription factors such as NF- κ B, resulting in down-regulation of cytokine expression, chemotaxis, phagocytosis and antigen-presenting activity of macrophages^{20,21}. In this study, we investigated effects of DX on liver homeostasis and TAA-induced liver lesion development in rats.

Effects of DX on macrophage appearance in normal rat livers (experiment 1)

In normal livers, there were no inflammatory macrophages expressing CD68. CD163-positive cells are found in normal livers and they are regarded as Kupffer cells, based on the distribution^{2,22}. Daily injections of DX for 3, 7 and 11 days at 0.5 and 1.0 mg/kg body weight markedly suppressed the appearance of CD163-positive Kupffer cells.

With the decrease of Kupffer cells by DX, the ALT level

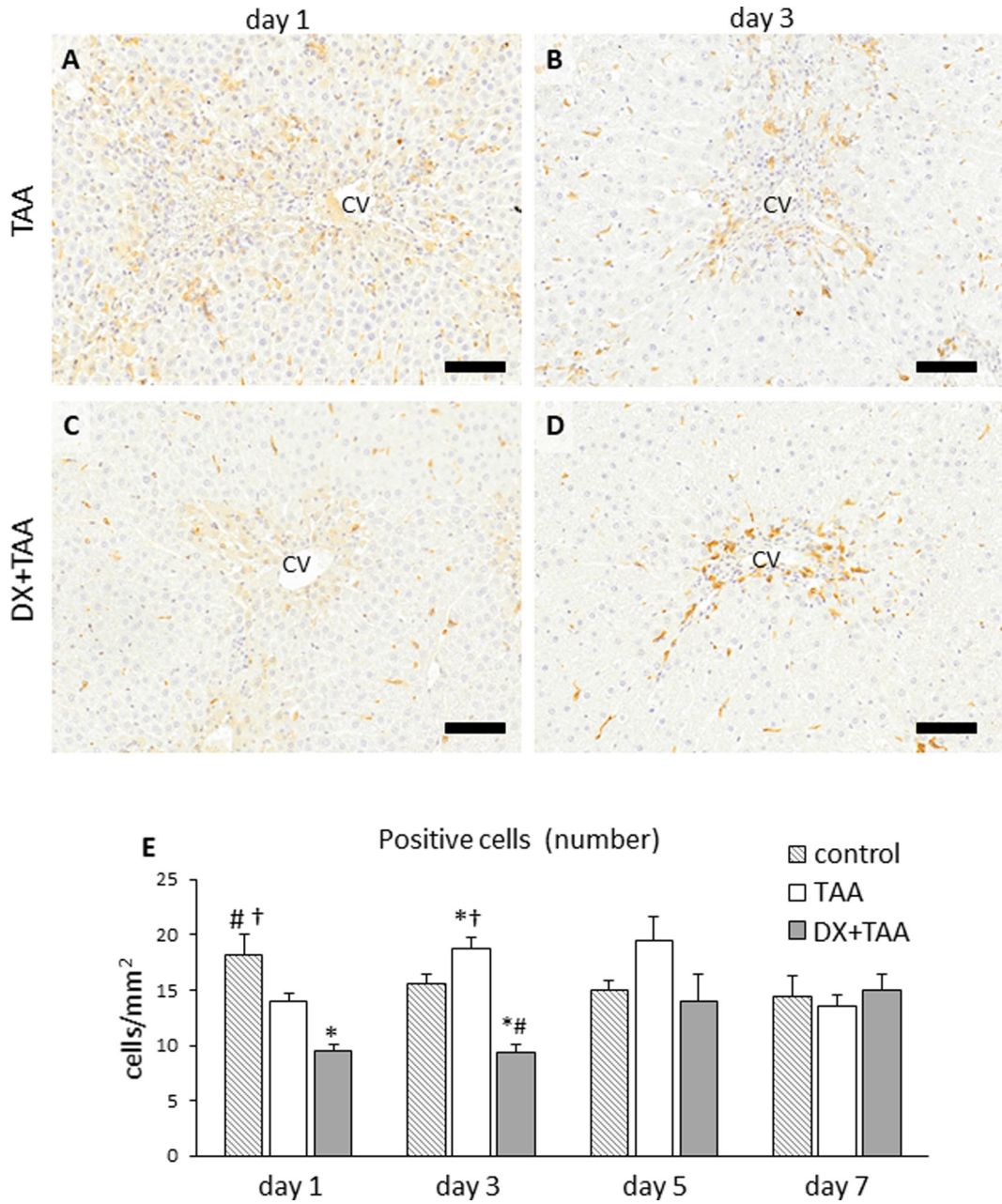


Fig. 7. Immunohistochemical analysis for CD163 for M2 macrophages. (A) In TAA group, CD163-positive macrophages with swollen cytoplasm are seen in the centrilobular area on day 1; (B) CD163-positive macrophages are still seen on day 3. (C) In DX+TAA group, CD163-positive macrophages also appear in the centrilobular area; (D) the appearance of CD163-positive macrophages is notable on day 3. (E) However, the numbers of CD163-positive macrophage in DX + TAA group are statistically less than that in TAA group on days 1 and 3. CV, central vein; bar = 100 μ m. $P < 0.05$; *, vs. control; #, vs. TAA; †, vs. DX+TAA; Tukey-Kramer's test.

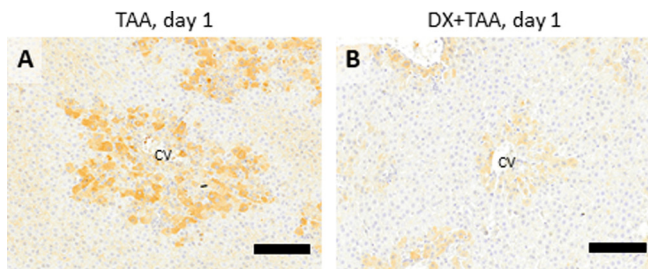


Fig. 8. Immunohistochemistry for macrophage-migration inhibitory factor (MIF) in liver samples. (A) Hepatocytes in the centrilobular area strongly express MIF in TAA group on day 1. (B) The MIF expressions is weaker in DX + TAA group liver samples. CV, central vein; bar = 100 μ m.

increased in a time and dose-dependent manner. Similarly, treatment with clodronate liposome, which induces apoptosis of macrophages including Kupffer cells, also increased the levels of ALT and AST²³. In contrast, our results showed that the ALT and AST values significantly decreased under the activation of Kupffer cells induced by empty liposome¹. Kupffer cells can be related to the clearance of hepatic deviation enzymes^{1, 23, 24}.

More interestingly, CD163-positive Kupffer cells showed recovery with the 4-day withdrawal after the DX treatment. Simultaneously, the mRNA band of TNF- α , which is a cytokine for tissue injury^{25, 26} appeared, although there were no bands during continuous treatment of DX and in controls. Therefore, recovered hepatic residential macrophage (Kupffer cells) might have had inflammatory functions related to the increase of TNF- α mRNA. Such mechanisms need to be investigated further.

DX attenuates drug induced liver fibrosis (experiment 2)

Liver lesions in rats injected once by TAA (300 mg/kg body weight) are characterized by coagulation necrosis, inflammatory cell reaction and subsequently reparative fibrosis in the centrilobular area; CD68- and CD163-positive macrophages appear in the affected areas⁵. In the present TAA group, the induced lesions were similar to those reported previously^{5, 27}. CD68- and CD163-positive macrophages, which showed an increased appearance in the TAA group, were markedly suppressed by the treatment with 0.5 mg/kg DX. Because immunoeexpression of MIF in the affected hepatocytes was inhibited at the early stages in DX + TAA group, the DX treatment might have suppressed MIF expression, presumably resulting in the inhibition of migration of M1/M2 macrophages into injured areas⁹. Under decreased number of M1/M2 macrophages, TAA-induced liver lesions, particularly reparative fibrosis, were attenuated in the late stages. Besides inhibition of fibroblasts, inhibition of macrophage infiltration, which might be caused by suppression of MIF by DX, plays a crucial role in the attenuation of reparative fibrosis^{28, 29}. A previous study showed that DX injection could attenuate the levels of bleomycin-induced interstitial pneumonia with decreased number of appearing macrophages in rats⁶. On the contrary, the clodronate liposome treatment in TAA-injected rats aggravated the liver lesions, which was characterized by prolonged coagulation necrosis and occurrence of dystrophic calcification³. Macrophages appearing in lesions might influence inflammation progression and subsequent fibrosis.

Summary

In conclusion, this study with DX treatment showed possible roles of macrophages in physiological and pathological settings; physiologically, resident macrophages (Kupffer cells) maintain hepatic homeostasis through possible clearance of AST and ALT, and pathologically, M1/M2 macrophages modify hepatic lesions induced by TAA. Particularly, hepatic reparative fibrosis by TAA injection was

attenuated by DX treatment. Further studies on fibrogenic factors and molecular mechanisms affecting DX would be useful to understand development of chemical-induced hepatic lesions.

Disclosure of Potential Conflicts of Interest: The authors have no conflicts of interest directly relevant to the content of this article.

Acknowledgments: This work was supported partly by JSPS KAKENHI Grant Numbers 18J14823 (to Kuramochi), 26292152 (to Yamate) and 19H03130 (to Yamate), and by the Platform Project for Supporting Drug Discovery and Life Science Research (Basis for Supporting Innovative Drug Discovery and Life Science Research (BINDS)) from AMED under Grant Number JP20am0101123 (to Yamate).

References

1. Pervin M, Golbar HM, Bondoc A, Izawa T, Kuwamura M, and Yamate J. Transient effects of empty liposomes on hepatic macrophage populations in rats. *J Toxicol Pathol.* **29**: 139–144. 2016. [[Medline](#)] [[CrossRef](#)]
2. Wijesundera KK, Izawa T, Tennakoon AH, Golbar HM, Tanaka M, Kuwamura M, and Yamate J. M1-/M2-macrophages contribute to the development of GST-P-positive preneoplastic lesions in chemically-induced rat cirrhosis. *Exp Toxicol Pathol.* **67**: 467–475. 2015. [[Medline](#)] [[CrossRef](#)]
3. Golbar HM, Izawa T, Wijesundera KK, Bondoc A, Tennakoon AH, Kuwamura M, and Yamate J. Depletion of hepatic macrophages aggravates liver lesions induced in rats by thioacetamide (TAA). *Toxicol Pathol.* **44**: 246–258. 2016. [[Medline](#)] [[CrossRef](#)]
4. Xu J, Liu X, Koyama Y, Wang P, Lan T, Kim IG, Kim IH, Ma HY, and Kisseleva T. The types of hepatic myofibroblasts contributing to liver fibrosis of different etiologies. *Front Pharmacol.* **5**: 167. 2014. [[Medline](#)] [[CrossRef](#)]
5. Wijesundera KK, Izawa T, Tennakoon AH, Murakami H, Golbar HM, Katou-Ichikawa C, Tanaka M, Kuwamura M, and Yamate J. M1- and M2-macrophage polarization in rat liver cirrhosis induced by thioacetamide (TAA), focusing on Iba1 and galectin-3. *Exp Mol Pathol.* **96**: 382–392. 2014. [[Medline](#)] [[CrossRef](#)]
6. Dik WA, McAnulty RJ, Versnel MA, Naber BAE, Zimmermann LJI, Laurent GJ, and Mutsaers SE. Short course dexamethasone treatment following injury inhibits bleomycin induced fibrosis in rats. *Thorax.* **58**: 765–771. 2003. [[Medline](#)] [[CrossRef](#)]
7. Armbrust T, Kreissig M, Tron K, and Ramadori G. Modulation of fibronectin gene expression in inflammatory mononuclear phagocytes of rat liver after acute liver injury. *J Hepatol.* **40**: 638–645. 2004. [[Medline](#)] [[CrossRef](#)]
8. Wickert L, Abiaka M, Bolkenius U, and Gressner AM. Corticosteroids stimulate selectively transforming growth factor (TGF)- β receptor type III expression in transdifferentiating hepatic stellate cells. *J Hepatol.* **40**: 69–76. 2004. [[Medline](#)] [[CrossRef](#)]
9. Hori Y, Sato S, Yamate J, Kurasaki M, Nishihira J, Hosokawa T, Fujita H, and Saito T. Immunohistochemical study of

- macrophage migration inhibitory factor in rat liver fibrosis induced by thioacetamide. *Eur J Histochem.* **47**: 317–324. 2003. [[Medline](#)] [[CrossRef](#)]
10. Fingerle-Rowson G, Koch P, Bikoff R, Lin X, Metz CN, Dhabhar FS, Meinhardt A, and Bucala R. Regulation of macrophage migration inhibitory factor expression by glucocorticoids in vivo. *Am J Pathol.* **162**: 47–56. 2003. [[Medline](#)] [[CrossRef](#)]
 11. Au JS, Navarro VJ, and Rossi S. Review article: Drug-induced liver injury--its pathophysiology and evolving diagnostic tools. *Aliment Pharmacol Ther.* **34**: 11–20. 2011. [[Medline](#)] [[CrossRef](#)]
 12. Larrey D. Drug-induced liver diseases. *J Hepatol.* **32**(Suppl): 77–88. 2000. [[Medline](#)] [[CrossRef](#)]
 13. Ramaiah SK, Apte U, and Mehendale HM. Cytochrome P4502E1 induction increases thioacetamide liver injury in diet-restricted rats. *Drug Metab Dispos.* **29**: 1088–1095. 2001. [[Medline](#)]
 14. Hajovsky H, Hu G, Koen Y, Sarma D, Cui W, Moore DS, Staudinger JL, and Hanzlik RP. Metabolism and toxicity of thioacetamide and thioacetamide S-oxide in rat hepatocytes. *Chem Res Toxicol.* **25**: 1955–1963. 2012. [[Medline](#)] [[CrossRef](#)]
 15. Chilakapati J, Shankar K, Korrapati MC, Hill RA, and Mehendale HM. Saturation toxicokinetics of thioacetamide: role in initiation of liver injury. *Drug Metab Dispos.* **33**: 1877–1885. 2005. [[Medline](#)]
 16. Koen YM, Sarma D, Hajovsky H, Galeva NA, Williams TD, Staudinger JL, and Hanzlik RP. Protein targets of thioacetamide metabolites in rat hepatocytes. *Chem Res Toxicol.* **26**: 564–574. 2013. [[Medline](#)] [[CrossRef](#)]
 17. Sarma D, Hajovsky H, Koen YM, Galeva NA, Williams TD, Staudinger JL, and Hanzlik RP. Covalent modification of lipids and proteins in rat hepatocytes and in vitro by thioacetamide metabolites. *Chem Res Toxicol.* **25**: 1868–1877. 2012. [[Medline](#)] [[CrossRef](#)]
 18. Niki T, Schuppan D, de Bleser PJ, Vrijssen R, Pipeleers-Marichal M, Beyaert R, Wisse E, and Geerts A. Dexamethasone alters messenger RNA levels but not synthesis of collagens, fibronectin, or laminin by cultured rat fat-storing cells. *Hepatology.* **23**: 1673–1681. 1996. [[Medline](#)] [[CrossRef](#)]
 19. Smyth GP, Stapleton PP, Freeman TA, Concannon EM, Mestre JR, Duff M, Maddali S, and Daly JM. Glucocorticoid pretreatment induces cytokine overexpression and nuclear factor-kappaB activation in macrophages. *J Surg Res.* **116**: 253–261. 2004. [[Medline](#)] [[CrossRef](#)]
 20. Muller DN, Shagdarsuren E, Park JK, Dechend R, Mervaaala E, Hampich F, Fiebeler A, Ju X, Finckenberg P, Theuer J, Viedt C, Kreuzer J, Heidecke H, Haller H, Zenke M, and Luft FC. Immunosuppressive treatment protects against angiotensin II-induced renal damage. *Am J Pathol.* **161**: 1679–1693. 2002. [[Medline](#)] [[CrossRef](#)]
 21. Chen ZT, Li SL, Cai EQ, Wu WL, Jin JS, and Zhu B. LPS induces pulmonary intravascular macrophages producing inflammatory mediators via activating NF-kappaB. *J Cell Biochem.* **89**: 1206–1214. 2003. [[Medline](#)] [[CrossRef](#)]
 22. van Golen RF, Reiniers MJ, Olthof PB, van Gulik TM, and Heger M. Sterile inflammation in hepatic ischemia/reperfusion injury: present concepts and potential therapeutics. *J Gastroenterol Hepatol.* **28**: 394–400. 2013. [[Medline](#)] [[CrossRef](#)]
 23. Pervin M, Golbar HM, Bondoc A, Izawa T, Kuwamura M, and Yamate J. Immunophenotypical characterization and influence on liver homeostasis of depleting and repopulating hepatic macrophages in rats injected with clodronate. *Exp Toxicol Pathol.* **68**: 113–124. 2016. [[Medline](#)] [[CrossRef](#)]
 24. Radi ZA, Koza-Taylor PH, Bell RR, Obert LA, Runnels HA, Beebe JS, Lawton MP, and Sadis S. Increased serum enzyme levels associated with kupffer cell reduction with no signs of hepatic or skeletal muscle injury. *Am J Pathol.* **179**: 240–247. 2011. [[Medline](#)] [[CrossRef](#)]
 25. Knittel T, Mehde M, Kobold D, Saile B, Dinter C, and Ramadori G. Expression patterns of matrix metalloproteinases and their inhibitors in parenchymal and non-parenchymal cells of rat liver: regulation by TNF- α and TGF- β 1. *J Hepatol.* **30**: 48–60. 1999. [[Medline](#)] [[CrossRef](#)]
 26. Dubois-Pot-Schneider H, Fekir K, Coulouarn C, Glaise D, Aninat C, Jarnouen K, Le Guével R, Kubo T, Ishida S, Morel F, and Corlu A. Inflammatory cytokines promote the redifferentiation of tumor-derived hepatocyte-like cells to progenitor cells. *Hepatology.* **60**: 2077–2090. 2014; [[CrossRef](#)]. [[Medline](#)]
 27. Kuramochi M, Izawa T, Pervin M, Bondoc A, Kuwamura M, and Yamate J. The kinetics of damage-associated molecular patterns (DAMPs) and toll-like receptors during thioacetamide-induced acute liver injury in rats. *Exp Toxicol Pathol.* **68**: 471–477. 2016. [[Medline](#)] [[CrossRef](#)]
 28. Bolkenius U, Hahn D, Gressner AM, Breitkopf K, Dooley S, and Wickert L. Glucocorticoids decrease the bioavailability of TGF- β which leads to a reduced TGF- β signaling in hepatic stellate cells. *Biochem Biophys Res Commun.* **325**: 1264–1270. 2004. [[Medline](#)] [[CrossRef](#)]
 29. Melgert BN, Olinga P, Van Der Laan JMS, Weert B, Cho J, Schuppan D, Groothuis GMM, Meijer DKF, and Poelstra K. Targeting dexamethasone to Kupffer cells: effects on liver inflammation and fibrosis in rats. *Hepatology.* **34**: 719–728. 2001. [[Medline](#)] [[CrossRef](#)]