



Appendectomy Scar Endometriosis: A Case Report

Mohadeseh Amini¹, Meysam Moghbeli^{2,*}

1. Assistant Professor, Department of surgery, Faculty of Medicine, North Khorasan University of Medical Sciences, Bojnurd, Iran
2. Assistant Professor, Clinical Research Development Center, North Khorasan University of Medical Sciences, Bojnurd, Iran

*** Corresponding Author:**

Meysam Moghbeli, Ph.D
Clinical Research Development Center,
Imam Hasan Hospital, North Khorasan
University of Medical Sciences,
Bojnurd, Iran
Tel: + 98 58 32742087
Fax: + 98 58 32742087
Email: m.moghbeli@nkums.ac.ir

Received: 25 Dec. 2017

Accepted: 10 Mar. 2018

ABSTRACT

Scar endometriosis is one of the rare cases of surgery, which specifically occurs in gynecological surgeries. It is important to do a correct diagnosis in such rare cases to have an efficient treatment. The disease is commonly observed in child-bearing women with clinical manifestations such as acute abdomen or chronic and cyclic pelvic pain. Herein we reported a case of appendectomy scar endometriosis.

KEYWORDS:

Endometriosis, Gynecology, Appendectomy Scar, Iran

Please cite this paper as:

Amini M, Moghbeli M. Appendectomy Scar Endometriosis: A Case Report. *Middle East J Dig Dis* 2018;**10**:114-116. doi: 10.15171/mejdd.2018.100.

INTRODUCTION

Endometriosis is commonly observed in up to 15% of child-bearing and 2-5% of post-menopausal women.¹ Endometriosis of the appendix is rare with a difficult preoperative diagnosis. Pelvic endometriosis involves 0.4% of cases. In rare cases it is observed in extra pelvic, gonads, and skin. One of the common places for the extra pelvic endometriosis is abdominal wall, which is specifically observed in gynecological surgeries. Clinical diagnosis is made by physical examination, biochemical tests, and sonography. It is important to consider scar endometriosis in patients with periodical pains following hormonal changes and gynecological surgeries. In this condition surgical intervention is required for pelvic pain. In the present report we describe a patient with an appendectomy scar endometriosis and report her subsequent management.

CASE REPORT

A 36-year-old woman was referred with bulging and pain in the site of appendectomy scar. Her pain was started since 2 years ago with a rising trend. Sonography revealed a hypoechoic mass of 10×29 mm diameters in the right lower quadrant. Although she was suggested to refer to a gynecologist, she rather preferred to refer to the emergency room because of severe pain. The patient had histories of normal vaginal delivery and appendectomy in 19 and 7 years earlier, respectively.



© 2018 The Author(s). This work is published by Middle East Journal of Digestive Diseases as an open access article distributed under the terms of the Creative Commons Attribution License (<https://creativecommons.org/licenses/by-nc/4.0/>). Non-commercial uses of the work are permitted, provided the original work is properly cited.

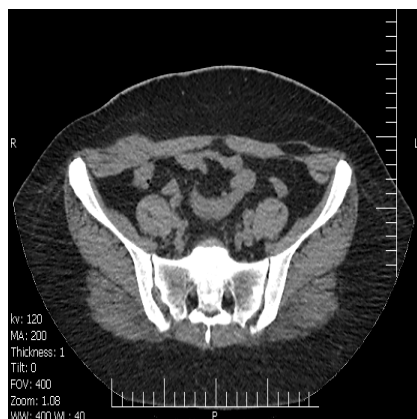

Fig.1: Computed tomogram of the abdomen and pelvis.

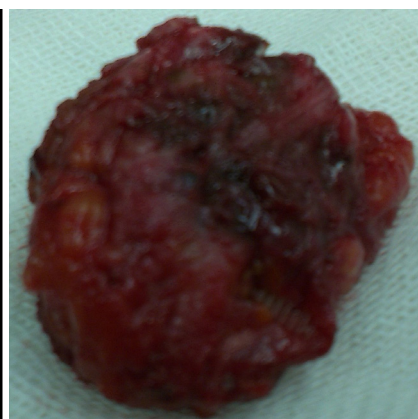


Fig.2: Gross examination of appendectomy scar endometriosis.

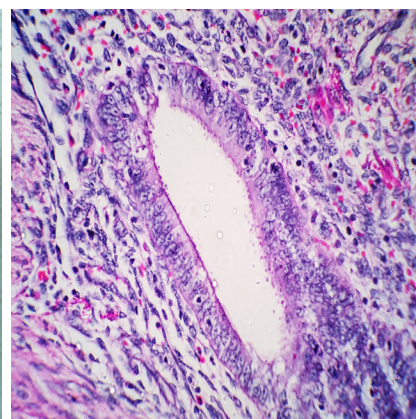


Fig.3: Microscopic examination of appendectomy scar endometriosis.

Moreover, because of severe dysmenorrhea she had undergone Pfannenstiel incision, laparotomy, left ovarian cystectomy, and enterolysis to recover the pelvic adhesions because she was suspected to have malignancy (high CA125) two years ago. She also complained of mild tenderness at the site of appendectomy scar with a sensible mass forcing her to refer to the emergency room. Findings of computed tomography of abdomen and pelvis showed that the mass was located within the abdominal muscles without any connection to the abdominal cavity (figure 1). Gross examination revealed an irregular creamy brownish tissue or fibrosis and firmed to elastic consistency (4.5 cm, figure 2). Microscopic examination also showed a soft tissue lesion/abdominal wall excision/endometriosis in which the endometrial glands were accompanied with related stroma including hemorrhagic areas in a fibrotic stroma (figure 3).

Surgery to excise the mass was performed and chocolate shape secretion areas were also eliminated which were located between the internal muscles.

DISCUSSION

Scar endometriosis is a problem that is observed rarely after gynecological surgeries. Such cases are rare and can happen in caesarian section surgeries. The diagnosis is difficult, which results in misdiagnosis and other gynecological problems.^{2,3} It has been shown that scar endometriosis is commonly observed in the connective tissues of the caesarian section and appendix surgeries

sites.⁴ Endometriosis is also observed in other places such as the muscular rectus after the caesarian surgery.⁵ It can be observed in primary umbilical endometriosis and ligament.⁶⁻⁹ There are several hypotheses explaining the cause of extra uterine endometriosis such as retrograde menstruation, extra pelvic, coelomic metaplasia, induction, embryonic rest, and cellular immunity theory.¹⁰⁻¹² Most of endometriosis cases are located in the ovaries and anterior/posterior cul-de-sac.^{13,14} Gastrointestinal (GI) endometriosis is seen in up to 37% of pelvic endometriosis cases.¹⁵⁻¹⁷ Among the GI endometriosis cases the most common location is recto-sigmoid (72%), and the least common type is the endometriosis of the appendix (3%).¹⁸ Appendiceal endometriosis is a rare type of endometriosis which can be presented as acute appendicitis, appendicular invagination, abdominal colic, and asymptomatic patients.¹⁹ This report was about a case with positive history of pelvic endometriosis. In this report we presented a scar endometriosis in muscular Mc-Burney. The correct diagnosis was based on histopathological features. Although endometriosis is usually asymptomatic, GI endometriosis may cause a wide spectrum of manifestations such as rectal bleeding, pelvic pain, and melena. Laparoscopic appendectomy is currently the first useful method for the patients who suffer from chronic abdominal pain, which is caused by hernias, endometriosis, and ovarian cysts. Hormonal therapies are also effective in recovering the chronic pain in endometriosis.

In conclusion, appendectomy scar endometriosis is a rare disease with difficult preoperative diagnosis, which should be considered especially in child-bearing women with clinical manifestations of an acute abdominal or cyclic pain. Although, our patient had a normal clinical course postoperatively and discharged after five days, post-operative follow-up may be required.

ETHICAL APPROVAL

There is nothing to be declared.

CONFLICT OF INTEREST

The authors declare no conflict of interest related to this work.

REFERENCES

- Saleem A, Navarro P, Munson JL, Hall J. Endometriosis of the appendix: Report of three cases. *Int J Surg Case Rep* 2011;**2**:16-9. doi: 10.1016/j.ijscr.2010.11.001.
- Khamechian T, Alizargar J, Mazoochi T. 5-Year data analysis of patients following abdominal wall endometrioma surgery. *BMC Womens Health* 2014;**14**:151. doi: 10.1186/s12905-014-0151-4.
- Leite GK, Carvalho LF, Korkes H, Guazzelli TF, Kenj G, Viana Ade T. Scar endometrioma following obstetric surgical incisions: retrospective study on 33 cases and review of the literature. *Sao Paulo Med J* 2009;**127**:270-7. doi: 10.1590/S1516-31802009000500005.
- Dainius E, Pankratjevaite L, Bradulskis S, Venskutonis D. Intussusception of the Appendix and Ileum Endometriosis: A Case Report. *Visc Med* 2016;**32**:211-3. doi: 10.1159/000445394.
- Dordevic M, Jovanovic B, Mitrovic S, Dordevic G, Radovanovic D, Sazdanovic P. Abdominal rectus muscle endometriosis after Cesarean section. Extrapelvic localization of endometriosis. *Bratisl Lek Listy* 2010;**111**:345-8.
- Minaidou E, Polymeris A, Vassiliou J, Kondi-Paphiti A, Karoutsou E, Katafygiotis P, et al. Primary umbilical endometriosis: case report and literature review. *Clin Exp Obstet Gynecol* 2012;**39**:562-4.
- Prabhu R, Krishna S, Shenoy R, Thangavelu S. Endometriosis of extra-pelvic round ligament, a diagnostic dilemma for physicians. *BMJ Case Rep* 2013;**2013**. doi: 10.1136/bcr-2013-200465.
- Brătilă E, Ionescu OM, Badiu DC, Berceanu C, Vlădăreanu S, Pop DM, et al. Umbilical hernia masking primary umbilical endometriosis - a case report. *Rom J Morphol Embryol* 2016;**57**:825-9.
- Cattrini B, Eisendle K. Primary umbilical endometriosis: description of a case. *G Ital Dermatol Venereol* 2014;**149**:471-3.
- Matsuura K, Ohtake H, Katabuchi H, Okamura H. Coelomic metaplasia theory of endometriosis: evidence from in vivo studies and an in vitro experimental model. *Gynecol Obstet Invest* 1999;**47 Suppl 1**:18-22. doi: 10.1159/000052855.
- Papavramidis TS, Sapalidis K, Michalopoulos N, Karayanopoulou G, Raptou G, Tzioufa V, et al. Spontaneous abdominal wall endometriosis: a case report. *Acta Chir Belg* 2009;**109**:778-81. doi: 10.1080/00015458.2009.11680536.
- Seli E, Berkkanoglu M, Arici A. Pathogenesis of endometriosis. *Obstet Gynecol Clin North Am* 2003;**30**:41-61. doi: 10.1016/S0889-8545(02)00052-9.
- Jenkins S, Olive DL, Haney AF. Endometriosis: pathogenetic implications of the anatomic distribution. *Obstet Gynecol* 1986;**67**:335-8.
- Emre A, Akbulut S, Yilmaz M, Bozdog Z. Laparoscopic trocar port site endometriosis: a case report and brief literature review. *Int Surg* 2012;**97**:135-9. doi: 10.9738/CC124.1.
- Croom RD 3rd, Donovan ML, Schwesinger WH. Intestinal endometriosis. *Am J Surg* 1984;**148**:660-7. doi: 10.1016/0002-9610(84)90347-7.
- Prystowsky JB, Stryker SJ, Ujiki GT, Poticha SM. Gastrointestinal endometriosis. Incidence and indications for resection. *Arch Surg* 1988;**123**:855-8. doi: 10.1001/archsurg.1988.01400310069011.
- Paramythiotis D, Stavrou G, Panidis S, Panagiotou D, Chatzopoulos K, Papadopoulos VN. Concurrent appendiceal and umbilical endometriosis: a case report and review of the literature. *J Med Case Rep* 2014;**8**:258. doi: 10.1186/1752-1947-8-258.
- Macafee CH, Greer HL. Intestinal endometriosis. A report of 29 cases and a survey of the literature. *J Obstet Gynaecol Br Emp* 1960;**67**:539-55. doi: 10.1111/j.1471-0528.1960.tb09211.x.
- Uncu H, Taner D. Appendiceal endometriosis: two case reports. *Arch Gynecol Obstet* 2008;**278**:273-5. doi: 10.1007/s00404-008-0570-2.