

Despoina Koulenti  
Dirk Vogelaers  
Stijn Blot

## What's new in invasive pulmonary aspergillosis in the critically ill

Received: 6 January 2014  
Accepted: 25 February 2014  
Published online: 20 March 2014  
© Springer-Verlag Berlin Heidelberg and ESICM 2014

D. Koulenti  
2nd Department of Critical Care Medicine, Attikon University Hospital, Athens, Greece

D. Koulenti · S. Blot  
Burns, Trauma and Critical Care Research Centre, The University of Queensland, Brisbane, Australia

D. Vogelaers · S. Blot (✉)  
Department of Internal Medicine, Faculty of Medicine and Health Science, Ghent University, De Pintelaan 185, 9000 Ghent, Belgium  
e-mail: stijn.blot@ugent.be  
Tel.: +32-9-3326216

5]. A recent large retrospective study among ICU patients without traditional risk factors for IPA reported that the most frequent underlying conditions were acute respiratory failure, acute renal failure, COPD, and septicemia/septic shock [3]. The real IPA incidence in ICU patients is difficult to estimate. Previously reported rates vary widely from 0.017 % to as high as 6.9 % [1, 3]. Despite the availability of novel potent antifungals, IPA continues to carry a dreadful prognosis in ICU patients with reported mortality rates of 46–95 %. The variability in incidence and fatality rates can be attributed to case-mix differences and the problematic diagnosis. Additionally, IPA is associated with considerable morbidity and healthcare costs [3]. For non-immunocompromised critically ill patients, an average length of hospital and ICU stay of 27 and 16 days, respectively, was reported, thereby contributing to a substantial cost burden [3].

### Epidemiology, risk factors, and outcomes

Invasive pulmonary aspergillosis (IPA) has been increasingly recognized as an emerging and understudied opportunistic infection in critically ill patients without classic host factors reflecting profound immunosuppression as defined by the European Organization for the Research and Treatment of Cancer/Mycosis Study Group (EORTC/MSG) [1, 2]. Impaired immune response following critical illness and particular underlying conditions put patients at risk of IPA [1]. Predisposing conditions frequently met in intensive care units (ICUs) include chronic obstructive pulmonary disease (COPD), corticosteroid (CS) use, decompensated liver disease, acute respiratory distress syndrome (ARDS), severe sepsis, post-sepsis immunoparalysis, and H1N1 virus infection (especially if CS prior to ICU admission) [1, 3–

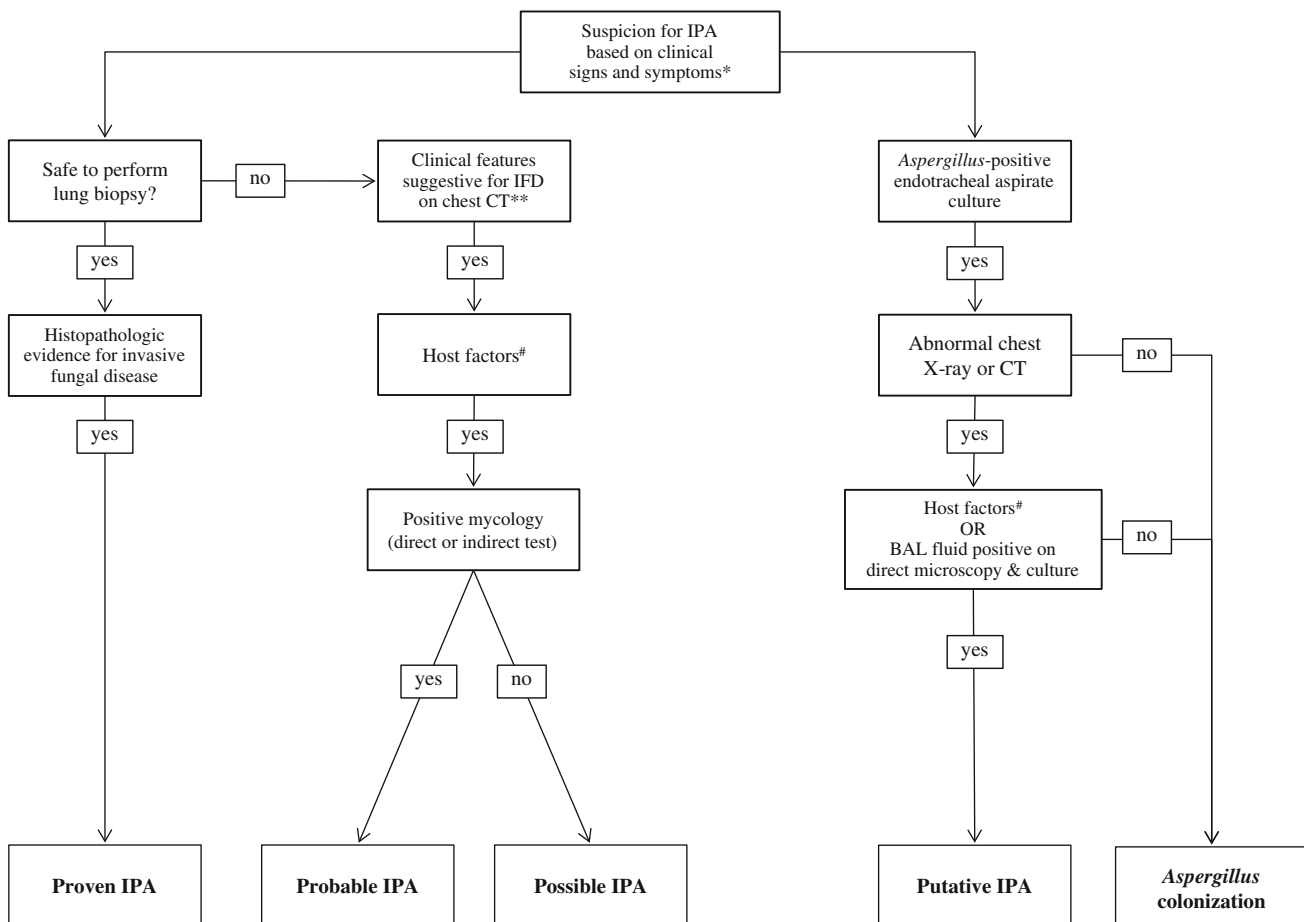
### Clinical diagnosis

Initiation of appropriate antifungal therapy at an early stage of the disease (possible IPA) is associated with improved outcomes in non-critically ill patients [6]. However, in ventilated patients clinical and radiologic presentation of IPA is often non-specific, thereby hampering early detection. The strict EORTC/MSG diagnostic criteria perform poorly in patients without the classic host factors, whereas lung biopsy is frequently contraindicated [1, 2, 7]. In patients with *Aspergillus*-positive respiratory tract samples (1–2 % of ventilated patients), discrimination of colonization from IPA represents a clinical dilemma, as culture results are equivocal [1]. About 20–40 % of these cases may represent IPA, depending on case-mix [1, 7]. A user-friendly clinical algorithm with high negative predictive value can assist clinicians to distinguish colonization from IPA [7, 8]. The clinical

algorithm outperformed the EORTC/MSG criteria and probably encompasses a broader proportion of the true IPA burden in ICUs [7]. Limitations of the algorithm include the necessity of a positive respiratory culture, while IPA may evolve in the absence of such diagnostic incentives. Also, given the high sensitivity and low specificity the clinical value of the algorithm is in excluding rather than diagnosing IPA. Additional use of biomarkers may strengthen the diagnostic certainty [9]. Figure 1 illustrates diagnostic pathways for patients with suspected IPA, according to the EORTC/MSG criteria and the clinical algorithm.

## Biomarkers

Galactomannan (GM) antigen detection in serum is an effective tool for diagnosing IPA in neutropenic patients. Unfortunately, exposure to mold-active antifungals reduces its sensitivity and diverse factors lead to false-positive results [1, 10]. GM is cleared by neutrophils and data on serum GM detection in non-neutropenic patients suggest that it has limited value for IA diagnosis in such patients. However, GM detection in bronchoalveolar lavage fluid (BAL) may be a useful tool for IPA diagnosis in the non-neutropenic population. An ICU cohort consisting mainly



**Fig. 1** Diagnostic pathways for patients suspected of having invasive pulmonary aspergillosis according to EORTC/MSG criteria and the alternative clinical algorithm. *IPA* invasive pulmonary aspergillosis, *IFD* invasive fungal disease, *HIV* human immunodeficiency virus, *BAL* bronchoalveolar lavage, *CT* computed tomography. \*One of the following: fever refractory to at least 3 days of appropriate antibiotic therapy, recrudescence fever after a period of defervescence of at least 48 h while still on antibiotics and without other apparent cause, pleuritic chest pain, pleuritic rub, dyspnea, hemoptysis, worsening respiratory insufficiency in spite of appropriate antibiotic therapy and ventilatory support. \*\*Presence

of at least one of three suggestive signs of fungal infection on chest CT scan (dense, well-circumscribed lesions, with or without a halo-sign, air crescent sign, or cavity). #One of the following: recent history of severe neutropenia (less than 500 neutrophils/mm<sup>3</sup>) for at least 10 days, allogeneic stem cell transplant recipient, prolonged corticosteroids use (at least 0.3 mg/kg/day prednisone equivalent for at least 3 weeks), T cell immunosuppressant treatment during the previous 3 months (e.g., cyclosporine, TNF- $\alpha$  blockers, specific monoclonal antibodies, or nucleoside analogues), inherited severe immunodeficiency

of non-neutropenic patients (78 %), using a cutoff index of 0.5 for GM detection in BAL, reported 88 % sensitivity and 87 % specificity for IPA diagnosis compared to only 42 % sensitivity of serum GM [11]. Interestingly, in 42 % of proven IPA cases BAL culture and serum GM remained negative while BAL-GM was positive [11]. In another cohort of medical critically ill patients that included only 12 % neutropenic patients (all in the control group), BAL-GM showed 100 % sensitivity and 89.4 % specificity for proven IPA cases with a cutoff of at least 1 [12]. Importantly, no differences in the mean BAL-GM levels between control neutropenic and control non-neutropenic patients were observed [12]. Moreover, a study of critically ill COPD patients reported that BAL-GM, compared to both serum GM and lower respiratory tract (LRT) *Aspergillus* isolation, has a better sensitivity in IPA diagnosis. These investigators suggested using a BAL-GM cutoff value of 0.8 [13]. Further studies to assess the utility of BAL-GM in non-immunocompromised critically ill patients are warranted. Also, future development and standardization of methods detecting GM in more accessible respiratory samples, such as tracheal aspirate, would be of great utility for diagnosing IPA.

Other biomarkers offer no advantage compared with GM assays [10].  $\beta$ -D-Glucan (BG) has demonstrated similar diagnostic accuracy as serum GM in a prospective cohort of non-neutropenic critically ill patients [14], but in another study it had lower accuracy than BAL GM [12]. It should be noted that BG is both time-consuming/not user-friendly and gives false-positive results in several conditions including Gram-positive bacteremia, thereby limiting its use in ICUs [10].

Polymerase chain reaction (PCR) for IPA diagnosis seems to be more sensitive than GM assay, but its use is limited because of lack of standardization of the method and, moreover, it has not been specifically tested in ICU patients [1]. The European *Aspergillus* PCR Initiative aims to standardize/validate the procedures [10]. This can add several benefits such as tailoring to species level and providing antifungal susceptibilities [10].

---

## Treatment

As the benefits of timely antifungal treatment seem obvious it is justified to initiate it upon IPA suspicion [6]. Therapy can be continued or stopped according to further diagnostic findings. Voriconazole is the suggested primary therapy for IPA; however, the indication is based in clinical trials that did not include ICU patients [1]. Voriconazole's use may be hampered by several drug interactions as well as renal and liver toxicity [1]. Moreover, voriconazole has a narrow therapeutic index and great intersubject variability of serum levels [1]. Yet,

therapeutic drug monitoring can reduce drug discontinuation rates due to adverse events while improving treatment response [15].

---

## Novel and future therapeutic strategies

Angioinvasion and tissue infarction represent an important hallmark in *Aspergillus* pathogenesis, leading to impaired fungal clearance and preventing delivery of antifungals to the site of infection [16]. Therefore, modulation of angiogenesis represents a potential future therapeutic target for IA [16]. Other promising targets for modulation of regulatory pathways of *Aspergillus* include calcineurin, heat shock protein 90 (Hsp90), and the unfolded protein response (UPR) [10].

However, given the high mortality despite the availability of potent antifungal agents, it appears that any survival benefit is to be expected from an earlier diagnosis rather than new therapeutic regimens. The identification of high-risk profiles for IPA of ICU patients without apparent immunosuppression might help in achieving earlier IPA diagnosis as it would lead to a higher level of suspicion and a lower threshold to perform thorough diagnostic workout for patients at high risk. Epidemiological research aimed at identifying patients at high risk of IPA is ongoing (<http://www.aspicu2.org>).

---

## Conclusion

Until more potent antifungals become available, a more timely diagnosis seems the only opportunity to improve outcomes of IPA. Diagnostic techniques should improve speed, ease-of-use, and diagnostic accuracy. In this regard it will be important to execute the lab test on readily available samples that do not require complex or potentially dangerous procedures. Large, well-designed studies that will assess the diagnostic accuracy of the newer diagnostic techniques in critically ill patients without apparent immunosuppression are essential. Finally, studies that will assess the effectiveness of the current therapeutic options specifically in the ICU population and that will also provide more pharmacokinetic/pharmacodynamic data on antifungal agents in critically ill patients are needed to optimize drug exposure and to minimize adverse events. Enhancing pharmacological insights and individual tailored therapy with use of therapeutic drug monitoring might as well improve survival and deserves further exploration.

**Conflicts of interest** DK and DV have no conflicts of interest. SB received an unrestricted educational grant from Pfizer and MSD, and received fees for speaking services from Pfizer and Gilead.

## References

- Koulenti D, Garnacho-Montero J, Blot S (2014) Approach to invasive pulmonary aspergillosis in critically ill patients. *Curr Opin Infect Dis* 27(2):174–183
- De Pauw B, Walsh TJ, Donnelly JP, Stevens DA, Edwards JE, Calandra T, Pappas PG, Maertens J, Lortholary O, Kauffman CA, Denning DW, Patterson TF, Maschmeyer G, Bille J, Dismukes WE, Herbrecht R, Hope WW, Kibbler CC, Kullberg BJ, Marr KA, Munoz P, Odds FC, Perfect JR, Restrepo A, Ruhnke M, Segal BH, Sobel JD, Sorrell TC, Viscoli C, Wingard JR, Zaoutis T, Bennett JE (2008) Revised definitions of invasive fungal disease from the European Organization for Research and Treatment of Cancer/Invasive Fungal Infections Cooperative Group and the National Institute of Allergy and Infectious Diseases Mycoses Study Group (EORTC/MSG) Consensus Group. *Clin Infect Dis* 46:1813–1821
- Baddley JW, Stephens JM, Ji X, Gao X, Schlamm HT, Tarallo M (2013) Aspergillosis in intensive care unit (ICU) patients: epidemiology and economic outcomes. *BMC Infect Dis* 13:29
- Wauters J, Baar I, Meersseman P, Meersseman W, Dams K, De Paep R, Lagrou K, Wilmer A, Jorens P, Hermans G (2012) Invasive pulmonary aspergillosis is a frequent complication of critically ill H1N1 patients: a retrospective study. *Intensive Care Med* 38:1761–1768
- Vandewoude K, Blot S, Benoit D, Depuydt P, Vogelaers D, Colardyn F (2004) Invasive aspergillosis in ICU patients: analysis of risk factors for acquisition and mortality. *Acta Clin Belg* 59:251–257
- Nivoix Y, Velten M, Letscher-Bru V, Moghaddam A, Natarajan-Ame S, Fohrer C, Lioure B, Bilger K, Lutun P, Marcellin L, Launoy A, Freys G, Bergerat JP, Herbrecht R (2008) Factors associated with overall and attributable mortality in invasive aspergillosis. *Clin Infect Dis* 47:1176–1184
- Blot SI, Taccone FS, Van den Abeele AM, Bulpa P, Meersseman W, Brusselsaers N, Dimopoulos G, Paiva JA, Missel B, Rello J, Vandewoude K, Vogelaers D (2012) A clinical algorithm to diagnose invasive pulmonary aspergillosis in critically ill patients. *Am J Respir Crit Care Med* 186:56–64
- Vandewoude KH, Blot SI, Depuydt P, Benoit D, Temmerman W, Colardyn F, Vogelaers D (2006) Clinical relevance of *Aspergillus* isolation from respiratory tract samples in critically ill patients. *Crit Care* 10:R31
- Blot S, Charles PE (2013) Fungal sepsis in the ICU: are we doing better? Trends in incidence, diagnosis, and outcome. *Minerva Anesthesiol* 79:1396–1405
- Steinbach WJ (2013) Are we there yet? Recent progress in the molecular diagnosis and novel antifungal targeting of *Aspergillus fumigatus* and invasive aspergillosis. *PLoS Pathog* 9:e1003642
- Meersseman W, Lagrou K, Maertens J, Wilmer A, Hermans G, Vanderschueren S, Spriet I, Verbeken E, Van Wijngaerden E (2008) Galactomannan in bronchoalveolar lavage fluid: a tool for diagnosing aspergillosis in intensive care unit patients. *Am J Respir Crit Care Med* 177:27–34
- Acosta J, Catalan M, del Palacio-Perez-Medel A, Lora D, Montejo JC, Cuetara MS, Moragues MD, Pontón J, del Palacio A (2011) A prospective comparison of galactomannan in bronchoalveolar lavage fluid for the diagnosis of pulmonary invasive aspergillosis in medical patients under intensive care: comparison with the diagnostic performance of galactomannan and of (1→3)-beta-D-glucan chromogenic assay in serum samples. *Clin Microbiol Infect* 17:1053–1060
- He H, Ding L, Sun B, Li F, Zhan Q (2012) Role of galactomannan determinations in bronchoalveolar lavage fluid samples from critically ill patients with chronic obstructive pulmonary disease for the diagnosis of invasive pulmonary aspergillosis: a prospective study. *Crit Care* 16:R138
- Acosta J, Catalan M, del Palacio-Pérez-Medel A, Montejo JC, De-La-Cruz-Bértolo J, Moragues MD, Pontón J, Finkelman MA, del Palacio A (2012) Prospective study in critically ill non-neutropenic patients: diagnostic potential of (1,3)-β-D-glucan assay and circulating galactomannan for the diagnosis of invasive fungal disease. *Eur J Clin Microbiol Infect Dis* 31:721–731
- Park WB, Kim NH, Kim KH, Lee SH, Nam WS, Yoon SH, Song KH, Choe PG, Kim NJ, Jang IJ, Oh MD, Yu KS (2012) The effect of therapeutic drug monitoring on safety and efficacy of voriconazole in invasive fungal infections: a randomized controlled trial. *Clin Infect Dis* 55:1080–1087
- Ben-Ami R (2013) Angiogenesis at the mold–host interface: a potential key to understanding and treating invasive aspergillosis. *Future Microbiol* 8:1453–1462