

Molecular Diagnosis of an Ocular Toxocariasis Patient in Vietnam

Nguyen Van De^{1*}, Nguyen Vu Trung², Le Van Duyet² and Jong-Yil Chai³

¹Department of Parasitology, Hanoi Medical University, Hanoi, Vietnam; ²National Hospital of Tropical Diseases, Hanoi, Vietnam;

³Department of Parasitology and Tropical Medicine, Seoul National University College of Medicine, Seoul 110-799, Korea

Abstract: An ocular *Toxocara canis* infection is reported for the first time in Vietnam. A 34-year-old man residing in a village of Son La Province, North Vietnam, visited the National Eye Hospital (NEH) in August 2011. He felt a bulge-sticking pain in his left eye and loss of vision occurred over 3 months before visiting the hospital. The eye examination in the hospital showed damage of the left eye, red eye, retinal fibrosis, retinal detachment, inflammation of the eye tissues, retinal granulomas, and a parasitic cyst inside. A larva of *Toxocara* was collected with the cyst by a medical doctor by surgery. Comparison of 264 nucleotides of internal transcribed spacer 2 (ITS2) of ribosomal DNA was done between our Vietnamese *Toxocara canis* and other *Toxocara* geographical isolates, including Chinese *T. canis*, Japanese *T. canis*, Sri Lankan *T. canis*, and Iranian *T. canis*. The nucleotide homology was 97-99%, when our *T. canis* was compared with geographical isolates. Identification of a *T. canis* infection in the eye by a molecular method was performed for the first time in Vietnam.

Key words: *Toxocara canis*, case report, eye, molecular diagnosis, PCR, ITS2, Vietnam

INTRODUCTION

Humans are an accidental host for *Toxocara*, yet human toxocariasis is seen throughout the world. Human toxocariasis is the parasitic disease caused by the larvae of 2 *Toxocara* species, namely, *T. canis* from dogs and, less commonly, *T. cati* from cats [1]. People become infected by accidental swallowing of dirt that has been contaminated with dog or cat feces containing *Toxocara* eggs, and although it is rare, people can become infected through eating undercooked meat containing *Toxocara* larvae of the paratenic hosts such as cats, foxes, cows, monkeys, pigs, lambs, mice, rats, chickens, pigeons, and ostriches [2-4]. After entering the body, the eggs hatch into larvae that penetrate through walls of the digestive tract, and the larvae then migrate through the organs and tissues of the accidental host (including humans), most commonly the lungs, liver, eyes, brain, and elsewhere.

Toxocariasis is a zoonotic infection that can cause serious illness, including organ damage and eye diseases in humans. There

were 4% ocular toxocariasis among lesions simulating retinoblastoma (pseudoretinoblastoma) patients [5]. Vision loss was reported in 85% of 54 patients with ocular toxocariasis [6]. Kwon et al. [7] reported that *Toxocara* granuloma was found in 52% of ocular toxocariasis patients in Korea. Morais et al. [8] analyzed ocular toxocariasis in which 63.6% occurred as posterior pole granuloma; 9.1% as chronic endophthalmitis; 18.2% as peripheral granuloma, and 9.1% as posterior pole granuloma associated with chronic endophthalmitis. Serology by ELISA was 100% positive among these cases. Symptoms include pallor, fatigue, weight loss, anorexia, fever, headache, rash, cough, asthma, chest tightness, increased irritability, abdominal pain, nausea, and vomiting [9]. Ocular infection is rare compared with visceral larva migrans. In Asian countries including Korea [7] and China [10], ocular larva migrans have been frequently reported, but in Vietnam there was no report of ocular larva migrans patients.

Recently, a *Toxocara* larva was collected from the eye of a Vietnamese man, which was identified by a molecular method as *T. canis*. This is the first report of ocular toxocariasis in Vietnam.

CASE RECORD

The patient was a 34-year old male residing in Phieng Ngua Village, Chieng Xom Commune, Son La City, Son La Province

•Received 6 July 2013, revised 21 August 2013, accepted 4 September 2013.

*Corresponding author (ngvdeyh@gmail.com)

© 2013, Korean Society for Parasitology and Tropical Medicine

This is an Open Access article distributed under the terms of the Creative Commons Attribution Non-Commercial License (<http://creativecommons.org/licenses/by-nc/3.0>) which permits unrestricted non-commercial use, distribution, and reproduction in any medium, provided the original work is properly cited.

of mountainous North Vietnam. In August 2011, he felt a bulge-sticking pain in his left eye and loss of vision occurred over 3 months before visiting the national hospital. A funduscopic examination showed damage of the left eye as red eye, retinal fibrosis, retinal detachment, inflammation of the eye tissues, retinal granulomas, and a parasitic cyst inside and under retina, while his right eye was normal. The rate of eosinophils was 30.2% and the patient was seropositive against *T. canis* antigen in ELISA. A larva of *Toxocara* (about 350 µm in length and 20 µm in width) embedded in the surrounding cyst was collected from his left eye by a medical doctor with surgery.

The larva from this patient was identified by the molecular method using the internal transcribed spacer 2 (ITS-2) of rDNA in comparison with standard strains in GenBank. Comparison of 264 nucleotides in ITS-2 of rDNA between Vietnamese *T. can-*

is (Tcavn) and other strains of *T. canis*, including Chinese *T. canis* (Tca1, Tca2, and Tca3; GenBank no. JF837170.1, JF837169.1, and JN617989.1, respectively), Japanese *T. canis* (Tca5 and Tca8; GenBank no. AB110032.1 and AB110034.1, relatively), Sri Lankan *T. canis* (Tca4; GenBank no. FJ418788.1) and Iranian *T. canis* (Tca7, Tca9, Tca10, and Tca11; GeneBank no. AB743615.1, AB743614.1, AB743617.1, and AB743616.1, relatively), and GenBank (Tca6; GenBank no. Y09489.1) [11-16] (Tables 1, 2; Fig. 1).

The results showed that the nucleotide homologies between the Vietnamese *Toxocara* and *T. canis* from China, Sri Lanka, Japan, Iran, and 1 from GenBank were 97-99%. Phylogenetic tree of Vietnamese *T. canis* and other isoaltes based on ITS-2 nucleotide sequence estimated by neighbor-joining (NJ) method using the MEGA5.1 [17]; Vietnamese *T. canis* was a group

Table 1. Sequencing of internal transcribed spacer (ITS-2) of rDNA of different *Toxocara* species from GenBank compared with the present case

Notation	Origin	Host	Length	Species	GeneBank	Author, year [Reference no.]
Tcavn	Vietnam	Human	264 bp	<i>Toxocara canis</i>	-	This study
Tca1	China	<i>Vulpes</i>	264 bp	<i>Toxocara canis</i>	JF837170.1	Chen et al., 2012 [11]
Tca2	China	<i>Alopex lagopus</i>	264 bp	<i>Toxocara canis</i>	JF837169.1	Chen et al., 2012 [11]
Tca3	China	Unknown	264 bp	<i>Toxocara canis</i>	JN617989.1	Wang et al., 2011 [12]
Tca4	Sri Lanka	Dog	264 bp	<i>Toxocara canis</i>	FJ418788.1	Wickramasinghe et al., 2009 [13]
Tca5	Japan	Dog	264 bp	<i>Toxocara canis</i>	AB110032.1	Ishiwata et al., 2009 [14]
Tca6	Unknown	<i>Canis familiaris</i>	264 bp	<i>Toxocara canis</i>	Y09489.1	Jacobs et al., 2003 [15]
Tca7	Iran	<i>Canis lupus</i>	264 bp	<i>Toxocara canis</i>	AB743615.1	Khademvatan et al., 2013 [16]
Tca8	Japan	Turkey	264 bp	<i>Toxocara canis</i>	AB110034.1	Ishiwata et al., 2009 [14]
Tca9	Iran	<i>Canis lupus</i>	264 bp	<i>Toxocara canis</i>	AB743614.1	Khademvatan et al., 2013 [16]
Tca10	Iran	<i>Canis lupus</i>	264 bp	<i>Toxocara canis</i>	AB743617.1	Khademvatan et al., 2013 [16]
Tca11	Iran	<i>Canis lupus</i>	264 bp	<i>Toxocara canis</i>	AB743616.1	Khademvatan et al., 2013 [16]

Table 2. Percentage of identity of nucleotide of ITS-2 sequences of Vietnamese *Toxocara canis* and others *Toxocara* in GenBank

	Tcavn	Tca1	Tca2	Tca3	Tca4	Tca5	Tca6	Tca7	Tca8	Tca9	Tca10	Tca11
Tcavn		99	99	99	99	99	99	98	98	97	97	98
Tca1	99		100	100	100	100	100	99	99	98	98	98
Tca2	99	100		100	100	100	100	99	99	98	98	98
Tca3	99	100	100		100	100	100	99	99	98	98	98
Tca4	99	100	100	100		100	100	99	99	98	98	98
Tca5	99	100	100	100	100		100	99	99	98	98	98
Tca6	99	100	100	100	100	100		99	99	98	98	98
Tca7	98	99	99	99	99	99	99		98	98	97	98
Tca8	98	99	99	99	99	99	99	98		97	97	97
Tca9	97	98	98	98	98	98	98	98	97		96	97
Tca10	97	98	98	98	98	98	98	97	97	96		97
Tca11	98	98	98	98	98	98	98	98	97	97	97	

Tcavn is Vietnamese *Toxocara*; Tca1, Tca2, Tca3 are Chinese *T. canis* (GenBank no. JF837170.1, JF837169.1, and JN617989.1, respectively), Tca4 is Sri Lanka *Toxocara* (GenBank no. FJ418788.1), Tca5 and Tca8 are Japanese *T. canis* (GenBank no. AB110032.1 and AB110034.1, relatively); Tca7, Tca9, Tca10, and Tca11 are from Iran (GeneBank no. AB743615.1, AB743614.1, AB743617.1, and AB743616.1, relatively), and Tca6 was not clarified (GenBank no. Y09489.1).

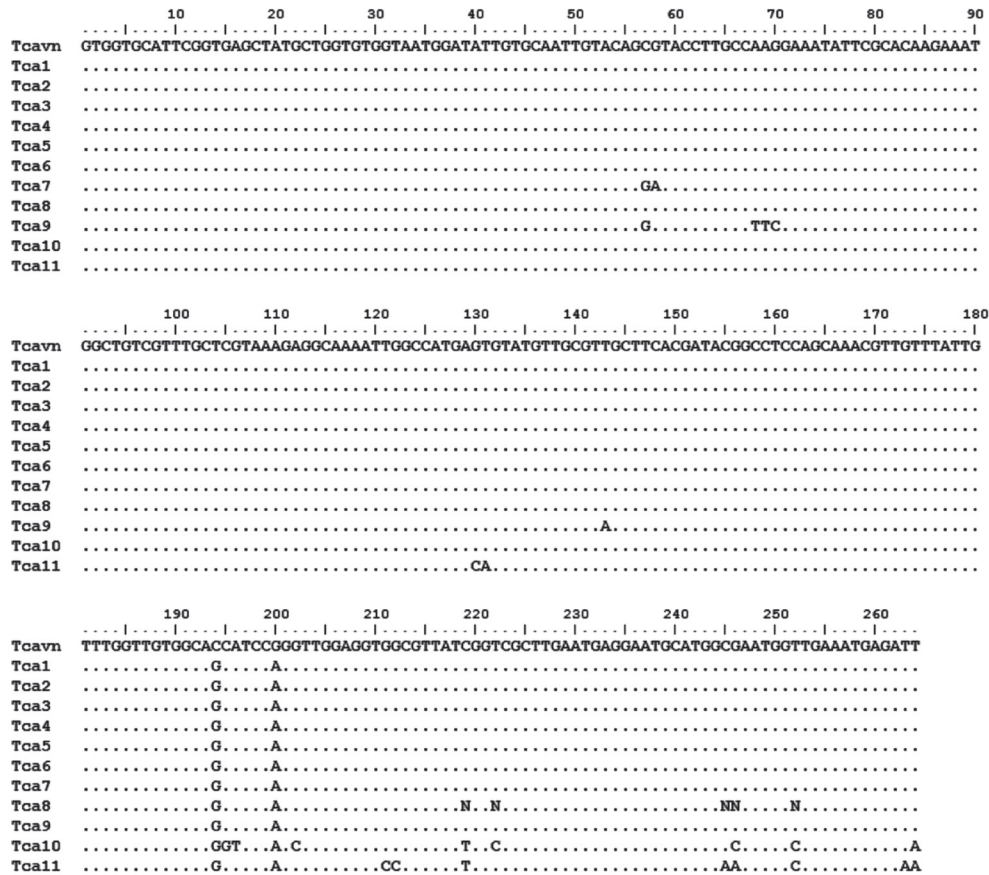


Fig. 1. Comparison of 264 nucleotides of internal transcribed spacer 2 (ITS-2) of rDNA between Vietnamese *Toxocara canis* and other geographical isolates including Chinese *T. canis* (Tca1, Tca2, and Tca3), Japanese *T. canis* (Tca5 and Tca8), Sri Lankan *T. canis* (Tca4), Iranian *T. canis* (Tca7, Tca9, Tca10, and Tca11), and an unknown origin *Toxocara* (Tca6). Note the difference between Vietnamese *T. canis* (Tcavn) and other isolates as shown by their sign nucleotides. Mark (.) is similar to each other in the nucleotide.

together with other *T. canis* isolates in the world (Fig. 2). The *Toxocara* larva collected from the eye of this patient (Vietnam) was identified as *T. canis* by the molecular methods.

DISCUSSION

In Vietnam, in recent years, toxocariasis are increasingly detected by serodiagnosis and there are hundreds of toxocariasis patients diagnosed each year. Based on ELISA test on suspected patients who visited hospitals, a *Toxocara* infection rate of 32.5% was found in the south, 30.2% in the middle, and 33.3% in the northern part of this country (unpublished). The clinical symptoms in these patients were similar to those found in visceral larva migrans. However, ocular larva migrans due to *Toxocara* larvae was never reported in Vietnam, and the present patient is the first ocular case in Vietnam.

The patient's family fed the dog and the patient was always

in contact with his dogs. We regret that we could not perform fecal examination of the dogs. Feeding dogs is very common in Vietnam, especially in rural areas; however, human toxocariasis is widespread in the whole country. Hundreds of toxocariasis patients are detected every year in Vietnam with many complicated symptoms, most of them are visceral larva migrans and some of them might have been ocular larva migrans. In our report, a single larva was detected in the eye of a patient. This case was similar to the report of John and Petri [9] and Review of Optometry Online, Handbook of Ocular Disease Management. The time onset of our patient was longer (over 3 months) compared with the report of Holland and Smith [1], in which loss of vision occurred over days or weeks [1]. The signs and symptoms were damage of the left eye including red eye, retinal fibrosis, retinal detachment, inflammation of the eye tissues, retinal granulomas, and a parasitic cyst inside and under retina, while his right eye was normal. These signs were

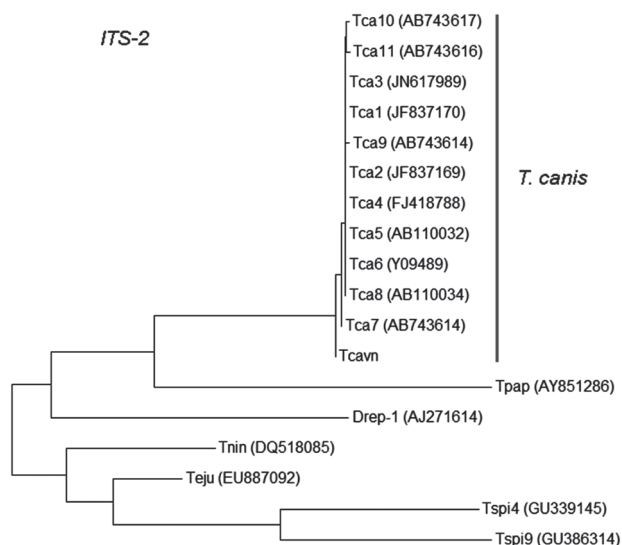


Fig. 2. Phylogenetic tree of Vietnamese *Toxocara canis* and other isolates based on ITS-2 nucleotide sequence as estimated by neighbor-joining (NJ) using MEGA5 (Tamura et al., 2004) [13]. Tcavn=Vietnamese *T. canis*; Tca1, Tca2, and Tca3=Chinese *T. canis*; Tca4=Sri Lankan *T. canis*; Tca5 and Tca8=Japanese *T. canis*; Tca6=unknown *Toxocara*; Tca7, Tca9, Tca10, and Tca11=Iranian *T. canis*; Tpap=*Trichinella papuae* (GenBank no. AY851286); Teju=*Troglodytes cf. juberthiei* (GenBank no. EU887092); Tnin=*Troglodytes ninqa* (GenBank no. DQ518085); Tspi4=Chinese *Trichinella spiralis* (GenBank number GU339145); Tspi9=GenBank *Trichinella* (GenBank no. GU386314); Drep-1=Italian *Dirofilaria repens* (GenBank no. AJ271614).

similar with the report of Stewart et al. [18]. *Toxocara* damage in the eye is permanent and can result in blindness [5,19].

In our study, the larva from an eye of a human was identified as *T. canis* using the molecular method. This is the first time when *T. canis* extracted from the eye of human infections was identified by the molecular method in Vietnam.

ACKNOWLEDGMENTS

We acknowledge the funds supported from the National Foundation for Science and Technology Development (NAFOSTED) of Vietnam (No. 106.12-2011.13 to Nguyen Van De), Ministry of Health Project 2012-2014, and National Eye Hospital (NEH), Hanoi, Vietnam.

Conflict of interest

We have no conflict of interest related to this study.

REFERENCES

- Holland C, Smith HV. *Toxocara*: The Enigmatic Parasite. Wallingford, UK and Cambridge, Massachusetts, USA. CABI Publishing, 2009.
- Choi D, Lim JH, Choi DC, Lee KS, Paik SW, Kim SH, Choi YH, Huh S. Transmission of *Toxocara canis* via ingestion of raw cow liver: a cross-sectional study in healthy adults. *Korean J Parasitol* 2012; 50: 23-27.
- Finsterer J, Auer H. Neurotoxocarosis. *Rev Inst Med Trop Sao Paulo*. 2007; 49: 279-287.
- Noh Y, Hong ST, Yun JY, Park HK, Oh JH, Kim YE, Jeon BS. Meningitis by *Toxocara canis* after ingestion of raw Ostrich liver. *J Korean Med Sci* 2012; 27: 1105-1108.
- Shields CL, Schoenberg E, Kocher K, Shukla SY, Kaliki S, Shields JA. Lesions simulating retinoblastoma (pseudoretinoblastoma) in 604 cases: results based on age at presentation. *Ophthalmology* 2013; 120: 311-316.
- Woodhall D, Starr MC, Montgomery SP, Jones JL, Lum F, Read RW, Moorthy RS. Ocular toxocarosis: epidemiologic, anatomic, and therapeutic variations based on a survey of ophthalmic subspecialists. *Ophthalmology* 2012; 119: 1211-1217.
- Kwon SI, Lee JP, Park SP, Lee EK, Huh S, Park IW. Ocular toxocarosis in Korea. *Jpn J Ophthalmol* 2011; 55: 143-147.
- Morais FB, Maciel AL, Arantes TE, Muccioli C, Allemann N. Ultrasonographic findings in ocular toxocarosis. *Arq Bras Oftalmol* 2012; 75: 43-47.
- John DT, Petri WA. Markell and Voge's Medical Parasitology. 9th ed. St. Louis, Missouri, USA. Saunders Elsevier, 2006.
- Zhou M, Chang Q, Gonzales JA, Chen Q, Zhang Y, Huang X, Xu G, Wang W, Jiang R. Clinical characteristics of ocular toxocarosis in Eastern China. *Graefes Arch Clin Exp Ophthalmol* 2012; 250: 1373-1378.
- Chen J, Zhou DH, Nisbet AJ, Xu MJ, Huang SY, Li MW, Wang CR, Zhu XQ. Advances in molecular identification, taxonomy, genetic variation and diagnosis of *Toxocara* spp. *Infect Genet Evol* 2012; 12: 1344-1348.
- Wang C. *Toxocara canis* internal transcribed spacer 1, partial sequence; 5.8S ribosomal RNA gene, complete sequence; and internal transcribed spacer 2, partial sequence. GenBank no. JN61-7989.1 (<http://www.ncbi.nlm.nih.gov/nuccore/JN617989.1>). 2011.
- Wickramasinghe S, Yatawara L, Rajapakse RP, Agatsuma T. *Toxocara vitulorum* (Ascaridida: Nematoda): mitochondrial gene content, arrangement and composition compared with other *Toxocara* species. *Mol Biochem Parasitol* 2009; 166: 89-92.
- Ishiwata K, Shinohara A, Yagi K, Horii Y, Tsuchiya K, Nawa Y. *Toxocara canis* genes for internal transcribed spacer 2, 5.8S ribosomal RNA, partial sequence, isolate: Tnj1. GenBank: AB110032.1 (<http://www.ncbi.nlm.nih.gov/nuccore/AB110032.1>). 2009.
- Jacobs DE, Gasser RB, Chilton NB. *Toxocara canis* rRNA gene, partial. 2003. GenBank no. Y09489.1 (<http://www.ncbi.nlm.nih.gov/nuccore/Y09489.1>).

- nih.gov/nuccore/Y09489.1). 2003.
16. Khademvatan S, Rahim F, Tavalla M, Abdizadeh R, Hashemitarbar M. PCR-based molecular characterization of *Toxocara* spp. using feces of stray cats: a study from Southwest Iran. PLoS One 2013; 8: e65293.
 17. Tamura K, Nei M, Kumar S. Prospects for inferring very large phylogenies by using the neighbor-joining method. Proc Natl Acad Sci USA 2004; 101: 11030-11035.
 18. Stewart JM, Cubillan LD, Cunningham ET. Prevalence, clinical features and causes of vision loss among patients with ocular toxocariasis. Retina 2005; 25: 1005-1013.
 19. Arevalo JE, Espinoza JV, Arevalo EA. Ocular toxocariasis. J Pediatr Ophthalmol Strabismus 2013; 50: 76-86.

