

CASE REPORT

Bilateral Mondor's disease in chikungunya virus infection

Sarah Djebara¹, Liesbet Henckaerts^{2,3,†} and Peter Vanbrabant^{*,1,2}

¹Center for Infectious Diseases, Polyclinic Department, Queen Astrid Military Hospital, Brussels, Belgium, ²Department of General Internal Medicine, University Hospitals Leuven, Leuven, Belgium, ³Department of Microbiology, Immunology and Transplantation, KU Leuven, Leuven, Belgium

*Correspondence address. Center for Infectious Diseases, Polyclinic Department, Queen Astrid Military Hospital, Bruynstraat 1, 1120 Neder-Over-Heembeek, Brussels, Belgium. Tel: +32-2-4432064; Fax: +32 16 34 42 30; E-mail: p_vanbrabant@yahoo.com

Abstract

Chikungunya virus (CHIKV) is an arthropod-borne virus that is transmitted by *Aedes* mosquitoes, and its main features are high fever and (debilitating) arthritis. Infection with CHIKV, as well as other viruses, has been associated with hypercoagulable states and may be linked with the development of venous thrombosis. In fact, the development of deep venous thrombosis has been described in CHIKV infection. We present a case of superficial thrombophlebitis of the thoracic wall, known as Mondor's disease, associated with CHIKV infection. To our knowledge, this probable association has never been described before.

INTRODUCTION

Mondor's disease (MD) is a rare, benign and spontaneously resolving condition characterized by thrombophlebitis involving the superficial veins. In 1939, Henri Mondor first described a sub-acute subcutaneous 'trunculitis' or superficial thrombophlebitis of the veins of the anterolateral thoracic wall [1]. Although Mondor and most other authors classify the characteristic cord-like structure as thrombosis of the superficial veins, some other factors, such as lymphangitis, retractile scarring of the fascia and a combination of factors, have been suspected to play a role in the underlying mechanism [2].

Chikungunya virus (CHIKV) is an arthropod-borne virus that is transmitted by *Aedes* mosquitoes, and its main features are high fever and arthritis [3]. Although several viruses have been implicated in the pathogenesis of deep venous thrombosis and pulmonary embolism, no link has ever been reported between CHIKV and superficial venous thrombosis or MD.

CASE REPORT

A 44-year-old Caucasian man, residing in Kinshasa (Democratic Republic of the Congo), with a past medical history of psoriasis, pneumonia, malaria and osteoarthritis, presented at an outpatient clinic with fever (39.6°C) and generalized joint pain. Clinical examination revealed a diffuse erythematous rash, but he was otherwise normal. He tested negative for malaria, and because of a known outbreak, chikungunya was suspected and treated symptomatically with acetaminophen and ibuprofen. Two weeks later, the patient complained of right-sided thoracic and left-sided infra-axillary pain. Clinical examination revealed a painful cord-like palpable induration on both sides of the chest (Fig. 1). Duplex ultrasound examination confirmed bilateral superficial thrombophlebitis (Figs 2 and 3). Subcutaneous administration of the low-molecular-weight heparin (LMWH) nadroparin was started at a dosage of 5700 U/day, and the patient was repatriated to Belgium and seen at our outpatient

†Liesbet Henckaerts, <http://orcid.org/0000-0003-2880-1400>

Received: May 25, 2020; Revised: June 25, 2020; Accepted: June 28, 2020

© The Author(s) 2020. Published by Oxford University Press. All rights reserved. For Permissions, please email: journals.permissions@oup.com

This is an Open Access article distributed under the terms of the Creative Commons Attribution Non-Commercial License (<http://creativecommons.org/licenses/by-nc/4.0/>), which permits non-commercial re-use, distribution, and reproduction in any medium, provided the original work is properly cited. For commercial re-use, please contact journals.permissions@oup.com

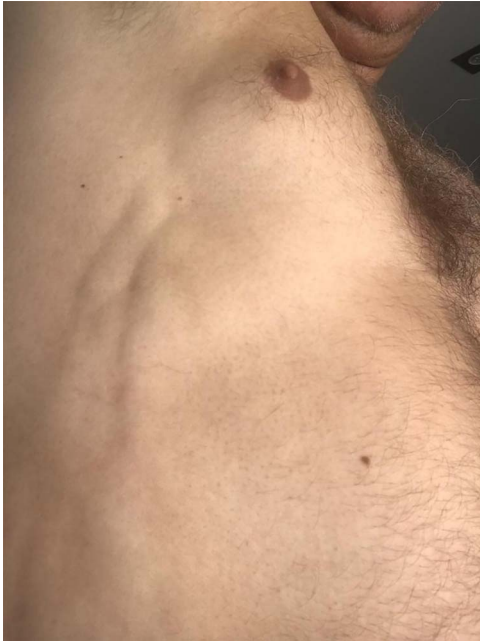

Figure 1: Right-sided painful cord-like palpable induration.

clinic. Treatment was continued with an intermediate dose of the LMWH enoxaparin (60 mg) and a nonsteroidal anti-inflammatory drug. Laboratory tests confirmed the diagnosis of chikungunya (IgM: positive; IgG titer > 1/160).

Six weeks later, the patient still had migratory pauciarticular arthritis (that is, arthritis of the shoulders, hips and knees) and had difficulty walking. The induration on the left anterior axillar line had disappeared, and the induration on the right mid-axillar line had almost completely regressed. Further investigations revealed that the patient was positive for antinuclear antibodies (titer, 1/380) without specificity; however, rheumatoid factor and

anticyclic citrullinated peptide were not detected. Only symptomatic treatment was administered, and after 6 months of follow-up, the patient no longer had arthritis.

DISCUSSION

Our patient had a confirmed diagnosis of chikungunya that was associated with bilateral MD. Chikungunya infection is characterized by abrupt onset of fever, arthralgia/arthritis, myalgia and rash. The usual duration of acute illness is 7–10 days. However, joint symptoms can persist for several months or years, sometimes necessitating anti-inflammatory drugs. Complications are rare, and include uveitis, retinitis, myocarditis, hepatitis, nephritis, bullous skin lesions, hemorrhage, meningoencephalitis, myelitis, Guillain-Barré syndrome and cranial nerve palsies. Deep venous thrombosis has been reported in patients with chikungunya [4]. However, to the best of our knowledge, the present case is the first reported one of chikungunya infection associated with superficial thrombophlebitis of the chest wall, suggestive of MD.

MD can broadly be categorized into three different entities based on the site of the lesion: original MD affecting the anterolateral thoracoabdominal wall, penile MD and axillary web syndrome complicating axillary surgery [5]. The incidence and prevalence of the disease are unclear, but it commonly affects middle-aged women, with a female: male ratio ranging from 9: 1 to 14: 1 [5]. Unlike classical superficial thrombophlebitis, MD of the chest wall is not accompanied by cutaneous inflammation. Thus, physical examination must be complemented with venous Doppler ultrasound, when necessary, for diagnosis.

The most important step after the diagnosis of MD is distinguishing between primary MD (which accounts for 45% of all MD cases) and secondary disease, in which a predisposing factor or underlying disease is present. Most secondary cases seem to be linked to trauma (22%) or are iatrogenic (20%). Association with breast cancer is less frequent (5%) [5], but MD can be the first manifestation of breast cancer, even in male patients [6,7].

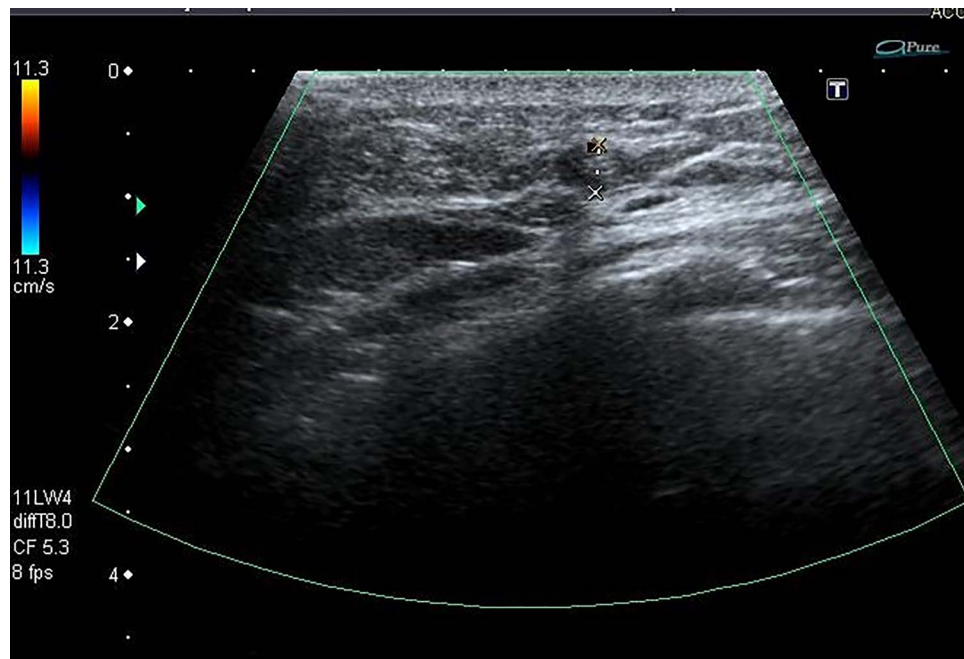

Figure 2: Duplex ultrasound: thrombosed right-sided superficial thoracic vein (transverse view).

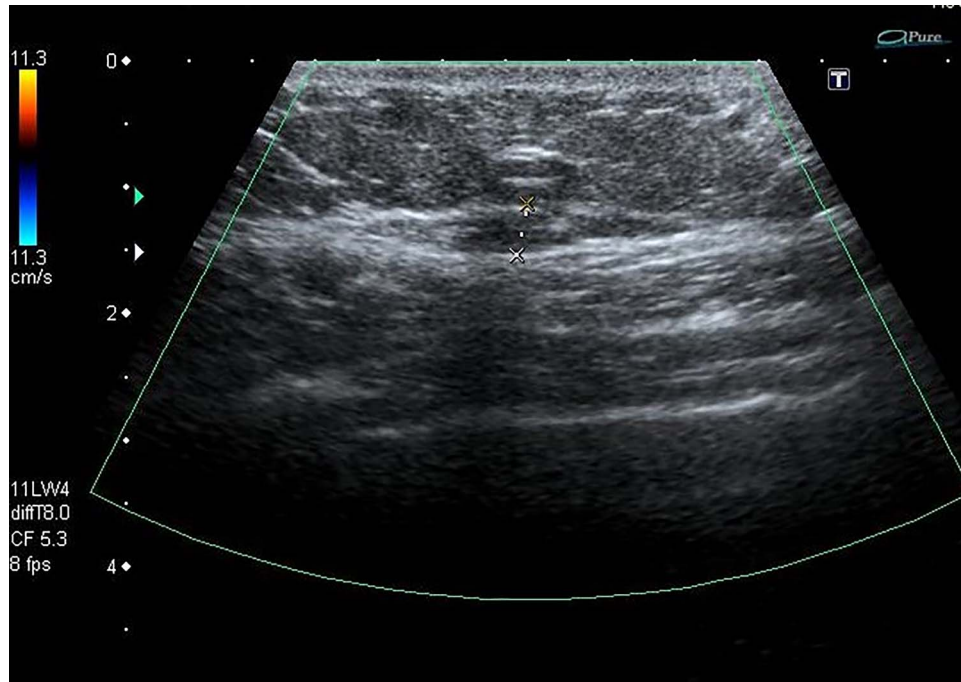


Figure 3: Duplex ultrasound: thrombosed right-sided superficial thoracic vein (longitudinal view).

Table 1: Predisposing factors and underlying diseases associated with MD.

Predisposing factors	Possible underlying diseases
Breast surgery/biopsy	Hypercoagulable states (protein C deficiency, protein S deficiency, anticardiolipin antibodies, hyperviscosity syndrome)
Mammary inflammation/infection	Infection (filariasis, rickettsiosis, etc.)
Vigorous upper extremity exercise	(Breast) malignancy
Tight clothes or bandages	Rheumatoid arthritis
Intravenous drug use, intravenous catheters	Vasculitis (Behçet's disease, giant cell arteritis, polyarteritis nodosa) and other vascular diseases (Buerger disease)
Pendulous breasts	Adenopathy, lymphangitis
Trauma (injury, shaving)	
Pregnancy	

Depending on the presence of other signs and symptoms, the possibility of infection, hypercoagulability, systemic metastasis, hyperviscosity syndrome, vasculitis or other rheumatic diseases should be considered. The other predisposing factors reported in the literature are summarized in Table 1. In cases of penile MD, tests for syphilis and other sexually transmitted infections are recommended.

Idiopathic MD tends to resolve spontaneously in a few weeks, but treatment with NSAIDs may be required to relieve the pain. Some authors have reported the effectiveness of anticoagulation treatment in the acute phase of MD [5]. Additionally, the administration of LMWH is an option, which was found to be effective in the present case. In secondary MD, the priority is treating the underlying cause or predisposing factor.

The prognosis of primary MD is excellent, as the symptoms can be resolved within 4 to 8 weeks. Recurrence is possible, but the long-term prognosis has not been studied extensively. In secondary MD, the prognosis depends on the underlying condition.

A relationship between certain viruses (such as HIV and hepatitis) and deep vein thrombosis or pulmonary embolism has been established [8]. Several mechanisms seem to play a role in

this relationship, for example, increased levels of procoagulant factors, direct endothelial injury with increased expression of tissue factors, the production of procoagulant microparticles and increased platelet adhesion [9]. In CHIKV infection, the occurrence of deep vein thrombosis has also been described [4,8] and linked to the combination of endothelial injury caused by the inflammatory process and immobilization due to severe joint pain. The same mechanisms may play a role in the development of MD, but its probable association with chikungunya infection has not been described before.

This is the first report to describe the probable association between MD and chikungunya infection. MD is a benign, self-limiting condition, characterized by thrombophlebitis of the superficial veins of the thoracic wall. The condition is mostly idiopathic or occurs in the presence of a benign provoking factor, but a variety of underlying conditions should also be considered.

CONFLICT OF INTEREST STATEMENT

The authors have no conflict of interest to declare.

FUNDING

The authors received no specific funding for this work.

ETHICAL APPROVAL

No ethical approval is required at our institution for case reports.

CONSENT

Written informed consent was obtained from the patient and is available on request.

GUARANTOR

Peter Vanbrabant, MD.

REFERENCES

- Mondor H. Tronculaire sous-cutanée subaiguë de la paroi thoracique antérolatérale. *Mem Acad Chir* 1939;**65**: 258–71.
- Ichinose A, Fukunaga A, Terashi H et al. Objective recognition of vascular lesions in Mondor's disease by immunohistochemistry. *J Eur Acad Dermatol Venereol* 2008;**22**:168–73. doi: [10.1111/j.1468-3083.2007.02358.x](https://doi.org/10.1111/j.1468-3083.2007.02358.x).
- Thiberville SD, Moyen N, Dupuis-Maguiraga L et al. Chikungunya fever: epidemiology, clinical syndrome, pathogenesis and therapy. *Antiviral Res* 2013;**99**:345–70. doi: [10.1016/j.antiviral.2013.06.009](https://doi.org/10.1016/j.antiviral.2013.06.009).
- Marques MA, ADAMI de SaFP, Lupi O, Brasil P, von Ristow A. Deep venous thrombosis and chikungunya virus. *J Vasc Bras* 2017;**16**:60–62. DOI: [10.1590/1677-5449.009616](https://doi.org/10.1590/1677-5449.009616)
- Amano M, Shimizu T. Mondor's disease: a review of the literature. *Intern Med* 2018;**57**:2607–12. doi: [10.2169/internalmedicine.0495-17](https://doi.org/10.2169/internalmedicine.0495-17).
- Levi L, Baum M. Mondor's disease as a presenting symptom of breast cancer. *Br J Surg* 1987;**74**:700. doi: [10.1002/bjbs.1800740817](https://doi.org/10.1002/bjbs.1800740817).
- Quéhé P, Saliou A-H, Guias B, Bressolette L. Mondor's disease report on three cases and literature review. *J Mal Vasc* 2009;**34**:54–60. doi: [10.1016/j.jmv.2008.10.007](https://doi.org/10.1016/j.jmv.2008.10.007).
- Ramacciotti E, Agati LB, Aguiar VCR et al. Zika and Chikungunya virus and risk for venous thromboembolism. *Clin Appl Thromb Hemost* 2019;**25**:1–5. doi: [10.1177/1076029618821184](https://doi.org/10.1177/1076029618821184).
- Goeijenbier M, van Wissen M, van de Weg C et al. Review: viral infections and mechanisms of thrombosis and bleeding. *J Med Virol* 2012;**84**:1680–96. doi: [10.1002/jmv.23354](https://doi.org/10.1002/jmv.23354).