

Endoscopic ultrasound-guided fine-needle aspiration from ascites and peritoneal nodules: A scoping review

Vishal Sharma, Surinder Singh Rana, Sobur Uddin Ahmed, Sonali Guleria¹, Ravi Sharma, Rajesh Gupta²

Departments of Gastroenterology and ²Surgery, Postgraduate Institute of Medical Education and Research, ¹Department of Botany, DAV College, Chandigarh, India

ABSTRACT

The peritoneum is involved in many diseases such as primary malignancy (mesothelioma), infectious disease (tuberculosis), and disseminated malignancy (peritoneal carcinomatosis). The peritoneal disease may manifest as ascites and/or peritoneal masses or nodules. Endoscopic ultrasound (EUS), due to its ability to provide high-resolution images, has revolutionized the imaging and diagnosis of pancreaticobiliary diseases among other gastrointestinal conditions. EUS can not only help in imaging of various lesions close to the gastrointestinal lumen but also aspirate/biopsy them. We conducted a systematic search to identify published literature on the value of EUS in detection and diagnosis of peritoneal disorders. This review aims to summarize the available literature on the use of EUS-guided paracentesis and fine-needle aspiration from peritoneal nodules.

Key words: Endosonography, fine-needle aspiration, malignancy, peritoneum, tuberculosis

INTRODUCTION

The peritoneum is the lining membrane of the abdominal cavity which can be involved by a number of benign as well as malignant diseases.^[1] The diseases involving the peritoneum may originate from the peritoneum or may be secondary, having spread from other sites.^[1,2] Peritoneal carcinomatosis refers to the involvement of the peritoneum by metastasis from various other primary sites. Peritoneal dissemination may result from one of the multiple pathways: hematological spread, contiguous involvement, lymphatic spread or transperitoneal surface spread.^[3] It is important to recognize the presence of peritoneal carcinomatosis

and to discriminate it from other causes of peritoneal diseases, especially benign treatable causes.

The presence of peritoneal carcinomatosis has implications in the management of patients with cancers as these patients have grave prognosis compared to patients without peritoneal involvement.^[4] Peritoneal involvement is usually associated with the presence of ascites in most patients but can also occur without ascites.^[5] Certain peritoneal diseases such as pseudomyxoma peritonei, tubercular involvement,

This is an open access article distributed under the terms of the Creative Commons Attribution-NonCommercial-ShareAlike 3.0 License, which allows others to remix, tweak, and build upon the work non-commercially, as long as the author is credited and the new creations are licensed under the identical terms.

For reprints contact: reprints@medknow.com

How to cite this article: Sharma V, Rana SS, Ahmed SU, Guleria S, Sharma R, Gupta R. Endoscopic ultrasound-guided fine-needle aspiration from ascites and peritoneal nodules: A scoping review. *Endosc Ultrasound* 2017;6:382-8.

Access this article online

Quick Response Code:



Website:

www.eusjournal.com

DOI:

10.4103/eus.eus_96_17

Address for correspondence

Dr. Surinder Singh Rana, Department of Gastroenterology, Postgraduate Institute of Medical Education and Research, Chandigarh - 160 012, India. E-mail: drsurinderrana@gmail.com

Received: 2017-03-06; **Accepted:** 2017-08-28

peritoneal mesothelioma, and lymphomatous involvement can closely mimic peritoneal carcinomatosis and may be difficult to differentiate.^[3,6] Cytological examination of fluid obtained by abdominal paracentesis is an important tool in the diagnosis of peritoneal carcinomatosis. While repeating the cytological analysis on at least three occasions helps in achieving a diagnosis in a vast majority of patients, occasionally the diagnosis may not be forthcoming even after repeating it multiple times.^[7] Furthermore, in the absence of ascites, this simple bedside investigation is not feasible.

Radiological evaluation of peritoneal disease may involve the use of ultrasound, computed tomography (CT), or magnetic resonance imaging (MRI). Certain features on imaging are suggestive of peritoneal carcinomatosis and include omental nodularity and caking, mesenteric invasion, peritoneal nodules or masses, visceral scalloping, etc. However, none of these is diagnostic, and most of these can occur in other causes including pseudomyxoma peritonei and tuberculosis.^[3,6] In a recent meta-analysis comparing the diagnostic performance of CT and MRI for detection of peritoneal metastasis, the performance was similar for both, but CT was recommended as the preferred modality due to the robustness of the data.^[8]

Often even after multiple radiological and cytological investigations, peritoneal carcinomatosis may still not be confirmed in a subset of patients with malignancy, and these patients may be wrongly categorized into the resectable group. In these patients, the presence of peritoneal deposits is revealed only on laparotomy and therefore, the resective surgery is abandoned. Therefore, it is of paramount importance to diagnose peritoneal carcinomatosis with a fair degree of certainty as positive diagnosis can avoid an unnecessary laparotomy and help in accurately prognosticating the patient. Furthermore, it is important to recognize and exclude alternative benign treatable causes of ascites (like tuberculosis) in patients with an underlying malignancy and hence that a resectable patient is not denied surgical treatment.

In this regard, endoscopic ultrasound (EUS) has become an important tool for evaluation of abdominal malignancies, especially pancreatic and biliary malignancies.^[9] Not only does EUS provide information about the local disease and vascular involvement but it can also help in detection of ascites. Furthermore, EUS provides an additional benefit of the ability to obtain

material for cytological analysis and thereby confirm the diagnosis. It performs better in the detection of ascites when compared to CT and correlates best with intra-operative findings.^[10] However, data on the utility of EUS-guided fine-needle aspiration (FNA) for paracentesis and of peritoneal nodules are limited. This paper reviews the published literature on the use of EUS-FNA for abdominal paracentesis and evaluation of peritoneal nodules.

MATERIALS AND METHODS

We performed a PubMed search with following keywords: EUS and peritoneum, EUS and peritoneal nodules, EUS and paracentesis, EUS and ascites and EUS and omentum. The search strategy was using these terms in MeSH or all fields. Of the results identified in PubMed, we included original research papers and cases series (at least 3 cases) which reported about the use of EUS for abdominal paracentesis and EUS-FNA for the evaluation of peritoneal nodules. The search was done on February 28, 2017. We also searched the bibliography of included papers for additional titles. We excluded nonEnglish papers, reviews and papers which were unrelated to the issue at hand or were published only as abstracts. In case of multiple papers from a single center, duplicates were excluded. On predesigned tabular format, we recorded the details of the records, namely, the origin of papers, the indication for the procedure, the technical details of the procedure like the type of needle, number of passes, site of FNA (peritoneal nodules/omentum), use of suction or not, the presence of onsite pathologist, etc. and also the technical success and diagnostic success of the procedure. The complications associated with the procedure were also recorded. The literature mostly consisted of a limited number of reports and most of which were small case series.

RESULTS

From the PubMed search, we got 227 results which were seen by two different authors and all reports in the English language, which reported more than three or more patients with EUS-guided paracentesis or FNA of peritoneal nodules were included.

For the EUS-guided paracentesis, we included 5 reports that described the utility of EUS-guided paracentesis [Table 1].^[11-15] These reports were from USA (4) and Japan (1). For EUS-guided

Table 1. Major studies reporting about endoscopic ultrasound-guided paracentesis

Reference	Location	Study design	Patient population	Previously suspected PC or ascites on imaging	Period	Age (years)	Gender (male/female)	Needle	Onsite cytologist	Route	Amount of fluid aspirated (mean; range) (mL)	Diagnosis on EUS	Actual diagnosis	Complications
Nguyen and Chang 2001*	USA	Retrospective study	31 patients with ascites and paracentesis	PC: None of 79 who underwent CT Ascites: 14 of 79	March 1994 to October 1997	NA	NA	NA	NA	NA	7.9 (1-40)	Malignant: 5 Benign: 26	NA	None
Kaushik <i>et al.</i> , 2006**	USA	Prospective case series	25 of 34 patients with ascites	14 of 21 who underwent CT	November 2005 to March 2005	68.56	16/9	22 or 25 G	NA	NA	6.8 (1-20)	Malignant: 16 Benign: 9	Malignant: 17 benign: 8	Peritonitis: 1
Dewitt <i>et al.</i> , 2007***	USA	Retrospective study	60 patients with EUS paracentesis	Ascites: 31 (51%)	January 1997 to July 2005	67 (30-89)	33/27	22 G	Yes	TG: 55 TD: 5	8.9 (1-40)	Benign: 42 Malignant or atypical: 18	Benign: 15 Malignant: 45	Fever: 2
Wardeh <i>et al.</i> , 2011****	USA	Retrospective study	101 patients with previous or concurrent diagnosis of malignancy	6 of 9 who underwent CT	January 2003 to February 2006	68.3 (33-94)	54/47	22 or 19 G	No	NA	<10 in all cases	Malignant: 19 Benign: 74 Suspicious: 4	3 false negatives identified, No false positive	None
Suzuki <i>et al.</i> , 2014*****	Japan	Retrospective study	11 patients with past cancer and EUS paracentesis	4 of 11	January 2001 to April 2011	66.4 (50-78)	7/4	22 G spring loaded automated	NA	NA	14.1 (0.5-38)	Malignant: 6 Benign: 5	NA	None

*Of those negative for malignancy, 7 underwent surgery and 5 had peritoneal carcinomatosis, i.e., 5 of these 7 had false negative cytology, **33 patients underwent EUS paracentesis, 8 with negative cytology were excluded as they did not undergo surgery and no definitive diagnosis is available. Of those with benign cytology on ascites FNA, 6 had underlying malignancy, ***EUS FNA of peritoneal nodules was not done but in 3 of 7 patients classified as benign who underwent surgery the surgical biopsy of peritoneal nodules suggested malignancy. The "actual diagnosis" is based on overall basic diagnosis in included patients and not the diagnosis of ascitic cytology or peritoneal histology. ****Of the six with negative ascitic cytology who underwent peritoneal biopsy one was positive for malignancy; no surgical correlation, *****Study included only the patients where a special automated spring loaded needle was used. PC: Peritoneal carcinomatosis, EUS: Endoscopic ultrasound, NA: Not available, CT: Computed tomography, FNA: Fine-needle aspiration, TG: Transgastric, TD: Transduodenal

FNA of peritoneal nodules, we included 4 case series [Tables 2 and 3].^[5,16-18] The case series have been reported from USA (2), India and Turkey (1 each). Multiple other reports have described the use of EUS for paracentesis and for FNA from peritoneal nodules and omentum but have not been included as they report about two or less patients.^[19-25]

Indications

The major indications which have been reported in the literature for EUS-FNA for abdominal paracentesis include cytological evaluation of peritoneal fluid in patients with underlying malignancy. Most of these series report that ascites was diagnosed only on EUS and in a majority of patients CT had failed to identify ascites and therefore, only EUS-guided paracentesis was feasible.^[14] In some reports, EUS was done primarily for the purpose of staging of suspected malignancy or for the staging of malignancy or unsuccessful percutaneous paracentesis or other reasons.^[12,13] Occasional case reports also describe the use of EUS paracentesis for therapeutic purposes when ascites could not be tapped percutaneously.^[24]

The use of EUS-FNA from peritoneal nodules has been reported in patients with peritoneal anomaly detected on other imaging or when detected during EUS done for the evaluation of undiagnosed ascites.^[5,17-18]

Technique

Endoscopic ultrasound-guided paracentesis

The EUS-guided abdominal paracentesis may be utilized in certain situations like the presence of small amount of ascites which is not detectable on cross-sectional imaging or when the percutaneous ascitic tap is not possible. EUS-paracentesis is usually done under the cover of periprocedural antibiotics using 22 gauge needle (although 25G needle has also been used).^[13] The EUS needle is passed through the transgastric or transduodenal route

until the tip is seen to be in the ascites [Figure 1]. Ascites is usually visualized as perigastric or periduodenal anechoic space which may be triangular or irregular.^[14] Care is taken to avoid any intervening vessels or any area involved by malignancy to avoid contamination of the sample and peritoneal seeding.^[14] Once the needle is in the peritoneal fluid, the stylet is removed and sample taken with the use of suction. During the procedure, minor adjustments like slight withdrawal may be needed to keep the needle in the fluid part as the amount of fluid diminishes.^[14] Repeat passes may be needed in event of clogging of the needle. The sample may be sent for cytological evaluation and other studies as required (biochemical analysis for serum-ascites albumin gradient, ascitic adenosine deaminase levels, etc). Use of an automated spring loaded needle has also been reported.^[15]

Endoscopic ultrasound-guided fine needle aspiration of peritoneal nodules

The procedure of EUS-FNA from the peritoneal nodules involves EUS using (curvi) linear echoendoscope from the gastric or duodenal station. The use of periprocedural antibiotics is routinely reported in patients undergoing EUS-guided paracentesis or FNA from peritoneal nodules.^[5,17,18] The ascites is visualized as an anechoic area close to the stomach or duodenal wall. The peritoneal nodules may occur with or without concomitant ascites and are seen as heteroechoic nodules which may seem to hang into the anechoic ascites [Figure 2a].^[5] The nodules are usually sampled with 22 G EUS-FNA needle, although the use of 19 and 25G needle has also been reported. The nodules are approached through a route which avoids any other diseased tissue or organ (*e.g.*, diseased area in gastric cancer) to avoid contamination or misdiagnosis. Once the needle enters the lesion, the stylet is removed, and needle passed to and fro into the lesion [Figure 2b].^[18] Use of suction is optional, and not all reports have used it.^[5,17,18] Samples are taken for cytological examination and/or other investigations

Table 2. Details of studies reporting about use of endoscopic ultrasound fine-needle aspiration from peritoneal nodules and patient profile

References	Location	Study design	Study period	Age	Gender (male/female)	Needle design (G)	Number of passes	Onsite pathologist
Levy <i>et al.</i> , 2015	USA	Single center, retrospective study	June 2006 to November 2013	65	59/39	22	3	Onsite technologist; Tele cytology review
Rana <i>et al.</i> , 2011	India	Single center, case series	18 months	47.5	9/3	22	3	No
Peter <i>et al.</i> , 2009	USA	Single center, case series	3 years	52.25	3/1	22	2 (1-4)	Information NA
Kocaman <i>et al.</i> , 2013	Turkey	Case series	NA	42.67	2/1	19	NA	No

NA: Not available

Table 3. Utility of endoscopic ultrasound fine-needle aspiration from peritoneal nodules

References	Number of patients	Patient subset	Ascites	Findings on EUS	Number of PC	True positive	False negative	Overall diagnosis	Complications
Levy <i>et al.</i> , 2015	98	Patients with peritoneal anomaly	58	Solid hypoechoic masses, thickening, nodularity	65	59	6	59: Malignant 39: Benign (6 false negative)	Pain: 2 Hypertensive emergency: 1 Acute pancreatitis: 1*
Rana <i>et al.</i> , 2011	12	Undiagnosed ascites	All	Hyperechoic nodules: 10 (malignant nodules larger than tubercular) Mucus flakes	8	6	2	Adenocarcinoma: 4 Poorly differentiated adenocarcinoma: 1 Inflammation: 4 Pseudomyxoma: 1 TB PCR positive: 2	None
Peter <i>et al.</i> , 2009	4	Ascites with peritoneal thickening on CT	4	Hypoechoic relative to surrounding tissue and hyperechoic to ascites	4	4	0	Adenocarcinoma: 2 Poorly differentiated carcinoma: 1 Lymphoma: 1	None
Kocaman <i>et al.</i> , 2013	3	Ascites with peritoneal nodules	3	Hyperechoic nodules, sheet like mass	0	NA	NA	All TB	None

*Also underwent ERCP. PC: Peritoneal carcinomatosis, EUS: Endoscopic ultrasound, NA: Not available, CT: Computed tomography, TB: Tuberculosis, PCR: Polymerase chain reaction, ERCP: Endoscopic retrograde cholangiopancreatography

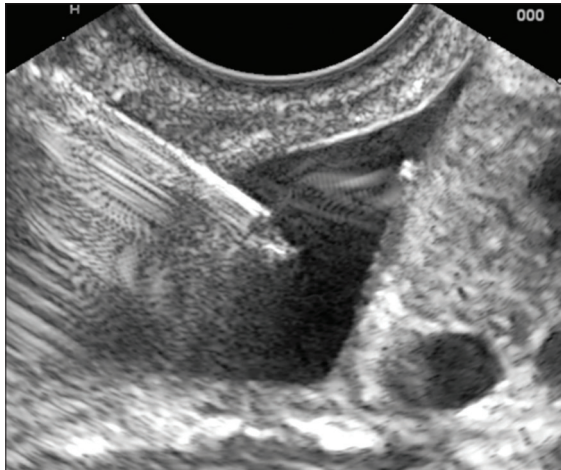


Figure 1. Endoscopic ultrasound-guided paracentesis of minimal ascites through the stomach

as clinically indicated (*e.g.*, mycobacterial culture or polymerase chain reaction testing, and flow cytometry) and ascitic fluid can also be simultaneously aspirated [Figure 2c]. Although, transrectal FNA may also help identify lesions in the peritoneum the use of this strategy has not been evaluated.^[26]

Subtle differences in malignant and benign peritoneal nodules have been reported: Malignant nodules are usually discrete hypoechoic masses or nodularity while the benign nodules are less well defined and may be isoechoic to surrounding structures.^[5]

Clinical Profile

The mean age of the patients included in various studies for EUS-FNA for paracentesis or peritoneal

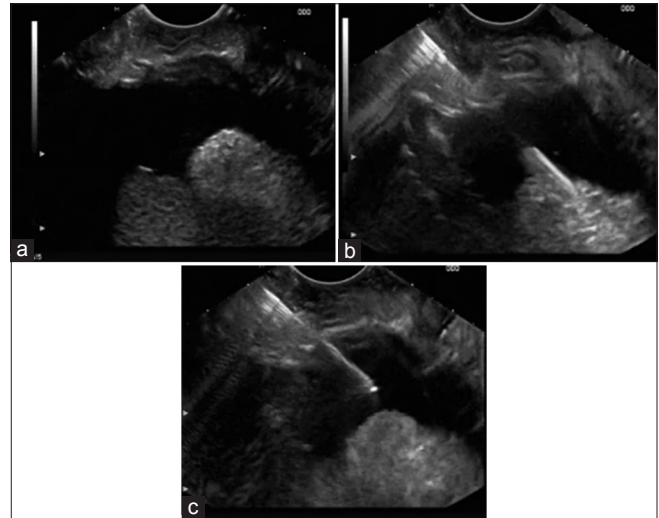


Figure 2. (a) Endoscopic ultrasound shows ascites with peritoneal deposits (b) Endoscopic ultrasound-guided fine needle aspiration of peritoneal deposits through the stomach (c) Endoscopic ultrasound-guided paracentesis of minimal ascites through the stomach

nodules is variable. Reports from Asia, where some patients with tubercular peritoneal involvement were included, have a mean age around a decade younger than Western series.^[5,16-18] The studies do not directly report success rate, but it seems technical success for EUS-FNA of ascitic paracentesis and peritoneal nodules was achieved in most patients. However, being retrospective studies and the common denominator being the inclusion of patients with EUS directed paracentesis or FNA of nodules, there may be a selection/inclusion bias as only successful cases would be included in such an analysis.^[11] While the eventual diagnosis in most patients with EUS-FNA of peritoneal

nodules was peritoneal carcinomatosis; in some of the reports, other diagnoses such as tuberculosis and lymphoma were also reported.^[16-18]

Clinical Utility

The entire estimate of the clinical utility is not possible as most studies are retrospective and therefore complete follow-up diagnosis may not be available. In series of 31 patients who underwent ascitic tap, unnecessary surgery could be avoided in 5 patients. However, of those reported to be negative for pancreatic cancer (PC), 7 had surgical correlation and 5 of these 7 had PC on surgery. This suggests that false negativity for PC is common with EUS-guided FNA of ascites.^[14] In another report of 25 patients, 16 had positive peritoneal cytology and in 10 of these patients unnecessary surgery could be avoided. Of the nine with negative cytology one was found to have omental metastasis on surgery while others had a true negative cytology.^[13] Another report suggested that in four patients with malignant ascites the malignancy was missed on EUS-FNA.^[12] Furthermore in a majority of these patients other cross-sectional imaging had failed to detect ascites.^[12,14]

The yield of EUS-FNA from the peritoneal nodules, as reported in literature, appears to be excellent. However, such lesions may be seen only in a subset of patients as over 4 years one center reported only 4 cases, whereas in another report of 12 patients of undiagnosed ascites, 10 patients had peritoneal nodules.^[17,18] Furthermore, the cytological findings in tuberculosis may be nonspecific inflammatory changes. Therefore, if suspicion of tuberculosis is high the material should also be sent for microbiological analysis.^[17] Since the yield of EUS paracentesis is often low, the additional use of EUS-FNA from nodules may provide incremental value in achieving the diagnosis of PC. EUS-FNA from peritoneal nodules may be feasible even in the absence of ascites. In one large report on EUS-FNA of peritoneal nodules, EUS was able to upstage patients and 21 of the 32 patients found to be resectable on basis of CT/MRI were converted to unresectable. This helps in avoiding unnecessary laparotomy and prognosticating the patients.^[5]

Complications

Complication related to EUS-paracentesis and FNA from nodules were infrequent with some reports of fever, peritonitis, pain, and one report of hypertensive emergency and a case of pancreatitis

(in a patient who also underwent endoscopic retrograde cholangiopancreatography [ERCP]) have been reported. In a report of 25 patients who underwent EUS-guided paracentesis one patient developed abdominal pain and was found to have bacterial peritonitis in spite of periprocedural antibiotics.^[13] Other reported complications for EUS paracentesis were abdominal pain and fever.^[12] Most reports suggest that peritoneal nodule FNA is safe except for one study which reported abdominal pain and vomiting in a couple of patients and a case of hypertensive urgency and mild acute pancreatitis (in a patient who underwent ERCP also) in one patient each.^[5]

DISCUSSION

Ascites is known to result from multiple causes, and the presence of ascites in patients with underlying malignancy may suggest peritoneal carcinomatosis and its presence alters the plan of management in these patients. Indeed, a majority of patients with malignancy-related ascites have underlying peritoneal carcinomatosis, and a vast majority of these may be identified by ascitic fluid cytological evaluation.^[7] Therefore, ascitic fluid cytological evaluation remains the cornerstone of evaluation of these patients.

Ascites can be detected by various imaging modalities such as ultrasound, CT, or MRI. However, EUS has been shown to be more sensitive than other imaging modalities for detection of ascites. In a prospective evaluation of patients with gastric cancer, 90% of patients were demonstrated to have ascites on EUS and EUS was more sensitive than combined ultrasound and CT examination.^[10] This implies that cross-sectional imaging techniques such as ultrasound, CT and MRI may not detect ascites in a subset of the patients. In one report in patients with low volume ascites in the setting of esophagogastric malignancy, 52% of patients were deemed to be inoperable in patients without detectable metastasis on CT.^[27]

Furthermore, in a report of EUS-guided paracentesis of the 60 patients who underwent ascitic tap, around half of the patients had ascites which had not been identified in previous investigations. However, as is apparent from this report, cytological evaluation of fluid obtained by EUS paracentesis may miss the presence of underlying malignancy. Of the 60 patients, EUS FNA classified 42 patients to have benign ascites, but follow-up eventually suggested that 45 patients

had the underlying malignant disease. Of the seven patients who were classified as having benign ascites and underwent surgery three had malignant peritoneal nodules on surgery.^[12] This clearly demonstrates the limited utility of EUS paracentesis alone in making a sure discrimination of benign and malignant ascites. Also, not all patients with underlying malignancy have peritoneal carcinomatosis as a cause of ascites. In another report of EUS-FNA of 25 patients, of the nine patients who had negative ascitic cytology, six patients had an underlying malignancy. Eventually, of the six patients with underlying malignancy and negative cytology, only one patient had evidence of omental metastasis on surgery, whereas rest five had no evidence of peritoneal disease.^[13] These findings suggest that ascitic fluid evaluation may provide the correct diagnosis in some patients and help avoid unnecessary laparotomy, but in some patients, the cytology may be a false negative. In these patients, identification of peritoneal nodules on EUS and subsequent sampling of these nodules/masses may help in establishing the correct diagnosis. However, as mentioned in the results, the incremental value of evaluation of peritoneal nodules and FNA from them has not been evaluated prospectively.

To conclude, EUS is an excellent tool for detection of the small amount of ascites and EUS paracentesis may help in the diagnosis of PC in a subset of patients. EUS-guided FNA from peritoneal nodules appears to have a good yield for the diagnosis of PC although occasionally other causes of peritoneal nodules such as tuberculosis, pseudomyxoma, or lymphoma may be identified.^[5,16-18]

Financial support and sponsorship

Nil.

Conflicts of interest

There are no conflicts of interest.

REFERENCES

- Healy JC, Reznick RH. The peritoneum, mesenteries and omenta: Normal anatomy and pathological processes. *Eur Radiol* 1998;8:886-900.
- Daya D, McCaughey WT. Pathology of the peritoneum: A review of selected topics. *Semin Diagn Pathol* 1991;8:277-89.
- Diop AD, Fontarensky M, Montoriol PF, et al. CT imaging of peritoneal carcinomatosis and its mimics. *Diagn Interio Imaging* 2014;95:861-72.
- Mo S, Cai G. Multidisciplinary treatment for colorectal peritoneal metastases: Review of the literature. *Gastroenterol Res Pract* 2016;2016:1516259.
- Levy MJ, Abu Dayyeh BK, Fujii LL, et al. Detection of peritoneal carcinomatosis by EUS fine-needle aspiration: Impact on staging and resectability (with videos). *Gastrointest Endosc* 2015;81:1215-24.
- Sharma V, Bhatia A, Malik S, et al. Visceral scalloping on abdominal computed tomography due to abdominal tuberculosis. *Ther Adv Infect Dis* 2017;4:3-9.
- Runyon BA, Hoefs JC, Morgan TR. Ascitic fluid analysis in malignancy-related ascites. *Hepatology* 1988;8:1104-9.
- Laghi A, Bellini D, Rengo M, et al. Diagnostic performance of computed tomography and magnetic resonance imaging for detecting peritoneal metastases: Systematic review and meta-analysis. *Radiol Med* 2017;122:1-5.
- Sharma V, Rana SS, Bhasin DK. Endoscopic ultrasound guided interventional procedures. *World J Gastrointest Endosc* 2015;7:628-42.
- Lee YT, Ng EK, Hung LC, et al. Accuracy of endoscopic ultrasonography in diagnosing ascites and predicting peritoneal metastases in gastric cancer patients. *Gut* 2005;54:1541-5.
- Wardeh R, Lee JG, Gu M. Endoscopic ultrasound-guided paracentesis of ascitic fluid: A morphologic study with ultrasonographic correlation. *Cancer Cytopathol* 2011;119:27-36.
- DeWitt J, LeBlanc J, McHenry L, et al. Endoscopic ultrasound-guided fine-needle aspiration of ascites. *Clin Gastroenterol Hepatol* 2007;5:609-15.
- Kaushik N, Khalid A, Brody D, et al. EUS-guided paracentesis for the diagnosis of malignant ascites. *Gastrointest Endosc* 2006;64:908-13.
- Nguyen PT, Chang KJ. EUS in the detection of ascites and EUS-guided paracentesis. *Gastrointest Endosc* 2001;54:336-9.
- Suzuki R, Irisawa A, Bhutani MS, et al. An automated spring-loaded needle for endoscopic ultrasound-guided abdominal paracentesis in cancer patients. *World J Gastrointest Endosc* 2014;6:55-9.
- Kocaman O, Danalioglu A, Ince AT, et al. Diagnosis of tuberculous peritonitis using endoscopic ultrasound-guided fine-needle aspiration biopsy of the peritoneum. *Turk J Gastroenterol* 2013;24:65-9.
- Rana SS, Bhasin DK, Srinivasan R, et al. Endoscopic ultrasound-guided fine needle aspiration of peritoneal nodules in patients with ascites of unknown cause. *Endoscopy* 2011;43:1010-3.
- Peter S, Eltoun I, Eloubeidi MA. EUS-guided FNA of peritoneal carcinomatosis in patients with unknown primary malignancy. *Gastrointest Endosc* 2009;70:1266-70.
- Somani P, Sharma M, Patil A, et al. Endoscopic ultrasound-guided fine-needle aspiration of peritoneal deposits in patients with ascites of unknown cause (with videos). *Endosc Ultrasound* 2017;6:69-70.
- Darr U, Renno A, Alkully T, et al. Diagnosis of pseudomyxoma peritonei via endoscopic ultrasound guided fine needle aspiration: A case report and review of literature. *Scand J Gastroenterol* 2017;52:609-12.
- Rana SS, Bhasin DK, Rao C, et al. Endoscopic ultrasound-guided fine-needle aspiration of omental deposits in undiagnosed ascites. *Dig Endosc* 2013;25:212-3.
- Rial NS, Gilchrist KB, Henderson JT, et al. Endoscopic ultrasound with biopsy of omental mass for cholangiocarcinoma diagnosis in cirrhosis. *World J Gastrointest Endosc* 2011;3:124-8.
- Rana SS, Bhasin DK, Srinivasan R, et al. Endoscopic ultrasound fine-needle aspiration of peritoneal deposits for diagnosis of tubercular peritonitis in a cirrhotic patient with ascites. *Endoscopy* 2010;42 Suppl 2:E306-7.
- Varadarajulu S, Drelichman ER. EUS-guided therapeutic paracentesis. *Gastrointest Endosc* 2008;67:758-9.
- Chang KJ, Albers CG, Nguyen P. Endoscopic ultrasound-guided fine needle aspiration of pleural and ascitic fluid. *Am J Gastroenterol* 1995;90:148-50.
- Rana SS, Bhasin DK. EUS: A panacea for detection of peritoneal carcinomatosis! *Gastrointest Endosc* 2015;81:1225-7.
- Sultan J, Robinson S, Hayes N, et al. Endoscopic ultrasonography-detected low-volume ascites as a predictor of inoperability for oesophago-gastric cancer. *Br J Surg* 2008;95:1127-30.