

Ophthalmia nodosa secondary to multiple intraocular caterpillar hairs in a 2-year-old girl

Abdulaziz I. Al Somali, Wael Otaif¹, Tamer M. Afifi², Ussama A. Moustsa², Khalid E. Emara²

Access this article online

Quick Response Code:



Website:

www.saudijophthalmol.org

DOI:

10.4103/1319-4534.310418

Abstract:

A 2-year-old girl presented with pain, itching, photophobia, and tearing in her left eye. These symptoms started after contact with a caterpillar. The patient was initially taken to another hospital, where the local ophthalmologist prescribed topical prednisolone acetate 1%, a topical antibiotic, and cyclopentolate 1% eye drops. However, 3 weeks later, the patient presented to our hospital with no symptomatic improvement. Slit-lamp examination showed moderate conjunctival injection and diffuse superficial punctate corneal epithelial erosions with numerous caterpillar hairs embedded in the bulbar and tarsal conjunctiva, and in the superficial and deep corneal stroma, extending into the anterior chamber (AC). In addition, the AC had 2+ cells with caterpillar hairs on the iris surface. The lens was clear, and the fundus examination was normal. The patient underwent AC wash and setae removal under general anesthesia; this was repeated 4 months later when symptoms recurred owing to retained setae. There was no evidence of any additional setae or ocular inflammation in 8 months of follow-up, and symptoms resolved completely. Caterpillar hairs can migrate intraocularly and induce an ocular inflammatory response. Immediate and thorough irrigation, continued scrupulous examinations for any retained setae, and meticulous setae extraction are crucial for treating this condition.

Keywords:

Caterpillar hair, ophthalmia nodosa, setae

INTRODUCTION

Ophthalmia nodosa is a rare ocular inflammatory process that is triggered by caterpillar setae or other specific hairs.^[1] The setae-induced ocular inflammatory response is related to the mechanical invasion of the setae and the toxic reaction to venom gland secretions.^[2] The clinical presentations of ophthalmia nodosa secondary to caterpillar hair are variable. The ocular manifestations may include keratitis, nodular conjunctivitis, anterior uveitis, vitritis, or chorioretinal lesions.^[3] Moreover, ophthalmia nodosa was described as an uncommon incidental finding during a routine examination of an asymptomatic patient without signs of uveitis or conjunctivitis.^[4]

Treatment includes removal of all setae if possible. However, the inflammatory response

at the initial presentation could impede the visualization, and late presentation of undetected seta is reported to necessitate further surgical intervention.^[5,6] Setae left *in situ* may migrate to the anterior chamber (AC),^[7] crystalline lens, or vitreous and cause posterior segment inflammation.^[6,8]

In this report, we describe a case of ophthalmia nodosa secondary to intraocular caterpillar hairs in a 2-year-old girl. To the best of our knowledge, no case has been previously reported in the Middle East.

CASE REPORT

A 2-year-old girl presented with pain, itching, photophobia, and tearing in her left eye. These symptoms started 3 h after the patient came in contact with a caterpillar while she was sleeping outside. The patient was initially taken to another hospital, where the local ophthalmologist prescribed topical prednisolone acetate 1%,

Department of Ophthalmology,
College of Medicine, King
Faisal University, Al Ahsa,

¹Department of Ophthalmology,
King Khalid University, Abha,

²Department of Ophthalmology,
Dhahran Eye Specialist
Hospital, Dhahran,
Saudi Arabia

Address for correspondence:

Dr. Wael Otaif,
Department of Ophthalmology,
King Khalid University,
P.O. Box 960, Abha 61421,
Saudi Arabia.
E-mail: waelotaif@gmail.com

Submitted: 13-Jul-2020

Revised: 05-Aug-2020

Accepted: 10-Aug-2020

Published: 27-Feb-2021

This is an open access journal, and articles are distributed under the terms of the Creative Commons Attribution-NonCommercial-ShareAlike 4.0 License, which allows others to remix, tweak, and build upon the work non-commercially, as long as appropriate credit is given and the new creations are licensed under the identical terms.

For reprints contact: WKHLRPMedknow_reprints@wolterskluwer.com

How to cite this article: Al Somali AI, Otaif W, Afifi TM, Moustsa UA, Emara KE. Ophthalmia nodosa secondary to multiple intraocular caterpillar hairs in a 2-year-old girl. Saudi J Ophthalmol 2020;34:230-2.

a topical antibiotic, and cyclopentolate 1% eye drops. However, the symptoms persisted over the next 3 weeks, at which point the patient presented to our hospital with no symptomatic improvement. Slit-lamp examination of the right eye was unremarkable, while the left eye examination showed moderate conjunctival injection with numerous caterpillar hairs embedded in the bulbar and tarsal conjunctiva, and in the superficial and deep corneal stroma, extending into the AC [Figure 1a]. In addition, the AC of the left eye had 2+ cells with caterpillar hair on the iris surface [Figure 1b]. The lens was clear, and the fundus examination was normal in both eyes. The patient underwent AC wash and setae removal under general anesthesia, during which the exposed conjunctival, superficial corneal stroma, and AC setae were removed [Figure 2a] and sent for microscopic examination [Figure 2b]. However, deep corneal stroma and the buried conjunctival hair that were not exposed and away from the visual axis were left in place. The patient was instructed to continue with the topical medications for a period of 2 weeks. At 2-week follow-up, slit-lamp examination showed no conjunctival injection, a clear cornea, and no AC reaction. However, 4 months later, the symptoms recurred owing to setae, which were originally concealed by the conjunctiva; the sharp points were uncovered, and the setae were then removed successfully. During the subsequent follow-up visits over the next 8 months, there was no evidence of any exposed setae or ocular inflammation, and symptoms were completely resolved.

DISCUSSION

Setae from moth caterpillars of the genus *Lepidoptera* can cause conjunctival granuloma, defined as ophthalmia nodosa. The prevalence of ophthalmia nodosa correlates to the caterpillar population size, which, due to their life cycle, peaks in the fall season.^[3] The link between these caterpillars and ophthalmia nodosa was discovered by Watson and Sevel and published in 1966.^[1] While there is substantial evidence to prove the prevalence of ophthalmia nodosa in India,^[9] there are no data or cases concerning the condition in Saudi Arabia.

In this instance, as with most cases reported, the patient was outside when the incident occurred. The 3-h time to the onset of symptoms was also fairly consistent with that in other reported

cases, in which symptoms occurred up to 3 h after exposure.^[6] The setae may become lodged in the conjunctival fornix through direct contact or having been swept up by the breeze. In this case, diagnosis was aided by the unusual fact that a caterpillar was seen by the patient's relatives before the incident occurred. However, they were not able to retrieve it. Normally, if a patient presents with a congested eye during the caterpillar season and there appears to be setae in the eye, ophthalmia nodosa ought to be suspected whether or not any caterpillar contact was observed.^[10]

Ophthalmia nodosa presents in several ways. Sudden chemosis and inflammation as a result of acute anaphylaxis caused by setae may last approximately 2 to 3 days. Chronic mechanical keratoconjunctivitis with linear corneal abrasions occurs when the setae enter the palpebral or bulbar conjunctiva. The patient may be asymptomatic or there may be a gray-tinged yellow granulomatous nodule in the conjunctiva when the hair is subconjunctival or intracorneal. Setae in the anterior segment may result in inflammation of the iris, increasing in severity if there is hypopyon or an iris nodule, and setae in the posterior segment may result in involvement of the retina and vitreous body.^[11] All setae cause mechanical irritation, but some also secrete toxin-containing protein, and this combination results in an array of symptoms.^[2] The patient in this case showed signs of keratoconjunctivitis, uveitis, and intraocular penetration.

An atypical case, where the lower palpebral conjunctiva exhibited an inflammation which caused no pain in the patient, has been reported. On biopsy, this was determined to be a granuloma with caterpillar hair; however, such cases are uncommon.^[4] Similarly, only a small number of intra-lenticular setae have been recorded.^[8,12] Agarwal *et al.*^[13] described a case where a young woman was found to have several caterpillar hairs in areas of her eye, including her AC, sclera, cornea, and pars plana. Savage *et al.*^[5] provided an account of a single case of ophthalmia nodosa, where the path of an intracorneal seta altered its direction. One case which bears a striking resemblance to ours was that of a 6-year-old boy, who had a number of caterpillar hairs lodged in his eyelids, periocular skin, and palpebral conjunctiva. However, there was no evidence of corneal or AC involvement in that particular case.^[14]

The setae were managed initially by reducing inflammation with topical steroids, antibiotics, and lubrications. At this point

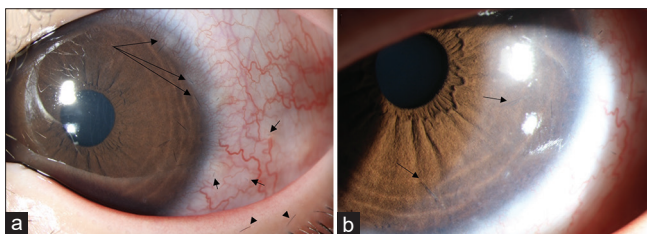


Figure 1: (a) Multiple hairs embedded in the peripheral cornea surrounded by mild stromal haze (long arrows). Multiple exposed subconjunctival hairs and diffuse conjunctival injection (short arrows) as well as two hairs embedded at the lid margin (arrowheads) are seen. (b) Two intraocular hairs are seen in the anterior chamber (arrows)

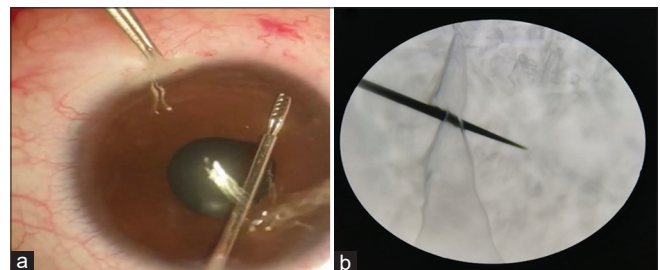


Figure 2: (a) Intraoperative extraction of the anterior chamber hairs using intraocular forceps. (b) Under simple microscope, the caterpillar hair appeared to be darkly pigmented with sharp tapered ends and no side barbs

of treatment, the setae in the AC were not causing inflammation, but this can occur several years after the initial incident. There was, however, continued inflammation of the ocular surface. Considering the potential for future inflammation, the family agreed that it was in the patient's best interest to extract the setae in the AC while the patient was under general anesthesia. However, 4 months after the initial incident, the patient's symptoms returned. Setae which originally were concealed by the conjunctiva had their sharp points uncovered. All setae were extracted in a second procedure, despite them being notoriously challenging to remove.

Immediate thorough irrigation, continued scrupulous examinations, and setae extraction are crucial for treating this condition. Informing patients about the harmful effects of repeatedly touching their eyes also aids treatment, according to Villiard and De Jean. In the case of conjunctival nodules, surgery may be necessary.^[15]

Intraocular penetration can have serious implications. In order to best protect the patient's vision, follow-up to detect any retained intracorneal hair is key. The presence of intracorneal hair is the single notable risk for intraocular penetration found by Sengupta *et al.*^[4] In practice, extracting all the hairs is extremely challenging; there is often swelling of the cornea and there are usually many hairs which can spread and break easily. Continued reviews and multiple attempts to remove hairs are required to prevent future difficulties.

In conclusion, ophthalmia nodosa is a rare condition that should be suspected if patients present with ocular congestion during caterpillar season, whether or not caterpillar contact has been documented. Successful treatment requires thorough efforts to remove all setae from the affected area and ascertain any intraocular penetration or inflammation. Furthermore, patients require continuous long-term follow-up as the setae may initially be masked by inflammation and are likely to migrate within the eye, causing significant risk of serious damage.

Financial support and sponsorship

Nil.

Conflicts of interest

There are no conflicts of interest.

REFERENCES

1. Watson PG, Sevel DA. Ophthalmia nodosa. *Br J Ophthalmol* 1966;50:209-17.
2. Lamy M, Pastureaud MH, Novak F, Ducombs G, Vincendeau P, Maleville J, *et al.* Thaumetopoein: An urticating protein from the hairs and integument of the pine processionary caterpillar (*Thaumetopoea pityocampa* Schiff, Lepidoptera, Thaumetopoeidae). *Toxicon* 1986;24:347-56.
3. Duke-Elder, Sir S, MacFaul PA. *System of Ophthalmology*. Vol. XIV., Part 2. London: Henry Kimpton; 1972, p. 1197-202.
4. Prasad SC, Korah S. Rare presentation of ophthalmia nodosa. *Middle East Afr J Ophthalmol* 2015;22:520-1.
5. Savage ND, Green JC, Carley F. Images in ophthalmia nodosa: An unusual presentation of red eye. *BMJ Case Rep* 2018;2018:1-2.
6. Doshi PY, Usgaonkar U, Kamat P. A hairy affair: Ophthalmia nodosa due to caterpillar hairs. *Ocul Immunol Inflamm* 2018;26:136-41.
7. Shankar S, Ahluwalia TS, Gurnadh VS, Sati A. Unique presentation of ophthalmia nodosa in an adult male patient with a novel management approach. *Med J Armed Forces India* 2016;72:400-2.
8. Singh A, Behera UC, Agrawal H. Intra-lenticular caterpillar seta in ophthalmia nodosa [published online ahead of print, 2019 Jul 8]. *Eur J Ophthalmol*. 2019;1120672119858899. doi:10.1177/1120672119858899.
9. Sengupta S, Reddy PR, Gyatsho J, Ravindran RD. Risk factors for intraocular penetration of caterpillar hair in ophthalmia nodosa: A retrospective analysis. *Indian J Ophthalmol* 2010;58:540-3.
10. Bishop JW, Morton MR. Caterpillar-hair keratoconjunctivitis. *Am J Ophthalmol* 1967;64:778-9.
11. Cadera W, Pachtman MA, Fountain JA, Ellis FD, Wilson FM2. Ocular lesions caused by caterpillar hairs (ophthalmia nodosa). *Can J Ophthalmol* 1984;19:40-4.
12. González-Martín-Moro J, Contreras-Martín I, Castro-Rebollo M, Fuentes-Vega I, Zarallo-Gallardo J. Focal cortical cataract due to caterpillar hair migration. *Clin Exp Optom* 2019;102:89-90.
13. Agarwal M, Acharya M, Majumdar S, Paul L. Managing multiple caterpillar hair in the eye. *Indian J Ophthalmol* 2017;65:248.
14. Saleh S, Brownstein S, Kapasi M, O'Connor M, Blanco P. Ophthalmia nodosa secondary to caterpillar-hair-induced conjunctivitis in a child. *Can J Ophthalmol* 2020;55:e56-9.
15. Villard H, Dejean CH. L'Ophthalmie des chenilles. *Arch Ophthalmol* 1934;51:719-45.