



Published in final edited form as:

*Ear Nose Throat J.* 2021 January ; 100(1): 9–11. doi:10.1177/0145561319876241.

## Salvage Transoral Robotic Surgery: A Case of a Nearly Missed Carotid Injury

Meghan T. Turner, MD<sup>1</sup>, Michael J. Persky, MD<sup>2</sup>, Jessica M. Moskovitz, MD<sup>3</sup>, Seungwon Kim, MD<sup>3</sup>

<sup>1</sup>Department of Otolaryngology–Head and Neck Surgery, West Virginia University Health Sciences Center, Morgantown, WV, USA

<sup>2</sup>Department of Otolaryngology–Head and Neck Surgery, New York University Langone Medical Center, New York, NY, USA

<sup>3</sup>Department of Otolaryngology–Head and Neck Surgery, University of Pittsburgh Medical Center, Pittsburgh, PA, USA

---

A 59-year-old male developed an asymptomatic, left-sided oropharyngeal lesion six months after chemoradiotherapy for a human papillomavirus-positive T2N2bM0 tonsillar cancer. In-office biopsy confirmed persistent disease. Preoperative imaging revealed a resectable recurrence without internal carotid artery (ICA) or retropharyngeal carotid abutment (see Figures 1 and 2). The patient was counseled about the increased risk of postoperative tracheostomy dependence, feeding tube dependence,<sup>1</sup> and postoperative hemorrhage.<sup>2-4</sup>

The patient underwent salvage transoral robotic surgery (TORS) using the incision shown in Figure 3. First, the pterygomandibular raphe was identified and careful blunt dissection was used to enter the parapharyngeal space just medial to the raphe. The superior constrictor was preserved as the lateral oncologic margin. Next, the incision was carried superiorly toward the muscularis uvulae and inferiorly toward the palatoglossus and intrinsic tongue base musculature. Finally, the posterior pharyngeal wall was incised, and dissection proceeded deep to the constrictor within the retropharyngeal space. Careful dissection and a high degree of suspicion for ICA medialization after radiation prevented near catastrophic ICA

---

Creative Commons Non Commercial CC BY-NC: This article is distributed under the terms of the Creative Commons Attribution-NonCommercial 4.0 License (<http://www.creativecommons.org/licenses/by-nc/4.0/>) which permits non-commercial use, reproduction and distribution of the work without further permission provided the original work is attributed as specified on the SAGE and Open Access pages (<https://us.sagepub.com/en-us/nam/open-access-at-sage>).

**Corresponding Author:** Meghan T. Turner, MD, Department of Otolaryngology, Head and Neck Surgery, West Virginia University Health Sciences Center, 1 Medical Center, Morgantown, WV 26506, USA., [meghan.tuner@hsc.wvu.edu](mailto:meghan.tuner@hsc.wvu.edu).

### Authors' Note

Author Meghan Turner, MD, was responsible for initial data collection, manuscript writing, video editing, and production. Authors Michael Persky, MD, and Jessica Moskovitz, MD, helped with follow-up data collection, manuscript writing, and video review. Author Seungwon Kim, MD, was responsible for the follow-up data collection, manuscript review, and video review. Informed consent was obtained from the patient for publication of this case report and any accompanying images. A copy of the written consent as obtained per institutional protocol is available.

### Declaration of Conflicting Interests

The author(s) declared no potential conflicts of interest with respect to the research, authorship, and/or publication of this article.

### Supplemental Material

Supplemental material for this article is available online.

injury in the inferior retropharyngeal space (see Figure 4 and Supplemental Video). Finally, the mass was removed en bloc, oriented, and sent for frozen section analysis.

Reconstruction was undertaken to prevent carotid blowout.<sup>5</sup> In this case, fascial edges were mobilized and sutured together primarily over the carotid.<sup>6</sup> Given prolonged healing (up to 35 days) following salvage surgery,<sup>2</sup> a nasoseptal flap was used to cover the lateral oropharyngeal defect,<sup>7</sup> and a fascia lata graft was used posteroinferiorly (see Supplemental Video). Tracheostomy (for airway protection in the event of hemorrhage) and nasogastric tube insertion were also performed.

The patient went to the intensive care unit for tracheostomy care and was transferred to a step-down unit on postoperative day (POD) #2. Intensive swallow therapy started on POD#2, but oral feeding was delayed until POD#4 after bolster removal. Repeat swallow evaluation revealed a mildly deconditioned swallow without aspiration, and the patient was discharged to a skilled nursing facility (SNF) on POD#7.

In clinic, final pathology revealed negative margins without perineural or lymphovascular invasion. The tracheostomy tube was removed on POD#18. The patient was discharged from the SNF to clinic on POD#23 but continued to have significant oropharyngeal phase dysfunction. The feeding tube was not removed until a final evaluation on POD#37.

Six months after salvage TORS, the cancer recurred. The patient then received stereotactic radiosurgery and cetuximab as part of a clinical trial. Fifteen months later, he developed radionecrosis of the pharynx, which required a total laryngopharyngectomy and microvascular free flap reconstruction. He is currently disease-free.

Salvage TORS for oropharyngeal cancer has been performed in single institution studies, albeit in limited fashion.<sup>1,8</sup> Currently, the 2-year disease-free survival following salvage TORS is 57.7% to 75.8%.<sup>1,8</sup> However, salvage TORS has been associated with higher risk of bleeding complications (10.8%-21.9%), higher rates of long-term tracheostomy dependence (0%-10%), and postoperative feeding tube dependency (10%-20%).<sup>1,8,9</sup> Salvage TORS is an advanced procedure and should only be performed by experienced TORS surgeons due to the technical challenges incurred following chemoradiation.<sup>1</sup> First, tissue fibrosis makes it difficult to recognize the natural anatomical dissection planes and landmarks amid dense scarring and/or bleeding.<sup>10</sup> Secondly, salvage TORS presents challenges for healing by secondary intention.<sup>11</sup> Therefore, the surgeon should have a reconstructive plan to prevent the development of nonhealing wounds and decrease the risk of hemorrhage.<sup>2,12</sup> To date, no one has reported ICA exposure rates after salvage TORS. There is only one other case report of salvage TORS with a retropharyngeal carotid artery, and this was reconstructed with an anterolateral thigh microvascular free flap.<sup>13</sup> We, along with others, advocate for salvage TORS reconstruction with either locoregional flaps or free tissue transfer.<sup>14,15</sup> Current practice may evolve with increasing salvage TORS experience.

## Supplementary Material

Refer to Web version on PubMed Central for supplementary material.

## Acknowledgments

### Funding

The author(s) disclosed receipt of the following financial support for the research, authorship, and/or publication of this article: This project was supported by the National Cancer Institute Specialized Programs of Research Excellence (SPORE) Grant P50 CA097190; and the National Institutes of Health T32 Grant CA060397, PI: Dr Robert L. Ferris, MD, PhD, FACS.

## References

1. Arora A, Kotecha J, Acharya A, et al. Determination of biometric measures to evaluate patient suitability for transoral robotic surgery. *Head Neck*. 2015;37(9):1254–1260. doi:10.1002/hed.23739.
2. Asher SA, White HN, Kejner AE, Rosenthal EL, Carroll WR, Magnuson JS. Hemorrhage after transoral robotic-assisted surgery. *Otolaryngol Head Neck Surg*. 2013;149(1):112–117. doi:10.1177/0194599813486254. [PubMed: 23585156]
3. Chia SH, Gross ND, Richmon JD. Surgeon experience and complications with transoral robotic surgery (TORS). *Otolaryngol Head Neck Surg*. 2013;149(6):885–892. doi:10.1177/0194599813503446. [PubMed: 24013139]
4. Dabas S, Dewan A, Ranjan R, Dewan AK, Shukla H, Sinha R. Salvage transoral robotic surgery for recurrent or residual head and neck squamous cell carcinoma: a single institution experience. *Asian Pac J Cancer Prev*. 2015;16(17):7627–7632. [PubMed: 26625773]
5. Day AT, Haughey BH, Rich JT. Prevertebral muscle flap for internal carotid artery coverage during oropharyngeal transoral surgery. *Laryngoscop*. 2017;127(10):2256–2259. doi:10.1002/lary.26542.
6. De Almeida JR, Park RC, Genden EM. Reconstruction of transoral robotic surgery defects: principles and techniques. *J Reconstr Microsurg*. 2012;28(7):465–472. doi:10.1055/s-0032-1313762. [PubMed: 22744899]
7. Turner MT, Geltzeiler M, Albergotti WG, Duvvuri U, Ferris RL, Kim SW, Wang EW. Reconstruction of TORS Oropharyngectomy Defects with the Nasoseptal Flap via Transpalatal Tunnel. *J Robot Surg*. 2019. doi: 10.1007/s11701-019-00984-5. (Epub ahead of print). PMID: 31183606
8. De Almeida JR, Park RC, Villanueva NL, Miles BA, Teng MS, Genden EM. Reconstructive algorithm and classification system for transoral oropharyngeal defects. *Head Neck*. 2014;36(7):934–941. doi:10.1002/hed.23353. [PubMed: 23606444]
9. Gleysteen J, Troob S, Light T, et al. The impact of prophylactic external carotid artery ligation on postoperative bleeding after transoral robotic surgery (TORS) for oropharyngeal squamous cell carcinoma. *Oral Oncol*. 2017;70:1–6. doi:10.1016/j.oraloncology.2017.04.014. [PubMed: 28622885]
10. Gorphe P, Auperin A, Honart JF, et al. Revisiting vascular contraindications for transoral robotic surgery for oropharyngeal cancer. *Laryngoscope Investig Otolaryngol*. 2018;3(2):121–126. doi:10.1002/liv.152.
11. Gun R, Durmus K, Kucur C, Carrau RL, Ozer E. Transoral surgical anatomy and clinical considerations of lateral oropharyngeal wall, parapharyngeal space, and tongue base. *Otolaryngol Head Neck Surg*. 2016;154(3):480–485. doi:10.1177/0194599815625911. [PubMed: 26814206]
12. Kubik M, Mandal R, Albergotti W, Duvvuri U, Ferris RL, Kim S. Effect of transcervical arterial ligation on the severity of postoperative hemorrhage after transoral robotic surgery. *Head Neck*. 2017;39(8):1510–1515. doi:10.1002/hed.24677. [PubMed: 28570011]
13. Guo T, Qualliotine JR, Ha PK, et al. Surgical salvage improves overall survival for patients with HPV-positive and HPV-negative recurrent locoregional and distant metastatic oropharyngeal cancer. *Cancer*. 2015;121(12):1977–1984. doi:10.1002/cncr.29323. [PubMed: 25782027]
14. Hockstein NG, O'Malley BW Jr, Weinstein GS. Assessment of intraoperative safety in transoral robotic surgery. *Laryngoscope*. 2006;116(2):165–168. doi:10.1097/01.mlg.0000199899.00479.75. [PubMed: 16467698]

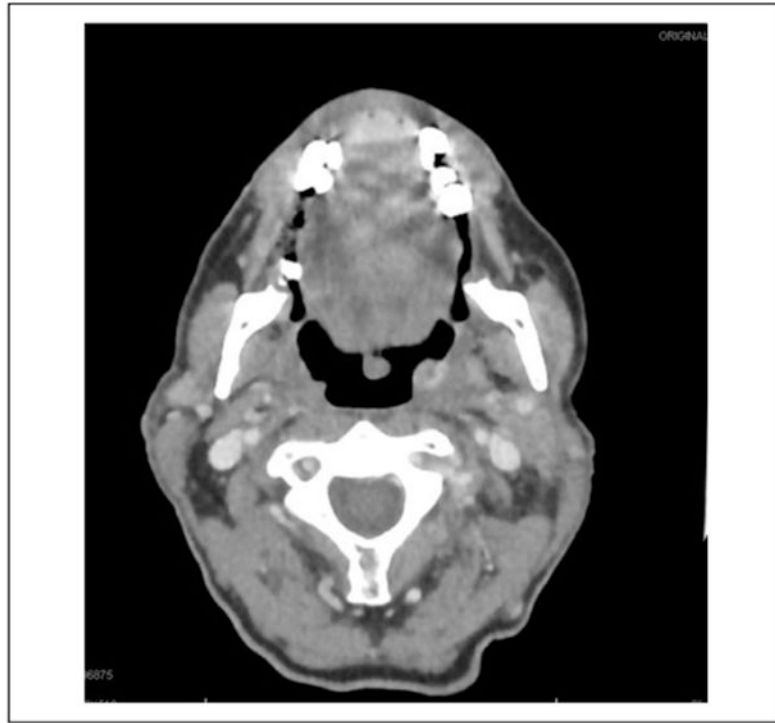
15. Kubik M, Mandal R, Albergotti W, Duvvuri U, Ferris RL, Kim S. Effect of transcervical arterial ligation on the severity of postoperative hemorrhage after transoral robotic surgery. *Head Neck*. 2017;39(8):1510–1515. doi:10.1002/hed.24677. [PubMed: 28570011]

Author Manuscript

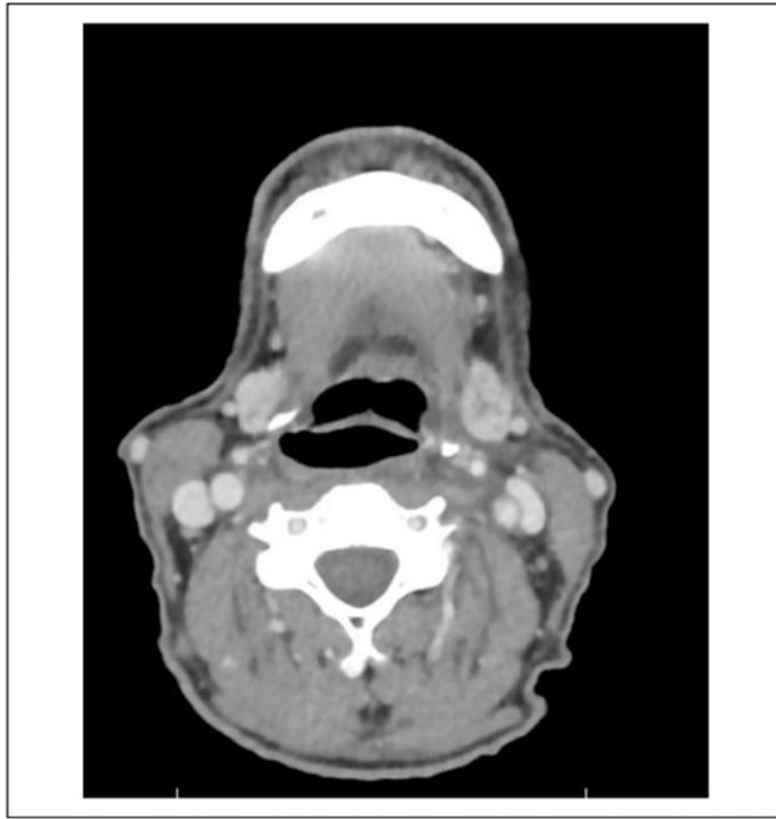
Author Manuscript

Author Manuscript

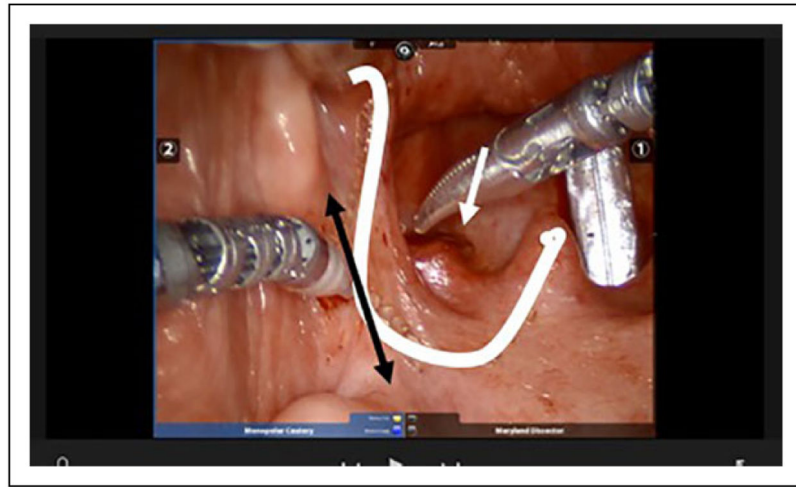
Author Manuscript



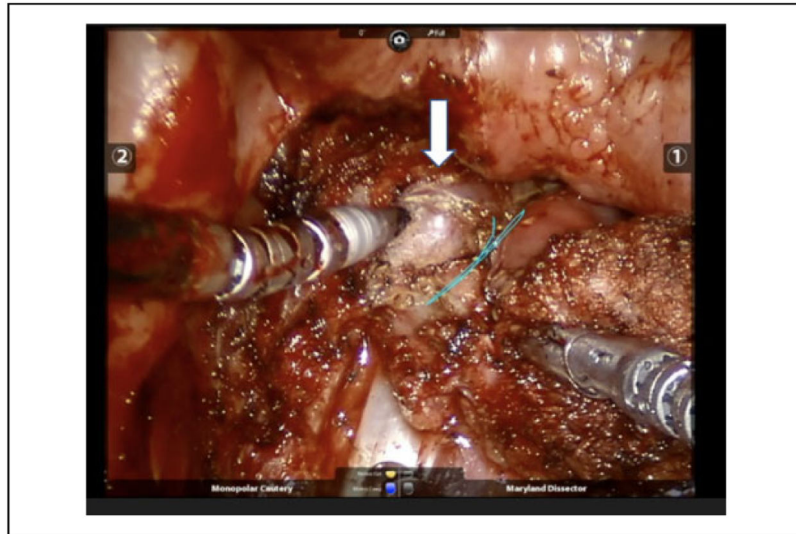
**Figure 1.** Preoperative CT scan images. Axial cuts demonstrating persistent cancer and relationship to the ICA. There is a very small recurrence with no direct tumor abutment to the carotid system and no retropharyngeal carotid. CT, computed tomography; ICA, internal carotid artery.



**Figure 2.** Preoperative CT scan images. Axial cuts demonstrate the ICA position inferiorly at the level of the vallecula and submandibular gland. Note that there is no obvious retropharyngeal carotid. CT, computed tomography; ICA, internal carotid artery.



**Figure 3.** Intraoperative image. The incision used during the procedure is shown in white. The approximate location of the pterygomandibular raphe is marked with the black, double arrowhead. The white arrowhead is pointing to the tumor.



**Figure 4.** Intraoperative image. The exposed retropharyngeal carotid artery, not appreciated on preoperative CT. The white arrow points to the internal carotid artery. CT indicates computed tomography.