

# The Role of Temporal Lobectomy as a Part of Surgical Resuscitation in Patients with Severe Traumatic Brain Injury

## Abstract

**Background:** Traumatic brain injuries (TBIs) are serious morbidity and mortality risk for especially in the young population. Primary and secondary injury mechanisms may cause cerebral edema and intracranial hypertension. The target point of the TBI treatment is lowering the intracranial pressure medically or surgically if indicated. **Methods:** The files of the patients with severe brain injury admitted between January 2015 and December 2017 were reviewed retrospectively. Patients who underwent decompression surgery due to severe brain injury ([The Glasgow Coma Scale [GCS] score] <8) and additional temporal lobectomy were included in the study group. **Results:** Ten patients were included in the study during the 3 years. All the patients were suffering from blunt severe TBI. Traumatic etiology was vehicle traffic accident in six cases, nonvehicle traffic accident in two cases, and falling from height in two cases. All the cases suffered from blunt trauma. The admission GCS of the patients was 4–7 (mean = 5.5). Right-sided decompression surgery and lobectomy were performed for seven patients and left-sided in three cases. The postoperational survival was 60%. All the survivors were functionally independent with mild cognitive disturbances. **Conclusion:** Temporal lobectomy might be added to the surgery to apply all the interventions available in combat with progressively increasing intracerebral pressure as a part of surgical resuscitation.

**Keywords:** Decompressive craniectomy, neurosurgical resuscitation, severe traumatic brain injury, temporal lobectomy

## Introduction

Traumatic brain injuries (TBIs) cause serious morbidity and mortality around the world, especially in the young population. These patients are clinically classified as mild (Glasgow Coma Scale [GCS] 14–15), moderate (GCS 9–13), and severe (GCS <9) according to its severity. Cerebral edema is observed both due to the primary and secondary injury mechanisms in TBIs with or without mass lesions, resulting in an increased intracranial pressure (ICP) and even transtentorial herniation which are associated with high mortality and poor functional outcomes. The target point of the TBI treatment is lowering ICP medically or surgically if indicated. Medical treatments consisted of osmotic diuresis; barbiturate-induced sedation and short-term hyperventilation in the subacute period are the first choice in most cases. Surgical options include cerebrospinal fluid drainage, craniotomy, and decompressive craniectomy (DC)

to relieve elevated ICP. ICP monitoring and ICP-targeted procedures have been recommended by most TBI guidelines. All these treatment options are known as traditional methods, except DC. DC stands for surgical removal of a portion of the skull is in use in the last decades with insufficient level I data in the literature. There are several DC modalities according to anatomic location and portion; bifrontal, large or small frontotemporoparietal, temporoparietal, and temporal. However, our focus is the role of temporal lobectomy which may be considered more aggressive surgical intervention even than DC in the setting of intractable high ICP in specific severe TBI patients. We will present our clinical experience with additional lobectomy in patients who underwent decompressive surgery due to severe head trauma in this study.

## Methods

The ethical approval of the study was provided by The Ethical Committee of Yozgat Bozok University with a reference

**How to cite this article:** Hakan AK, Daltaban IS, Vural S. The role of temporal lobectomy as a part of surgical resuscitation in patients with severe traumatic brain injury. *Asian J Neurosurg* 2019;14:436-9.

**Hakan AK,  
Iskender Samet  
Daltaban,  
Sevilay Vural<sup>1</sup>**

*Departments of Neurosurgery  
and <sup>1</sup>Emergency Medicine,  
Faculty of Medicine,  
Bozok University, Yozgat, Turkey*

### Address for correspondence:

*Dr. Sevilay Vural,  
Department of Emergency  
Medicine, Bozok University  
Research Hospital, Yozgat,  
Turkey.  
E-mail: sevilayvural@yahoo.  
com*

### Access this article online

**Website:** [www.asianjns.org](http://www.asianjns.org)

**DOI:** 10.4103/ajns.AJNS\_240\_18

### Quick Response Code:



This is an open access journal, and articles are distributed under the terms of the Creative Commons Attribution-NonCommercial-ShareAlike 4.0 License, which allows others to remix, tweak, and build upon the work non-commercially, as long as appropriate credit is given and the new creations are licensed under the identical terms.

**For reprints contact:** [reprints@medknow.com](mailto:reprints@medknow.com)

number of 2017-KAEK-189\_2017.11.22\_05. The study was planned to cover 3 years. The files of the patients with severe brain injury admitted between January 2015 and December 2017 were reviewed retrospectively. Patients with missing file information were excluded from the study. Patients who underwent decompression surgery due to severe brain injury (GCS <8) and additional temporal lobectomy included in the study group. Surgical side decision was made according to the presence of bone fracture, epi/subdural, intracerebral hemorrhage/hematoma, and cortical contusion. In case of no accompanying aforementioned lesion/s, the right-sided approach was performed [Figure 1].

The patients with chest and/or abdominal trauma that required surgery or would affect the mortality and under the age of 18 years were also excluded from the study.

## Results

Ten patients were included in the study. Of these patients, seven were male and three were female. The age range of the patients was 22–72 (mean = 41.6). Traumatic etiology was vehicle traffic accident in six cases, nonvehicle traffic accident in two cases, and falling from height in two cases. All the cases suffered from blunt trauma. The admission

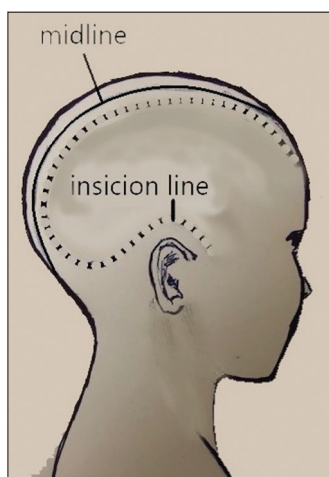


Figure 1: Surgical approach

GCS of the patients was 4–7 (mean = 5.5). All the patients were undergone to surgery within hours from the emergency department. Right-sided decompression surgery and lobectomy were performed for seven patients and left-sided in three cases. Basal cisterns were completely closed in all patients. The post-operational survival was 60%. The mean postoperative survival duration of the patients who died ranged between 2 and 9 days (mean = 6.5 days) [Table 1]. During 9–38 (mean = 20 months) months of follow-up of the survivors, all of them were functionally independent with mild cognitive disturbances.

## Discussion

Primary TBI occurs due to the direct effect of trauma. When it happens, macroscopic and microscopic changes are triggered, and there is no way to reverse or stop it. The first focus of moderate and severe TBI treatment is to sustain clinical stability and to restore optimal cerebral blood flow to minimize secondary brain injury. Because the nature of the fixed size of the skull (Monroe-Kellie Doctrine), any volume increase in intracranial components (blood, brain parenchyma, and cerebrospinal fluid) will cause displacement of these components, increase in ICP, and sometimes it will end up with herniation syndromes. Cerebral swelling and edema are the major macro determinants of the primary and/or secondary injuries by causing hypoperfusion which is associated with poor outcomes.<sup>[1]</sup> Standard medical treatment protocols are well-defined in the current guidelines with little changes over the last decade. These guidelines consist of almost similar recommendations and generally focused on medical interventions other than the surgical management of TBI.<sup>[2-7]</sup> The surgical options are limited with intraventricular ICP monitoring, cerebrospinal fluid drainage, evacuation of hematoma, debridement of the contused brain areas, and DC. Even DC is evaluated as an emerging intervention for severe TBI added recently into the major guidelines with lack of Class I evidence and controversial results.<sup>[8-14]</sup>

Lobectomy may be a new surgical option for specific severe TBI patients; although, it is not covered by current surgical guidelines. In fact, the observation of lobectomy

Table 1: The general patient parameters

Sex	Age	Etiology	GCS	Light reflex	Lobectomy side	Postoperative survival	Postoperative survival duration
Male	42	NMVE	4	-/+	Right	Exitus	7 days
Male	28	MVE	5	+/+	Left	Alive	38 months
Male	54	Fall	5	-/-	Left	Exitus	8 days
Female	48	MVE	7	+/+	Right	Alive	25 months
Female	26	MVE	6	-/+	Right	Alive	23 months
Male	72	Fall	5	-/+	Right	Exitus	2 days
Female	64	NMVE	6	-/-	Left	Exitus	9 days
Male	32	MVE	5	+/+	Right	Alive	21 months
Male	22	MVE	6	+/+	Right	Alive	8 months
Male	28	MVE	6	-/+	Right	Alive	9 months

GCS – Glasgow Coma Scale; NMVE – Nonmotor vehicle accident; MVE – Motor vehicle accident

results in severe TBI patients with medically-refractory intracranial hypertension started in the 90s. However, the low number of patients and the publications makes it hard to extrapolate a conclusion about its clinical effects on survival. While craniectomy stands for removal of a part of the bony portion of the skull, lobectomy can be described as craniectomy plus removal of a brain lobe completely or partially. The main goal of lobectomy based on changing and extending the fixed volume of the skull in the setting of intractable intracranial hypertension or herniation during surgery in a more aggressive and radical way. The first publication in the literature started by Nussbaum *et al.* in 1991.<sup>[15]</sup> They performed complete temporal lobectomy for surgical resuscitation of 10 patients suffering from transtentorial herniation due to unilateral hemispheric edema without any significant focal lesion. Tseng reported more rapid and complete recovery of oculomotor nerve function and motor status in 10 patients with severe TBI and uncal herniation (Group A) treated with reduction of herniated temporal lobe in addition to classical surgical procedures (evacuation of hematoma and debridement of the contused brain areas) comparing to 22 patients (Group B) treated with classical surgical procedures alone.<sup>[16]</sup> Litofsky *et al.* retrospectively investigated 20 blunt severe TBI patients who had intractable ICP or herniation treated with different kinds of lobectomies and found that lobectomy could be a useful adjuvant in the management of severe TBI, especially in rapidly deteriorated young patients.<sup>[17]</sup> Lee *et al.* followed up and compared 29 surgically treated patients by conventional surgery and complete/partial temporal lobectomy who suffered from uncal herniation due to frontotemporal acute subdural hematoma with swelling.<sup>[18]</sup> They determined better survival and functional outcomes in complete temporal lobectomy group. The last publication on the role of lobectomy in severe TBI was held by Oncel *et al.* in 2007.<sup>[19]</sup> They had a relatively large number of patients who underwent frontal lobectomy, temporal lobectomy, or combination/other lobectomy. Their study group consisted of 183 patients who had focal brain lesions with intractable intracranial hypertension or herniation. Their results showed that a lobectomy is an acceptable option.

As mentioned above, it has been reported that frontal, temporal, or combined lobectomies lobectomy was performed additionally after DC in patients with severe TBI. In our cases, the dura layer was opened following the removal of the bone flap (minimum diameter of 12 cm and more) as decompression intervention. After that any focal lesions such as subdural hematoma or contused parenchymal area were debrided, if present. However, in the patients whose brain continues to swell, an anteromedial lobectomy was performed to reduce the likelihood of herniation development.

Other types of temporal lobectomy are available. These can be listed as anterior, anteromedial complete. We thought

that anteromedial lobectomy would be more appropriate because of the anatomical relationships in preventing the transtentorial herniation in our patients. Despite the small number of patients, we achieved successful results of up to 60%. Our results are compatible with the existing publications in the literature.<sup>[15-19]</sup>

## Conclusion

Patients with and medical-refractory high ICP or herniation syndrome secondary to severe TBI should be treated surgically. Lobectomy as a surgical modality is not only a newly defined option but also there is insufficient data to promote its effectivity. Its aggressive nature and rarely usage in clinical practice slow its literary evaluation by evidence-based medicine. The topic needs further high-quality prospective randomized studies.

Temporal lobectomy should be added to the DC surgery to apply all the intervention methods available in this pathology and warfare of especially in patients with severe head trauma in whom cerebral pulsation does not return, and the intraoperative increase of the edema continues although decompression surgery.

## Financial support and sponsorship

Nil.

## Conflicts of interest

There are no conflicts of interest.

## References

1. Stein DM, Hu PF, Brenner M, Sheth KN, Liu KH, Xiong W, *et al.* Brief episodes of intracranial hypertension and cerebral hypoperfusion are associated with poor functional outcome after severe traumatic brain injury. *J Trauma* 2011;71:364-73.
2. Maas AI, Dearden M, Teasdale GM, Braakman R, Cohadon F, Iannotti F, *et al.* EBIC-guidelines for management of severe head injury in adults. European Brain Injury Consortium. *Acta Neurochir (Wien)* 1997;139:286-94.
3. The Society of British Neurological Surgeons. Guidelines for the initial management of head injuries: Recommendations from the Society of British Neurological Surgeons. *Br J Neurosurg* 1998;12:349-52.
4. Bullock MR, Chesnut R, Ghajar J, Gordon D, Hartl R, Newell DW, *et al.* Surgical management of acute subdural hematomas. *Neurosurgery* 2006;58(3 Suppl):S16-24.
5. Adelson PD, Bratton SL, Carney NA, Chesnut RM, du Coudray HE, Goldstein B, *et al.* Guidelines for the acute medical management of severe traumatic brain injury in infants, children, and adolescents. Chapter 17. Critical pathway for the treatment of established intracranial hypertension in pediatric traumatic brain injury. *Pediatr Crit Care Med* 2003;4:1-71.
6. Carney N, Totten AM, O'Reilly C, Ullman JS, Hawryluk GW, Bell MJ, *et al.* Guidelines for the management of severe traumatic brain injury, Fourth Edition. *Neurosurgery* 2017;80:6-15.
7. Grandhi R, Bonfield CM, Newman WC, Okonkwo DO. Surgical management of traumatic brain injury: A review of guidelines, pathophysiology, neurophysiology, outcomes, and controversies. *J Neurosurg Sci* 2014;58:249-59.

8. Hutchinson PJ, Koliass AG, Timofeev I, Corteen E, Czosnyka M, Menon DK, *et al.* Update on the RESCUEicp decompressive craniectomy trial. *Crit Care* 2011;15 Suppl 1:P312.
9. Cooper DJ, Rosenfeld JV, Murray L, Arabi YM, Davies AR, D'Urso P, *et al.* Decompressive craniectomy in diffuse traumatic brain injury. *N Engl J Med* 2011;364:1493-502. Erratum in: *N Engl J Med* 2011;365:2040.
10. Jiang JY, Xu W, Li WP, Xu WH, Zhang J, Bao YH, *et al.* Efficacy of standard trauma craniectomy for refractory intracranial hypertension with severe traumatic brain injury: A multicenter, prospective, randomized controlled study. *J Neurotrauma* 2005;22:623-8.
11. Qiu W, Guo C, Shen H, Chen K, Wen L, Huang H, *et al.* Effects of unilateral decompressive craniectomy on patients with unilateral acute post-traumatic brain swelling after severe traumatic brain injury. *Crit Care* 2009;13:R185.
12. Huang AP, Tu YK, Tsai YH, Chen YS, Hong WC, Yang CC, *et al.* Decompressive craniectomy as the primary surgical intervention for hemorrhagic contusion. *J Neurotrauma* 2008;25:1347-54.
13. Soukiasian HJ, Hui T, Avital I, Eby J, Thompson R, Kleisli T, *et al.* Decompressive craniectomy in trauma patients with severe brain injury. *Am Surg* 2002;68:1066-71.
14. Akyuz M, Ucar T, Acikbas C, Kazan S, Yilmaz M, Tuncer R, *et al.* Effect of early bilateral decompressive craniectomy on outcome for severe traumatic brain injury. *Turk Neurosurg* 2010;20:382-9.
15. Nussbaum ES, Wolf AL, Sebring L, Mirvis S. Complete temporal lobectomy for surgical resuscitation of patients with transtentorial herniation secondary to unilateral hemispheric swelling. *Neurosurgery* 1991;29:62-6.
16. Tseng SH. Reduction of herniated temporal lobe in patients with severe head injury and uncal herniation. *J Formos Med Assoc* 1992;91:24-8.
17. Litofsky NS, Chin LS, Tang G, Baker S, Giannotta SL, Apuzzo ML, *et al.* The use of lobectomy in the management of severe closed-head trauma. *Neurosurgery* 1994;34:628-32.
18. Lee EJ, Chio CC, Chen HH. Aggressive temporal lobectomy for uncal herniation in traumatic subdural hematoma. *J Formos Med Assoc* 1995;94:341-5.
19. Oncel D, Demetriades D, Gruen P, Salim A, Inaba K, Rhee P, *et al.* Brain lobectomy for severe head injuries is not a hopeless procedure. *J Trauma* 2007;63:1010-3.