

# Advanced molecular approaches pave the road to a clear-cut diagnosis of hereditary retinal dystrophies

Zeinab Ravesh,<sup>1</sup> Mahdi Dianatpour,<sup>2</sup> Majid Fardaci,<sup>2</sup> Maryam Taghdiri,<sup>3</sup> Feyzollah Hashemi-Gorji,<sup>1</sup> Vahid Reza Yassaee,<sup>1</sup> Mohammad Miryounesi<sup>1</sup>

<sup>1</sup>Genomic Research Center, Shahid Beheshti University of Medical Sciences, Tehran, Iran; <sup>2</sup>Department of Medical Genetics, School of Medical Sciences, Shiraz University of Medical Sciences, Shiraz, Iran; <sup>3</sup>Comprehensive Medical Genetic Center, Shiraz University of Medical Sciences, Shiraz, Iran

**Purpose:** The aim of this study was to identify the molecular genetic basis of hereditary retinal dystrophies (HRDs) in five unrelated Iranian families.

**Methods:** Whole exome sequencing and Sanger sequencing were performed in all families. Variants were analyzed using various bioinformatics databases and software.

**Results:** Based on the selected strategies, we identified potentially causative variants in five families with HRDs: the novel homozygous deletion mutation c.586\_589delTTTG (p.F196Sfs\*56) in the *TTC8* gene of family A, the novel homozygous missense mutation c.2389T>C (p.S797P) in the *CRBI* gene in family B, the novel homozygous frameshift mutation c.2707dupA (p.S903Kfs\*66) in the *LRP5* gene in family C, the novel homozygous splice mutation c.584-1G>T in the *MERTK* gene in family D, and the novel homozygous missense mutation c.1819G>C (p.G607R) rs61749412 in the *ABCA4* gene of family E.

**Conclusions:** This study highlights the presence of five novel variants associated with retinal dystrophies in selected Iranian families with hereditary blindness.

Hereditary retinal dystrophies (HRDs) are clinically and genetically broad disorders of the retina leading to severe visual impairment. More than 200 genes and loci have been reported to contribute to the genetic diversity and subtypes of retinal dystrophies [1]. Relative to the affected gene, the onset of the phenotype may arise at birth, occur during childhood, or become evident in early adulthood. The overlapping of clinical characteristics intensifies the genetic complexity and hampers accurate clinical diagnosis [2]. Consanguinity plays a significant role in the prevalence of HRDs [3]. Advanced molecular techniques (targeted gene panel, whole genome sequencing [WGS], and whole exome sequencing [WES]) have significantly boosted the detection of candidate variants paving the road to the extensive study of genes and determination of the underlying variations which has now become a crucial process in genotype–phenotype correlation and disease management. Owing to the complex nature of HRDs, next-generation sequencing offers adequate resources and insight into the genetics of novel disease genes and strongly influences genetic counseling for recurrence risk assessment, prenatal diagnosis (PND), as well as helping predict the clinical course of the disease. Overall, amalgamation

of advanced technologies and clinical counseling underpin improvements in disease management and clinical outcome providing greater support for the patient’s everyday life.

The aim of this study was to investigate the genetic basis of hereditary retinal dystrophies in five Iranian families. Applying WES, we report the ascertainment of homozygous mutations in the *TTC8* (Gene ID 123016; OMIM 613464), *CRBI* (Gene ID 23418; OMIM 600105), *LRP5* (Gene ID 4041; OMIM 603506), *MERTK* (Gene ID 10461; OMIM 604705), and *ABCA4* (Gene ID 24; OMIM 601718) genes.

## METHODS

The present study was approved by the Ethical Committee, Deputy of Research Affairs of Shahid Beheshti University of Medical Sciences, following the Declaration of Helsinki. The families presented at the multidisciplinary genetic clinic at Genomic Research Center, Shahid Beheshti University of Medical Sciences (SBMU) and the Comprehensive Shiraz Medical Genetics Center for genetic counseling and investigation of the underlying cause of blindness in their families.

### Clinical description:

**Family A**—Family A is a non-consanguineous family of north Iranian descent in the Mazandaran province with two affected children (Figure 1). The proband is a 7-year-old girl with developmental delays born via uncomplicated

Correspondence to: Mohammad Miryounesi, Genomic Research Center, Shahid Beheshti University of Medical Sciences, Tehran-1985717413, Iran; Phone: +98 21 22439959; FAX: +98 21 2243996; email: miryounesi@sbmu.ac.ir

Caesarean section. She presented speech and mental delays, autistic behavior, and nephronophthisis. Visual problems appeared at the age of 3 when the patient was unable to move around and stood still in dim light conditions. At present, she is incapable of noticing objects and may trip if not warned. Her older brother also expresses similar features of visual impairment but is healthy otherwise. Based on an overview of the clinical examinations, age at presentation, and family history, WES was proposed to the family.

**Family B**—The proband is a 10-year-old healthy boy born to first-cousin parents from the city of Shiraz (Figure 1). When he was 5 months old, his parents realized his lack of attention to objects. He turned his head only at noises. Ophthalmic examination confirmed roving eye movements and congenital retinal dysgenesis in both eyes. Fundus

examination revealed pigmentary changes (Figure 2A; Table 1). He has had a progressive decrease in visual acuity, and at present, despite being able to notice light, he cannot distinguish colors. The patient has nystagmus and nyctalopia. He attends a school for the blind and uses the Braille system to read and write. The patient is mentally stable and physically healthy. There was no previous family history of genetic disorders. WES was recommended to the family for further investigations of the genetic defect.

**Family C**—A 6-month-old girl was born to consanguineous parents in Shiraz via normal vaginal delivery. There was no evidence of genetic disorders in the family pedigree (Figure 1). At 2 months of age, the patient was in constant distress, but as her parents and doctors were unable to localize the pain, the infant lost vision in both eyes due to

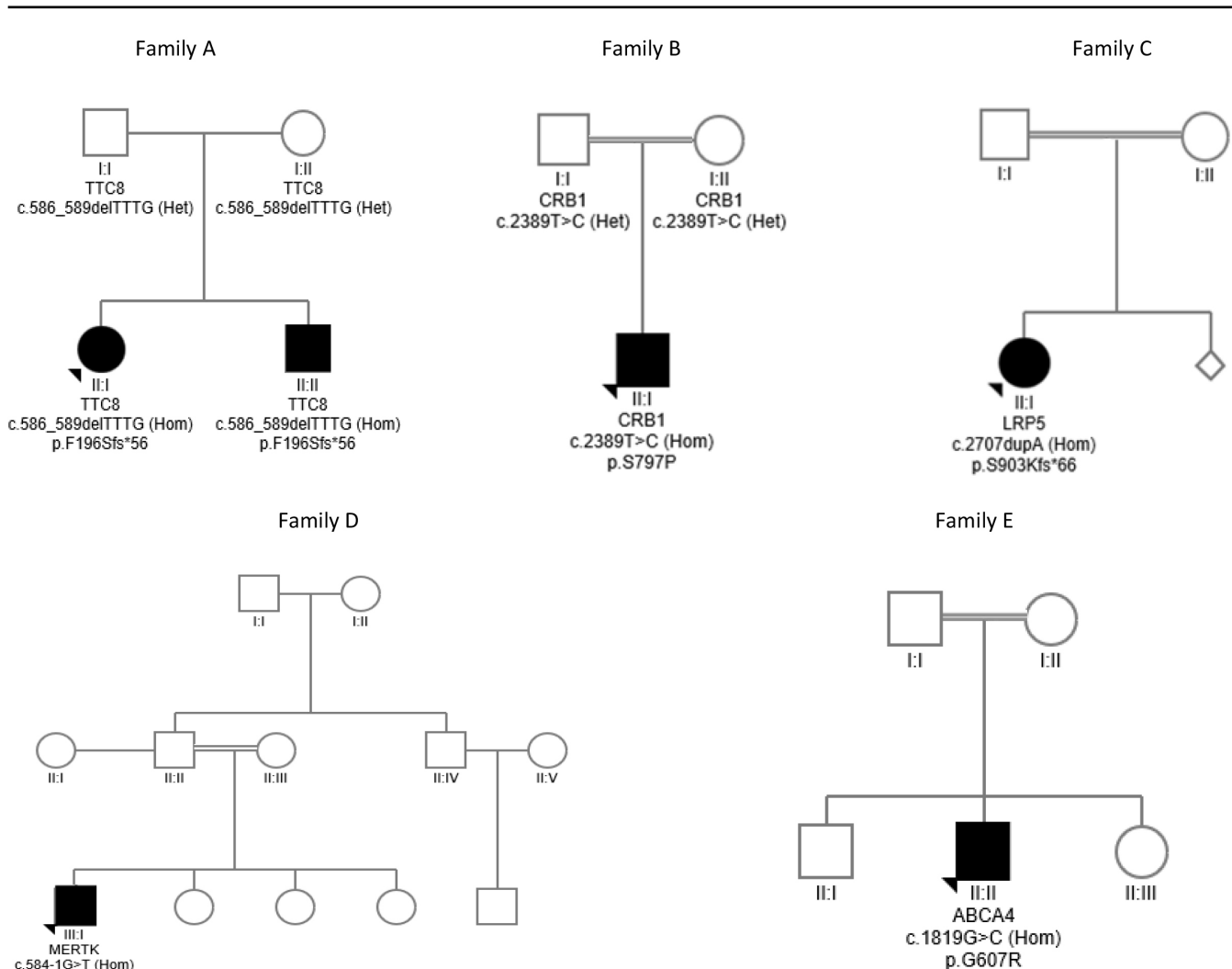


Figure 1. Overview of the pedigree and genotyping results of the participating families. Genotypes and cosegregation results are provided for all probands and available family members. Proband is indicated with an arrow. Affected individuals are shown in black. Hom=Homozygous, Het=Heterozygous.

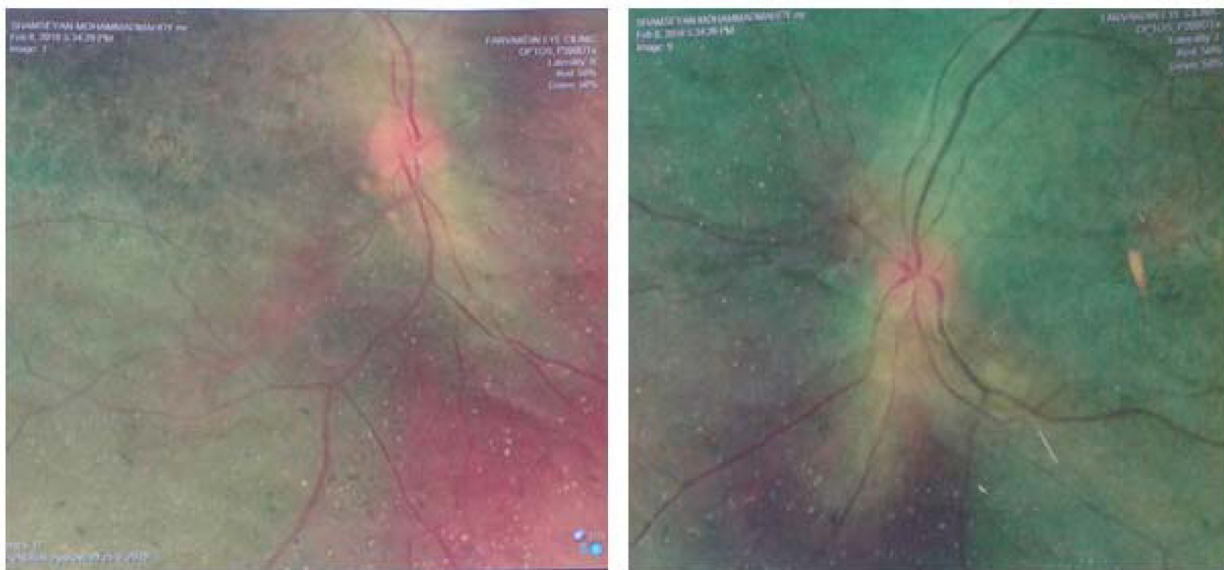ocular hypertension. Subsequently, she had bilateral retinal detachment, bilateral persistent hyperplastic primary vitreous (PHPV), and arterial septal defect (ASD). With respect to the clinical evidence and the lack of a clearcut diagnosis, WES was offered to the family.

**Family D**—A 33-year-old man with visual defect from the city of Ilam was born to consanguineous parents (Figure 1). At the age of 8, he experienced night blindness followed by gradual loss of peripheral vision. By the age of 23, he had difficulty reading and writing and could not recognize colors.

Fundus examination showed widespread retinal degeneration (Figure 2B; Table 1). At present, he uses a Zoomax electronic magnifier to read. The patient underwent cataract surgery. His cousin also experienced similar visual symptoms but did not seek genetic counseling. The patient wanted to get married and was curious to learn about the genetic basis of his blindness. WES was advised to the patient.

**Family E**—A 30-year-old man from Hamedan province was born to first-cousin parents (Figure 1). When he was 13, the first symptoms of loss of central vision emerged followed

A)



B)

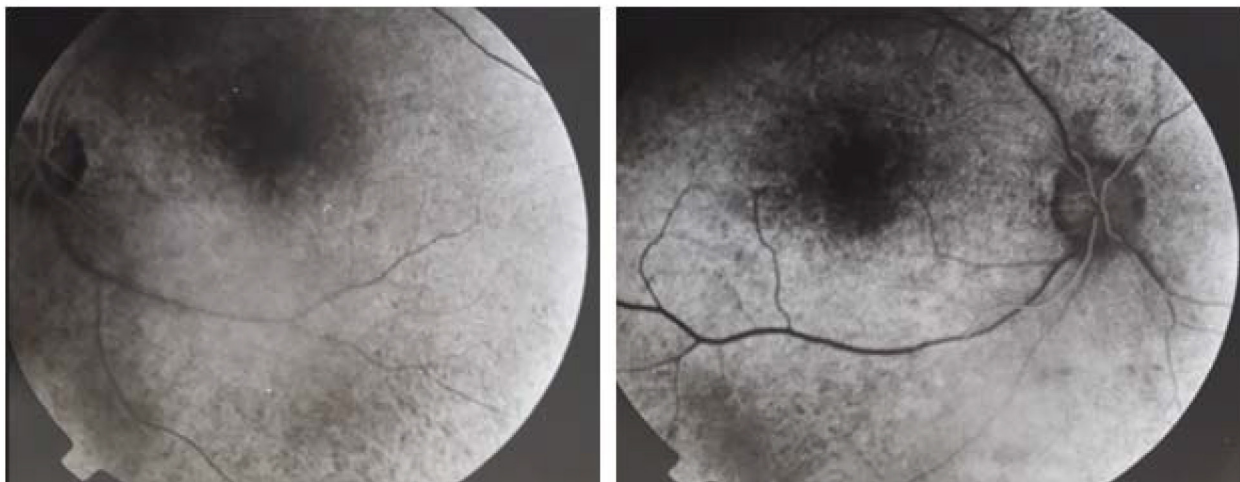


Figure 2. Fundus photograph of affected individuals. **A:** Left and right eyes of proband (II:I) of family B presenting Drusen-like spots, attenuated vessels, pallor optic disc, and pigmentary changes. **B:** Left and right eyes of proband (III:I) of family D showing diffuse pigmentary retinal degeneration, bony spicule, attenuated vessels, and optic disc pallor.

Table 1.

Family	Patient ID	Gender (M/F)	Age (m/y)	Age at disease onset (m/y)	Visual Acuity	Color Vision	Fundus Examination	Diagnosis
<b>A</b>	III: I	F	7 y	3 y	CF and CF	Absent	N/A	Bardet Biedl syndrome
<b>B</b>	III: I	M	10 y	5 m	LP and LP	Absent	Pigmentary changes Drusen-like deposits Pallor optic disc Attenuated vessels	Leber congenital Amaurosis
<b>C</b>	III: I	F	6 m	2 m	N/A	Absent	N/A	Familial exudative vitreoretinopathy
<b>D</b>	III: I	M	33 y	8 y	20/60 and 20/70	Absent	Bone Spicules Pigmentary changes Pallor optic disc Attenuated vessels	Retinitis Pigmentosa
<b>E</b>	II: II	M	30 y	13 y	CF and CF LP and LP	Present	Macular hyperpigmentation Chorioretinal scars	Stargardt disease

M=Male, F=Female, m=months, y=years, CF=Count finger, LP=Light perception, N/A=Not available

by gradual loss of visual acuity. Fundus examination detected macular degeneration (Table 1). At present, the patient has normal peripheral vision in both eyes; however, he experiences difficulty adjusting to dim and dark light conditions. He is able to differentiate colors but is unable to notice details in the objects. He also has strabismus for which he did not undergo surgery. The patient wished to marry a healthy woman and was interested in a risk assessment to perform PND during every pregnancy. Based on the absence of a history of genetic disorders in the family and the desire of the bride's family, the patient requested WES.

**Genetic analysis:** Peripheral blood samples were collected from the patients and their family members after written informed consent was obtained. Peripheral blood (3-5 ml) was collected from affected individuals and their parents where these were available by venepuncture and drawn in BD vacutainer® EDTA blood collection tubes (BD Biosciences, Oxford UK). Samples were stored at 4 °C prior to use. Genomic DNA was extracted from peripheral blood leukocytes as according to standard procedures. WES was initially performed (Macrogen Inc., Seoul, Korea) on the probands to sequence close to 100 million reads on an Illumina HiSeq4000 Sequencer (Macrogen Inc. Seoul, Korea) with paired-end sequencing, read length 101 bp, and coverage of 100X. Exon enrichment was performed according to the SureSelect Human All Exon kit (Agilent). The sequencing read was aligned and mapped to hg19 from the [UCSC Genome Browser](#), and identified variants were annotated and filtered using the in-house developed annotation pipeline based on ANNOVAR. After extensive filtration using databases such as [1000 genome](#), [ExAC](#), and [Varsome](#), we ended up with more than 1,000 genetic variations. Focusing on homozygous variants (minor allele frequency [MAF]<0.001), they were prioritized based on their pathogenicity degree, and variants in genes related to hereditary retinal dystrophies were selected for interpretation. Genomic DNA was analyzed by PCR using ABI 9700 PCR System (Applied Biosystems) and Sanger sequencing using specific primers ([Primer3](#)) for amplifying all exons and exon-intron boundaries of the identified variants in *TTC8*, *CRBI*, *MERTK*, and *ABCA4* (Primer sequences can be provided upon request). Results were analyzed using Lasergene SeqMan Pro software (DNASTAR, Madison, WA; Figure 3). Furthermore, protein modeling was conducted to assess the structural and functional effects of the identified mutations.

## RESULTS

Five native Iranian families from across the country were investigated in this study. Despite the variability and severity of the phenotypic presentations, all affected patients had moderate to severe loss of visual acuity (Table 1). To identify the causative mutations, genomic DNA of the affected patients were analyzed through WES. Molecular approaches identified five novel homozygous mutations: the deletion mutation c.586\_589delTTTG (p.F196Sfs\*56) in the *TTC8* gene of family A associated with Bardet-Biedl syndrome, the missense mutation c.2389T>C (p.S797P) in the *CRBI* gene (*ClinVar* SCV000746539.1) in family B associated with Leber congenital amaurosis, the frameshift mutation c.2707dupA (p.S903Kfs\*66) in the *LRP5* gene associated with familial exudative vitreoretinopathy in family C, the splice mutation c.584-1G>T in the *MERTK* gene (*ClinVar* SCV000588383.1) associated with retinitis pigmentosa in family D, and the missense mutation c.1819G>C (p.G607R) rs61749412 in the *ABCA4* gene (*ClinVar* SCV000117568) associated with Stargardt disease in family E (Table 2). Mutation nomenclature was based on cDNA nucleotide position according to Ensembl and [Mutalyzer 2.0.28](#). To interpret the pathogenicity of the sequence alterations, we implemented in silico analyses using different prediction programs and software, including [Provean](#), [SIFT](#), [Mutation Taster](#), and Combined Annotation Dependent Depletion ([CADD](#)) [4-7]. cosegregation was performed in families A and B to verify the genotype-phenotype correlation (Figure 3).

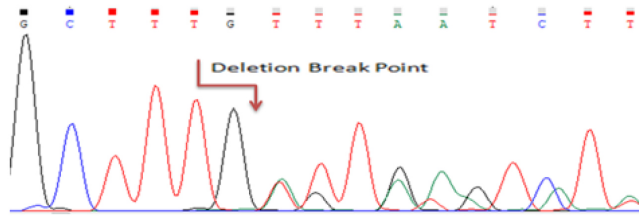
## DISCUSSION

Hereditary retinal dystrophies are a group of heterogeneous disorders caused by mutations in more than 200 genes [1]. HRDs can be subdivided into different groups based on the primary degeneration of rod or cone photoreceptor cells. This study was conducted to investigate the underlying HRD genes and mutations in five families from Iran.

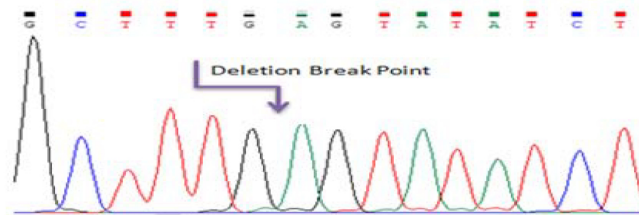The *MERTK* gene is predominantly associated with retinitis pigmentosa (OMIM [613862](#)). It encodes a 984-amino acid protein localized at the membrane of the RPE and is a key element in the process of outer segment (OS) phagocytosis [8]. The RPE undergoes one of the largest phagocytic burdens in the body [9]. Mutations in the *MERTK* gene hinder phagocytic engulfment of the OS by the RPE causing accumulation of debris between the RPE and photoreceptors leading to progressive degeneration of the retinal cells [10,11]. The c.584-1 G>T splice site mutation may alter or abolish correct mRNA splicing during the process of precursor mRNA maturation.

**Family A: (TTC8) c.586\_589delTTTG**

Heterozygous Carrier

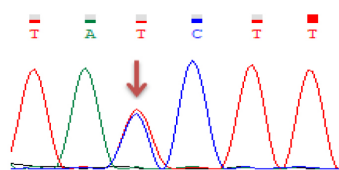


Homozygous Affected

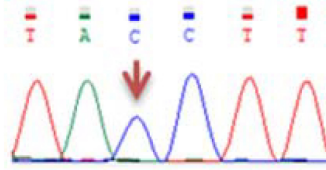


**Family B: (CRB1) c.2389T>C**

Heterozygous Carrier

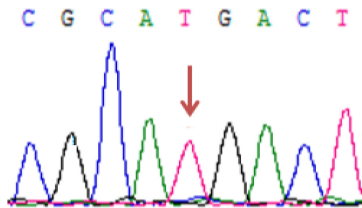


Homozygous Affected



**Family D: (MERTK) c.584-1G>T**

Homozygous Affected



**Family E: (ABCA4) c.1819G>C**

Homozygous Affected

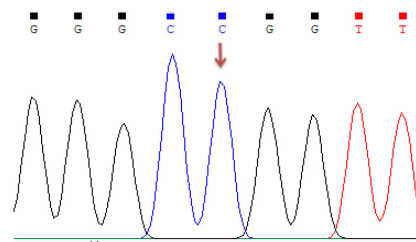


Figure 3. Chromatogram of families A, B, D, and E presenting homozygous affected and cosegregation analysis in the kindred. Arrow indicates the location of the nucleotide variation.

Defects in the *CRB1* gene account for a series of autosomal recessive retinal dystrophies, such as Leber congenital amaurosis (LCA; OMIM 613835) [12]. It is a large complex mapped to chromosome 1q31.3 [13,14] and is located in the microvilli and the outer plexiform layer of Müller glial cells and in the inner segments of photoreceptors [15]. *CRB1* contains three laminin G-like domains that form the globular

part of the protein. In this mutation c. 2389T>C (p.S797P), the serine amino acid at position 797 is located in the second laminin G-like domain (LAMG 2), and substitution of this amino acid with proline affects interaction with other proteins [16] (Figure 4). A functional glitch of the *CRB1* gene results in several types of retinal dystrophies, including early-onset RP, telangiectasia, and mild retinopathies [17,18].

Table 2.

Family	Gene	RefSeq ID	Nucleotide Variant	Amino Acid Alteration	Zygoty	Prediction Tools			ACMG Classification
						Provean	SIFT	CADD Score	
<b>A</b>	<i>TTC8</i>	NM_144596	c.586_589delTTTG	p.F196Sfs*56	Hom.	N/A	N/A	35	Likely Pathogenic
<b>B</b>	<i>CRBI</i>	NM_201253	c.2389T>C	p.S797P	Hom.	Damaging	Damaging	18.47	Likely Pathogenic
<b>C</b>	<i>LRP5</i>	NM_001291902	c.2707dupA	p.S903Kfs*66	Hom.	N/A	N/A	35	Likely Pathogenic
<b>D</b>	<i>MERTK</i>	NM_006343	c.584-1G>T	Splice Defect	Hom.	N/A	N/A	N/A	Likely Pathogenic
<b>E</b>	<i>ABCA4</i>	NM_000350	c.1819G>C	p.G607R	Hom.	Damaging	Damaging	33	Pathogenic

Hom.=Homozygous, N/A=Not available

The *ABCA4* gene encodes a 2273 amino acid protein produced by the photoreceptor cells in the retina. This protein is specifically active during phototransduction to remove a potentially toxic substance called N-retinylidene-PE from the photoreceptors. Mutations in the *ABCA4* gene result in accumulation of toxin products causing Stargardt disease (OMIM 248200), a condition generating injury and loss of function in the light receptor cells [19,20]. The c.1819G>C (p.G607R) mutation leads to substitution of the arginine amino acid at position 607 in the *ABCA4* gene. Thus far, two variants at this position, c.1819G>A (p.G607R) and c.1819G>T (p.G607W), have been associated with Stargardt disease [21,22]. The results of this study together with results from previous studies show that position 607 is a hotspot in this gene. *ABCA4* has high sequence homology with *ABCA1*, and protein modeling based on PDB 5XJY suggests that the

side chain of the arginine probably inhibits correct folding of the protein (Figure 4).

The *LRP5* gene, positioned to chromosome 11q13.2, encodes single-pass transmembrane receptors that communicate with the seven-pass transmembrane receptor to bind wingless (Wnt) proteins to activate the canonical Wnt- $\beta$ -catenin pathway essential for angiogenesis of the retina [23-25]. Familial exudative vitreoretinopathy (FEVR, OMIM 133780) is a group of hereditary disorders of the retina generated by the premature vascularization of the peripheral retina leading to retinal neovascularization or tractional retinal detachment [26,27]. Thus far, mutations in the *LRP5*, *NDP* (Gene ID 4693; OMIM 310600), *FZD4* (Gene ID 8322; OMIM 133780), and *TSPAN12* (Gene ID 23554; OMIM 613138) genes are known to account for FEVR. The c.2707dupA (p.S903Kfs\*66) mutation in *LRP5* is located at the extracellular binding domain of the protein sequence.

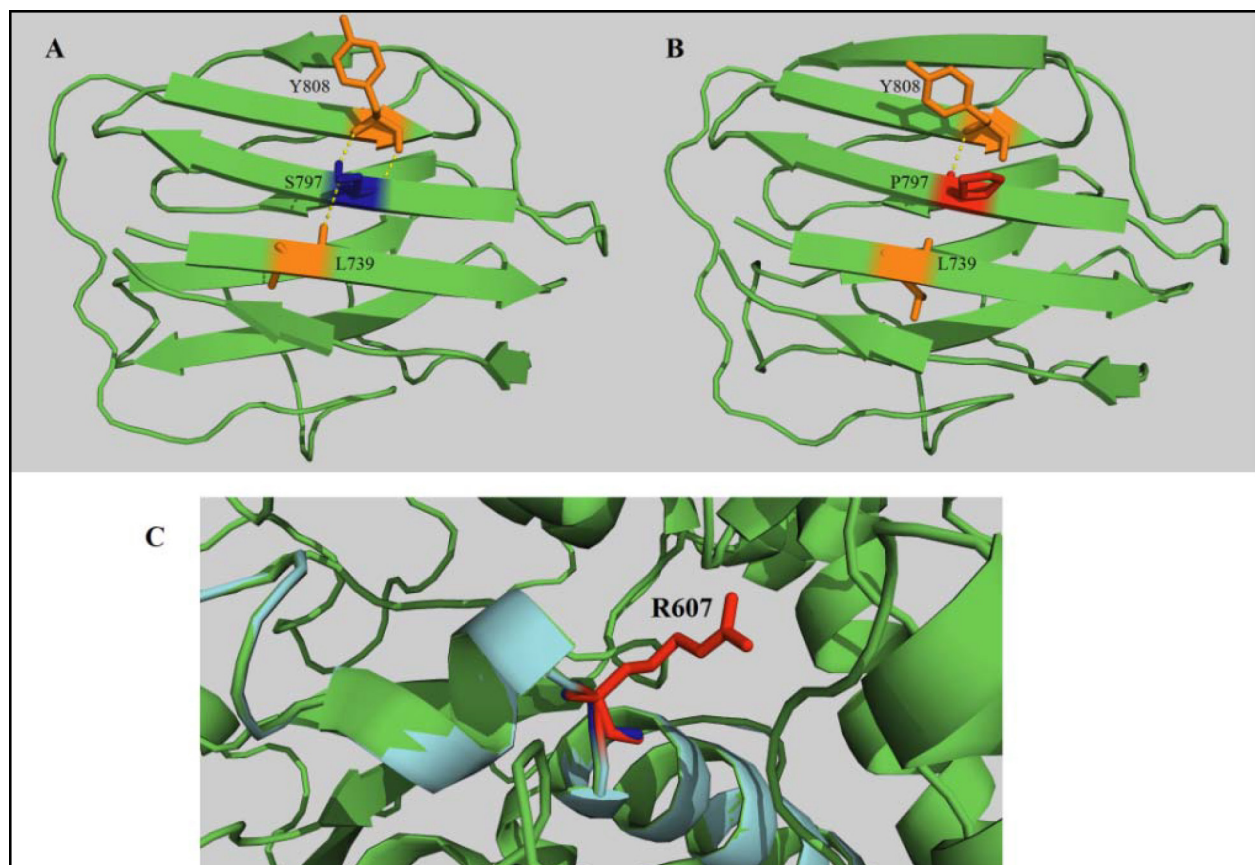


Figure 4. Schematic representation of S797P substitution in the LAMG domain of the *CRBI* 336 gene. **A:** Modeling of LAMG 2 (amino acids from 735 to 860) using Phyre2 showed 337 that S797 (wild type in blue) is located in beta-sheet and has polar contacts with L739 (in 338 orange) and Y808 (in orange) which are also located in the beta-sheet of the second laminin G-339 like domain. Substitution of proline at position 797 (mutant type in red) is conducive to the beta-340 sheet. **B:** It can hinder the binding of other proteins or result in destabilization of the protein 341 structure and protein folding. **C:** Schematic presentation of the G607R substitution in the *ABCA4* 342 gene. Wild-type residue glycine in blue and mutated residue arginine in red are shown at position 343 607.



Therefore, frameshift mutations in this region are likely pathogenic and may lead to protein truncation or nonsense mediated mRNA decay (NMD) [28].

Bardet-Biedl syndrome (BBS; OMIM 209900) is a genetically heterogeneous disorder associated with progressive early-onset retinitis pigmentosa, polydactyly, renal abnormalities, obesity, hypogonadism, and mental disability [29]. BBS is a member of group of ciliopathies needed to modulate intraflagellar transport (IFT) [30]. Cilia play an essential role regulating and maintaining the photoreceptor cells [31]. To date, 21 BBS genes (BBS1–21) have been identified [32]. Seven BBS proteins (BBS1, BBS2, BBS4, BBS5, BBS7, TTC8/BBS8, and BBS9) which form the BBSome complex are involved in the intracellular vesicular transport and ciliogenesis [33]. The encoded protein mediates protein–protein interactions and the assembly of multiprotein complexes through its tetratricopeptide repeat (TRP) motif consisting of six tandem repeats of 34 amino acids each [34]. The mutation in the *TTC8* gene, c.586\_589delTTTG (p.F196Sfs\*56), may result in the production of a truncated protein or NMD.

In summary, hereditary retinal dystrophies are degenerative diseases of the retina with common clinical and genetic presentations. The complexity and wide phenotypic spectrum of the HRDs often create a challenge in definite diagnosis of the disorder. In such circumstances, genetic testing could help to delete the clinical ambiguity. The data presented in this study are novel and have not been reported in any population to date. These data highlight the importance of meticulous clinical diagnosis for lifestyle management of patients with visual disabilities. The need to uncover genetic diagnosis of HRDs is particularly important in the development of gene therapy–based treatments, prenatal diagnosis, and advances in reproductive options. Therefore, the combination of precise clinical and advanced molecular diagnoses may open new horizons for therapeutic services aiding future decision-making and assisting with research. It is anticipated that this approach could minimize the risk of hereditary retinal diseases in relevant Iranian families.

#### ACKNOWLEDGMENTS

We thank the patients and their family members for their cooperation and for participating in this study.

#### REFERENCES

- Weisschuh N, Mayer AK, Strom TM, Kohl S, Glöckle N, Schubach M, Andreasson S, Bernd A, Birch DG, Hamel CP, Heckenlively JR, Jacobson SG, Kamme C, Kellner U, Kunstmann E, Maffei P, Reiff CM, Rohrschneider K, Rosenberg T, Rudolph G, Vámos R, Varsányi B, Weleber RG, Wissinger B. Mutation Detection in Patients with Retinal Dystrophies Using Targeted Next Generation Sequencing. *PLoS One* 2016; 11:e0145951-[PMID: 26766544].
- Ravesh Z, E Asrag ME, Weisschuh N, McKibbin M, Reuter P, Watson CM, Baumann B, Poulter JA, Sajid S, Panagiotou ES, O’Sullivan J, Abdelhamed Z, Bonin M, Soltanifar M, Black GC, Amin-ud Din M, Toomes C, Ansar M, Inglehearn CF, Wissinger B, Ali M. Novel C8orf37 mutations cause retinitis pigmentosa in consanguineous families of Pakistani origin. *Mol Vis* 2015; 21:236-43. [PMID: 25802487].
- Khan AO. Ocular genetic disease in the Middle East. *Curr Opin Ophthalmol* 2013; 24:369-78. [PMID: 23846189].
- Choi Y, Chan AP. PROVEAN web server: a tool to predict the functional effect of amino acid substitutions and indels. *Bioinformatics* 2015; 31:2745-7. [PMID: 25851949].
- Ng PC, Henikoff S. SIFT: Predicting amino acid changes that affect protein function. *Nucleic Acids Res* 2003; 31:3812-4. [PMID: 12824425].
- Schwarz JM, Rodelsperger C, Schuelke M, Seelow D. MutationTaster evaluates disease-causing potential of sequence alterations. *Nat Methods* 2010; 7:575-576-[PMID: 20676075].
- Kircher M, Witten DM, Jain P, O’Roak BJ, Cooper GM, Shendure J. A general framework for estimating the relative pathogenicity of human genetic variants. *Nat Genet* 2014; 46:310-5. [PMID: 24487276].
- Shelby SJ, Feathers KL, Ganos AM, Jia L, Miller JM, Thompson DA. MERTK signaling in the retinal pigment epithelium regulates the tyrosine phosphorylation of GDP dissociation inhibitor alpha from the GDI/CHM family of RAB GTPase effectors. *Exp Eye Res* 2015; 140:28-40. [PMID: 26283020].
- Strick DJ. Mertk Drives Myosin II Redistribution during Retinal Pigment Epithelial Phagocytosis. *Invest Ophthalmol Vis Sci* 2009; 50:2427-35. [PMID: 19117932].
- Shelby SJ, Feathers KL, Ganos AM, Jia L, Miller JM, Thompson DA. MERTK signaling in the retinal pigment epithelium regulates the tyrosine phosphorylation of GDP dissociation inhibitor alpha from the GDI/CHM family of RAB GTPase effectors. *Exp Eye Res* 2015; 140:28-40. [PMID: 26283020].
- LaVail MM. Legacy of the RCS rat: impact of a seminal study on retinal cell biology and retinal degenerative diseases. *Prog Brain Res* 2001; 131:617-27. [PMID: 11420975].
- Lu L, Wang X, Lo D, Weng J, Liu X, Yang J, He F, Wang Y, Liu X. Novel mutations in *CRB1* gene identified in a chinese pedigree with retinitis pigmentosa by targeted capture and next generation sequencing. *Oncotarget* 2016; 7:79797-804. [PMID: 27806333].
- den Hollander AI, ten Brink JB, de Kok YJ, van Soest S, van den Born LI, van Driel MA, van de Pol DJ, Payne AM, Bhat-tacharya SS, Kellner U, Hoyng CB, Westerveld A, Brunner HG, Bleeker-Wagemakers EM, Deutman AF, Heckenlively JR, Cremers FP, Bergen AA. Mutations in a human

- homologue of *Drosophila* crumbs cause retinitis pigmentosa (RP12). *Nat Genet* 1999; 23:217-21. [PMID: 10508521].
14. den Hollander AI, Davis J, van der Velde-Visser SD, Zonneveld MN, Pierrottet CO, Koenekoop RK, Kellner U, van den Born LI, Heckenlively JR, Hoyng CB, Handford PA, Roepman R, Cremers FP. CRB1 mutation spectrum in inherited retinal dystrophies. *Hum Mutat* 2004; 24:355-69. [PMID: 15459956].
  15. Quinn PM, Pellissier LP, Wijnholds J. The CRB1 Complex: Following the Trail of Crumbs to a Feasible Gene Therapy Strategy. *Front Neurosci* 2017; 11:175-[PMID: 28424578].
  16. Richard M, Muschalik N, Grawe F, Ozüyan S, Knust E. A role for the extracellular domain of Crumbs in morphogenesis of *Drosophila* photoreceptor cells. *Eur J Cell Biol* 2009; 88:765-77. [PMID: 19717208].
  17. Pellissier LP, Alves CH, Quinn PM, Vos RM, Tanimoto N, Lundvig DM, Dudok JJ, Hooibrink B, Richard F, Beck SC, Huber G, Sothilingam V, Garcia Garrido M, Le Bivic A, Seeliger MW, Wijnholds J. Targeted ablation of CRB1 and CRB2 in retinal progenitor cells mimics Leber congenital amaurosis. *PLoS Genet* 2013; 9:e1003976-[PMID: 24339791].
  18. Alves CH, Sanz AS, Park B, Pellissier LP, Tanimoto N, Beck SC, Huber G, Murtaza M, Richard F, Sridevi Gurubaran I, Garcia Garrido M, Levelt CN, Rashbass P, Le Bivic A, Seeliger MW, Wijnholds J. Loss of CRB2 in the mouse retina mimics human retinitis pigmentosa due to mutations in the CRB1 gene. *Hum Mol Genet* 2013; 22:35-50. [PMID: 23001562].
  19. Mullins RF, Kuehn MH, Radu RA, Enriquez GS, East JS, Schindler EI, Travis GH. Stone. Autosomal recessive retinitis pigmentosa due to ABCA4 mutations: clinical, pathologic, and molecular characterization. *Invest Ophthalmol Vis Sci* 2012; 53:1883-94. [PMID: 22395892].
  20. Weng J, Mata NL, Azarian SM, Tzekov RT, Birch DG, Travis GH. Insights into the function of Rim protein in photoreceptors and etiology of Stargardt's disease from the phenotype in aber knockout mice. *Cell* 1999; 98:13-23. [PMID: 10412977].
  21. Rivera A, White K, Stöhr H, Steiner K, Hemmrich N, Grimm T, Jurklics B, Lorenz B, Scholl HP, Apfelstedt-Sylla E, Weber BH. A comprehensive survey of sequence variation in the ABCA4 (ABCR) gene in Stargardt disease and age-related macular degeneration. *Am J Hum Genet* 2000; 67:800-13. [PMID: 10958763].
  22. Webster AR, Héon E, Lotery AJ, Vandenburgh K, Casavant TL, Oh KT, Beck G, Fishman GA, Lam BL, Levin A, Heckenlively JR, Jacobson SG, Weleber RG, Sheffield VC, Stone EM. An analysis of allelic variation in the ABCA4 gene. *Invest Ophthalmol Vis Sci* 2001; 42:1179-89. [PMID: 11328725].
  23. Wehrli M, Dougan ST, Caldwell K, O'Keefe L, Schwartz S, Vaizel-Ohayon D, Schejter E, Tomlinson A, DiNardo S. Arrow encodes an LDL-receptor-related protein essential for Wingless signalling. *Nature* 2000; 407:527-30. [PMID: 11029006].
  24. Pinson KI, Brennan J, Monkley S, Avery BJ, Skarnes WC. An LDL-receptor-related protein mediates Wnt signalling in mice. *Nature* 2000; 407:535-8. [PMID: 11029008].
  25. Sızmaç S, Yonekawa Y, T Trese M. Familial Exudative Vitreoretinopathy. *Turk J Ophthalmol*. 2015; 45:164-8. [PMID: 27800225].
  26. Criswick VG, Schepens CL. Familial exudative vitreoretinopathy. *Am J Ophthalmol* 1969; 68:578-94. [PMID: 5394449].
  27. Van Noyhuys CESigns, complications, and platelet aggregation in familial exudative vitreoretinopathy. van Noyhuys CE. *Am J Ophthalmol* 1991; 111:34-41. [PMID: 1985487].
  28. Salvo J, Lyubasyuk V, Xu M, Wang H, Wang F, Nguyen D, Wang K, Luo H, Wen C, Shi C, Lin D, Zhang K, Chen R. Next-generation sequencing and novel variant determination in a cohort of 92 familial exudative vitreoretinopathy patients. *Invest Ophthalmol Vis Sci* 2015; 56:1937-46. [PMID: 25711638].
  29. Hernandez-Hernandez V, Pravincumar P, Diaz-Font A, May-Simera H, Jenkins D, Knight M, Beales PL. Bardet-Biedl syndrome proteins control the cilia length through regulation of actin polymerization. *Hum Mol Genet* 2013; 22:3858-68. [PMID: 23716571].
  30. Blacque OE, Reardon MJ, Li C, McCarthy J, Mahjoub MR, Ansley SJ, Badano JL, Mah AK, Beales PL, Davidson WS, Johnsen RC, Audeh M, Plasterk RH, Baillie DL, Katsanis N, Quarby LM, Wicks SR, Leroux MR. Loss of *C. elegans* BBS-7 and BBS-8 protein function results in cilia defects and compromised intraflagellar transport. *Genes Dev* 2004; 18:1630-42. [PMID: 15231740].
  31. Taub DG, Liu Q. The Role of Intraflagellar Transport in the Photoreceptor Sensory Cilium. *Adv Exp Med Biol* 2016; 854:627-33. [PMID: 26427468].
  32. Ullah A, Umair M, Yousaf M, Khan SA, Nazim-Ud-Din M, Shah K, Ahmad F, Azeem Z, Ali G, Alhaddad B, Rafique A, Jan A, Haack TB, Strom TM, Meitinger T, Ghous T, Ahmad W. Sequence variants in four genes underlying Bardet-Biedl syndrome in consanguineous families. *Mol Vis* 2017; 23:482-94. [PMID: 28761321].
  33. Nachury MV, Loktev AV, Zhang Q, Westlake CJ, Peränen J, Merdes A, Slusarski DC, Scheller RH, Bazan JF, Sheffield VC, Jackson PK. A core complex of BBS proteins cooperates with the GTPase Rab8 to promote ciliary membrane biogenesis. *Cell* 2007; 129:1201-13. [PMID: 17574030].
  34. Das AK, Cohen PW, Barford D. The structure of the tetratripeptide repeats of protein phosphatase 5: implications for TPR-mediated protein-protein interactions. *EMBO J* 1998; 17:1192-9. [PMID: 9482716].

Articles are provided courtesy of Emory University and the Zhongshan Ophthalmic Center, Sun Yat-sen University, P.R. China. The print version of this article was created on 19 October 2018. This reflects all typographical corrections and errata to the article through that date. Details of any changes may be found in the online version of the article.