

Skin fragility syndrome in a cat with feline infectious peritonitis and hepatic lipidosis

Tara K. Trotman*, Elizabeth Mauldin†, Vickie Hoffmann§, Fabio Del Piero‡ and Rebecka S. Hess*

*Departments of Clinical Studies and †Pathobiology, School of Veterinary Medicine, University of Pennsylvania, Philadelphia, Pennsylvania 19104-6010, USA

‡Departments of Pathobiology and Clinical Studies New Bolton Center, School of Veterinary Medicine, University of Pennsylvania, Kennett Square, Pennsylvania 19348, USA

§Present address: Division of Veterinary Resources, National Institutes of Health, 28 Library Drive, MSC 5230, Bethesda, MD 20892-5280, USA

Correspondence: Tara K. Trotman, Department of Clinical Studies-Philadelphia, School of Veterinary Medicine, University of Pennsylvania, 3900 Delancey Street, Philadelphia, PA 19104-6010, USA. Tel.: +1 215 573 4352; Fax: +1 215 573 6050; E-mail: trotman@vet.upenn.edu

What is known about the topic of this paper

- Feline infectious peritonitis (FIP) is a common and often fatal disease recognized in our feline patients.
- Feline acquired skin fragility is a rare disorder that has been associated with several underlying disease processes.

What this paper adds to the field of veterinary dermatology

- FIP is a common disease in cats, and it may be difficult to diagnose antemortem. Recognition of all possible clinical signs associated with FIP may facilitate a clinical suspicion and diagnosis of FIP.
 - Clinicians should be aware that cats presenting with skin tears may have underlying debilitating diseases such as FIP.
-

Abstract

A 6-year-old spayed female domestic shorthair cat with a 3-week history of inappetence, weight loss, and hiding was examined. A palpable abdominal fluid wave, dehydration, and a small tear on the left flank were noted during initial examination. When the cat was gently restrained for blood sampling, the skin on the dorsal neck tore, leaving a 15 cm × 7 cm flap of skin. Clinicopathological abnormalities included non-regenerative anaemia, hypoalbuminaemia, increased globulin concentration, and mildly elevated aspartate aminotransferase and alkaline phosphatase activities. Abdominal fluid was viscous and had a total protein of 5.3 g dL⁻¹ with 316 cells μL⁻¹, consistent with a modified transudate. Cytology of the abdominal fluid revealed 86% nondegenerate neutrophils, 13% macro-

phages, and 1% small lymphocytes. Histopathological evaluation and indirect immunohistochemistry confirmed a diagnosis of feline infectious peritonitis, hepatic lipidosis and feline skin fragility syndrome. Feline skin fragility syndrome has not previously been reported in association with feline infectious peritonitis (FIP). Its inclusion as a clinical sign associated with FIP may facilitate a diagnosis.

Accepted 03 July 2007

Introduction

Feline skin fragility syndrome (FSFS) is characterized by markedly fragile, thin skin, usually in middle-aged to older cats with no previous history of skin tears.^{1,2} The skin is damaged readily by minor trauma, and irregular tears may cause shedding of sheets of skin.^{1,2} Histological changes in the skin are distinctive, and characterized by a thin epidermis, with a severely atrophic dermis.^{1,2} Dermal collagen fibres are thin and disorganized.¹ Hair follicles may be uniformly short and thin, but the dermal atrophy is the most striking feature in this condition,² and the panniculus is often not represented.^{1,2} FSFS is an uncommon acquired disease¹ that has been reported to be associated with conditions such as diabetes mellitus,² excessive use of progestational drugs² and spontaneous or iatrogenic hyperadrenocorticism.^{3,4} FSFS has also been reported in one cat with hepatic lipidosis,⁵ and one with cholangiocarcinoma.⁶

Feline infectious peritonitis (FIP) is a common disease in cats, but can be difficult to diagnose antemortem. This paper describes a cat with FSFS, FIP and hepatic lipidosis, which to the authors' knowledge has not been reported before. Given the rare occurrence of FSFS, and the limited number of diseases with which it has been associated, clinicians should consider FIP as a potential underlying condition in cats with skin fragility.

Case report

A 6-year-old spayed female domestic shorthair cat with a 3-week history of hiding, inappetence, and weight loss was presented, as an emergency case. It had been found as a kitten 6 years previously, and had subsequently been kept strictly indoors, although another outdoor cat lived in the household. Vaccinations for rabies rhabdovirus, feline viral rhinotracheitis herpesvirus, feline calicivirus, and parvovirus were up-to-date, but FIP vaccine had never been administered. The cat was not receiving any medication at the time of admission and the owner reported no polyuria, polydipsia, or polyphagia.

Table 1. Complete blood count in a cat with skin fragility syndrome, infectious peritonitis, and hepatic lipidosis

Complete blood count	Patient's value	Reference range
White blood cells	12.48 K μL^{-1}	4.0–18.7 K μL^{-1}
Neutrophils	12.0 K μL^{-1}	2.0–14.0 K μL^{-1}
Band neutrophils	0.120 K μL^{-1}	0.0 K μL^{-1}
Lymphocytes	0.240 K μL^{-1}	0.80–6.10 K μL^{-1}
Monocytes	0.120 K μL^{-1}	0.0–0.70 K μL^{-1}
Hematocrit	14.4%	31.7–48.0%
Reticulocyte count	0 μL^{-1}	

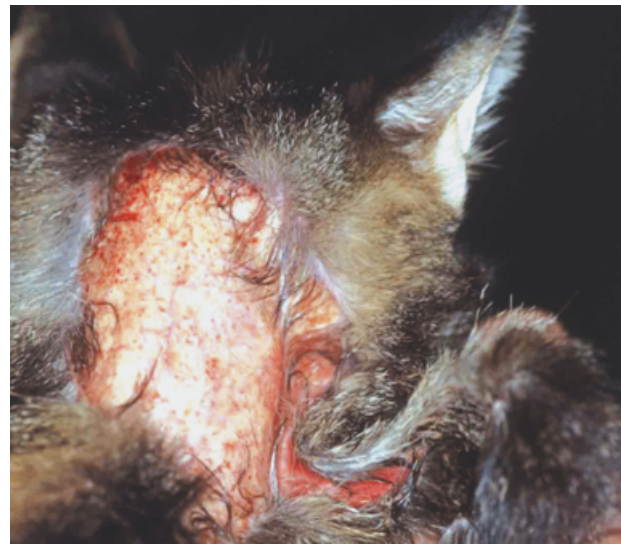Table 2. Chemistry screen in a cat with skin fragility syndrome, infectious peritonitis, and hepatic lipidosis

Chemistry screen	Patient's value	Reference range
Blood urea nitrogen	7 mg dL^{-1}	15–32 mg dL^{-1}
Creatinine	0.4 mg dL^{-1}	1.0–2.0 mg dL^{-1}
Phosphorus	4.0 mg dL^{-1}	3.0–6.6 mg dL^{-1}
Sodium	139 mmol L^{-1}	146–157 mmol L^{-1}
Potassium	4.6 mmol L^{-1}	3.5–4.8 mmol L^{-1}
Chloride	110 mmol L^{-1}	116–126 mmol L^{-1}
Total protein	7.0 g dL^{-1}	6.0–8.6 g dL^{-1}
Albumin	2.0 g dL^{-1}	2.4–3.8 g dL^{-1}
Globulin	5.0 g dL^{-1}	
Alanine aminotransferase	30 U L^{-1}	33–152 U L^{-1}
Aspartate aminotransferase	232 U L^{-1}	1–37 U L^{-1}
Alkaline phosphatase	137 U L^{-1}	22–87 U L^{-1}
GGT	8 U L^{-1}	5–19 U L^{-1}
Cholesterol	193 mg dL^{-1}	96–248 mg dL^{-1}
Total bilirubin	0.9 mg dL^{-1}	0.1–0.8 mg dL^{-1}

At initial physical examination (day 1), the rectal temperature was 38.8 °C, pulse rate 200 bpm, and respiratory rate 48 bpm. The cat was depressed, cachectic, and was subjectively assessed as 5–7% dehydrated based on the degree of skin tenting and hydration status of mucous membranes. Mucous membranes were pale and pulses were weak but synchronous with the heart. The abdomen was distended with a palpable fluid wave. A lesion (3 cm in diameter), consistent with a skin tear, and undetected by the owner, was noted on the caudodorsal surface of the left flank.

Initial testing in the emergency service showed a packed cell volume of 18%, total solids of 7.3 g dL^{-1} , dextrose of 102 mg dL^{-1} , and blood urea nitrogen (BUN) of 7 mg dL^{-1} . Systolic blood pressure was 90 mmHg (indirect Doppler technique). Blood was drawn for complete blood and reticulocyte counts, and a chemistry screen (Tables 1 and 2). A cystocentesis was not attempted because ascites interfered with bladder palpation. Approximately 170 mL of yellow, viscous fluid was removed from the abdomen by abdominocentesis and submitted for fluid analysis and cytology. The cat was placed on i.v. Normosol-R at a rate of 2 mL $\text{kg}^{-1} \text{h}^{-1}$ and i.v. cefazolin (22 mg kg^{-1} every 8 h) for suspected skin infection.

Analysis of the abdominal fluid revealed a pale yellow liquid with a specific gravity of 1.033, and a total protein content of 5.3 g dL^{-1} . The nucleated cell count was 316 cells μL^{-1} . Cytology of the abdominal fluid revealed 86% nondegenerate neutrophils, 13% macrophages, and 1% small lymphocytes. The fluid was characterized as a modified transudate with an acute inflammatory component.

**Figure 1.** Feline acquired skin fragility. Dorsal neck just caudal to the ears. A flap of skin has torn and exposed underlying subcutis and muscle.

The markedly elevated total protein with low nucleated cell count was consistent with FIP.⁷ Aerobic bacterial culture of the abdominal fluid yielded no growth but a polymerase chain reaction (PCR) directed at the 7B gene sequence of the FIP virus was positive (Engene, Antech Diagnostics, Farmingdale, NY, USA; results were received on day 5).

A blood type was determined (type A) and the cat was transfused with 30 mL of type A packed red blood cells. An additional palliative abdominal fluid tap was performed, and 600 mL of fluid was removed. The cat responded by eating a small amount of food. The following morning (day 3), the cat was restrained by being gently held over her neck for a physical examination, during which she turned her head and a piece of skin on the dorsal neck (approximately 15 × 7 cm) tore as a flap, with little to no bleeding, leaving the underlying neck muscles exposed (Fig. 1). At this point, the owners requested that the cat be euthanized.

At postmortem examination, the cat was in thin body condition. The dorsal cervical skin had a 15 cm by 7 cm defect. Moderate subcutaneous oedema was present at the ventral abdomen. The peritoneal cavity contained 400 mL of translucent yellow viscous fluid, with strands of fibrin diffusely adhered to the parietal and visceral peritoneum. Raised yellow nodules (1–2 mm diameter) were distributed throughout the serosa of the gastrointestinal tract, the spleen, mesentery, pancreas, and both capsules of the kidneys. The liver was enlarged (4.4% of body weight), had rounded edges, and was diffusely yellow-pink. The adrenal glands, pituitary gland, and remainder of the organs were normal.

Histopathological findings included multifocal chronic pyogranulomatous peritonitis and enterotyphlitis. The inflammatory infiltrates were composed of mainly macrophages and neutrophils with smaller numbers of lymphocytes and plasma cells, which variably surrounded foci of necrosis, with fibrinous exudate and mild fibroplasia. The inflammation was often perivascular and sometimes associated with vascular necrosis. The lesions in the small intestine were predominantly on the serosa with extension to the muscularis and mucosa. The inflammation in

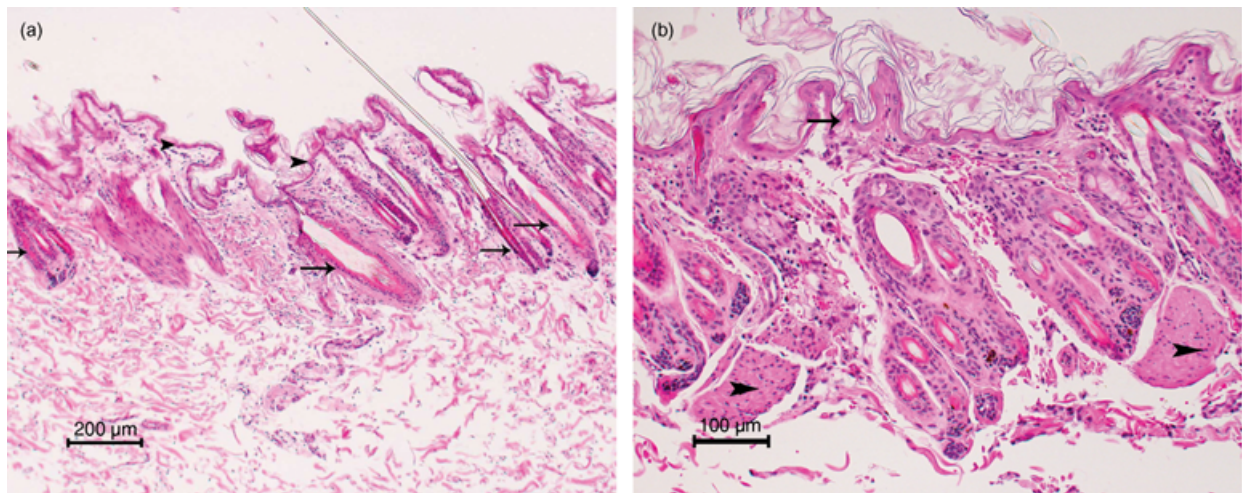


Figure 2. Photomicrograph. (a) Feline acquired skin fragility. Skin from the dorsal thorax. Note the severe dermal atrophy and thin epidermis with telogen phase hair follicles (arrows). The arrowheads are pointing at the epidermis. Haematoxylin and eosin (H&E) 4x. (b) Higher magnification of Figure 2a. The severity of the dermal atrophy becomes more apparent when compared to the normal arrector pili muscles (arrowheads). The epidermis is also thin (arrow). H&E 10x.

the caecum was more severe and differed by having larger epithelioid macrophages with abundant cytoplasm. Large inflammatory aggregates effaced much of the caecal mucosa and submucosa forming large inflammatory nodules. Gram's and Gomori methamine silver stains of the small intestine and caecum were negative for bacteria (including acid fast) and fungi. Multifocal, pyogranulomatous infiltrates extended into the liver parenchyma from the capsular surface. The liver also had mid-zonal to centrilobular fatty change. There was marked interlobular and intralobular fibrosis of the pancreas with lymphoplasmacytic inflammation. The pituitary gland, adrenal glands, and remainder of the organs did not exhibit any histological alterations.

The dermis of the dorsal neck and thorax was profoundly atrophied (Fig. 2a,b) as compared to that of an age-matched control cat (Fig. 3). It measured one-third the thickness of the skin of the ventral abdomen, and was less than one-fourth of the dorsal thoracic skin from an age-matched cat used as a control. Dermal collagen fibres were markedly thinned. Most hair follicles were in the telogen phase. The epidermis was also atrophied (one nucleated layer) with mild orthokeratotic hyperkeratosis. These findings were consistent with skin fragility syndrome.

Indirect immunohistochemistry, using an immunoperoxidase technique, was performed on formalin-fixed paraffin-embedded tissues (intestine, stomach, omentum, mesenteric lymph node) using a monoclonal murine antibody to detect FIP feline coronavirus nucleocapsid protein (courtesy of Dr Edward J. Dubovi, NY State Diagnostic Laboratory, Cornell University).⁸ Abundant coronavirus antigen was detected within the cytoplasm of macrophages in the submucosa, muscularis of the intestines as well as the gastric serosa, mesenteric lymph node and the omentum. No coronavirus antigen was detected within the dorsal cervical skin.

Discussion

FSFS is an acquired disease that has been reported in association with several concurrent diseases, most com-

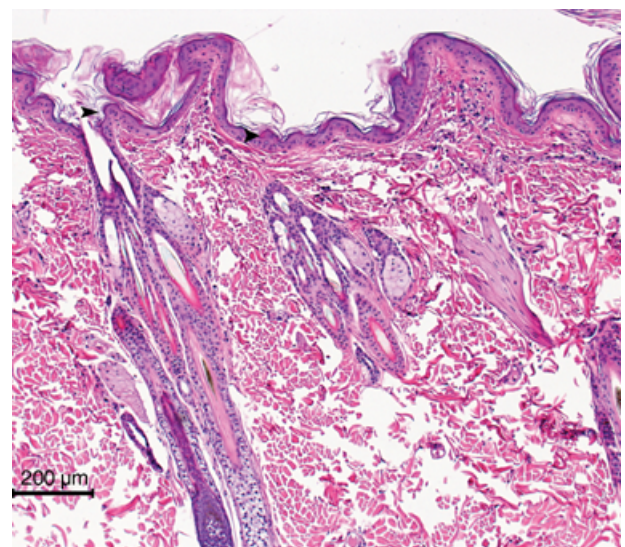


Figure 3. Photomicrograph. Age-matched control cat. Dorsal neck skin. Note the normal dermal collagen fibres and the thickness of the dermis. Arrowheads are pointing at the epidermis. Haematoxylin and eosin 4x. The control cat used for obtaining normal feline skin was provided by NIH grant RR02512.

monly spontaneous or iatrogenic hyperadrenocorticism,^{3,4} diabetes mellitus,² or excessive use of progestational compounds.² The pathogenesis of cutaneous changes in these disorders remains unknown; however, it may be related to the effect of glucocorticoids on collagen production.⁹ Other disease processes that have been associated with FSFS include hepatic lipidosis⁵ and cholangiocarcinoma.⁶ The pathogenesis in these cats remains unclear, but a severe catabolic state and starvation have been suggested as possible causes.⁶

In the present case, skin fragility was noted at the time of presentation but the investigation to determine the underlying reason failed to detect the conditions previously reported in association with this syndrome. Hyperadrenocorticism was excluded based on lack of

characteristic clinical signs (such as polyuria, polydipsia, and polyphagia), lack of a diabetic state that characterizes most cats with hyperadrenocorticism, and normal adrenal and pituitary glands on postmortem examination. Diabetes mellitus was excluded based on normal blood glucose concentration. Neoplastic processes, in particular that of cholangiocarcinoma, were excluded based on histopathology. Use of drugs was excluded based on the history.

Hepatic lipidosis has been reported in association with FSFS.⁵ While there were fatty changes present in the liver of this cat, this is a common finding in cats with other primary systemic disease.¹⁰ Elevations in alkaline phosphatase, aspartate aminotransferase, and total bilirubin are suggestive of liver disease and can be seen with hepatic lipidosis, hepatic FIP, or other liver diseases. Based on histopathology, the fatty changes in the liver were moderate. Multifocal pyogranulomatous infiltrates in the liver, consistent with FIP, were also present. Therefore, hepatic lipidosis and FIP likely both contributed to liver disease in this cat. However, FIP was likely the main disease process that resulted in development of characteristic abdominal effusion and cachexia. Hepatic lipidosis most likely developed secondarily to FIP. However, both hepatic lipidosis and FIP may have contributed to the skin changes observed.

Other biochemical evidence of liver dysfunction included hypoalbuminaemia and low BUN. Hypoalbuminaemia may have developed as a result of decreased albumin production due to hepatic dysfunction or leakage of albumin into the abdominal cavity. Decreased BUN may have also been due to hepatic dysfunction. These changes are not unique to any specific liver disease.

Cutaneous asthenia is a congenital form of FSFS that has also been reported in young cats.¹¹ It is usually associated with a congenital connective tissue disorder, and a chronic history of recurrent skin lacerations. Histologically, some cases of cutaneous asthenia are difficult to distinguish from acquired skin fragility with differentiation based on signalment and history and the skin extensibility index. Masson's trichrome staining can be undertaken, but staining abnormalities can occur in dermatological diseases with abnormal collagen metabolism.¹² The markedly atrophied skin in the present case is not typical of cutaneous asthenia. The cat in this case report was 6 years old, and, until presentation, had no history of skin lacerations, making cutaneous asthenia unlikely. Additionally, the skin was not hyperextensible.

FIP has been previously reported in association with dermatological abnormalities including ulcerative lesions, superficial vasculitis,¹ and nodular lesions.¹³ Vasculitis induced by *Coronavirus* was reported in a cat with concurrent FIP and feline immunodeficiency virus infection.¹⁴ However, to the authors' knowledge, this is the first report of FSFS associated with FIP in a cat. Skin lesions associated with FIP have previously appeared to be directly linked with FIP, as FCoV antigen was identified within skin lesion macrophages.^{13,14} In the present case, it is possible that changes in the skin were not due to a direct effect of FCoV on the skin, but rather to the severe catabolic state associated with it. Loss of protein into the abdominal cavity, along with decreased protein production due to hepatic dysfunction, may lead to tissue starvation or loss of the dietary protein needed to maintain skin homeostasis.

In summary, although FIP is a common disease in cats,¹⁵ it can be difficult to diagnose antemortem.¹⁶ Recognition of all possible associated clinical signs will facilitate a diagnosis. Although a cause and effect relationship cannot be stated with certainty in this case, clinicians should be aware that in cats presenting with skin tears FIP should be taken into consideration as a possible underlying cause.

References

1. Scott DW, Miller WH, Griffin CE. Miscellaneous skin diseases: feline acquired skin fragility. In: Muller and Kirk's Small Animal Dermatology, 6th edn. Philadelphia, PA: W.B. Saunders, 2001: 1170–3.
2. Gross TL, Ihrke PJ, Walder EJ. Veterinary Dermatopathology: a Macroscopic and Microscopic Evaluation of Canine and Feline Skin Disease. St. Louis: Mosby-Year Book, 1992: 234–6.
3. Helton-Rhodes K, Wallace M, Baer K. Cutaneous manifestations of feline hyperadrenocorticism. In: Ihrke, PJ et al. ed. Advances in Veterinary Dermatology, Vol. 2. New York: Pergamon Press, 1993: 391–6.
4. Canfield PJ, Hinchliffe JM, Yager JA. Probable steroid-induced skin fragility in a cat. Australian Veterinary Practitioner 1992; 22: 164–70.
5. Zur G. Feline skin fragility syndrome in a cat with hepatic lipidosis. In: Kwochka KW, Willemse T, von Tscharner C, eds Advances in Veterinary Dermatology Vol. 3. Butterworth-Oxford: Heinemann Ltd, 1998: 495–6.
6. Regnier A, Pieraggi MT. Abnormal skin fragility in a cat with cholangiocarcinoma. Journal of Small Animal Practice 1989; 30: 419–23.
7. Norris JM, Bosword KL, White JD et al. Clinicopathological findings associated with feline infectious peritonitis in Sydney, Australia: 42 cases (1990–2002). Australian Veterinary Journal 2005; 83: 666–73.
8. Harvey CJ, Lopez JW, Hendrick MJ. An uncommon intestinal manifestation of feline infectious peritonitis: 26 cases (1986–93). Journal of the American Veterinary Association 1996; 209: 1117–20.
9. Uitto J, Pulkkinen L, Chu ML. Collagen. In: Freedberg, IM, Eisen, AZ, Wolff, K et al. eds. Fitzpatrick's Dermatology in General Medicine, 6th edn. New York: McGraw-Hill, 2003; 165–79.
10. Scherk MA, Center SA. Toxic, metabolic, infectious, and neoplastic liver diseases. In: Ettinger SJ, Feldman EC. Textbook of Veterinary International Medicine, 6th edn. St. Louis, MO: Elsevier Saunders, 2005: 1464–78.
11. Scott DW. Cutaneous asthenia in a cat, resembling Ehlers Danlos syndrome in man. Veterinary Medicine/ Small Animal Clinician 1974; 69: 1265.
12. Fernandez CJ, Scott DW, Erb HN et al. Staining abnormalities of dermal collagen in cats with cutaneous asthenia or acquired skin fragility as demonstrated with Masson's trichrome stain. Veterinary Dermatology 1998; 9: 49–54.
13. Gross TL. Pyogranulomatous vasculitis and mural folliculitis associated with feline infectious peritonitis in a Sphinx cat. Veterinary Pathology 1999; 36: 507.
14. Cannon MJ, Silkstone MA, Kipar AM. Cutaneous lesions associated with coronavirus-induced vasculitis in a cat with feline infectious peritonitis and concurrent feline immunodeficiency virus infection. Journal of Feline Medicine and Surgery 2005; 7: 233–6.
15. Rohrbach BW, Legendre AM, Baldwin CA et al. Epidemiology of feline infectious peritonitis among cats examined at veterinary medical teaching hospitals. Journal of the American Veterinary Medical Association 2001; 218: 1111–5.
16. Hartmann K, Binder C, Hirschberger J et al. Comparison of different tests to diagnose feline infectious peritonitis. Journal of Veterinary International Medicine 2003; 17: 781–90.

Résumé Une femelle européenne âgée de 6 ans, stérilisée, à poils courts, a été présentée pour une perte d'appétit, une perte de poids évoluant depuis 3 semaines. Durant l'examen initial, une déshydratation, un épanchement abdominal et une cicatrice sur le flanc gauche ont été notés. Après tranquillisation, la peau du cou s'est déchirée laissant un volet de peau de 15 cm x 7 cm. Les anomalies clinicopathologiques incluaient une anémie non régénérative, une hypoalbuminémie, une augmentation des globulines et des aminotransférases et des phosphatases alcalines. L'épanchement abdominal était visqueux et avait un taux de protéines de 5.3 g/dl avec 316 cellules/ μ l, en faveur d'un transudat modifié. La cytologie du liquide d'épanchement a montré 86% de neutrophiles non dégénérés, 13% de macrophages, et 1% de petits lymphocytes. L'examen histopathologique et l'immunohistochimie indirecte ont confirmé le diagnostic de péritonite infectieuse féline, de lipidose hépatique et de syndrome de fragilité cutanée. Le syndrome de fragilité cutanée n'a pas été rapportée en association avec la péritonite infectieuse féline. Son inclusion comme signe clinique associé à la PIF peut faciliter le diagnostic.

Resumen Se examinó una gata castrada de seis años de edad con una historia clínica de tres semanas con inapetencia, pérdida de peso y tendencia a ocultarse. Durante el examen físico la palpación identificó la presencia de fluido en el abdomen, deshidratación, y una pequeña rasgadura de la piel en el flanco izquierdo. Cuando el gato fue manipulado cuidadosamente para obtener una muestra de sangre, la piel dorsal del cuello se rasgó, dejando un lengüeta de piel de 15 x 7 cm. Las anomalías clinicopatológicas incluyeron anemia no-regenerativa, hipoalbuminemia, hiperglobulinemia, y elevación ligera de la actividad de las enzimas aspartato aminotransferasa y fosfatasa alcalina. El fluido abdominal era viscoso, con un contenido total de proteína de 5,3 g/dl y 316 células/ μ l, consistente con un trasudado modificado. La citología del fluido abdominal demostró la presencia de un 86% de neutrófilos no degenerativos, 13% de macrófagos, y 1% de linfocitos pequeños. Tras el examen histopatológico y mediante inmunohistoquímica indirecta se confirmó el diagnóstico de Peritonitis Infecciosa Felina, lipidosis hepática y síndrome de fragilidad de la piel. Este último síndrome no ha sido diagnosticado previamente en asociación con peritonitis infecciosa felina. Su inclusión como un signo clínico asociado con la Peritonitis Infecciosa Felina podría facilitar su diagnóstico.

Zusammenfassung Es wurde eine 6 Jahre alte kastrierte weibliche kurzhaarige Hauskatze mit einer 3-wöchigen Vorgeschichte von Inappetenz, Gewichtsverlust und sich Verstecken untersucht. Bei der Erstuntersuchung wurde eine palpierbare abdominale Flüssigkeitswelle, Dehydrierung und ein kleiner Riss an der linken Flanke festgestellt. Als die Katze während einer Blutabnahme sanft festgehalten wurde, riss die Haut des dorsalen Halses, was einen 15 cm x 7 cm großen Hautlappen hinterließ. Klinisch-pathologische Abweichungen bestanden aus einer nicht-regenerativen Anämie, Hypoalbuminämie, erhöhter Globulinkonzentration und geringfügig erhöhter Aktivität der Aspartat-Aminotransferase und der alkalischen Phosphatase. Die Abdominalflüssigkeit war viskös und wies einen Totalproteingehalt von 5,3 g/dl mit 316 Zellen/ μ l auf, was einem modifizierten Transudat entsprach. Die zytologische Untersuchung der Abdominalflüssigkeit zeigte 86% nichtdegenerative neutrophile Granulozyten, 13% Makrophagen, und 1% kleine Lymphozyten. Die histopathologische Evaluierung und indirekte Immunhistochemie bestätigte die Diagnose von feliner infektiöser Peritonitis, hepatischer Lipidose und felinem Hautfragilitätssyndrom. Das feline Hautfragilitätssyndrom wurde bisher noch nicht im Zusammenhang mit feliner infektiöser Peritonitis (FIP) beschrieben. Die Einbeziehung des felinen Hautfragilitätssyndroms als klinisches Symptom im Zusammenhang mit FIP könnte eine Diagnose erleichtern.