

Hydrophilic Acrylic Intraocular Lens Opacification after Descemet Stripping Automated Endothelial Keratoplasty

Amir Norouzpour, MD; Siamak Zarei-Ghanavati, MD, FICO

Eye Research Center, Khatam-Al-Anbia Eye Hospital, Mashhad University of Medical Sciences, Mashhad, Iran

Abstract

Purpose: To report hydrophilic acrylic intraocular lens (IOL) opacification after Descemet Stripping Automated Endothelial Keratoplasty (DSAEK) in an eye with multiple prior intraocular surgeries and iatrogenic aniridia.

Case Report: A 34-year-old woman with history of penetrating keratoplasty (PKP) for advanced keratoconus and subsequent Urrets-Zavalía Syndrome (UZS) underwent phacoemulsification and hydrophilic acrylic IOL implantation for her cataract. In order to control post-PKP glaucoma, multiple glaucoma surgeries including two glaucoma drainage implants were performed. As the original corneal graft failed, the patient subsequently underwent re-PKP. Four years later, she underwent DSAEK for treatment of the second graft failure. Ten months after DSAEK, a double semi-circular pattern of IOL opacification was observed on the anterior surface of the IOL. The patient did not report any complaints and we decided not to exchange the IOL.

Conclusion: In an eye with UZS and iatrogenic aniridia, IOL opacification may result from direct contact between the IOL surface and exogenous air. Aniridia can be a risk factor for development of IOL opacification after DSAEK. Further studies are required to confirm this hypothesis.

Keywords: Descemet Stripping Automated Endothelial Keratoplasty; Hydrophilic Intraocular lens; Intracameral Air; Opacification

J Ophthalmic Vis Res 2016; 11 (2): 225-227.

INTRODUCTION

Descemet stripping endothelial keratoplasty/Descemet stripping automated endothelial keratoplasty (DSEK/DSAEK) is currently considered as the procedure of choice in eyes with corneal endothelial dysfunction.^[1]

Correspondence to:

Siamak Zarei-Ghanavati, MD, FICO. Eye Research Center, Khatam-Al-Anbia Eye Hospital, Mashhad University of Medical Sciences, Abooteleb Blvd, Mashhad 91959, Iran. E-mail: zareis@mums.ac.ir

Received: 14-08-2014

Accepted: 27-12-2014

Although these procedures offer certain advantages over conventional penetrating keratoplasty (PKP),^[2-4] experience with these procedures is not as extensive and few reports regarding their complications have been published.^[3]

Patients undergoing DSEK/DSAEK are frequently pseudophakic because the crystalline lens has usually been removed before or during DSEK/DSAEK.^[5] Therefore, few cases with intraocular lens (IOL) complications after DSEK/DSAEK have been reported.^[6-9]

In this report, we describe a patient with IOL opacification 10 months after DSAEK, with a history of

This is an open access article distributed under the terms of the Creative Commons Attribution-NonCommercial-ShareAlike 3.0 License, which allows others to remix, tweak, and build upon the work non-commercially, as long as the author is credited and the new creations are licensed under the identical terms.

For reprints contact: reprints@medknow.com

How to cite this article: Norouzpour A, Zarei-Ghanavati S. Hydrophilic acrylic intraocular lens opacification after descemet stripping automated endothelial keratoplasty. *J Ophthalmic Vis Res* 2016;11:225-7.

Access this article online

Quick Response Code:



Website:

www.jovr.org

DOI:

10.4103/2008-322X.158897

multiple intraocular surgeries and iatrogenic aniridia as a result of Urrets-Zavalía Syndrome (UZS).

CASE REPORT

A healthy 34-year-old woman with a history of bilateral keratoconus underwent PKP in her left eye because of advanced ectasia in 1999 followed by UZS after surgery. The patient was treated with topical β -blocker and carbonic anhydrase inhibitor drops. Seven years later in 2006, trabeculectomy was performed in the left eye to control post-PKP glaucoma. In 2007, she underwent uneventful phacoemulsification with foldable hydrophilic acrylic IOL implantation (Akreos Adapt Advanced Optics [AO], Bausch and Lomb Inc., Berlin, Germany). Intraocular pressure (IOP) of the same eye became uncontrolled again, requiring Ahmed Glaucoma Valve (AGV) implantation twice within a 9-month interval after cataract surgery.

The original corneal graft was failed in 2009, requiring re-PKP, which also failed in 2013. Subsequently, she was subjected to an uncomplicated DSAEK in the left eye. In order to completely appose the lenticule to the recipient's stroma and control postoperative hypotony secondary to the AGV (considering no risk of pupillary block in an eye with aniridia), the anterior chamber was filled with air at the end of DSAEK. The patient was treated with topical betamethasone eye drops 4 times per day for 3 months which was tapered off monthly and maintained at a dose of once daily. No sign of postoperative anterior chamber inflammation was noted. Best corrected distance visual acuity (BCDVA) of the left eye was 20/600 (1.47 LogMAR) before DSAEK, which improved to 20/100 (0.699 LogMAR) and 20/50 (0.398 LogMAR) at months 2 and 4 after DSAEK, respectively.

Ten months following DSAEK, the corneal graft was clear. No sign of anterior chamber inflammation was noted, and IOP was controlled. BCDVA remained at 20/50 (0.398 LogMAR) and the patient was asymptomatic. However, slit lamp examination revealed a double semi-circular pattern of white opacification on the anterior surface of the IOL. The semi-circles consisted of white granular opacities on the lens surface. The semi-circles were attached superiorly and there was a tapering tail inferiorly [Figure 1].

DISCUSSION

Distinctive patterns of calcification on various hydrophilic acrylic IOLs following procedures using intracameral injections of air or gas have been reported.^[6-10] Calcification is localized to the anterior surface/subsurface of the IOL, within the pupillary area, and occurs in a circular pattern.^[9,10] It remains unclear whether the localized IOL calcification results from direct contact between the IOL surface and exogenous gas (i.e., gas/air), a metabolic

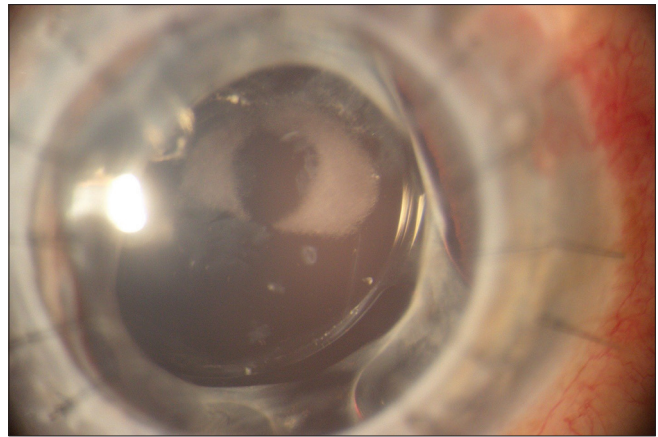


Figure 1. A double semi-circular pattern of IOL opacification is seen superiorly, on the anterior surface of the intraocular lens adjacent to the Ahmed glaucoma valve tube.

change in the anterior chamber due to the presence of exogenous gas, or an exacerbated inflammatory reaction after multiple surgical procedures.

In this report, we describe a case with IOL opacification 10 months after DSAEK in an eye with history of multiple intraocular surgeries including PKP and AGV implantation. Our patient had a similar pattern of opacification as similar cases reported in the literature; the IOL opacification was limited to the anterior surface of the IOL. Furthermore, our patient experienced a similar history of intracameral air injection. IOL opacification, in our case, was observed after the last surgical procedure, namely DSAEK, and not after other surgeries such as PKP or glaucoma surgery. One factor which differentiates DSAEK from PKP is leaving an air bubble in the anterior chamber after the former procedure and this intracameral air may have played a key role in the development of IOL opacification. Moreover, UZS developed in our patient and the subsequently iatrogenic aniridia provided a large contact area between the IOL and the air bubble in the anterior chamber.

IOL opacification had a distinctive, double semi-circular pattern superiorly. The opacification was adjacent to the tip of the AGV tube. As air stays superiorly and exits the anterior chamber through the AGV tube, the superior part of the IOL adjacent to the tip of the AGV tube can get into direct contact with the air bubble for a long time. Interestingly, the white semi-circles were incomplete inferiorly which might have resulted from an air-fluid interface at the lower border of the air bubble. These observations support the hypothesis that IOL opacification may occur due to direct contact between the IOL surface and exogenous air.

The presence of intraocular air in the anterior chamber can lead to dehydration of the anterior surface of hydrophilic IOL. This structural change may induce proteins and/or other soluble materials in the aqueous to precipitate onto the anterior substance of the IOL

and then act as a nidus for dystrophic calcification. In case of multiple ocular surgeries, the blood-ocular barrier breakdown could promote the opacification by increasing calcium and protein levels in the aqueous humor. However, further experimental studies are warranted to clarify the mechanism of IOL calcification and confirm the possible role of intraocular air and blood-ocular barrier breakdown.

In summary, IOL opacification after DSAEK in an eye with multiple prior ocular surgeries and aniridia due to UZS may occur due to direct contact between the IOL surface and exogenous air. Regardless of the mechanism(s) underlying IOL opacification after intracameral air injection, it may be wise to avoid the use of hydrophilic acrylic IOLs when procedures with intracameral injection of air/gas are anticipated, particularly in aniridic eyes.

Financial Support and Sponsorship

Nil.

Conflicts of Interest

There are no conflicts of interest.

REFERENCES

1. Price MO, Price FW. Descemet's stripping endothelial keratoplasty. *Curr Opin Ophthalmol* 2007;18:290-294.
2. Bahar I, Kaiserman I, Levinger E, Sansanayudh W, Slomovic AR, Rootman DS. Retrospective contralateral study comparing Descemet stripping automated endothelial keratoplasty with penetrating keratoplasty. *Cornea* 2009;28:485-488.
3. Lee WB, Jacobs DS, Musch DC, Kaufman SC, Reinhart WJ, Shtein RM. Descemet's stripping endothelial keratoplasty: Safety and outcomes: A report by the American Academy of Ophthalmology. *Ophthalmology* 2009;116:1818-1830.
4. Price MO, Gorovoy M, Benetz BA, Price FW Jr., Menegay HJ, Debanne SM, et al. Descemet's stripping automated endothelial keratoplasty outcomes compared with penetrating keratoplasty from the cornea donor study. *Ophthalmology* 2010;117:438-444.
5. Terry MA, Shamie N, Chen ES, Phillips PM, Shah AK, Hoar KL, et al. Endothelial keratoplasty for Fuchs' dystrophy with cataract: Complications and clinical results with the new triple procedure. *Ophthalmology* 2009;116:631-639.
6. Fellman MA, Werner L, Liu ET, Stallings S, Floyd AM, van der Meulen IJ, et al. Calcification of a hydrophilic acrylic intraocular lens after Descemet-stripping endothelial keratoplasty: Case report and laboratory analyses. *J Cataract Refract Surg* 2013;39:799-803.
7. Werner L, Wilbanks G, Ollerton A, Michelson J. Localized calcification of hydrophilic acrylic intraocular lenses in association with intracameral injection of gas. *J Cataract Refract Surg* 2012;38:720-721.
8. Saeed MU, Singh AJ, Morrell AJ. Sequential Descemet's membrane detachments and intraocular lens haze secondary to SF6 or C3F8. *Eur J Ophthalmol* 2006;16:758-760.
9. Patryn E, van der Meulen IJ, Lapid-Gortzak R, Mourits M, Nieuwendaal CP. Intraocular lens opacifications in Descemet stripping endothelial keratoplasty patients. *Cornea* 2012;31:1189-1192.
10. Dhital A, Spalton DJ, Goyal S, Werner L. Calcification in hydrophilic intraocular lenses associated with injection of intraocular gas. *Am J Ophthalmol* 2012;153:1154-1160.e1.