



Case report

Reconstruction of tracheocutaneous fistula with a rhomboid flap

Kazuya Kashiyama^{a,b,*}, Takahara Eisaku^b, Oshiro Yurie^{a,b}^a Department of Plastic and Reconstructive Surgery, Nagasaki University Hospital, Nagasaki, Japan^b Department of Plastic Surgery, Maxillofacial Surgery, Aesthetic Surgery, Yuaikai Tomishiro Central Hospital, Okinawa, Japan

ARTICLE INFO

Keywords:

Tracheal stoma
Rhomboid flap
Limburg flap

ABSTRACT

Various complications associated with tracheal stomas have been reported, including mechanical trauma to the peristomal skin, infection, folliculitis, granuloma, and fistula. Among them, a tracheocutaneous fistula generally requires surgical repair. A number of methods have been reported for reconstruction of fistulas using musculocutaneous flaps or free flaps. However, those surgical techniques are all designed for complete close of the tracheocutaneous fistula and stoma, while partial closure of the stoma around the indwelling tracheal tube is not well described in the literature. We report on the use of a rhomboid flap for partial closure of a tracheal stoma. The rhomboid flap is a local flap that is frequently used by plastic surgeons because of its broad applications and not being very invasive. This is a low invasive and simple technique for partial closure of an excessively enlarged stoma.

1. Introduction

A number of complications associated with tracheal stomas have been reported, such as mechanical trauma to the peristomal skin, infection, folliculitis, granuloma, and fistula. Among them, tracheocutaneous fistula needs surgical treatment [1], and various methods have been reported for fistula reconstruction using musculocutaneous flaps and free flaps [2,3]. However, those techniques are intended for complete close of the tracheocutaneous fistula and stoma. In contrast, partial closure of a stoma with the tracheal tube in situ is not well described. Here we report a patient who underwent partial closure and local flap reconstruction together with a review of the literature.

1.1. Case presentation

A 37-year-old woman with chronic type 2 respiratory failure had used noninvasive positive pressure ventilation at night for several years and also suffered from recurrent pneumothorax. She developed severe respiratory failure and recurrent right pneumothorax was diagnosed. Video-assisted thoracoscopic surgery was performed under general anesthesia. However, tracheostomy was needed because of post-operative complications. Subsequently, she developed multiple problems, including high fever, pneumonia and pyothorax, and could not be weaned from mechanical ventilation. Long-term pressure from the

tracheal tube caused enlargement of the stoma and exposed the balloon (Fig. 1). Therefore, the respiratory department consulted the plastic surgeons at 6 months after tracheotomy. On examination, the stoma was excessively large and the balloon was exposed with instability of the tube. We decided to perform reconstruction of the tracheal stoma by using a rhomboid flap. Under general anesthesia, the flap was raised and its tip was folded to make a base for supporting the tube (Fig. 2). The operating time was about 20 minutes, and the patient could eat a meal and take a bath on the same day. Removal of sutures was done at seven days after operation. At 1 month after reconstruction of the tracheal stoma, the patient was discharged from hospital on ventilator support (Fig. 3). There has been no recurrence of tracheal stoma enlargement at 1 year after surgery.

2. Discussion

Numerous methods have been reported for closing a tracheal stoma, such as direct closure or use of local flaps, myocutaneous flaps, and free flaps. However, the surgical techniques that have been described in the literature are intended for complete close of the stoma [2,4,5], while our patient only needed partial closure. The patient had several complications, including thin skin, low body weight, malnutrition, and recurrent pneumothorax. In addition, a tracheal stoma was still required for ongoing ventilator support, but the tracheal tube was very unstable and

* Corresponding author. Department of Plastic and Reconstructive Surgery, Nagasaki University Hospital, 1-12-1 Sakamoto, Nagasaki, 852-8501, Japan. Tel: +81 95 819 7327; fax: +81 95 819 7330.

E-mail addresses: tempnauts.2061@gmail.com, kkashiyama@nagasaki-u.ac.jp (K. Kashiyama).

<https://doi.org/10.1016/j.rmcr.2019.100934>

Received 31 August 2019; Received in revised form 14 September 2019; Accepted 15 September 2019

Available online 16 September 2019

2213-0071/© 2019 The Authors.

Published by Elsevier Ltd.

This is an open access article under the CC BY-NC-ND license

(<http://creativecommons.org/licenses/by-nc-nd/4.0/>).

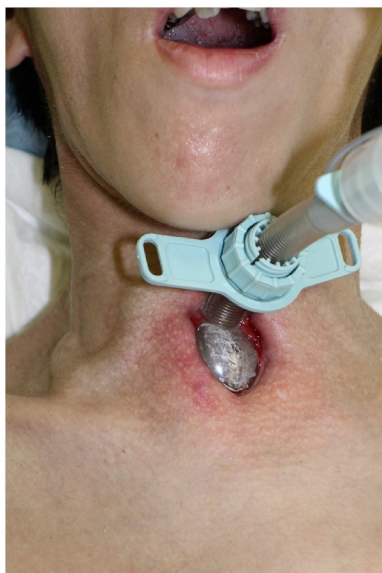

Fig. 1. Preoperative findings.

the balloon was exposed because the stoma had become enlarged. Therefore, we needed a method of stoma reconstruction that showed low invasiveness and was rapid, and that could be done with the tube in situ. Direct closure is the simplest method, but there were disadvantages for this patient. The suture line would be located below the tracheal tube after direct closure, which is the site most affected by pressure from the tube, so suture separation could easily occur. Also, creating a straight scar under the tube and caudal to the stoma could lead to undesirable stoma deformity and pain. Accordingly, we performed reconstruction of the fistula with a Limberg flap.

There are various transposition flaps, including rectangular or parabolic transposition flaps, note flaps, bi-lobar flaps, Z-plasty, and rhomboid flaps. We used a Limberg flap, which is a type of rhomboid flap [6]. The rhomboid flap is a local flap commonly employed by plastic surgeons due to its very low invasiveness and broad utility. In our patient, respiratory management by an anesthesiologist was required because of respiratory complications, but we can usually raise a rhomboid flap under local anesthesia. The classic rhombic flap was reported by Limberg, and there are a number of variations of this flap. The Limberg flap is used for a rhomboid defect with two opposing angles of 60° and two of 120°. As stated previously, it was necessary to cover the balloon by partially closing the stoma and creating a margin of the tracheal stoma that would withstand the pressure of the tube or balloon.

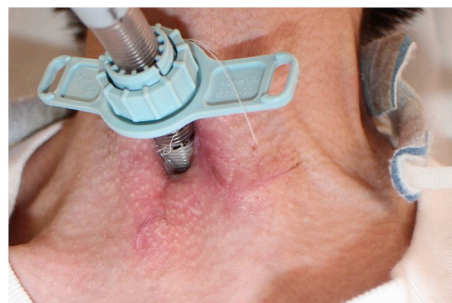


Fig. 3. Postoperative findings. One month after the operation. There is no recurrence.

So we used an irregular flap. After debridement of granulation tissue, the Limburg flap was designed to either side of the defect. Because there was a large cutaneous vein on the right side, we raised the flap on the left side. The flap was raised with the upper layer of platysma. This patient will need complete closure of the stoma when respiratory support is no longer required, and an additional local flap can be raised near the stoma at that time. While the flap is raised as usual, the orifice of the tube can be preserved by using the flap after partially folding it, and a tracheal stoma that resists pressure can be created by placing the skin, rather than subcutaneous tissue, in the area that sustains the pressure of the tube (Fig. 4).

3. Conclusion

We reported a patient who underwent partial closure of a tracheal stoma. The Limburg flap is suitable for reconstruction of a tracheal stoma, and we can raise an additional flap near the stoma when complete closure becomes possible. This technique shows low invasiveness and is easy to employ for partial closure of an excessively enlarged stoma.

4. Consent for publication

The patient and her family were informed and provided consent for clinical information and the accompanying images to be included in this case report.

Conflicts of interest

The authors declare that they have no competing interests.

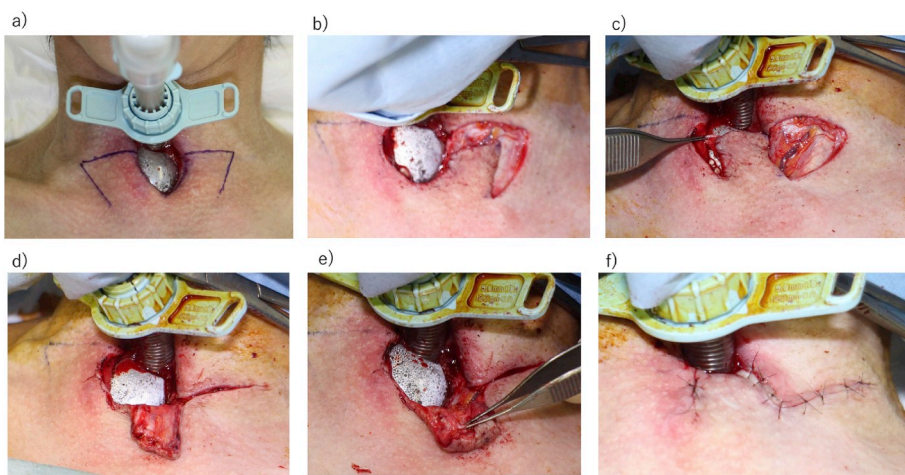


Fig. 2. Surgical procedure. a) Design of the skin flap (The design on the left was used.) b) Skin incision and raising the flap c) Transposition of the flap d) Closing the donor site e) Creating support for the tube by using the flap f) Wound closure.

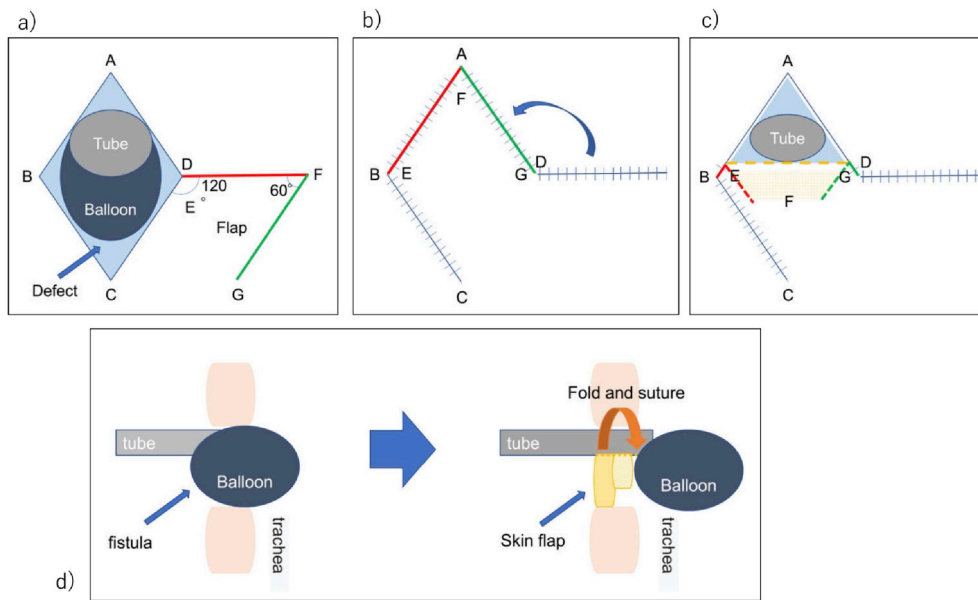


Fig. 4. Schema of skin flap
 a) By regarding the skin defect (ABCD) as a rhomboid, a Limberg flap (EFG) that covers the entire defect is designed. The length of each side of the rhomboidal defect is the same as that of the flap.
 b) Conventional transposition of the flap. The defect is closed as points EFG are transposed.
 c) Transposition of the flap in Japan. Points E and G are the same as in conventional closure of the skin flap. Point F is sutured to the reverse side of the flap by folding the flap along the orange dotted line. The skin of the folded part serves as the foundation that supports the tube.
 d) Sagittal section. The flap is folded inside and sutured. (For interpretation of the references to colour in this figure legend, the reader is referred to the Web version of this article.)

Authors’ contributions

KK conceived and wrote the article. KK, TE, and OY were involved in treating the patient. KK participated in editing the manuscript critically. All authors declare that they contributed to this article and that they have read and approved the final manuscript.

Funding

No grant support of funding from public institutions or private enterprises was received for this case report.

Acknowledgements

None.

References

- [1] A. Marchioni, F. Mattioli, A. Piccinini, D. Marchioni, M. Alicandri-Ciuffelli, M. Monelli, et al., Bronchial selective ventilation in a wide tracheocutaneous fistula, *Respir Med. Case Rep.* 7 (2012) 1–3.
- [2] A.K. Royer, M.C. Royer, J.Y. Ting, E.C. Weisberger, M.G. Moore, The use of a prefabricated radial forearm free flap for closure of a large tracheocutaneous fistula: a case report and review of the literature, *J. Med. Case Rep.* 9 (2015) 251.
- [3] Y. Tatekawa, H. Yamanaka, T. Hasegawa, Closure of a tracheocutaneous fistula by two hinged turnover skin flaps and a muscle flap: a case report, *Int. J. Surg. Case Rep.* 4 (2) (2013) 170–174.
- [4] Q.L. Huang, H.P. Liu, S.Q. Lu, A simple skin flap plasty to repair tracheocutaneous fistula after tracheotomy, *Chin. J. Traumatol.* 18 (1) (2015) 46–47.
- [5] F.P. Caronia, A. Fiorelli, M. Santini, S. Castorina, A persistent tracheocutaneous fistula closed with two hinged skin flaps and rib cartilage interpositional grafting, *Gen. Thorac. Cardiovasc. Surg.* 64 (10) (2016) 625–628.
- [6] Y. Watanabe, T. Umehara, A. Harada, M. Aoki, T. Tokunaga, S. Suzuki, et al., Successful closure of a tracheocutaneous fistula after tracheostomy using two skin flaps: a case report, *Surg. Case Rep.* 1 (1) (2015) 43.