

Basal cell carcinoma is the most common skin cancer in the Caucasian population. The cancer arises in sun exposed areas of the skin. The incidence of morbidity is high and it is still growing. The metastatic rate is low, but the enlarging tumor may cause severe tissue disfigurement and a poor cosmetic outcome. The diagnosis is usually clinical but there are many subtypes of this carcinoma and correct diagnosis is the clue to appropriate treatment of the lesion. The main problem in basal cell carcinoma management is the high recurrence rate.

Key words: basal cell carcinoma, BCC, dermoscopy, USG, histology.

Contemp Oncol (Pozn) 2013; 17 (4): 337–342
DOI: 10.5114/wo.2013.35684

Basal cell carcinoma – diagnosis

**Małgorzata Mackiewicz-Wysocka, Monika Bowszyc-Dmochowska,
Daria Strzelecka-Węklar, Aleksandra Dańczak-Pazdrowska, Zygmunt Adamski**

Chair and Department of Dermatology, Poznan University of Medical Sciences,
Poznan, Poland

Introduction

Basal cell carcinoma (BCC) is a slow growing, locally aggressive tumor that arises from the basal layer of the epidermis. It is the most common cancer in the fair-skinned population [1]. Lifetime risk of developing BCC is approximately 30% and the incidence is continuously increasing worldwide [2].

According to data recorded by the Polish National Cancer Registry (Narodowy Rejestr Nowotworów) 10,000 new cases of non-melanoma skin cancers (NMSC) were registered in Poland in 2010 [3]. The incidence of NMSC in Poland has also been increasing for the last few years.

The most significant etiological factors are: genetic predisposition and a history of exposure to ultraviolet radiation [4], especially in people with a tendency to sunburn [5]. Basal cell carcinoma lesions are usually localized on sun-exposed areas of the body such as the face, ears, and neck [6]. Other important risk factors are age over 40, male sex, immunosuppression and arsenic exposure [7]. Basal cell carcinoma, like squamous cell carcinoma (SCC), can also arise in scars, ulcers, burn sites and lesions of chronic inflammation [8].

Basal cell carcinoma rarely metastasizes but once the BCC is diagnosed, the risk of a new lesion increases by a factor of 10 [9]. The mortality associated with this tumor is low but spreading tumor can cause severe tissue damage and a poor functional and cosmetic outcome. Recurrences represent the main challenge in BCC treatment; therefore determination of the risk of recurrence is very important. The risk factors for BCC recurrence are: large size of a tumor (over 2 cm); particular localization – central facial site (periocular, perioral, nasal); perineural and perivascular invasion; aggressive histology (morphoeic, micronodular); and prior recurrence of BCC [9]. The type of applied treatment method depends on BCC recurrence risk identification. There are several diagnostic methods to make the diagnosis of BCC and to distinguish the aggressive variants of the tumor. Proper diagnosis is the key to selection of the most appropriate treatment.

Clinical diagnosis

Morphological classification of BCC includes: nodular (with micronodular), infiltrative (with morphoeic), superficial and mixed subtype [10]. The nodular subtype occurs most commonly on the head (mainly the nose and forehead), neck and upper back, while the micronodular subtype occurs most commonly around the eyes. The morpheaform localizes mainly on the nose, eye angles, forehead and cheeks. It is very rare on the trunk [11]. The lesions of superficial BCC, usually multifocal, are localized on the trunk. In some cases superficial BCC may appear on the head, within the parietal part of the scalp.

At early stages BCC manifests as a small plaque or a papule covered with telangiectasias. Sometimes there is some crust over a delicate wound that bleeds during shaving and does not heal.

The most common type of BCC is the nodular subtype (Figs. 1–3) and clinically it presents as a well-defined, pearly, translucent nodule. The border is rolled and mimics a chain of pearls. The central depression or ulceration of the lesion might be covered by a crust that causes bleeding when removed. Larger lesions show ulceration.

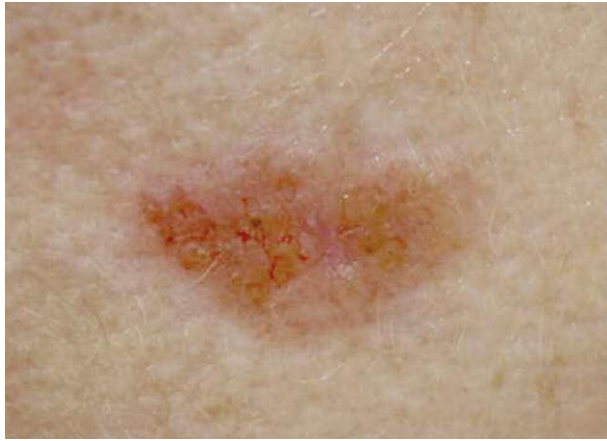

Fig. 1. Nodular BCC

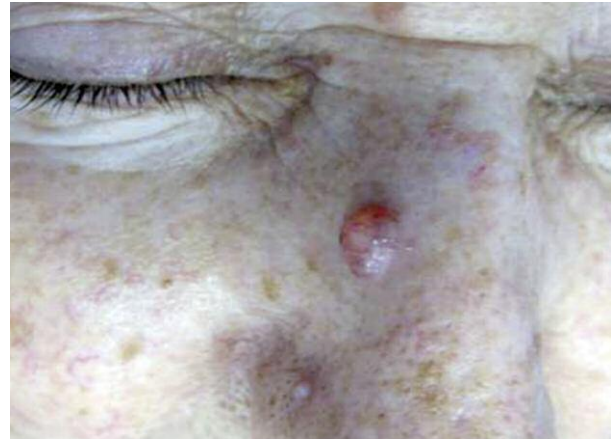

Fig. 2. Nodular BCC

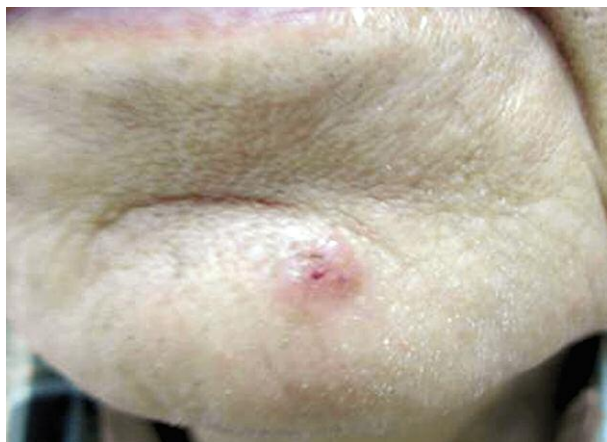

Fig. 3. Nodular BCC

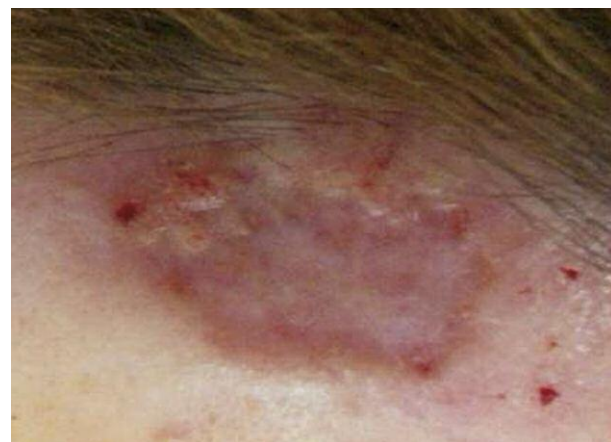

Fig. 4. BCC morphoeic

An aggressive subtype of nodular BCC is the micronodular BCC. It has a typical distribution, is firm to the touch and may have a well-defined border. Micronodular BCC is skin or grayish in color and may appear yellow-white when stretched. It is less prone to ulceration than nodular BCC.

The infiltrative BCCs also show ulceration. In aggressive growth variants such as infiltrative and morphoeic, neoplasms finally cause destruction of surrounding tissues. The border is usually not well defined and often extends beyond clinical margins. Extensively growing tumor used to be called *ulcus rodens*. This aggressive malignancy is usually localized in nasolabial folds, angle of an eye and around the ears. In the area of lower shank BCC lesions mimic post-injury or ischemic ulcers. The border of a carcinomatous ulcer partially shows a *chain of pearls* and the lesion is not painful. This kind of BCC ulcer used to be called *ulcus terebrans*. These lesions damage not only skin or fat tissue but may also infiltrate cartilage and bone tissue. Even though the destruction of surrounding tissue might be extensive, metastases are rare [12].

Morpheaform subtype (Fig. 4) manifests as a depressed scariform skin-colored plaque. In this subtype, ulceration, bleeding and crusting are uncommon. It may be mistaken for scar tissue.

Pigmented BCC is a type of nodular BCC and it is common in dark skin complexion individuals. The color of this carci-

noma ranges from brown to blue black and it may be mistaken for melanoma [13]. Phagocytosis of melanosomes by tumor cells and presence of melanophages in stroma and parenchyma of tumors is the cause of the pigmentation in BCCs [14].

Superficial BCC is an erythematous, well-circumscribed macule with minimal scale. Often there is a central clearing and a threadlike border. Erosion is less common than in nodular type. Papules may mimic eczema or psoriasis but are slowly progressive. Patients usually have no complaints. Tenderness or pain might be present in BCCs localized perineurally or in infiltrating tumors, suggesting an aggressive growth variety of the carcinoma.

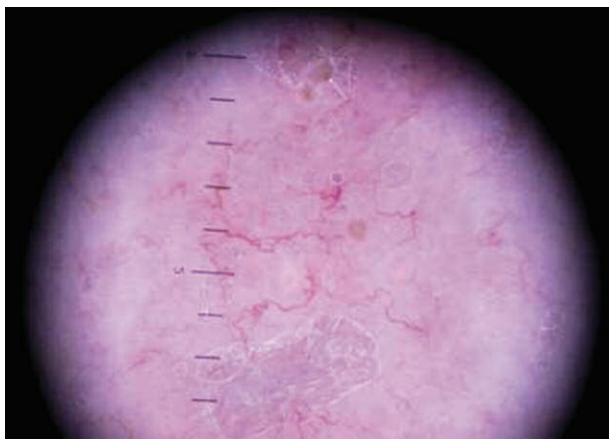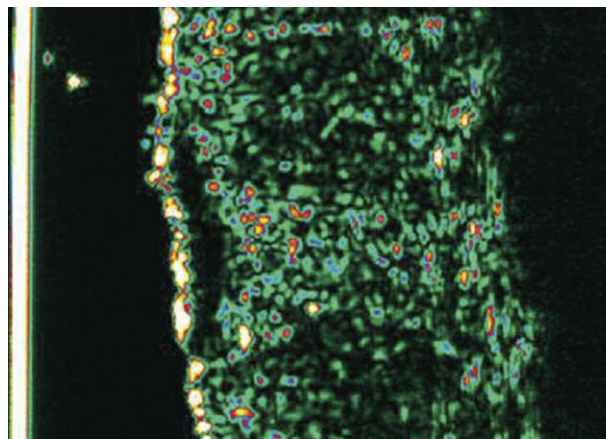
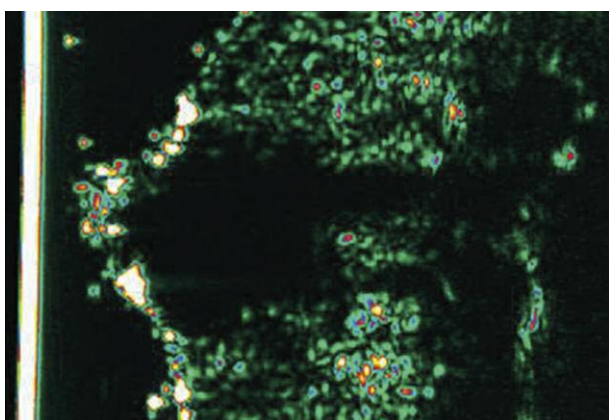
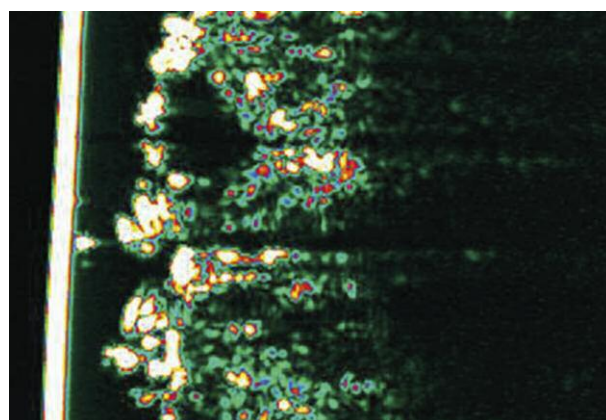
Mixed BCC is a subtype of BCC with a mixed histology. This mixed tumor is a carcinoma which is composed of two or more tumors within the same lesion, such as BCC and squamous cell carcinoma (SCC). An appropriate therapy for a nonaggressive tumor diagnosed from a superficial biopsy may not be adequate for the treatment of mixed BCC and the cancer may recur [15].

Dermoscopy

Dermoscopy is a noninvasive diagnostic technique that enables visualization of structures of the epidermis and dermis. The lesion is magnified 10–20 fold in a dermoscope or

Table 1. Dermoscopic patterns of BCC. Features are listed below according to frequency of their appearance in BCC lesions

	Non-pigmented BCC	Pigmented BCC	Superficial BCC
Frequency of appearance ↓	<ul style="list-style-type: none"> – lack of pigmentation – arborizing telangiectasias – ulceration – short fine superficial telangiectasia (D3) 	<ul style="list-style-type: none"> – lack of pigment network – large blue-gray ovoid nests – multiple blue-gray globules – leaf-like areas – spoke wheel areas – arborizing vessels – ulceration (D3) 	<ul style="list-style-type: none"> – shiny white to red areas – short fine telangiectasias – erosions – arborizing telangiectasias – blue-gray globules – leaf-like areas – large blue-gray ovoid nests (D4)

**Fig. 5.** Dermoscopy – non-pigmented nodular BCC**Fig. 6.** Nodular BCC. Trunk. Depth of infiltration 0.626 mm; transverse diameter 6.770 mm; perpendicular diameter 6.211 mm**Fig. 7.** Nodular BCC. Chin. Depth of infiltration 2.334 mm; transverse diameter 6.780 mm; perpendicular diameter 7.745 mm**Fig. 8.** Recurrent BCC. Scalp. Depth of infiltration 0.983 mm; transverse diameter 3.358 mm; perpendicular diameter 2.998 mm

even 70 fold in videodermoscopes [16]. Dermoscopy plays an important role in clinical differential diagnosis and is an adjunct to clinical examination improving the diagnosis of BCCs. The first step in dermoscopy is to differentiate non-melanocytic from melanocytic lesions. The next step in BCC diagnosis is to find at least one positive feature for BCC [17] (Table 1).

The dermoscopic criteria for BCC include the lack of a pigment network and at least one positive feature including: ulceration, multiple blue-gray globules, leaf-like areas, large blue-grey ovoid nests, spoke-wheel areas and arborizing (tree-like) telangiectasia [18]. Nodular pigmented BCCs may present as diffuse blue-white areas with ulceration [19].

The dermoscopic model for the diagnosis of non-pigmented BCC (Fig. 5) is based on the absence of pigmentation and

presence of such dermoscopic features such as arborizing telangiectasia, short fine superficial telangiectasia, non-arborizing vessels, ulceration and multiple small erosions [20].

Dermoscopic features observed in superficial BCC present as: shiny white to red areas, short fine telangiectasia, arborizing telangiectasia, small surface erosions, blue-gray globules, leaf-like areas and large blue-gray ovoid nests [21].

Ultrasonography

High frequency ultrasonography (HF-USG, ≥ 20 MHz) allows non-invasive three-dimensional assessment of skin tumors. Typically they present as spindle-shaped echo-poor or echo-lucent areas in the upper epidermis (Figs. 6–8). Def-

initely distinguishing between different types or subtypes of tumors (BCC, SCC, melanoma, nevi) is not possible [22, 23]. However, in some BCC lesions, contrary to melanoma and SCC, scattered hyperechoic spots were observed [24]. Histological structures which could be responsible for hyperechoic spots on HF-USG include calcification, cornfield cysts, clusters of parakeratotic or apoptotic cells, and necrosis [24].

HF-USG seems to be helpful in planning the treatment. A number of studies have shown a high correlation between ultrasonic and histological measurements of tumor thickness. Most of them were focused on melanoma, but there were some regarding BCC [25, 26]. However, in some cases when the tumor extends beyond the dermis-subcutis border, demarcation of the tumor mass is impossible since fatty tissue is also hypoechoic [27]. Preoperative assessment of tumor size may have an impact on decreasing morbidity. Moreover, HF-USG as a non-invasive method represents a great opportunity to follow up patients treated with non-invasive treatment methods such as imiquimod, 5-fluorouracil or photodynamic therapy [28, 29]. HF-USG performed before photodynamic therapy was shown to predict the probability of local recurrence following treatment [28].

Another tool which can be used for the estimation of tumor size is optical coherence tomography (OCT). It uses infrared light instead of ultrasound and is characterized by better resolution than HF-USG. The correlation between histological and OCT measurements was also proven [26, 30].

Histopathology

The radical treatment of BCC is usually preceded by biopsy of a lesion. Basal cell carcinoma is derived from undifferentiated pluripotent epithelial germ cells that are present in the basal cell layer of the interfollicular epidermis and in the bulge region of a hair follicle [31]. The place of origin is sometimes visible in well-prepared histological specimens; the tumor mass grows from the basal layer of the epidermis or from the follicular outer root sheath into the skin where it is surrounded by fibromyxoid stroma. The relationship with germinal appendage cells and interaction with the stroma results in different histological types of BCC and determines their biological behavior.

Basal cell carcinoma is composed of uniform cells with round or oval basophilic nuclei, larger and darker than nuclei of epidermal basal keratinocytes, with minimal cytoplasm. Cellular atypia is infrequent in most cases of BCC, excluding the rare pleomorphic (giant cell) type of BCC, but mitoses and apoptotic cells are frequent [31]. Interestingly, nuclear atypia and multiple mitoses do not alter the clinical course of BCC [32]. The most common histological type is nodular BCC with solid, well-bordered, irregular, lobulated tumor nests of various sizes surrounded by dense stroma with numerous fibroblasts and mucinous material, mostly hyaluronic acid. Typical for this type is empty peritumoral cleft due to retraction of the stroma (Fig. 9). The tumor nests extend to the papillary and reticular dermis. The basaloid cells form a regular palisade at the periphery while their distribution in the middle is chaotic. In the center of larger lobules areas of necrosis may develop leading to formation of cystic spaces containing mucinous material (nodulocystic BCC). In some places keratin cysts with parakeratotic debris can be seen as an example of hair follicle differentiation potential (keratotic BCC) (Fig. 10). Rarely, small infundibular cysts (infundibulocystic BCC) or cells with differentiation towards matrical cells of the hair follicle (BCC with matrical differentiation) can be seen within tumor lobules. Other tumor islands are composed of thin lace-like strands resembling tubular, gland-like structures surrounded by mucoid stroma (adenoid BCC). Sometimes parts of the tumor present features of sebaceous, eccrine or apocrine differentiation. All these types belong to the nodular clinical type and are of little importance for the biological behavior of the tumor. The foci of various adnexal differentiation can be visible within one nodular tumor as well as a micronodular, superficial, infiltrative or morpheaform component (Figs. 10, 11). Micronodular BCC is composed of small tumor nests with less prominent palisading and without peritumoral clefts (Fig. 11), which often infiltrates the dermis and subcutis. Clinical presentation differs from the nodular type and manifests as poorly demarcated indurated plaque and belongs to the high-risk BCCs. Superficial (multifocal) BCC represents horizontal spreading but can be aggressive. The histological presentation is characterized by numerous, small, basaloid nests attached to the lower part of the epidermis, separated by areas of normal epidermis

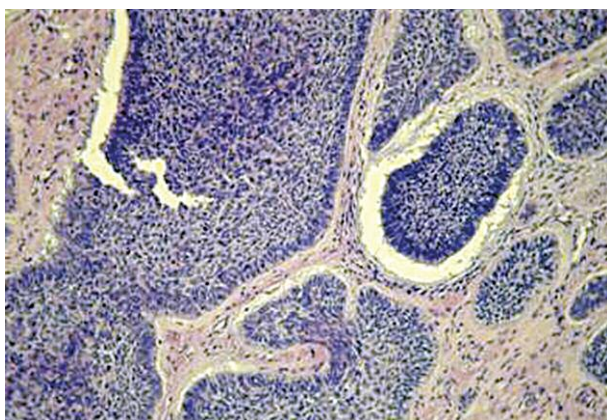


Fig. 9. Nodular BCC with peripheral palisade, mucofibrotic stroma and retraction clefts. HE, magnification 20×

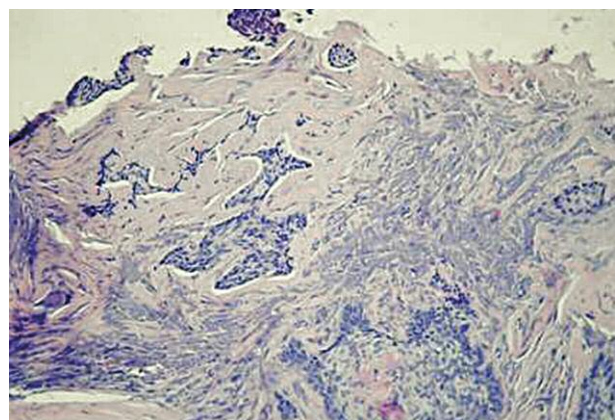


Fig. 10. Keratotic and infiltrative BCC. HE, magnification 20×

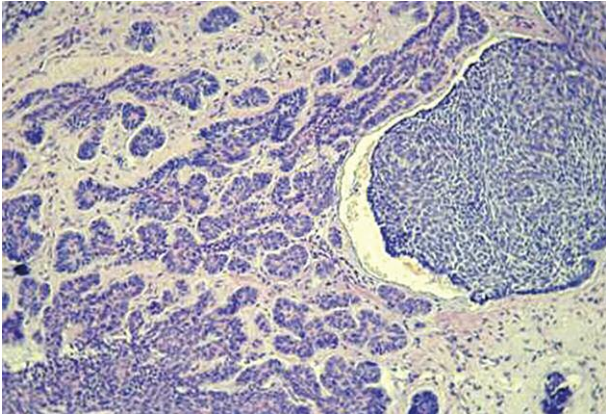


Fig. 11. Micronodular and nodular BCC. HE, magnification 20×

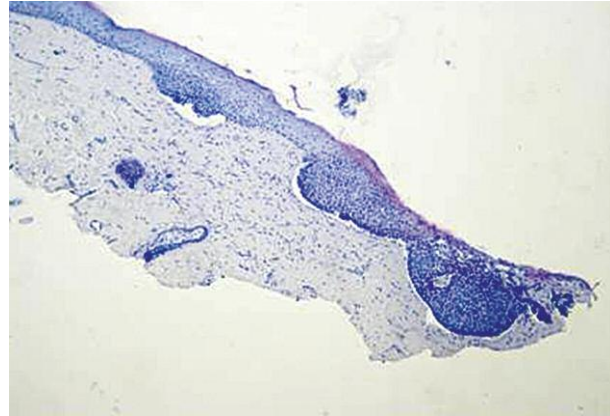


Fig. 12. Superficial BCC. HE, magnification 10×

(Fig. 12). They are in fact interconnected. Retraction artefacts are frequent. The spaces between lobules are sometimes quite wide so it is difficult to estimate the lateral border of the lesion. Peripheral parts of the nodulo-ulcerative tumor nests sometimes present infiltrative growth (Fig. 13). Small, narrow, sharp, irregular tumor strands invade fibrotic stroma. Palisading is usually absent. This BCC type is more aggressive and destructive due to extensive spread beyond the skin and higher mitotic activity. In morpheaform (sclerosing) type the dense fibrotic stroma dominates over small thin strands of the tumor cells. Peripheral palisading and retraction are usually absent. It is very difficult to estimate the border of the tumor both clinically and histologically. Keloidal BCC is a variant of morpheaform BCC. Infiltrative and morpheaform BCCs have high recurrence rates. They sometimes show perineural invasion, another poor prognostic feature. Pigmented BCC can represent all histological types, but mostly nodular and superficial type with melanin deposition within tumor lobules or in stromal macrophages (Fig. 14). Other rare variants are clear cell BCC, signet ring BCC, and granular BCC. Sometimes beside typical BCC islands foci of neoplastic squamous differentiation are seen. This type is called metatypical (basosquamous) BCC and is associated with more aggressive growth and poorer prognosis [31–33]. The highest number, 26 histological BCC subtypes, was described by Wade *et al.* [34].

In Gorlin-Goltz syndrome all histological types can be seen but nodular and superficial types are most frequent [30].

Pathological reports of both biopsied and excised tumors can give the clinician valuable information that is important for the choice of treatment method and follow-up procedures. The potential for subclinical extension beyond a clinically defined border and high recurrence risk can be determined on the basis of histological subtype (morpheaform, micronodular, metatypical) or particular features such as infiltrative growth or neurotropism. These BCCs belong to the aggressive, “high risk” group and require wider excision or Mohs surgery. The list of histological BCC subtypes and their potential for aggression is presented in Table 2 [33, 35]. However, biopsy may not be representative for the whole lesion since only a part of the tumor demonstrates infiltrative growth and perineural invasion. The pathological report of excised tumors should include the type and subtype of the tumor, features of aggressiveness such as those mentioned above, and assessment of lateral and deep

Table 2. Recurrence risk of different histological BCC variants

BCC – histological type	Recurrence risk, aggressiveness
nodular	low risk
nodulocystic	low risk
adenoid	low risk
keratotic	low risk
BCC with adnexal differentiation	low risk
superficial (multicentric)	low risk
micronodular	high risk
infiltrative	high risk
morpheaform	high risk
morpheaform with neural invasion	high risk
pleomorphic	low risk
clear cell	low risk
signet ring	low risk
basosquamous (metatypical)	high risk

surgical margins. However, even detailed examination of bread-loafed sections every 2–3 mm can miss small foci of the tumor extending beyond the excision margin between the sections, particularly in the case of infiltrative or sclerosing BCC. Whether the pathological report should include clinical recommendations has still to be determined [35].

In most cases BCC is easy to diagnose despite numerous variants and does not require confirmation by immunohistochemical staining. The immunohistochemical profile can be used to demonstrate the expression of cytokeratins that is typical for the bulge region of a hair follicle [31]. When compared with normal epidermis there is overexpression of desmoglein 2 and lower expression of desmoglein 3 in the BCC nests [36]. Tumors express BerEP4, bcl-2, CD10, SOX9, p53 and actin in more aggressive cases [31] (Table 2).

In conclusion diagnosis is usually clinical and clinical features are dependent on the subtype of BCC. Dermoscopy may be helpful. Skin biopsy is usually taken to identify a histological subtype of BCC for treatment planning. The key decision is to identify high versus low risk tumors. No matter

which treatment method is chosen, recurrences do occur and patients need to stay in a regular follow-up schedule.

The authors declare no conflict of interest.

References

- Miller DL, Weinstock MA. Non melanoma skin cancer In the United States: incidence. *J Am Acad Dermatol* 1994; 30: 774-8.
- Lear JT, Smith AG. Basal cell carcinoma. *Postgrad Med J* 1997; 73: 538-42.
- Krajowy rejestr nowotworów. <http://epid.coi.waw.pl/krn/>
- Gailani MR, Leffell DJ, Ziegler A, Gross EG, Brash DE, Bale AE. Relationship between sunlight exposure and a key genetic alternation in a basal cell carcinoma. *J Natl Cancer Inst* 1996; 88: 349-54.
- Hogan DJ, To T, Gran L, Wong D, Lane PR. Risk factors for basal cell carcinoma. *Int J Dermatol* 1989; 28: 591-4.
- Roenigk RK, Ratz JL, Bailin PL, Wheeland RG. Trends in the presentation and treatment of basal cell carcinomas. *J Dermatol Surg Oncol* 1986; 12: 860-5.
- Telfer NR, Colver GB, Morton CA. Guidelines for management of basal cell carcinoma. *Br J Dermatol* 2008; 159: 35-48.
- Goldberg LH. Basal cell carcinoma. *Lancet* 1996; 347: 663-7.
- Samarasinghe V, Madan V, Lear JT. Focus on basal cell carcinoma. *J Skin Cancer* 2011: 1-5.
- Ripley JJ. Why classify basal cell carcinoma? *Histopathology* 1998; 32: 393-8.
- Scrivener Y, Grosshans E, Cribier B. Variations of basal cell carcinomas according to gender, age, location and histopathological subtype. *Br J Dermatol* 2002; 147: 41-7.
- Reifenberger J, Ruzicka T. Rak podstawnokomórkowy. In: *Dermatologia*. Burgdorf WHC, Plewig G, Wolff HH, Landthaler M (ed.). Czelej, Lublin 2011: 1372-80.
- Abbas OL, Borman H. Basal cell carcinoma; a single-center experience. *ISRN Dermatol* 2012; 2012: 246542.
- Takenouchi T. Key points in dermoscopic diagnosis of basal cell carcinoma and seborrheic keratosis in Japanese. *J Dermatol* 2011; 38: 59-65.
- Cohen PR, Schulze KE, Nelson BR. Basal cell carcinoma with mixed histology: a possible pathogenesis for recurrent skin cancer. *Dermatol Surg* 2006; 32: 542-51.
- Kamińska-Winciorek G. Dermatoskopia jako technika diagnostyczna. In: *Dermatologia cyfrowa*. Cornetis, Wrocław 2008: 11.
- Argenziano G, Soyer HP, Chimenti S, et al. Dermoscopy of pigmented skin lesions: results of a consensus meeting via the internet. *J Am Acad Dermatol* 2003; 48: 679-93.
- Menzies SW, Westerhoff K, Rabinovitz H, Kopf AW, McCarthy WH, Katz B. Surface microscopy of pigmented basal cell carcinoma. *Arch Dermatol* 2000; 136: 1012-6.
- Felder S, Rabinovitz H, Oliviero M, Kopf A. Dermoscopic pattern of pigmented BCC, blue-white variant. *Derm Surg* 2006; 32: 569-70.
- Altamura D, Menzies SW, Argenziano G, et al. Dermoscopy of basal cell carcinoma: morphologic variability of global and local features and accuracy of diagnosis. *J Am Acad Dermatol* 2010; 62: 67-75.
- Scalvenzi M, Lembo S, Francia MG, Balato A. Dermoscopic patterns of superficial basal cell carcinoma. *Int J Dermatol* 2008; 47: 1015-8.
- Jasaitiene D, Valiukeviciene S, Linkeviciute G, Raisutis R, Jasiuniene E, Kazys R. Principles of high-frequency ultrasonography for investigation of skin pathology. *J Eur Acad Dermatol Venereol* 2011; 25: 375-82.
- Polańska A, Dańczak-Pazdrowska A, Silny W, Sadowska A, Jenerowicz D, Osmola-Mańkowska A, Olek-Hrab K. High frequency ultrasonography in monitoring the effects of treatment of selected dermatoses. *Postep Derm Alergol* 2011; 4: 255-60.
- Uhara H, Hayashi K, Koga H, Saida T. Multiple hypersonographic spots in basal cell carcinoma. *Dermatol Surg* 2007; 33: 1215-9.
- Bobadilla F, Wortsman X, Muñoz C, Segovia L, Espinoza M, Jemec GB. Pre-surgical high resolution ultrasound of facial basal cell carcinoma: correlation with histology. *Cancer Imaging* 2008; 8: 163-72.
- Hinz T, Ehler LK, Hornung T, Voth H, Fortmeier I, Maier T, Höller T, Schmid-Wendtner MH. Preoperative characterization of basal cell carcinoma comparing tumor thickness measurement by optical coherence tomography, 20-MHz ultrasound and histopathology. *Acta Derm Venereol* 2012; 92: 132-7.
- Schmid-Wendtner MH, Dill-Müller D. Ultrasound technology in dermatology. *Semin Cutan Med Surg* 2008; 27: 44-51.
- Moore JV, Allan E. Pulsed ultrasound measurements of depth and regression of basal cell carcinomas after photodynamic therapy: relationship of probability of 1-year local control. *Br J Dermatol* 2003; 149: 1035-40.
- Desai TD, Desai AD, Horowitz DC, Kartono F, Wahl T. The use of high-frequency ultrasound in the evaluation of superficial and nodular basal cell carcinomas. *Dermatol Surg* 2007; 33: 1220-7.
- Mogensen M, Nürnberg BM, Forman JL, Thomsen JB, Thrane L, Jemec GB. In vivo thickness measurement of basal cell carcinoma and actinic keratosis with optical coherence tomography and 20-MHz ultrasound. *Br J Dermatol* 2009; 160: 1026-33.
- Calonje E, Brenn T, Lazar A, McKee PH. Tumors of the surface epithelium. In: *McKee's Pathology of the skin with clinical correlations*. 4th ed. Vol. 2. Elsevier Saunders 2012: 1076-149.
- Lever WF, Schaumburg-Lever G. *Histopathology of the skin*. 7th ed. J.B. Lippincott Company 1990.
- Tüzün Y, Kutlubay Z, Engin B, Serdaroglu S. Basal cell carcinoma. In: *Skin Cancer Overview*. Yaguang X (ed.). InTech 2011; 51-86.
- Wade TR, Ackerman AB. The many faces of basal cell carcinoma. *J Dermatol Surg Oncol* 1978; 4: 23-8.
- Weinstein MC, Brodell RT, Bordeaux J, Honda K. The art and science of surgical margins for the dermatopathologist. *Am J Dermatopathol* 2012; 34: 737-45.
- Gornowicz-Porowska J, Bowszyc-Dmochowska M, Dmochowski M. Desmosomal Cadherins in Basal Cell Carcinomas. In: *Skin Cancer Overview*. Yaguang X (ed.). In Tech 2011; 31-50.

Address for correspondence

Małgorzata Mackiewicz-Wysocka MD, PhD
Chair and Department of Dermatology
Poznan University of Medical Sciences
Przybyszewskiego 49
60-355 Poznan, Poland
e-mail: mmackwys@ump.edu.pl

Submitted: 11.04.2013

Accepted: 10.06.2013