

# Identification of Complex Pneumonia during the Outbreak of COVID-19: Bacterial Pneumonia Combined with Acute Eosinophilic Pneumonia in Patients with Maintenance Hemodialysis

Qiong-dan Hu<sup>a</sup> Nan Mao<sup>b</sup> Xin-chun Huang<sup>a</sup> Ding-guo Chen<sup>a</sup> Qiong Zhang<sup>a</sup>

<sup>a</sup>Department of Nephrology, The Affiliated Traditional Chinese Medicine (TCM) Hospital of Southwest Medical University, Luzhou, China; <sup>b</sup>Department of Nephrology, The First Affiliated Hospital of Chengdu Medical College, Chengdu, China

## Keywords

COVID-19 · Hemodialysis · Acute eosinophilic pneumonia · Meropenem

## Abstract

It is of crucial importance to diagnose patients in a timely and clear manner during the outbreak of COVID-19. Different causes of pneumonia makes it difficult to differentiate COVID-19 from others. Hemodialysis patients are a special group of people in this outbreak. We present a successfully treated case of a patient with maintenance hemodialysis from acute eosinophilic pneumonia for using meropenem when treating bacterial pneumonia, avoiding possible panic and waste of quarantine materials in dialysis centers.

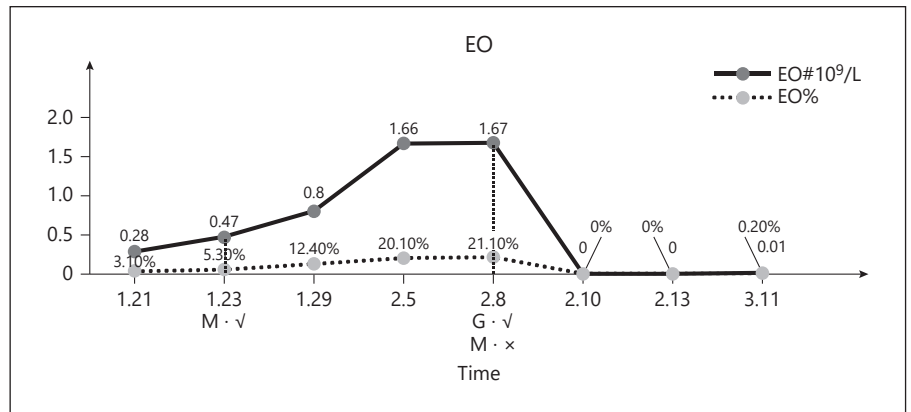
© 2020 S. Karger AG, Basel

## Introduction

On January 31, 2020, WHO declared the COVID-19 outbreak a Public Health Emergency of International Concern [1]. When screening patients without symptoms of COVID-19 in our Blood Purification Center, 26.5% of patients are found to have changes in pulmonary imag-

ing, including but not limited to pulmonary edema, atelectasis, acute and chronic bronchitis, pulmonary fibrosis, and bacterial pneumonia. Therefore, the differential diagnosis of COVID-19 is particularly important at this stage. Hemodialysis patients are a special group of people in this outbreak in the following ways. (1) patients need to travel between home and hospital frequently for dialysis treatment, suffering high risk of exposure and infection as they cannot complete absolute home quarantine. (2) Most dialysis centers are hall-style, no single-room isolated dialysis, so the risk of concentrated outbreak is very high. (3) Most patients with ESRD have low immunity, are more susceptible, and have a low cure rate after infection. Therefore, such patients, once presented with pneumonia symptoms, should be diagnosed at early stage in order to avoid the spread of infection or panic. Guidance on Treating COVID-19 from National Health Commission of the People's Republic of China (P.R.C) suggests differentiation of COVID-19 from other varieties of pneumonia, including flu virus, adenovirus, respiratory syncytial virus, mycoplasma pneumonia infection, vasculitis, dermatomyositis, organizing pneumonia, and eosinophilic pneumonia (EP) [2]. Among these, EP has an in-

Qiong-dan Hu and Nan Mao contributed equally.



**Fig. 1.** Eosinophil levels increased significantly after meropenem administration and decreased significantly after methylprednisolone administration.

**Table 1.** Laboratory investigations of patients before and after meropenem and methylprednisolone use: eosinophil levels increased significantly after meropenem administration and decreased significantly after methylprednisolone administration. Hs-CRP decreased with methylprednisolone and elevated PCT suggested bacterial infection

Drugs and indicator	Date								
	1.21	1.23	1.29	2.5	2.8	2.10	2.13	3.11	
Meropenem	– (before 3 d)	– (before 1 d)	+ (after 5 d)	– (after 12 d)	– (stop 1 d)	– (stop 3 d)	– (stop 6 d)	– (stop 33 d)	
Methylprednisolone	– (before 18 d)	– (before 16 d)	– (before 10 d)	– (before 3 d)	+ (after 0 d)	+ (after 2 d)	+ (after 5 d)	+ (after 32 d)	
WBC, 10 <sup>9</sup> /L	9.18	8.91	6.45	8.26	7.9	7.56	8.2	5.21	
NEUT%, %	73.50	69.30	54.70	53.00	46.50	87.00	80.30	86.50	
LYMPH%, %	15.30	16.60	20.90	16.90	19.50	9.50	10.60	7.70	
LYMPH#, 10 <sup>9</sup> /L	1.4	1.48	1.35	1.4	1.54	0.72	0.87	0.4	
EO#, 10 <sup>9</sup> /L	0.28	0.47	0.8	1.66	1.67	0	0	0.01	
EO%, %	3.10	5.30	12.40	20.10	21.10	0	0	0.20	
HGB, g/L	100	98	97	94	91	86	99	127	
PLT, 10 <sup>9</sup> /L	223	199	278	303	309	382	376	146	
hs-CRP, mg/L	84.47	127.02	95.27	113.14	135.74	52.06	9.51	0.89	
ESR, mm/H	–	–	–	–	123	–	–	3	
PCT, ng/mL	–	1.040	0.847	1.750	–	–	1.410	0.526	

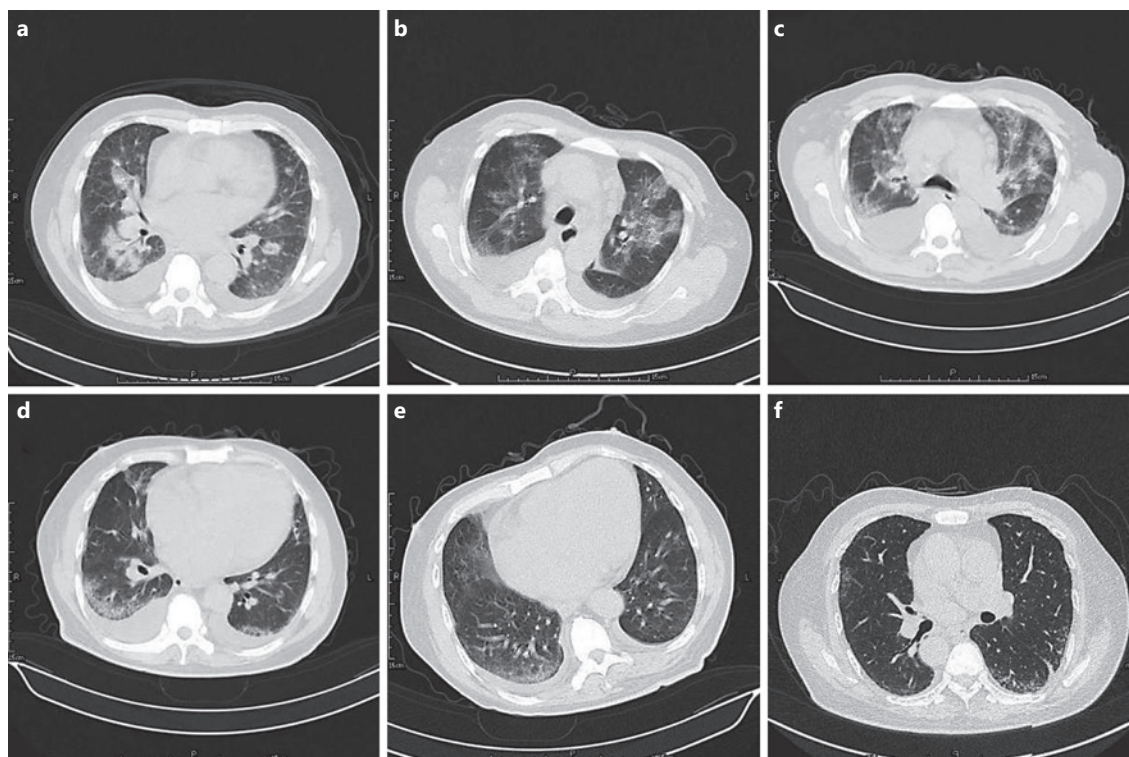
PCT, procalcitonin.

idence rate lower than 1/100,000 and is prone to misdiagnosis as an infectious disease, which will delay the diagnosis and treatment [3, 4]. Chest computed tomography (CT) in acute eosinophilic pneumonia (AEP) patients found that all patients had a glass-like impermeable shadow and no special lesions [5], a characteristic similar to COVID-19, making it difficult to identify.

### Case Report

A 63-year-old male patient, admitted on January 21, 2020, has been suffering from maintenance hemodialysis for 4 years and coughing for more than 10 days. The patient had his 1st hemodialysis on March 17, 2015, with unknown primary kidney disease

and allergic rhinitis history. He started to cough and felt heart exhaustion, breathing difficulties, and fatigue since January 11, 2020. After admission, physical check result came out as body temperature 36.2–37.2°C, heart rate 130 beats/min, blood pressure 120/65 mm Hg, respiratory rate of 22 breaths/min, medium crackles in double lungs, SO<sub>2</sub> 92–95% (low flow oxygen absorption), blood routine: lymphocyte percentage 15.3%↓ (Table 1), procalcitonin (PCT) 1.040 ng/mL↑ and negative in 9 counts of respiratory virus. Chest CT showed multiple infections in both lungs and pleural effusion (Fig. 2). Diagnosis considered it as possible bacterial pneumonia, suggested sputum culture, and used 3.75 g q12 h mezlocillin sodium/sulbactam sodium in intravenous drip based on experience. On January 24, coughing and breathing difficulties were not eased and lymphocyte percentage dropped by 16.6% (Table 1). In order to rule out the possibility of COVID-19, we did twice assessments of COVID-19 research including (1) on January 23, 2020, the 1st throat swab nucleic acid test was found



**Fig. 2.** Changes in chest CT: after the use of antibiotics, the imaging performance of pulmonary inflammation did not improve, while after the use of meropenem, the pulmonary patchy shadow significantly increased and pleural effusion increased. After the use of methylprednisolone, the pulmonary inflammation was absorbed and finally cured. The imaging changes of the lung were consistent with the time nodes of eosinophil changes. CT, computed tomography. **a** 21st Jan. **b** 31st Jan. **c** 06th Feb. **d** 06th Feb. **e** 15th Feb. **f** 12th Mar.

negative on the 3rd day of admission; (2) on January 24, 2020, the 2nd nose swab nucleic acid test was negative on the 4th day of admission. The above tests were carried out in the laboratory of the Traditional Chinese Medicine Hospital Affiliated to Southwest Medical University under the guidance of the Prevention and Control Headquarters for COVID-19 of the hospital. Doctors considered that bacterial pneumonia is still not under control, so they upgraded the antibiotic to 1 g q12 h meropenem in drip infusions. Subsequently, the patient suffered aggravated breathing difficulties, and oxygen saturation dropped to 85% (non-oxygen absorption). Chest CT showed multiple inflammations in both lungs, some lesions absorbed, but other lesions accumulated, and fluid increased in the right chest cavity (Fig. 2). Peripheral blood eosinophils (EOS) were found to have increased to 12.4% on January 29 followed by a progressive elevation, reaching 21.1% by February 8 (Table 1; Fig. 1). With negative endotoxin + G test, chest CT was conducted again on February 6, showing multiple inflammation and increased lesions in upper lobe of both lungs and fluid in both chests (Fig. 2). We had to reconsider the diagnosis and believed that bacterial pneumonia had combined with AEP which is very likely to be caused by drugs. As meropenem was the only drug approved then, it was, therefore, stopped. Due to the continuous rise of PCT and the ongoing bacterial pneumo-

nia, antibiotics were replaced with 0.4 g qd moxifloxacin and 40 mg q.d. methylprednisolone in drip infusions since February 8. Patient's symptoms improved significantly and peripheral blood EOS returned to normal on February 10 (Table 1; Fig. 1). On February 16, the patient was discharged from the hospital as he has turned significantly better (chest CT showed inflammation has started to be absorbed in both lungs and the amount of fluid in the both chest cavity kept dropping.) (Fig. 2). After discharge from the hospital, the patient was instructed to take 10 mg t.i.d. prednisone. Follow-up on March 12 found normal peripheral blood EOS (Table 1; Fig. 1) and basically absorbed inflammation in both lungs and no fluid in both chests in CT (Fig. 2).

## Discussion

It is easy to be misdiagnosed as EP has a low incidence rate and similar clinical symptoms with other infectious diseases, particularly during the outbreak of COVID-19. The diagnosis of AEP is as follows: (1) acute onset, mainly manifested as fever, myalgia, cough, shortness of

breath, and chest pain, (2) increase in peripheral blood EOS, (3) hypoxemia ( $\text{PaO}_2 < 60$  mm Hg); some patients developed severe respiratory failure, (4) CT showed diffuse infiltration of pulmonary parenchyma; small to moderate amounts of pleural effusion may be present, and (5) a large number of eosinophilic cells were found in bronchoalveolar lavage fluid. EP and COVID-19 shared similar clinical symptoms and CT image results as glass-like impermeable shadows and lesions appearing in the double lung [5–8], making it crucial to carefully differentiate the two. The etiology of EP is unknown, and almost half of EP patients have a history of allergic reactions, rhinitis, chronic sinusitis, etc. [9]. It maybe idiopathic or caused by parasitic infections and toxicity from certain drugs [10]. The Food and Drug Administration declared in 2010 that EP may occur when using Cubicin [11]. Literature reports that there are more than 20 patients worldwide diagnosed with AEP because of minocycline [12]. Even though the review on literature did not show the direct link between meropenem and AEP, a scholar once presented a case of AEP caused by meropenem [13]. The patient in this report has a history of allergic rhinitis, and the possibility of viral pneumonia, mycoplasma, pneumonia, and fungal infection has been ruled out. Novel corona virus pneumonia was excluded after the 2 nucleic acid tests because the patient had no history of epidemiology or exposure history of COVID-19 and PCT was elevated. The successful treatment of the patient did again prove that he was not infected with COVID-19. In the early stage of diagnosis and treatment, considering he has been coughing for 10 days, we have reason to believe it as bacterial pneumonia based on his clinical manifestations, pulmonary imaging, and PCT results, so we gave him antibiotic treatment. However, the symptoms and the pathological changes of chest imaging aggravated after the sufficient treatment of antibiotics, which was not consistent with the common features of bacterial pneumonia. With the gradual increase of EOS in peripheral blood a few days after the use of meropenem, we began to suspect the possibility of bacterial pneumonia combined with AEP. Moreover, the time of eosinophil elevation in peripheral blood is closely related to the time that meropenem was applied, and the patient recovered completely after switching from meropenem to methylprednisolone. We highly suspect that the patient did not suffer from primary EP but AEP likely caused by meropenem. We would consider primary EP only after we cannot find AEP caused by drugs, parasites, and other factors. Though we also consider the possibility that the

hemodialysis patient may have allergic reactions due to poor biocompatibility such as dialysis water and filter membranes, the patient has been going to the same dialysis centers and using the same dialysis machine over the past 4 years. Also, he did not replace the filters. All being said, it can be concluded that meropenem is the possible new culprit of AEP, whether from the perspective of the patient's history and progress of disease, the high consistency in timing of using meropenem and increase of eosinophilia in peripheral blood, the complete and rapid remission after changing from meropenem to glucocorticoid, or the fact that there's no recurrence in the patient in his follow-up monitoring.

There are 2 minor regrets in this case report. (1) As the patient was very weak, the amount of sputum was very limited. Although we managed to take sputum samples for sputum culture and drug sensitivity test, the test results showed that the sample did not cultivate typical pathogenic bacteria. This kind of situation is very common in clinical, especially in severe patients, as they have no strength to cough out the deep thick sputum, and even the sputum aspirator cannot obtain qualified samples. But this cannot exclude bacterial pneumonia because the diagnosis of the patient was evaluated based on symptoms, PCT examination, and imaging support. (2) This case occurred in a very special period. We had very limited knowledge about the corona virus at the beginning of the outbreak in China, January 2020, and nucleic acid testing can show false-negative results. In order to prevent and control the large area infection, the government and the hospitals in China have to formulate such preventive measures: unless in life-threatening situations, all hospitals shall stop all invasive respiratory operations in order to avoid being infected by patients who has not been confirmed without COVID-19. That was why we did not perform the bronchoscopy and biopsy for the patient. With the help of clinical experience when we cannot confirm from pathological perspectives, we not only cured the patient but also avoided the panic of such a special population as hemodialysis patients and saved the protective materials. We think the current measure may exist in many hospitals around the world and will last for a while. Therefore, it would be highly appreciated if we can pay attention to the authenticity and reliability of this case which reflects the reality of diagnosis and treatment in a special period and our practical and realistic academic attitude. Hopefully, it can provide new directions when formulating prevention and control measures around the world.

## Conclusion

In conclusion, as we only have a preliminary understanding of COVID-19 since the outbreak and patients with maintenance hemodialysis suffer very high risk of infection after exposure, it is worthwhile to conduct in-depth study and discussion on identification diagnosis of such group of people in order to facilitate effective prevention and control.

## Acknowledgement

The authors would like to thank our renal dialysis center and the nursing colleagues in carrying out this treatment based on our newly developed protocol.

## References

- 1 World Health Organization [Internet]. COVID-19 outbreak declared to be a Public Health emergency of international concern (PHEIC). 2020
- 2 General Office of the National Health Commission of China Published [Internet]. Guidance on treating COVID-19 (Draft Version VI). 2020 <http://www.nhc.gov.cn/yzygi/s7653p/202002/8334a8326dd94d329df351d7da8aefc2/files/b218cfef1bc54639af227f922bf6b817.pdf>.
- 3 Kara PH, Uenal R, Unluer EE. A must diagnosis of persistent cough: chronic eosinophilic pneumonia (Carrington disease). *Am J Emerg Med*. 2016;34(8):1734–6.
- 4 Bernheim A, McLoud T. A review of clinical and imaging findings in eosinophilic lung diseases. *AJR Am J Roentgenol*. 2017;208(5):1002–10.
- 5 De Giacomi F, Decker PA, Vassallo R, Ryu JH. Acute eosinophilic pneumonia: correlation of clinical characteristics with underlying cause. *Chest*. 2017;152(2):379–85.
- 6 Mehrian P, Doroudinia A, Rashti A, Aloosh O, Doroudinia A. High-resolution computed tomography findings in chronic eosinophilic vs. cryptogenic organising pneumonia. *Int J Tuberc Lung Dis*. 2017;21(11):1181–6.
- 7 Jin Y-H, Cai L, Cai L, Cheng Z-S, Cheng H, Deng T, et al. A rapid advice guideline for the diagnosis and treatment of 2019 novel coronavirus (2019-nCoV) infected pneumonia (standard version). *Mil Med Res*. 2020;7(1):4.
- 8 General Office of the National Health Commission of China Published [Internet]. Guidance on treating COVID-19 (Draft Version VII). 2020 <http://www.nhc.gov.cn/yzygj/s7653p/202003/46c9294a7dfe4cef80dc7f5912eb1989/files/ce3e6945832a438eaae415350a8ce964.pdf>.
- 9 Funda Y, Zafer HAS, Nurefsan B, Mehmet G. A chronic eosinophilic pneumonia case with long exposure to isocyanates. *J Pak Med Assoc*. 2014;64(10):1191–4.
- 10 Nakayasu H, Shirai T, Tanaka Y, Saigusa M. Chronic eosinophilic pneumonia after radiation therapy for squamous cell lung cancer. *Respir Med Case Rep*. 2017;22:147–9.
- 11 The U.S. Food and Drug Administration Published [Internet]. FDA Drug Safety Communication: Eosinophilic pneumonia associated with the use of Cubicin (daptomycin). 2010 <https://www.fda.gov/drugs/postmarket-drug-safety-information-patients-and-providers/fda-drug-safety-communication-eosinophilic-pneumonia-associated-use-cubicin-daptomycin>.
- 12 You GH, Jia L. Summary and data analysis of foreign cases of minocycline-induced acute eosinophilic granulocytes. *Chin J New Drugs*. 2017;26(13):1590–4.
- 13 Hatem NA, Campbell S, Rubio E, Loschner AL. Meropenem: a possible new culprit in eosinophilic lung diseases. *Lung India*. 2017;34(5):461–4.

## Statement of Ethics

This research complied with the guidelines for human studies and was conducted ethically in accordance with the 1964 Helsinki Declaration. We state that the subject has given his written informed consent to publish his case (including publication of images).

## Conflict of Interest Statement

The authors have no conflicts of interest to declare.

## Author Contributions

Q.H.: literature research, collecting data, writing, and editing the manuscript (nephrologist, associate professor). N.M.: writing and editing the manuscript (nephrologist, associate professor). X.H. and D.C.: collecting data (resident). Q.Z.: writing and editing the manuscript (nephrologist, professor).