

Diagnostic performance of magnetic resonance technology in detecting steatosis or fibrosis in patients with nonalcoholic fatty liver disease

A meta-analysis

Xiao-min Wang, MM^{a,b}, Xiao-jing Zhang, MM^a, Lin Ma, MD^{a,*}

Abstract

Background: The aim of this study was to evaluate the diagnostic accuracy of magnetic resonance (MR) imaging-based methods for detecting steatosis and fibrosis in nonalcoholic fatty liver disease (NAFLD).

Methods: Data were extracted from research articles obtained after a literature search from multiple electronic databases. Random-effects meta-analyses were performed to obtain overall effect size of the area of operator receiver curve (AUROC), sensitivity and specificity of MR imaging, MR elastography, and MR spectroscopy in detecting or grading steatosis/fibrosis. Meta-analysis of correlation coefficients was performed to have an overall effect size of correlation between MR-based diagnosis and histological diagnosis.

Results: Twenty-one studies (1658 subjects; 45.32 years [95% CI: 35.94, 54.71] of age, 53.67% [45.39, 61.95] males, and 29.98 kg/m² [21.93, 38.04] BMI) were included in the meta-analysis. Pooled analyses of the AUROC, specificity, and sensitivity values reported in the individual studies revealed an overall effect sizes of 0.90 (0.88, 0.92), 82.27% (77.74, 86.80), and 86.94% (84.18, 95.28) in the use of any MR-based technique for the diagnosis of NAFLD or its severity. The correlation coefficient between MR-based detection of liver steatosis and histologically measured steatosis was 0.748 (0.706, 0.789) ($P < .00001$).

Conclusion: MRI-based diagnostic methods are valuable additions in detecting NAFLD or determining the severity of the NAFLD.

Abbreviations: AUROC = area of operator receiver curve, MR = magnetic resonance, MRE = MR elastography, MRI = MR imaging, MRS = MR spectroscopy, NAFLD = nonalcoholic fatty liver disease, NASH = nonalcoholic steatohepatitis, NHANES = National Health and Nutrition Examination Survey.

Keywords: diagnosis, fibrosis, magnetic resonance, nonalcoholic fatty liver disease, steatosis

1. Introduction

Nonalcoholic fatty liver disease (NAFLD) is characterized by fat accumulation found in the liver of individuals with no excessive alcohol consumption or other known pathologies.^[1] NAFLD is the most common chronic liver disease of adults and children with a strong potential for developing into a serious public health problem.^[2] NAFLD represents a wide spectrum of liver damage, ranging from simple steatosis (infiltration of fat into the liver) to

steatohepatitis (hepatocellular inflammation and injury) and advanced fibrosis (accumulation of fibrous connective tissue). These conditions have the potential to progress to cirrhosis, portal hypertension, terminal liver failure, and hepatocellular carcinoma.^[3]

NAFLD is thought to be linked to metabolic syndrome with visceral obesity and type II diabetes being the 2 most important associations.^[4–6] In patients with nonalcoholic steatohepatitis (NASH), almost half of deaths are due to cardiovascular disease and malignancy. Cirrhosis is the 3rd-leading cause of death in patients with NAFLD and is likely to become the most common indication for liver transplantation. Moreover, the morbidity associated with NAFLD may also extend beyond the liver.^[7]

In United States, between 75 and 100 million individuals, or 30% of the population are affected by NAFLD, while NASH affects approximately 5% of the population.^[7] In a National Health and Nutrition Examination Survey III, unexplained aminotransferase elevations (most likely due to NAFLD) were found in 5.4% of the general population.^[8] Similar prevalence rates are also reported for Japanese^[9] and Italian^[10] populations. In subjects recruited by random selection from the Chinese government census database, NAFLD were found in 27.3% of the general adult population.^[11]

A number of methods are used for the diagnosis of NAFLD. For the distinction of simple steatosis from NASH, liver biopsy is still the gold standard not only for diagnosis, but also for the assessment of fibrosis and to stage the disease. Liver histology is also an accurate tool for therapeutic efficacy and prognosis of NAFLD. However, several noninvasive imaging methods have

Editor: Kou Yi.

Ethics approval and consent to participate: Informed consent was not required owing to the meta-analytical design of this study.

The authors have no funding and conflicts of interest to disclose.

Supplemental Digital Content is available for this article.

^a Department of Radiology, Chinese PLA General Hospital, Beijing, ^b School of Medical Imaging, Tianjin Medical University, Tianjin, China.

* Correspondence: Lin Ma, Department of Radiology, Chinese PLA General Hospital, No.28, Fuxing Road, Beijing 100853, China (e-mail: cjr.malin@vip.163.com).

Copyright © 2018 the Author(s). Published by Wolters Kluwer Health, Inc. This is an open access article distributed under the terms of the Creative Commons Attribution-Non Commercial-No Derivatives License 4.0 (CCBY-NC-ND), where it is permissible to download and share the work provided it is properly cited. The work cannot be changed in any way or used commercially without permission from the journal.

Medicine (2018) 97:21(e10605)

Received: 24 October 2017 / Accepted: 6 April 2018

<http://dx.doi.org/10.1097/MD.00000000000010605>

been introduced or being developed for the detection and staging of liver steatosis and fibrosis. Among these, ultrasound-based transient elastography and shear wave elastography involve acoustic force radiation imaging and supersonic imaging. Magnetic resonance (MR)-based methods such as diffusion-weighted MR imaging (MRI), dynamic contrast-enhanced MRI, MR elastography (MRE), and MR spectroscopy (MRS) are also useful for the detection or grading of hepatic steatosis and fibrosis.^[2,12]

Many authors have reported the diagnostic performance of MR methods for detecting or grading liver steatosis and/or fibrosis in NAFLD patients. In general, all have reported good diagnostic accuracy of MRE, MRI, and MRS, but outcomes vary across these studies. The aim of this study is to provide a comprehensive analysis of the relevant statistical indices used to assess the diagnosis accuracy evaluating the overall performance of MR methods used to diagnose NAFLD.

2. Method

This study was performed by following the Cochrane Collaboration guidelines for conducting systematic reviews and meta-analyses and is reported in accordance with the PRISMA statement.

2.1. Inclusion and exclusion criteria

The inclusion criteria for this review were studies that evaluated the diagnostic performance of one or more MR method/s for diagnosing steatosis or fibrosis in subjects with NAFLD or suspected NAFLD and studies that reported area of operator receiver curve (AUROC), specificity, and sensitivity values of the diagnostic efficiency in NAFLD. Studies were excluded if they utilized an MR method for liver fat detection but did not report AUROC values, used an MR method to detect or measure fat of an organ other than liver in NAFLD patients, or reported the outcomes of both NAFLD and other patients with related conditions without discrimination.

2.2. Literature search

Several electronic databases were searched including Embase, Google Scholar, Ovid SP, and PubMed. The databases were searched for the retrieval of research articles reporting the outcomes of the diagnostic accuracy of one or more MR method/s of detecting steatosis or fibrosis in subjects with suspected NAFLD or in NAFLD patients. The literature search was based on important keywords which were used in logical combinations. These included “non-alcoholic fatty liver disease,” “NAFLD, steatosis,” “fibrosis,” “fat,” “fat fraction,” “lipids,” “magnetic resonance,” “MR imaging,” “MRI,” “MR elastography,” “MRE,” “MR spectroscopy,” “MRS, proton spectroscopy,” “H-MRS,” “proton-density fat fraction,” “area under operator receiver curve,” “AUROC,” “specificity,” “sensitivity,” “true positive,” “false positive,” “false negative,” “diagnosis,” and “diagnostic accuracy.” Corroborations and cross references of relevant research papers were also searched. The literature search included research articles written in the English language and published before October 2017.

2.3. Data extraction, synthesis, and statistical analysis

Data regarding the demographic, clinical, and pathological variables of the participants, MR method/s, outcome measures, and outcomes of the study were obtained from published research articles of

respective studies. Extracted data were organized in specialized datasheets. For achieving the pooled estimates of AUROC, sensitivity, and specificity, meta-analyses were performed using a random-effects model with Stata software (version 12; Stata Corporation, College Station, TX). For each of the pooled analyses, the overall effect size was a weighted average of the inverse variance adjusted for individual effect sizes. Subgroup analyses were performed with regards to MRI, MRE, and MRS methods or with regards to diagnostic accuracy of detecting steatosis versus fibrosis.

For determining the strength of relationship between histological measurement of steatosis and MR-based steatosis measurement, meta-analysis of correlation coefficients (r) was performed by using r values reported by individual studies. The r values reported in each of the included studies were first converted into Fisher z scores. Meta-analyses were performed under random-effects model with Stata software. For each of the pooled analysis, the overall effect size was a weighted average of the inverse variance adjusted individual effect sizes (z scores). Significance of relationship was tested by a z -test against zero-effect size. The overall effect size achieved in the meta-analysis was then back-transformed into correlation coefficients.

The random-effects model for meta-analyses was selected for 2 reasons. The first was the need for a pooling effect of the sizes resulting from varying diagnosing techniques and clinical conditions of steatosis and MRI discrimination cutoff used in the individual studies. The 2nd reason the random-effects model was chosen was due to the statistical heterogeneity of the outcome data. Between-study inconsistency was tested by I^2 index. For the assessment of publication bias, funnel plot symmetry test (Begg tests) was performed and trim and fill method was used for the estimation of missing studies. All data are presented as weighted effect sizes with 95% confidence interval. Table 1 and Figs. S1–6, <http://links.lww.com/MD/C226>, can be found in supporting information file.

3. Results

Twenty-one studies^[13–33] were included in the meta-analysis (Fig. 1). In these studies, one or more MR techniques to detect steatosis or fibrosis were used for 1658 subjects. Important characteristics of these studies are presented in Table 1. Age, percentage of males, and body mass index of the subjects were 45.32 years (95% confidence interval: 35.94, 54.71), 53.67% (45.39, 61.95), and 29.98 kg/m² (21.93, 38.04). Begg test indicated a significant publication bias (adjusted Kendall score: 29 ± 11.18; $P = .009$) and fill and trim method identified 3 possible missing studies (Fig. 2).

Pooled analysis of the AUROC values reported in the individual studies revealed an overall AUROC value of 0.90 (0.88, 0.92) ($I^2 = 76.2\%$) in the use of any MR technique (MRI, MRE, or MRS) for the diagnosis of NAFLD or its severity (Fig. 3). In the subgroup analysis, use of MRI had AUROC of 0.95 (0.93, 0.97) ($I^2 = 71.5\%$), whereas use of MRE and MRS were associated with effect sizes of 0.89 (0.86, 0.91) ($I^2 = 61.2\%$) and 0.88 (0.82, 0.93) ($I^2 = 0\%$), respectively.

Pooled analysis of the sensitivity of any MR technique (MRI, MRE, or MRS) for the diagnosis of NAFLD or its severity revealed an overall sensitivity of 82.27 (77.74, 86.80) ($I^2 = 99\%$; Fig. S1, <http://links.lww.com/MD/C226>) in use. In the subgroup analysis, the use of MRI had sensitivity of 90.78 (86.21, 95.34) ($I^2 = 98\%$), whereas use of MRE and MRS were associated with effect sizes of 77.29 (71.51, 83.03) ($I^2 = 99\%$) and 91.27 (89.85, 93.93) ($I^2 = 0\%$), respectively.

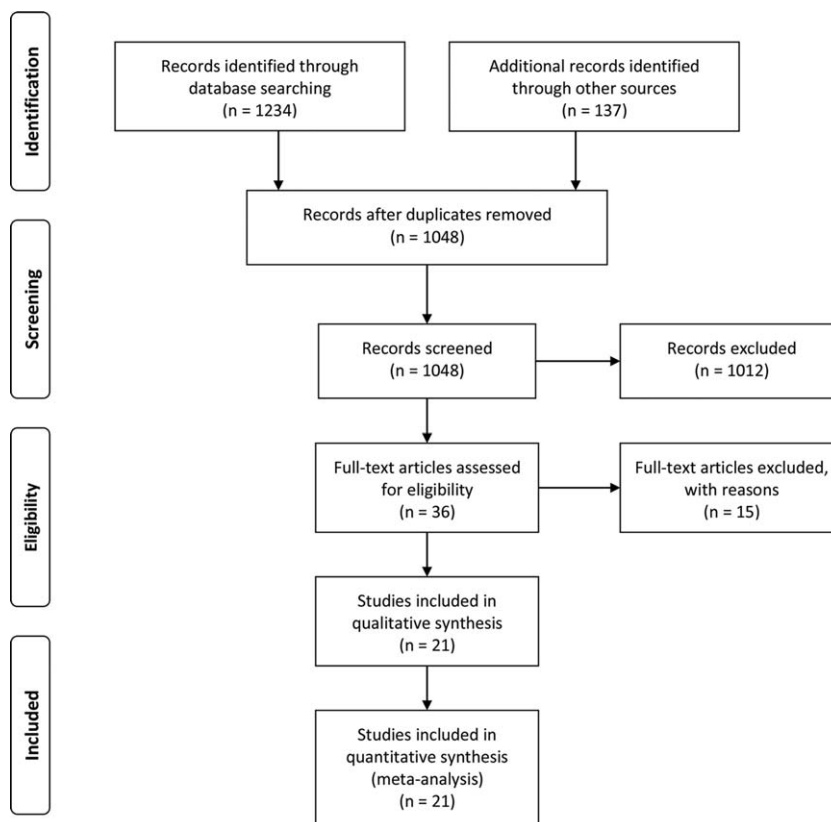
Table 1**Important characteristics of the included studies.**

Study	n	Age, y	Males, %	BMI, kg/m ²	Steatosis stage				Fibrosis stage				
					S0	S1	S2	S3	F0	F1	F2	F3	F4
Bastati 2014	81	55 ± 13	56	28.5 ± 4.5	0	44	14	23	26	36	10	9	0
Chen2011	58	51.5 ± 13	17	38.3 ± 7.5						15	3	5	6
Chen 2017	111	48.8 ± 2.5		40 ± 2					42	29	18	11	11
Cui 2015	102	51.3 ± 14	41	31.7 ± 5.5	4	36	39	31	48	26	9	13	6
Cui 2016	125	48.9 ± 15.4	54	31.8 ± 7	4	41	39	39	53	39	12	12	9
dAssignies 2009	20	53.7 ± 11	75	27.7 ± 3.9									
Hatta 2010	26	44.7 ± 16.4	46	28.4 ± 4.4					7	13	4	2	0
Idilman 2015	19	41.7 ± 13.1	78.9	27.5 ± 3.3	2	5	5	7	12	6	1	0	0
Imajo 2016	142	57.5 ± 14.6	57	28.1 ± 4.63	0	59	59	24	14	51	32	34	11
Karlas 2014	65	55 ± 10	38.5	29.2 ± 4.4	15	18	20	12	15	32	2	3	2
Kim 2013	142	52.8 ± 12.8	27	36.3 ± 7.4					50	34	12	10	36
Loomba 2014	117	50.1 ± 13.4	44	32.4 ± 5	0	41	43	33	43	39	13	12	10
Loomba 2016	100	50.2 ± 13.6		32.1 ± 5									
Middleton 2017	78	51 ± 11	35		1	37	44	31					
Pacifico 2007	50	10.5 ± 3.25		2.48 ± 0.72									
Pacifico 2011	25		64	28.4 ± 4.97	0	9	9	7	7	8	9	1	0
Park 2017	72	50.8 ± 14.6	62.5	30.4 ± 5.2	9	49	29	16	47	24	11	13	8
Permutt 2012	50	48.5 ± 2.8	53	32 ± 1.2	0	13	24	13					
Smits 2016	24	56.3 ± 9	70.8	28.2 ± 3.6	2	4	5	7	4	2	9	1	2
Schwimmer 2015	174	14.4 ± 2.3	67.8	33 ± 6	24	50	50	50	99	45	4	20	6
Tang 2013	77	14 ± 13	79.2	33.2 ± 6	5	26	27	19	31	28	10	8	0

BMI=body mass index.

Pooled analysis of the specificity values reported in the individual studies revealed an overall specificity of 86.94 (84.18, 95.28) ($I^2=99%$; Fig. S2, <http://links.lww.com/MD/C226>). In the subgroup analysis, the use of MRI had

specificity of 90.10 (85.81, 94.40) ($I^2=98%$), whereas use of MRE and MRS were associated with specificity of 86.40 (82.92, 89.89) ($I^2=99%$) and 82.13 (68.99, 95.28) ($I^2=91%$), respectively.

**Figure 1.** A flowchart of study screening and selection process.

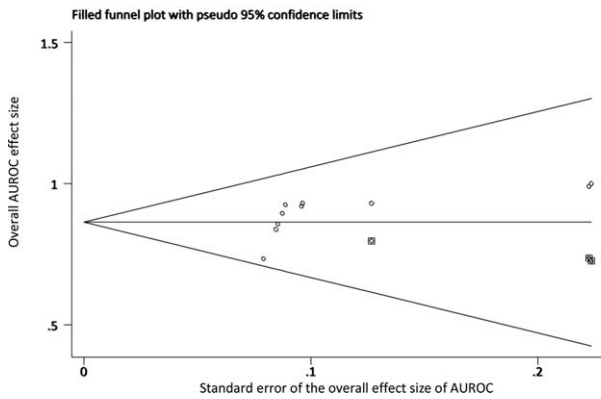


Figure 2. A funnel plot showing the outcomes of a publication bias test.

A meta-analysis of correlation coefficients between an MR method of detecting liver steatosis and histologically measured steatosis reported in individual studies revealed an overall effect size of 0.748 (0.706, 0.789); ($I^2=12\%$; $P<.00001$; Fig. S3, <http://links.lww.com/MD/C226>).

4. Discussion

In the diagnosis of steatosis or fibrosis or their severities, MR methods are found to have good diagnostic accuracy with an overall AUROC of 0.90, sensitivity of 82%, and specificity of 87%. All 3 major MR methods; the MRI, MRE, and MRS also exhibited good AUROC (0.95, 0.89, and 0.88, respectively). Moreover, the correlation coefficient between MR-based diagnosis of steatosis and histologically measured steatosis was significantly predictive ($r=0.75$).

Liver fibrosis and steatosis are the most usual targets of noninvasive imaging tests for the assessment of NAFLD. MRI,

AUROC for MR techniques to diagnose NAFLD

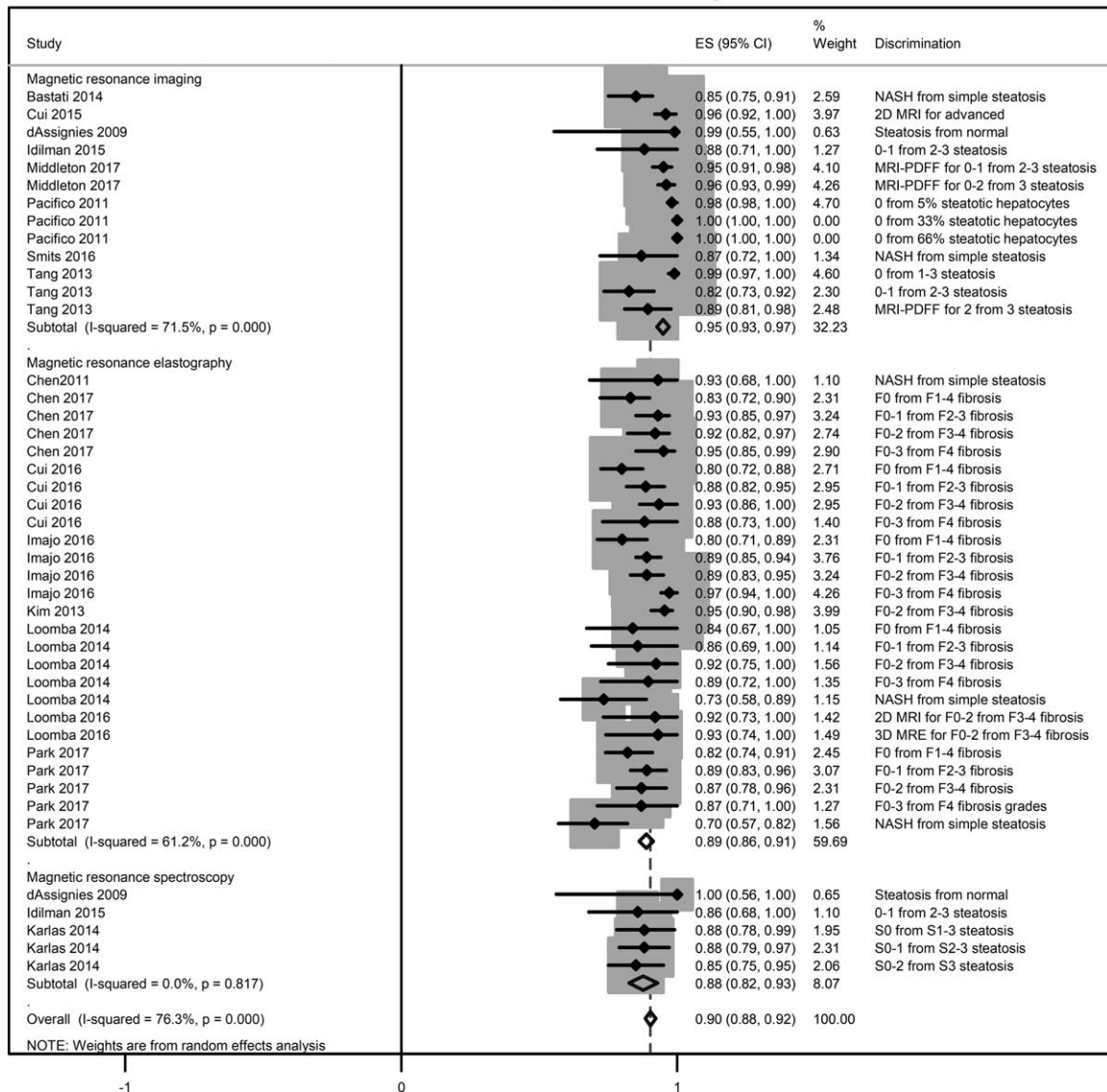


Figure 3. A forest chart showing the overall and subgroup wise effect size of the area of operator receiver curve (AUROC) values obtained by the pooling of effect sizes reported in the individual studies.

MRE, and MRS accurately diagnose fibrosis and steatosis in NAFLD patients.^[29] MR-based methods are now increasingly used for NAFLD diagnosis. Unlike sonographic methods which are operator-dependent, MRI is easier to interpret and have no interobserver variation constraints.^[27] MRE is a valuable tool for differentiating NAFLD from NASH and unlike conventional transient elastography, works well with obese subjects.^[34] MRS is an accurate and faster method of detecting liver fat and allows detailed examination of areas of interest. However, MRS is expensive and may not be routinely available.^[35] Chemical shift-based MRI techniques such as proton density fat fraction-MRS can provide high-resolution 3-dimensional imaging. These techniques have shorter acquisition time and measure fat content in whole liver.^[36,37] Diffusion-weighted MRI, which is based on the random motion of water protons, is a valuable technique to measure tissue microstructure. Clinically, diffusion-weighted MRI is used in the assessment of diffuse diseases, including the diagnosis of diffuse liver disease and for grading of hepatic fibrosis.^[38]

In pediatric populations, NAFLD tends to develop in obese children, even though many remain asymptomatic. This makes it difficult to recognize NAFLD in children, except in those with hepatomegaly.^[27] Liver biopsy is not frequently performed in children and NAFLD cannot be predicted by clinical and/or anthropometrical findings, although there is good correlation between the degree of liver fatty infiltration and elevation of liver enzymes.^[39] A study using histopathologic validation has shown that the modified T1-weighted dual-echo MRI method provides high diagnostic and fat-grading accuracy in obese children with NAFLD.^[28]

McPherson et al^[40] have reported the accuracy of the MRI techniques was lower in patients with moderate to severe fibrosis, although the diagnostic accuracy was better with MRS. Idilman et al^[20] have also found the estimation of liver fat content by both proton density fat fraction MRI and MRS methods was better in patients without fibrosis in the liver. However, in the present study no differences could be noted in the effect sizes achieved in the meta-analysis (AUROC 0.91 [0.88, 0.94] for detecting steatosis vs 0.90 [0.88, 0.92] for detecting fibrosis; sensitivity 68.96 [68.61, 69.30] steatosis vs 77.24 [77.06, 77.42] fibrosis; and specificity 84.31 [83.93, 84.70] vs 87.19 [87.00, 87.38] fibrosis) (Figs. S4–6, <http://links.lww.com/MD/C226>). The correlation between an MR method of steatosis detection and histological hepatic steatosis may be complicated in patients with advanced liver fibrosis due to the reduced number of hepatocytes volume found in highly fibrotic liver. This leads to an apparent reduction in liver fat. In this scenario, it will be important to consider fibrosis stage while measuring steatosis especially in patients with chronic liver disease. Also, an assessment of liver fibrosis and steatosis concomitantly by MRI may overcome this constraint.^[41]

Earlier identification of patients with NAFLD especially with NASH may improve the prognosis and patient outcomes through intervention or transplantation for decompensated cirrhosis.^[7] Although identification of NASH in NAFLD patients will require liver biopsy, MRI methods to detect advanced fibrosis are increasingly reliable. MR-based techniques can measure liver fat most directly and accurately. Compared to signal fat-fraction, the proton density fat-fraction provides an unconfounded measurement of liver fat. Developing advanced MRI techniques such as those involving proton density fat-fraction also have high potential for accurate detection and quantification of hepatic

steatosis, although, these techniques are subject to further technical refinement and validation.^[42]

5. Conclusion

In this meta-analytical review, MRI and spectroscopic techniques are found to have good diagnostic accuracy with an overall AUROC of 0.90, sensitivity of 82%, and specificity of 87% in diagnosing or grading steatosis and/or fibrosis. All 3 major methods, the MRI, MRE, and MRS exhibited good AUROC (0.95, 0.89, and 0.88, respectively). Moreover, limited data suggested that there was a strong correlation between MR-based diagnosis and histologically measured steatosis, although more correlative data will be required to determine conclusive evidence.

Acknowledgments

The authors thank the support and input from Chinese PLA General Hospital.

Author contributions

Conceptualization and designing of study: Lin Ma.

Data collection, analyses, and interpretation: Xiaomin Wang, Xiaojing Zhang.

Literature search, manuscript writing, and review: Xiaomin Wang.

Conceptualization: Lin Ma.

Data curation: Xiaomin Wang.

Formal analysis: Xiaomin Wang, Lin Ma.

Methodology: Xiaojing Zhang, Lin Ma.

Project administration: Xiaomin Wang.

Resources: Xiaomin Wang.

Software: Lin Ma.

Validation: Xiaojing Zhang.

Writing – original draft: Xiaomin Wang, Xiaojing Zhang.

Writing – review and editing: Xiaojing Zhang.

References

- Anderson EL, Howe LD, Jones HE, et al. The prevalence of non-alcoholic fatty liver disease in children and adolescents: a systematic review and meta-analysis. *PLoS One* 2015;10:e0140908.
- Wieckowska A, Feldstein AE. Diagnosis of nonalcoholic fatty liver disease: invasive versus noninvasive. *Semin Liver Dis* 2008;28:386–95.
- Bugianesi E, Gastaldelli A, Vanni E, et al. Insulin resistance in non-diabetic patients with non-alcoholic fatty liver disease: sites and mechanisms. *Diabetologia* 2005;48:634–42.
- Matteoni CA, Younossi ZM, Gramlich T, et al. Nonalcoholic fatty liver disease: a spectrum of clinical and pathological severity. *Gastroenterology* 1999;116:1413–9.
- Chitturi S, Abeygunasekera S, Farrell GC, et al. NASH and insulin resistance: insulin secretion and specific association with the insulin resistance syndrome. *Hepatology* 2002;35:373–9.
- Adams LA, Lymp JF, St Sauver J, et al. The natural history of nonalcoholic fatty liver disease: a population-based cohort study. *Gastroenterology* 2005;129:113–21.
- Rinella ME. Nonalcoholic fatty liver disease: a systematic review. *JAMA* 2015;313:2263–73.
- Clark JM, Brancati FL, Diehl AM. The prevalence and etiology of elevated aminotransferase levels in the United States. *Am J Gastroenterol* 2003;98:960–7.
- Nomura H, Kashiwagi S, Hayashi J, et al. Prevalence of fatty liver in a general population of Okinawa, Japan. *Jpn J Med* 1988;7:142–9.
- Bellentani S, Saccoccio G, Masutti F, et al. Prevalence of and risk factors for hepatic steatosis in Northern Italy. *Ann Intern Med* 2000;132:112–7.

- [11] Wong VW, Chu WC, Wong GL, et al. Prevalence of non-alcoholic fatty liver disease and advanced fibrosis in Hong Kong Chinese: a population study using proton-magnetic resonance spectroscopy and transient elastography. *Gut* 2012;61:409–15.
- [12] Taouli B, Serfaty L. Magnetic resonance imaging/elastography is superior to transient elastography for detection of liver fibrosis and fat in nonalcoholic fatty liver disease. *Gastroenterology* 2016;150:553–6.
- [13] Bastati N, Feier D, Wibmer A, et al. Noninvasive differentiation of simple steatosis and steatohepatitis by using gadoxetic acid-enhanced MR imaging in patients with nonalcoholic fatty liver disease: a proof-of-concept study. *Radiology* 2014;271:739–47.
- [14] Chen J, Talwalkar JA, Yin M, et al. Early detection of nonalcoholic steatohepatitis in patients with nonalcoholic fatty liver disease by using MR elastography. *Radiology* 2011;259:749–56.
- [15] Chen J, Yin M, Talwalkar JA, et al. Assessment of diagnostic performance of MR elastography (MRE) and vibration-controlled transient elastography (VCTE) for detecting hepatic fibrosis in patients with severe to morbid obesity. *Radiology* 2017;283:418–28.
- [16] Cui J, Ang B, Haufe W, et al. Comparative diagnostic accuracy of magnetic resonance elastography vs. eight clinical prediction rules for non-invasive diagnosis of advanced fibrosis in biopsy-proven non-alcoholic fatty liver disease: a prospective study. *Aliment Pharmacol Ther* 2015;41:1271–80.
- [17] Cui J, Heba E, Hernandez C, et al. Magnetic resonance elastography is superior to acoustic radiation force impulse for the diagnosis of fibrosis in patients with biopsy-proven nonalcoholic fatty liver disease: a prospective study. *Hepatology* 2016;63:453–61.
- [18] d'Assignies G, Ruel M, Khiat A, et al. Noninvasive quantitation of human liver steatosis using magnetic resonance and bioassay methods. *Eur Radiol* 2009;19:2033–40.
- [19] Hatta T, Fujinaga Y, Kadoya M, et al. Accurate and simple method for quantification of hepatic fat content using magnetic resonance imaging: a prospective study in biopsy-proven nonalcoholic fatty liver disease. *J Gastroenterol* 2010;45:1263–71.
- [20] Idilman IS, Keskin O, Celik A, et al. A comparison of liver fat content as determined by magnetic resonance imaging-proton density fat fraction and MRS versus liver histology in non-alcoholic fatty liver disease. *Acta Radiol* 2016;57:271–8.
- [21] Imajo K, Kessoku T, Honda Y, et al. magnetic resonance imaging more accurately classifies steatosis and fibrosis in patients with nonalcoholic fatty liver disease than transient elastography. *Gastroenterology* 2016;150:626–37.
- [22] Karlas T, Petroff D, Garnov N, et al. Non-invasive assessment of hepatic steatosis in patients with NAFLD using controlled attenuation parameter and 1H-MR spectroscopy. *PLoS One* 2014;9:e91987.
- [23] Kim D, Kim WR, Talwalkar JA, et al. Advanced fibrosis in nonalcoholic fatty liver disease: noninvasive assessment with MR elastography. *Radiology* 2013;268:411–9.
- [24] Loomba R, Wolfson T, Ang B, et al. Magnetic resonance elastography predicts advanced fibrosis in patients with nonalcoholic fatty liver disease: a prospective study. *Hepatology* 2014;60:1920–8.
- [25] Loomba R, Cui J, Wolfson T, et al. Novel 3D magnetic resonance elastography for the noninvasive diagnosis of advanced fibrosis in NAFLD: a prospective study. *Am J Gastroenterol* 2016;111:986–94.
- [26] Middleton MS, Heba ER, Hooker CA, et al. NASH Clinical Research Network. Agreement between magnetic resonance imaging proton density fat fraction measurements and pathologist-assigned steatosis grades of liver biopsies from adults with nonalcoholic steatohepatitis. *Gastroenterology* 2017;153:753–61.
- [27] Pacifico L, Celestre M, Anania C, et al. MRI and ultrasound for hepatic fat quantification: relationships to clinical and metabolic characteristics of pediatric nonalcoholic fatty liver disease. *Acta Paediatr* 2007;96:542–7.
- [28] Pacifico L, Martino MD, Catalano C, et al. T1-weighted dual-echo MRI for fat quantification in pediatric nonalcoholic fatty liver disease. *World J Gastroenterol* 2011;17:3012–9.
- [29] Park CC, Nguyen P, Hernandez C, et al. Magnetic resonance elastography vs transient elastography in detection of fibrosis and noninvasive measurement of steatosis in patients with biopsy-proven nonalcoholic fatty liver disease. *Gastroenterology* 2017;152:598–607.
- [30] Permutt Z, Le TA, Peterson MR, et al. Correlation between liver histology and novel magnetic resonance imaging in adult patients with non-alcoholic fatty liver disease – MRI accurately quantifies hepatic steatosis in NAFLD. *Aliment Pharmacol Ther* 2012;36:22–9.
- [31] Schwimmer JB, Middleton MS, Behling C, et al. Magnetic resonance imaging and liver histology as biomarkers of hepatic steatosis in children with nonalcoholic fatty liver disease. *Hepatology* 2015;61:1887–95.
- [32] Smits LP, Coolen BF, Panno MD, et al. Noninvasive differentiation between hepatic steatosis and steatohepatitis with MR imaging enhanced with USPIOs in patients with nonalcoholic fatty liver disease: a proof-of-concept study. *Radiology* 2016;278:782–91.
- [33] Tang A, Desai A, Hamilton G, et al. Accuracy of MR imaging-estimated proton density fat fraction for classification of dichotomized histologic steatosis grades in nonalcoholic fatty liver disease. *Radiology* 2015;274:416–25.
- [34] Myers RP. Noninvasive diagnosis of nonalcoholic fatty liver disease. *Ann Hepatol* 2009;8:S25–33.
- [35] Loria P, Adinolfi LE, Bellentani S, et al. NAFLD Expert Committee of the Associazione Italiana per lo studio del Fegato. Practice guidelines for the diagnosis and management of nonalcoholic fatty liver disease. A decalogue from the Italian Association for the Study of the Liver (AISF) Expert Committee. *Dig Liver Dis* 2010;42:272–82.
- [36] Cassidy FH, Yokoo T, Aganovic L, et al. Fatty liver disease: MR imaging techniques for the detection and quantification of liver steatosis. *Radiographics* 2009;29:231–60.
- [37] Fabbrini E, Conte C, Magkos F. Methods for assessing intrahepatic fat content and steatosis. *Curr Opin Clin Nutr Metab Care* 2009;12:474–81.
- [38] Razek AA, Khashaba M, Abdalla A, et al. Apparent diffusion coefficient value of hepatic fibrosis and inflammation in children with chronic hepatitis. *Radiol Med* 2014;119:903–9.
- [39] Radetti G, Kleon W, Stuefer J, et al. Non-alcoholic fatty liver disease in obese children evaluated by magnetic resonance imaging. *Acta Paediatr* 2006;95:833–7.
- [40] McPherson S, Jonsson JR, Cowin GJ, et al. Magnetic resonance imaging and spectroscopy accurately estimate the severity of steatosis provided the stage of fibrosis is considered. *J Hepatol* 2009;51:389–97.
- [41] Hardy T, McPherson S. Imaging-based assessment of steatosis, inflammation and fibrosis in NAFLD. *Curr Hepatology Rep* 2017;16:298–307.
- [42] Reeder SB, Cruite I, Hamilton G, et al. Quantitative assessment of liver fat with magnetic resonance imaging and spectroscopy. *J Magn Reson Imaging* 2011;34:729–49.