



Fibroelastomas of the left ventricular outflow tract

Sujatha Kesavan • Lovesh Dyal • Martin Nelson •
Mandie Townsend • Franco Ciulli • Gianni Angelini

Bristol Heart Institute, Bristol, UK

Correspondence to: Sujatha Kesavan. E-mail: sujatha.kesavan@uhbristol.nhs.uk

DECLARATIONS

Competing interests

None declared

Funding

None

Ethical approval

Written informed consent to publication has been obtained from the patient or next of kin

Guarantor

MT

Contributorship

All authors contributed equally

Acknowledgements

None

Reviewer

Ganesh Shivu

Fibroelastomas of the left ventricular outflow tract are extremely rare, benign, primary cardiac tumours.

Introduction

Primary cardiac tumours are uncommon and most of them are benign myxomas. Only one-tenth of the tumours are fibroelastomas of the cardiac valves. We report two cases with a longstanding history of valvular heart disease where a diagnosis of fibroelastoma of the left ventricular outflow tract was confirmed by histology.

Case 1

A 70-year-old woman with a longstanding history of a heart murmur, presented with severe shortness of breath and ankle swelling. Her past medical history includes a left mastectomy for breast cancer and Parkinson's disease.

A systolic, a diastolic murmur and bi-basal pulmonary crackles were heard on auscultation. ECG revealed an incomplete right bundle branch block with ST depression in leads V₂ to V₆. A chest X-ray revealed bilateral pleural effusions. Cardiac troponin was negative and CRP was normal.

A transthoracic echocardiogram (Figure 1) revealed a mobile mass measuring 19 × 5 mm, in the left ventricular outflow tract. An initial diagnosis of a subacute infective endocarditis or a mural thrombus was made, however the patient remained afebrile with a normal white cell count and a CRP <10. Repeated blood cultures were also negative. Trans-oesophageal echocardiogram (Figure 2) confirmed the above findings

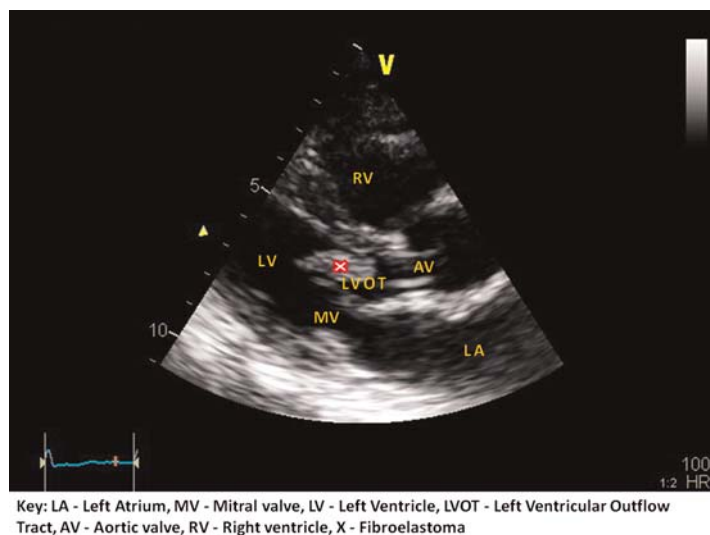
along with a structurally abnormal tricuspid valve. The pulmonary valve was structurally and functionally normal. The mobile left ventricular outflow tract mass was found extending down to the level of the papillary muscles at mid-cavity level. Coronary angiogram revealed 60% stenosis of the right coronary artery at the ostium with diffuse plaque disease in the left main stem and anterior descending arteries.

Surgery was planned for aortic valve repair/replacement, tricuspid valve repair, coronary artery bypass graft to the right coronary artery and removal of left ventricular outflow tract mass. At surgery, the left ventricular outflow tract mass was described as myxoid and attached to the septum. The mass was resected in the subendocardial plane and sent for histology. Thoracoscope inspection of the left ventricular cavity did not reveal any residual mass. A 19 mm St Jude Epic bioprosthetic valve was inserted in the aortic position, a 30 mm annuloplasty ring was used to repair the tricuspid valve and a saphenous vein graft to the right coronary artery was performed.

Macroscopically, the irregular fragment measured 17 × 5 × 3 mm with a soft fibular tissue. Microscopically multiple papillary fragments of fibrous tissue focally lined by endothelial cells were observed, with a centralized hyalinized core, typical of a papillary fibroelastoma (Figure 3).

Transthoracic echocardiogram performed on the first postoperative day showed good left ventricular function, normal aortic and tricuspid valve mobility and function. A central jet of mitral regurgitation was observed and the left atrium was non-dilated. The postoperative period was complicated by anaemia, pleural effusions and heart failure. She was eventually discharged home after a prolonged hospital stay.

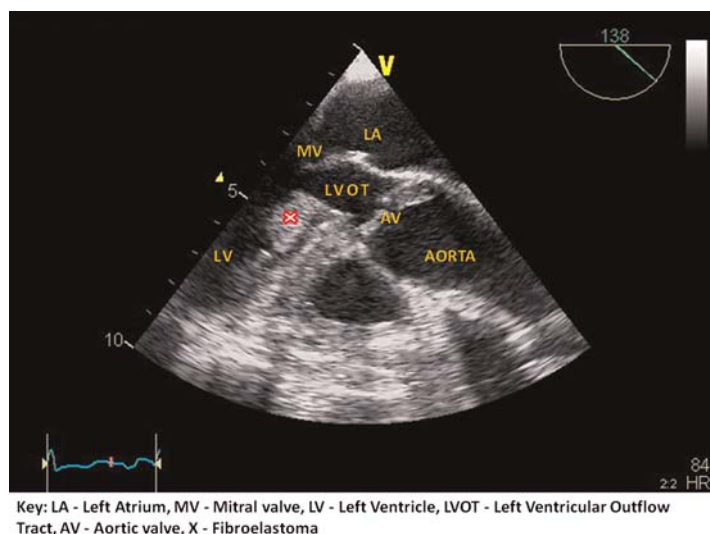
Figure 1
2D echocardiogram demonstrating a mass (fibroelastoma) of the left ventricular outflow tract



Case 2

A 43-year-old woman with a diagnosis of bicuspid aortic valve with mixed aortic valve disease was hospitalized for worsening exercise tolerance.

Figure 2
Transoesophageal echocardiogram demonstrating a mass (fibroelastoma) of the left ventricular outflow tract



Routine transthoracic echocardiogram showed mild left ventricular hypertrophy (no dilation) and an aortic peak pressure drop of 57 mmHg (mean of 27 mmHg) with moderate aortic regurgitation. A subaortic membrane like structure was also noticed for the first time. Mild mitral regurgitation and moderate pulmonary hypertension were found.

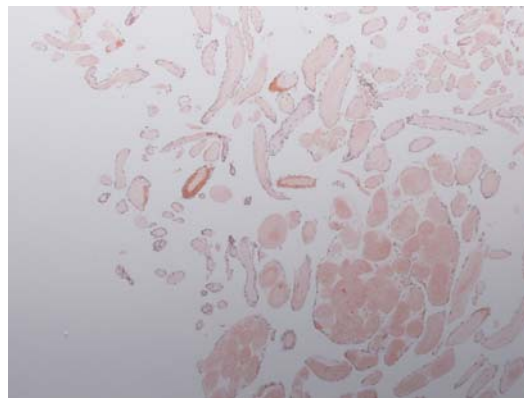
Cardiac MRI revealed an additional finding – a subaortic opacity/membrane in the left ventricular outflow tract. The aortic valve was bicuspid with central incompetence. She underwent aortic and mitral valve replacement, with the removal of the left ventricular outflow tract mass. At surgery, a large fibrous membrane extending from the septum below the aortic valve down to (almost reaching) the apex and back towards the anterior leaflet of the mitral valve was found. The surgeon noted that the 'membrane' did not look like a classic subaortic membrane but felt like a subaortic mass.

The subaortic mass was subsequently removed. After cardiopulmonary bypass was discontinued, torrential mitral regurgitation was observed as the anterior leaflet was not co-apting in the centre. It was therefore decided to re-establish cardiopulmonary bypass, open the left atrium and inspect the mitral valve. The anterior leaflet of the valve was retracted and a split between P1 and P2 was seen (possibly due to removal of the fibrous membrane). After attempts at repairing the valve, a mitral valve replacement was performed and the aortic valve was also replaced. A 19 mm and a 25 mm Sorin mechanical valve were replaced in the aortic and mitral position.

The fibroelastoma measured $4.0 \times 2.5 \times 0.2$ cm with focal thickening and surface papillary changes. Microscopic analysis showed fibrovascular tissue with a minimal amount of cardiac muscle. Multiple papillae comprising hyalinized stroma covered by benign endothelium were noted. These features were deemed characteristic of papillary fibroelastoma.

Postoperative transthoracic echocardiogram showed competent aortic and mitral, mechanical valve prostheses with no regurgitation or para-valvular leaks. The postoperative period was complicated by a left lower lobe consolidation of lung which was treated with Vancomycin and Tazocin. The patient recovered well and was discharged home.

Figure 3
Haematoxylin-eosin staining shows multiple fragments of fibrous tissue with a hyalinized collagenous matrix typical of a fibroelastoma



Discussion

Primary cardiac tumours are rare with an autopsy incidence ranging from 0.001–0.30%.^{1,2} Fibroelastomas are benign cardiac tumours arising characteristically from the cardiac valves or an adjacent endocardium. These tumours are described as resembling sea anemones with frondlike projections. The atrioventricular and semilunar valves^{4–6} are affected with an equal frequency. They have been considered as neoplasms, hamartomas, organized thrombi and unusual endocardial responses to infection or haemodynamic trauma.^{7,8} They are capable of producing obstruction to the blood flow, particularly coronary ostial flow, may embolize to the brain and produce stroke.³

The location, occurrence and the growth of the tumour can be related to the haemodynamic trauma experienced by the adjacent valve or the endocardium, due to co-existent, longstanding valvular heart disease. Small tumours may

remain asymptomatic and larger tumours result in haemodynamic compromise as noted in our two cases. Clinical features may mimic the features of infective endocarditis. A definitive diagnosis is made by cardiac imaging and histological analysis.

Surgical resection of the tumours is the only definitive treatment. In our two cases, the surgeons experienced intraoperative difficulty due to the extent and attachment of the tumour to intracardiac structures.

During routine review of patients with valvular heart disease, a change in the clinical condition should alert the clinician to consider co-existent pathology like papillary fibroelastoma. They are usually asymptomatic until a critical event occurs but now are found more often because of the increased frequent use of echocardiography and advances in cardiac imaging.

References

- 1 Walkes J, Ci M, Smythe W, Reardon M. Cardiac neoplasms. In: Cohn L, ed. *Cardiac Surgery in the Adult*. New York, NY: McGraw-Hill, 2008:1479–510
- 2 Sampurna R. Papillary Fibroelastoma Histology. *Histopathology India* 2009. See <http://www.histopathology-india.net/papfib.htm>
- 3 Cohn L. *Cardiac Surgery in the Adult*. New York, NY: McGraw-Hill Medical, 2008
- 4 Khaira T, Mazidib P, Laosb LF. Cardiac papillary fibroelastoma: case report and review of the literature. *Int J Cardiol* 2008;**139**:102–4
- 5 Al-Mohammad A, Pambakian H, Young C. Fibroelastoma: case report and review of the literature. *BMJ Heart* 1998;**79**:301–4
- 6 Butany J, Nair V, Naseemuddin A, Nair GM, Catton C, Yau T. Cardiac tumours: diagnosis and management. *Lancet Oncology* 2005;**6**:219
- 7 Bicer M, Cikirkcioglu M, Pektok E, Muller H, Dettwiler S, Kalangos A. Papillary fibroelastoma of the left atrial wall: a case report. *J Cardiothoracic Surg* 2009;**4**:28
- 8 Sastre-Garriga J, Molina C, Montaner J, et al. Mitral papillary fibroelastoma as a cause of cardiogenic embolic stroke: report of two cases and review of the literature. *Eur J Neurology* 2000;**7**:449