


Contents lists available at [ScienceDirect](https://www.elsevier.com/locate/aott)

## Acta Orthopaedica et Traumatologica Turcica

journal homepage: <https://www.elsevier.com/locate/aott>

## Effectiveness of posterior structures in the development of proximal junctional kyphosis following posterior instrumentation: A biomechanical study in a sheep spine model

Murat Korkmaz <sup>a,\*</sup>, Turgut Akgul <sup>b</sup>, Kerim Sariyilmaz <sup>c</sup>, Okan Ozkunt <sup>d</sup>, Fatih Dikici <sup>c</sup>, Onder Yazicioglu <sup>b</sup>

<sup>a</sup> Koc University Hospital, Department of Orthopedics and Traumatology, Istanbul, Turkey

<sup>b</sup> Istanbul University, Istanbul Faculty of Medicine, Department of Orthopedics and Traumatology, Istanbul, Turkey

<sup>c</sup> Acibadem Atakent University Hospital, Department of Orthopedics and Traumatology, Istanbul, Turkey

<sup>d</sup> Istinye University Hospital, Department of Orthopedics and Traumatology, Istanbul, Turkey

## ARTICLE INFO

## Article history:

Received 5 November 2018

Received in revised form

4 January 2019

Accepted 11 January 2019

Available online 30 January 2019

## Keywords:

Proximal junctional kyphosis

Junctional disorders

Biomechanics

PJK

Adolescent idiopathic scoliosis

Scheuermann kyphosis

## ABSTRACT

**Introduction:** Proximal junctional kyphosis – PJK has been defined by a 10 or greater increase in kyphosis at the proximal junction as measured by the Cobb angle from the caudal endplate of the uppermost instrumented vertebrae (UIV) to the cephalad endplate of the vertebrae 1 segment cranial to the UIV. In this biomechanical study, it is aimed to evaluate effects of interspinous ligament complex disruption and facet joint degeneration on PJK development.

**Materials and methods:** Posterior instrumentation applied between T2 – T7 vertebrae using pedicle screws to randomly selected 21 sheeps, divided into 3 groups. First group selected as control group (CG), of which posterior soft tissue and facet joints are protected. In second group (spinosus group, SG) interspinous ligament complex which 1 segment cranial to UIV has been transected, and third group (facet group-FG) was applied facet joint excision. 25 N, 50 N, 100 N, 150 N and 200 N forces applied at frequency of 5 Hertz as 100 cycles axial to the samples. Then, 250 N, 275 N and 300 N forces applied static axially. Interspinous distance, kyphosis angle and disc heights was measured in radiological evaluation. Abnormal PJK was defined by a proximal junctional angle greater than 10° and at least 10° greater than the corresponding preoperative measurement.

**Results:** In CG group, average interspinous distance was 6,6 ± 1.54 mm and kyphosis angle was 2,2 ± 0.46° before biomechanical testing, and they were measured as 9,4 ± 1.21 mm and 3,3 ± 0.44° respectively after forces applied to samples. In SG group, average interspinous distance was 6,2 ± 1.72 mm and kyphosis angle was 2,7 ± 1.01° before experiment, and they were measured as 20,8 ± 5.66 mm and 15,1 ± 2.34° respectively after forces applied to samples. In FG group, average interspinous distance was 4,8 ± 1.15 mm and kyphosis angle was -1 ± 4.14° before experiment, and they were measured as 11,1 ± 1.96 mm and 11 ± 2.87° respectively after forces applied to samples. In comparison to group CG, statistically significant junctional kyphosis was seen on both FG and SG group after statistical analysis. (p < 0.05). PJK was seen statistically significant more on SG group than FG group. (p < 0.05). Not any statistically significant difference was seen on measurement of disk distances among three groups. (p > 0.05)

**Conclusions:** Protecting interspinous ligament complex and facet joint unity during posterior surgical treatment for spine deformation is vital to prevent PJK development. Based on our literature review, this is the first biomechanical study that reveals interspinous ligament complex are more effective on preventing PJK development than facet joints.

© 2019 Turkish Association of Orthopaedics and Traumatology. Publishing services by Elsevier B.V. This is an open access article under the CC BY-NC-ND license (<http://creativecommons.org/licenses/by-nc-nd/4.0/>).

\* Corresponding author. Koc University Hospital, Department of Orthopedics and Traumatology, Davutpaşa Caddesi No:4, 34010, Topkapı, İstanbul, Turkey.

E-mail address: [mrtmkz@gmail.com](mailto:mrtmkz@gmail.com) (M. Korkmaz).

Peer review under responsibility of Turkish Association of Orthopaedics and Traumatology.

## Introduction

With the improvements in surgical techniques and instruments, severe sagittal and coronal deformities of the spine could be successfully corrected. Nonetheless, adjacent segment pathologies secondary to overcorrection and rigid fixation, also known as proximal junctional kyphosis (PJK), has emerged as a frequent surgical problem,<sup>1–3</sup> with a reported incidence of 5,8%–59%.<sup>4–6</sup> Although the literature is conflicting regarding the definition of PJK, the most commonly accepted definition is an angling of more than 10° between the instrumented level and the next vertebra.<sup>7,8</sup>

PJK results from the stress secondary to rigid instrumentation that is placed in the flexible transition zone of the spine. Although many risk factors have been attributed to PJK development, rigid posterior instrumentation, excessive soft tissue damage, overcorrection in the sagittal plane, and advanced age are the most commonly identified etiologies.<sup>5,9,10</sup> Furthermore, the facet joint injury and damage to paravertebral muscles and ligaments in the transition zone are among the most commonly cited causes of PJK.<sup>11,12</sup> Although several biomechanical and cadaveric studies<sup>13,14</sup> investigating the impacts of soft tissue injury on PJK development are available in the literature, to the best of our knowledge, studies have not yet been conducted to compare the facet joint integrity with posterior ligament protection in terms of their roles in PJK development to date.

The present study aimed to biomechanically evaluate the integrity of supraspinous and interspinous ligaments and facet joints on PJK development in a sheep spine.

## Materials and methods

The current study was carried out on 21 skeletally mature sheep spines (over 6 years of age) which included the vertebrae from C7 to T8, intervertebral discs, posterior elements, end-plates and all posterior ligaments. The fresh frozen spine models were kept at –20° Celsius throughout the whole study. Before performing the biomechanical testing, each spine was thawed with physiologic serum at room temperature. In the preparation of specimens, initially, the supraspinous and interspinous ligaments and facet joints were identified and preserved. The costovertebral joints were protected at all levels, and the distal joint of the ribs was excised at a distance of 2 cm. A total of 10 titanium pedicle screws (5 cm\* 25 mm) were inserted using an image intensifier at the 5 vertebral levels between the T2 and T7 vertebrae. After that, posterior instrumentation was completed using two 6 × 460 mm titanium rods which countered as nearly physiologically kyphotic in an attempt to mimic the physiological thoracic kyphosis of 25°. Finally, all models were confirmed radiologically (Fig. 1). After above initial preparations, all the sheep spines were divided into 3 groups of 7 spines each: control group (CG), ligament group (LG), and facet group (FG).

The control group included spines in which the facet joint and inter- and supraspinous structures were protected. The ligament group involved spines in which the facet joint was protected but the inter- and supraspinous structures were completely resected. Finally, the facet group was composed of spines in which the facet joint alone was resected at one level proximal to the upper instrumented vertebra.

## Biomechanical experiment

For the biomechanical experiment, the spine specimens were subjected to axial loading with a MTS acumen electrodynamic biomechanical test device. The specimens were then fixed

proximally and distally with K wires and 15 gram polyester putty (steel putty) mixed with a catalyzer (Dibenzoil peroxide), in order to obtain biomechanical loading in an erect position similar to that observed in humans. After confirming the stiffness of the spine models, 100 cycles of forces of 25 N, 50 N, 100 N, 150 N and 200 N at a frequency of 5 Hertz were, respectively, performed axially. Following the cyclical loading, 250 N, 275 N and 300 N forces were, respectively, performed statically in the axial direction (Fig. 2).

After the biomechanical testing, direct radiography and computerized tomography of the spine models were obtained, and all were radiologically analyzed and compared before and after the biomechanical experiment by an orthopedic surgeon who specialized in the spinal column and a radiologist who specialized in the musculoskeletal system.

The evaluation criteria included:

- 1) the distance between the spinous processes of the upper instrumented and adjacent vertebrae before and after axial loading,
- 2) the kyphosis angle,
- 3) the anterior and posterior disc height (Fig. 3).

All statistical analyses were performed using the SPSS 18.0.0 statistical package (SPSS, Inc., Chicago, IL, USA), and p value of less than 0.05 was accepted as significant. The Kolmogorov–Smirnov and Shapiro–Wilk tests were used to evaluate the normality of the data distribution. Differences between groups were tested for significance using the Kruskal–Wallis test, and paired groups were evaluated using the Mann–Whitney U test.

## Results

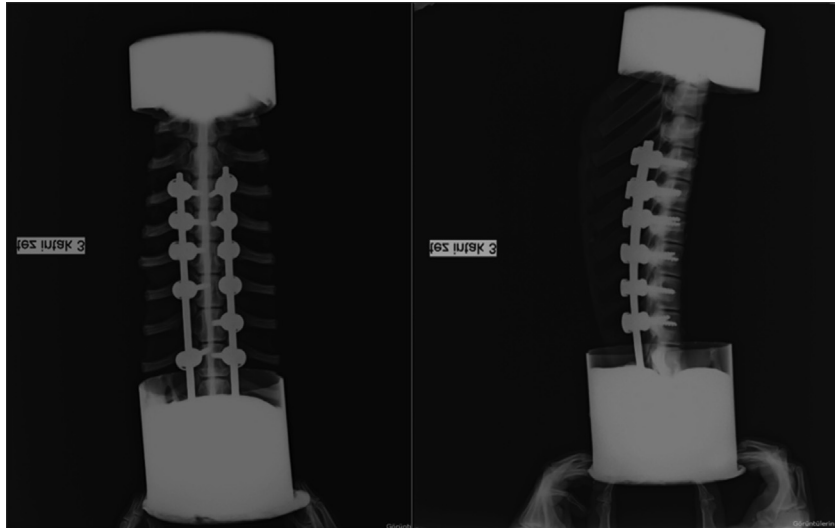
The interspinous distance that was measured radiologically from elevated from 6,6+/-1,55 mm before the biomechanical loading to 9,4+/-12,1 mm after the biomechanical loading in the CG ( $p > 0,05$ ), from 6,2+/-1,7 mm to 20,8+/-5,7 mm in the LG ( $p < 0,05$ ), and 4,8+/-1,1 mm to 11,1+/-2 mm in the FG ( $p < 0,05$ ). The statistical analyses showed that the interspinous distance increased significantly following biomechanical loading in the LG and FG compared with the CG ( $p < 0,05$ ). Furthermore, the increase in the interspinous distance was greater for the LG when compared to the FG (Table 1).

The interspinous distance that was measured manually raised from 7,5+/-0,5 mm before the biomechanical loading to 11,5+/-0,5 mm after the loading in the CG ( $p > 0,05$ ), from 7,5+/-0,5 mm to 20,2+/-6,5 mm in the LG ( $p < 0,05$ ), and 5,6+/-1,1 mm to 17,3+/-1,4 mm in the FG ( $p < 0,05$ ). These increases were statistically greater in the LG compared to the FG ( $p < 0,05$ ).

The local kyphosis angle raised from 2,5+/-0,2 before the axial loading to 3,3+/-0,44 after the loading in the CG, from 2,7+/-1,1 to 15,1+/-2,3 in the LG, and -0,9+/-4,1 to 11+/-2,9 in the FG ( $p < 0,05$ ). The statistical analyses revealed that the increases in local junctional kyphosis angle in the LG and FG were significantly greater compared with the CG ( $p < 0,05$ ). Also, the increase in the LG was greater than in the FG ( $p < 0,05$ ).

In cycle 28 of 200 N loading, insufficiency developed in the proximal junction of one of the samples from the ligament group and resulted in dislocation.

The anterior disk height dropped from 4,19+/-0,27 mm before the biomechanical testing to 3+/-0,5 mm after the biomechanical testing ( $p < 0,0001$ ), although the posterior disk height increased from 3,15+/-0,5 mm to 4,25+/-0,6 mm ( $p < 0,0001$ ). In terms of disk height, no statistically significant difference was observed among three groups ( $p > 0,05$ ).



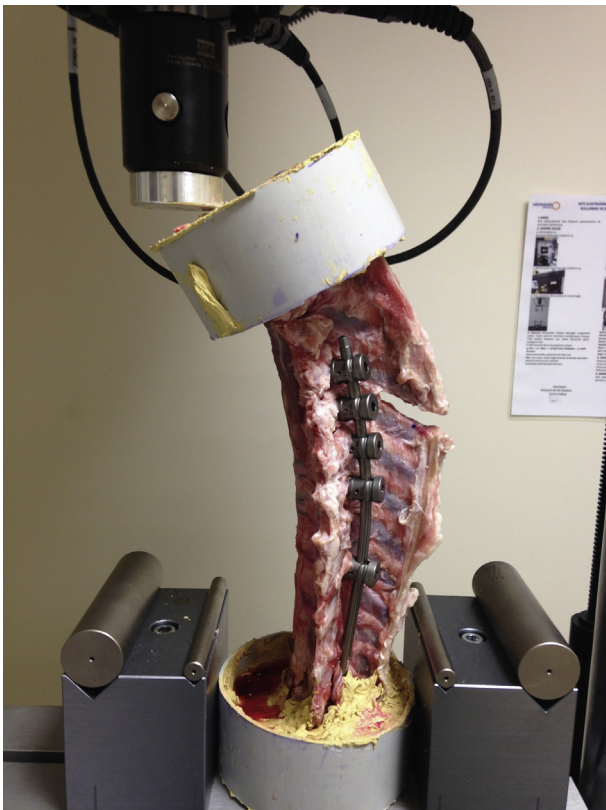
**Fig. 1.** All spines were instrumented with pedicle screws at the 5 vertebral levels between the T2 and T7 vertebrae. Anterior-posterior and lateral radiography view of the spine.

## Discussion

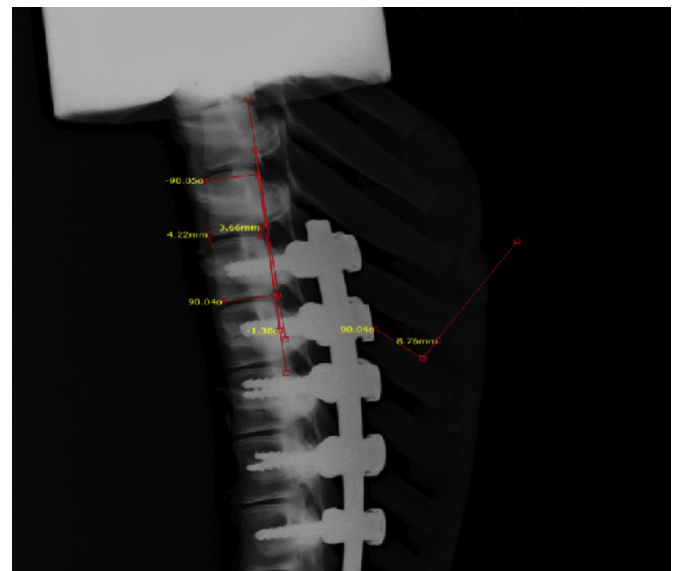
Although posterior instrumentation and fusion procedure has been widely recognized as the choice of treatment method for the correction of spinal deformities with favorable outcomes, the development of proximal junctional kyphosis has emerged as a serious problem in the orthopedic practice.<sup>15</sup> According to the several studies many potential factors were described such as long

rigid instrumentations, dissection of the paravertebral muscles, in the vertebrae adjacent to the instrumented vertebra secondary to rigid systems. Despite these several reports describe the potential risk factors of PJK, there is no consensus yet. In our biomechanical study the effect of posterior ligament complex and facet joint integrity were examined.

Many researchers viewed the risk factors of PJK. Lee reported that a kyphosis of 5° or more at one level proximal to the upper instrumented vertebra prior to surgery could lead to the development of postoperative junctional kyphosis.<sup>16</sup> Lowe and Kasten thought that the prevalence of PJK to be as high as 50% of patients who underwent spinal deformity correction.<sup>17,18</sup> In a finite element study Cammarata et al concluded that the development of deformity might be related to sagittal balance, the implant type used in the proximal vertebra, and posterior soft tissue damage or the loss of joint unity.<sup>19</sup>



**Fig. 2.** Instrumented spines were fixed proximally and distally with K wires and polyester putty (steel putty) and axially loaded with MTS acumen electrodynamic biomechanical test device.



**Fig. 3.** All groups were radiologically evaluated included the distance between the spinous processes of the upper instrumented and adjacent vertebrae before and after axial loading, the kyphosis angle, and the anterior and posterior disk height.

**Table 1**  
Statistically significantly junctional kyphosis development was detected on both FG and SG group than control group ( $p < 0.05$ ). PJK was seen significantly more frequently on SG group than FG group ( $p < 0.05$ ).

	Interspinous distance (mm)		Local kyphosis angle (degree)		Discus height (mm)			
	Before	After	Before	After	Anterior discus height -Before	Anterior discus height -After	Posterior discus height -Before	Posterior discus height -After
Control group (CG)	6,6	9,4	2,2	3,3	4,2	3,3	3,3	3,9
Spinous group (SG)	6,2	20,8	2,7	15,1	4,1	3,3	2,8	4,7
Facet group (FG)	4,8	11,1	1,0	11,0	4,2	2,7	2,9	4,1

Posterior ligamentous complex consist of ligamentum flavum, facet joints and interspinous and supraspinous ligaments. Integrity of these strong structure plays a major role to prevent PJK. During posterior instrumentation and fusion surgery, PJK can develop as a secondary trauma to the posterior ligamentous complex.<sup>14</sup> Also, in a biomechanical study which effects of posterior elements were evaluated on human cadavers, effects of posterior elements on stability were evaluated. When posterior soft tissue and ligaments were fully excised, a 44.72% loss in stability was recorded.<sup>13</sup> In these respect, we resected the facet joints and inter- and supraspinous ligaments at one level proximal to the upper instrumented vertebra in two groups. To detect the effects of facet joints and inter- and supraspinous ligaments on PJK, these groups were compared separately and compared with the control group. To the best of our knowledge, only few studies have been designed to investigate the role of facet joint and posterior soft tissue in the development of PJK.

Anatomically cervico-thoracic spine allows a transition zone because of flexible and lordotic cervical spine and rigid and kyphotic thoracic spine. As we know that PJK results from enhanced stress concentration after posterior spinal surgery because of transition zone at the junction. Also increasing of stiffness after long instrumentation enhances the risk of PJK at proximal of the instrumentation. However at the cervico-thoracic junction pedicles smaller and locate more medially and inter- and supraspinous ligaments weaker than lumbar spine. Because of this anatomic features the risk of disruption of the posterior ligamentous complex more than lower spinal regions. In addition, since an increased risk of PJK due to the use of implant combinations with pedicle screws has been reported, we examined implantation using a pedicle screw rod combination and thoracic stabilization.

In a finite element study which set out to determine the risk factors of PJK, Cammarata et al concluded that the development of deformity might be related to sagittal balance, the implant type used in the proximal vertebra, and posterior soft tissue damage or the loss of joint unity. Their findings also supported the fact that if the level of upper instrumented vertebra was between T1 and T3, there was an increased risk for PJK development.<sup>19</sup> Therefore, we evaluated the possibility of junctional kyphosis development between T1 and T2 by performing long segment pedicle screw instrumentation in our spine model.

After the biomechanical testing interspinous distance, kyphosis angle and discus heights was measured in radiological evaluation. Our data showed that interspinous distance increased from 5,9+/-1,6 mm to 13,8+/-6,2 mm and the kyphosis angle increased from 1,43+/-2,9 to 9,8+/-5,4 ( $p < 0,0001$ ) from before to after biomechanical loading. Statistically, these changes were higher in the ligament group than in all other groups, and they were higher in the facet group than in the control group ( $p < 0,05$ ). While our study suggests that facet joint and ligament injury can both lead to PJK development, the supraspinous and interspinous ligaments are the main structures that prevent PJK development, while the facet joint plays an auxiliary role.

Clinical studies have pinpointed many factors that influence PJK development. In our study, although the control group was more stable than the ligament or facet groups, it still experienced statistically significant kyphosis changes with loading. A trend toward kyphosis development was observed in the control group in terms of changes in interspinous distance (6,6+/-1,55 mm to 9,4+/-12,1 mm), kyphosis angle (2,5+/-0,2 to 3,3+/-0,44) and disk height (anterior disk height from 4,2+/-0,2 mm to 3,3+/-0,65 mm) ( $p < 0,05$ ). This may be interpreted as a result of biomechanical loading or surgery alone in the biomechanical evaluation of cadavers that do not have the ability to rejuvenate. However, injury of supraspinous and interspinous ligaments significantly increased the likelihood kyphosis changes.

In our study, similar to previous studies in the literature, we found that the posterior structures of the facet joint and interspinous and supraspinous ligaments contributed significantly to stability. Based on our literature review, this is the first biomechanical study that reveals interspinous ligament complex are more effective on preventing PJK development than facet joints.

Finally, limitation of the study was due to the nature of the animal model chosen. Experimental biomechanical studies can be conducted on cadavers or animal models. Also, animal models can have anatomical and biomechanical differences from human spine. Human cadaver bones represent a better in vivo environment than animal models and provide an erect spine which has advantageous as biomechanical features. Also, it's difficult to obtain and expensive. As sheep and human spines are similar, particularly in the thoracic and lumbar regions, sheep spine models may be used in place of human spine models.<sup>20,21</sup>

## Conclusion

Rigid and long segment posterior instrumentation and fusion surgery can be considered to be a risk factor for PJK development. The protection of the inter- and supraspinous ligaments can provide solid stability. Furthermore, the integrity of facet joints can contribute an additional stability. Therefore, protection of the interspinous and supraspinous ligaments as well as facet joints is important in preventing PJK.

## References

- Cotrel Y, Dubouset J, Guillaumat M. New universal instrumentation in spinal surgery. *Clin Orthop Relat Res.* 1988;(227):10–23.
- Edmonston SJ, Singer KP, Day RE, Bredahl PD, Price RL. Formalin fixation effects on vertebral bone density and failure mechanics: an study of human and sheep vertebrae. *Clin Biomech.* 1994 May;9(3):175–179.
- Eggli S, Schläpfer F, Angst M, Witschger P, Aebi M. Biomechanical testing of three newly developed transpedicular multisegmental fixation systems. *Eur Spine J.* 1992 Sep;1(2):109–116.
- Hostin R, McCarthy I, O'Brien M, et al. Incidence, mode, and location of acute proximal junctional failures following surgical treatment for adult spinal deformity. *Spine (Phila Pa 1976).* 2013 May 20;38(12):1008–1015.
- Yagi M, Akilah KB, Boachie-Adjei O. Incidence, risk factors and classification of proximal junctional kyphosis: surgical outcomes review of adult idiopathic scoliosis. *Spine (Phila Pa 1976).* 2011;36(1):E60–E68.



6. Kim YJ, Bridwell KH, Lenke LG, Glattes CR, Rhim S, Cheh G. Proximal junctional kyphosis in adult spinal deformity after segmental posterior spinal instrumentation and fusion: minimum five-year follow-up. *Spine (Phila Pa 1976)*. 2008;33(20):2179–2184.
7. Helgeson MD, Shah SA, Newton PO, et al. Evaluation of proximal junctional kyphosis in adolescent idiopathic scoliosis following pedicle screw, hook, or hybrid instrumentation. *Spine (Phila Pa 1976)*. 2010;35(2):177–181.
8. Sucato DJ, Kassab F, Dempsey M. Analysis of screw placement relative to the aorta and spinal canal following anterior instrumentation for thoracic idiopathic scoliosis. *Spine (Phila Pa 1976)*. 2004;29(5):554–559. discussion 559.
9. Glattes RC, Bridwell KH, Lenke LG, Kim YJ, Rinella A, Edwards 2nd C. Proximal junctional kyphosis in adult spinal deformity following long instrumented posterior spinal fusion: incidence, outcomes, and risk factor analysis. *Spine (Phila Pa 1976)*. 2005;30(14):1643–1649.
10. Kim YJ, Bridwell KH, Lenke LG, Kim J, Cho SK. Proximal junctional kyphosis in adolescent idiopathic scoliosis following segmental posterior spinal instrumentation and fusion: minimum 5-year follow-up. *Spine (Phila Pa 1976)*. 2005;30(18):2045–2050.
11. Yang SH, Chen PQ. Proximal kyphosis after short posterior fusion for thoracolumbar scoliosis. *Clin Orthop Relat Res*. 2003;411:152–158.
12. Coe JD, Arlet V, Donaldson W, et al. Complications in spinal fusion for adolescent idiopathic scoliosis in the new millennium. A report of the scoliosis research society morbidity and mortality committee. *Spine (Phila Pa 1976)*. 2006;31(3):345–349.
13. Anderson AL, McIlff TE, Asher MA, Burton DC, Glattes RC. The effect of posterior thoracic spine anatomical structures on motion segment flexion stiffness. *Spine (Phila Pa 1976)*. 2009;34(5):441–446.
14. Kretzer RM, Hu N, Umekoji H, et al. The effect of spinal instrumentation on kinematics at the cervicothoracic junction: emphasis on soft-tissue response in an in vitro human cadaveric model. *J Neurosurg Spine*. 2010;13(4):435–442.
15. Arlet V, Aebi M. Junctional spinal disorders in operated adult spinal deformities: present understanding and future perspectives. *Eur Spine J*. 2013;22(2):S276–S295.
16. Lee GA, Betz RR, Clements 3rd DH, Huss GK. Proximal kyphosis after posterior spinal fusion in patients with idiopathic scoliosis. *Spine (Phila Pa 1976)*. 1999;24(8):795–799.
17. Lowe TG, Kasten MD. An analysis of sagittal curves and balance after Cotrel-Dubouset instrumentation for kyphosis secondary to Scheuermann's disease. A review of 32 patients. *Spine (Phila Pa 1976)*. 1994;19(15):1680–1685.
18. Herkowitz HN, Garfin Steven R, Eismont Frank J, Bell Gordon R, Balderston Richard A. *Rothman simeone the Spine: expert consult*. Elsevier Health Sciences; 2011.
19. Cammarata M, Wang X, Mac-Thiong JM, Ce A. Biomechanical analysis of proximal junctional kyphosis: preliminary results. *Stud Health Technol Inform*. 2012;(176):299–302.
20. Osti OL, Vernon-Roberts B, Fraser RD. 1990 Volvo Award in experimental studies. Anulus tears and intervertebral disc degeneration. An experimental study using an animal model. *Spine (Phila Pa 1976)*. 1990;15(8):762–767.
21. Hans-Joachim Wilke AK, Kettler Annette, Howard Wenger Karl, Eberhardt Claes Lutz. Anatomy of the sheep spine and its comparison to the human spine. *Anatomical Rec*. 1997 Apr;247(4):542–555.