

CASE REPORT

Porcelain laminate veneer management for a discolored central incisor with total root replacement resorption: A case report

Mohamed Alessa  | Raed Almanea | Emad Alhazzani | Abdullah Alsirhani

Restorative Dentistry Department, Dental Center, Prince Sultan Military Medical City, Riyadh, Saudi Arabia

Correspondence

Mohamed Alessa, Restorative Dentistry Department, Dental Center, Prince Sultan Military Medical City, Riyadh, Saudi Arabia.

Email: dr.malessa85@hotmail.com

Funding information

All parts of this presentation were self-funded

Abstract

This case highlights the significance of conducting an in-depth clinical and radiographic examination before treating a single discolored tooth and proves the effectiveness of porcelain laminate veneers in masking intrinsic teeth discoloration.

KEYWORDS

intrinsic teeth discoloration, porcelain laminate veneers, traumatic dental injuries

1 | INTRODUCTION

Intrinsic teeth discoloration resulting from traumatic dental injuries represents a severe challenge to both dentists and patients, and their management is a demanding task and involves intensive planning and coordination among the restorative team members. Despite the case complexity, porcelain laminate veneers provide an excellent opportunity for masking intrinsic discoloration.

Traumatic dental injuries (TDIs) are highly prevalent during childhood and adolescence and significantly affect their oral health-related quality of life (OHRQoL). Uncomplicated TDIs and dental trauma involving enamel, enamel and dentin, and tooth discolorations account for approximately two-thirds of all diagnosed TDIs in children and adolescents.

The frequent dental problem seen in children is an injury to both primary and permanent dentition and supporting structures, typically caused by accidental falls.^{1,2} Al Majed et al³ 2001 reported a high prevalence (34%) of dental trauma to maxillary incisors in 12–14-year-old Saudi boys, with enamel fracture being the most prevalent type of trauma.

TDIs may lead to complications such as root resorption and may also result in severe discoloration of the teeth.⁴ *Teeth discoloration* is an essential esthetic consideration that may lead to psychological problems such as anxiety, depression, and post-traumatic stress resulting in an impaired day-to-day life.⁵ Unfortunately, there is a deficiency in knowledge, awareness, and immediate management strategies for dental trauma. Al Sehaibiany et al⁶ in 2018 suggested a need for effective TDI educational programs to be delivered at primary healthcare levels, which mothers in a survey considered valuable and relevant. At the same time, proper management of TDIs with a satisfying esthetic outcome is essential and a challenging task.

We present a case of an ankylosed and intrinsically yellowish discolored central incisor with total root replacement resorption as a result of dental trauma, managed with multiple ceramic veneers. Though management with ceramic veneers is a promising approach for decades, this case is unique as an attempt was made for restoring a completely resorbed tooth with a compromised prognosis and a very challenging task in improving the overall patient smile with perfect teeth color matching.

This is an open access article under the terms of the Creative Commons Attribution-NonCommercial-NoDerivs License, which permits use and distribution in any medium, provided the original work is properly cited, the use is non-commercial and no modifications or adaptations are made.

© 2021 The Authors. *Clinical Case Reports* published by John Wiley & Sons Ltd.

2 | CASE REPORT

A 42-year-old female patient presented to the dental clinic with the chief complaint of a discolored upper left central incisor and improper shape of the teeth. On examination, the patient showed an intrinsically yellowish discolored tooth #21 with ankylosis and total root replacement resorption, in addition to a healed root fracture of the adjacent tooth #11, as a sequela of previous dental trauma.

A review of the patient's history was made, and data were collected. However, the data were incomplete, and observations were made by recording the patient's history and obtaining an old periapical radiograph.

1. The patient was medically fit without a significant family medical history and considered an ASA1 according to the American Society of Anesthesiologists classification.

2. The past dental history revealed a dental trauma to the upper anterior segment a long time ago, without noticeable complications.

3. She showed an excellent oral hygiene, with an average probing depth measurement (2–3 mm) and slight bleeding on probing.

4. Multiple dental restorations were noticed, with acceptable qualities and without need for repair or replacement.

5. Pulp sensibility testing using cold refrigerant spray and electric pulp test was done for the upper anterior teeth and premolars, in which all revealed normal responses except for tooth #21 was non-responsive to both tests.

6. Percussion test with the back of a metal mirror handle was also done for the area of interest (from tooth #15 up to tooth #25) and revealed normal responses.

7. No detectable mobilities were noticed for all teeth.

8. Intrinsic yellowish discoloration was noticed on tooth #21 due to the previous dental trauma.

9. Smile analysis was done for the patient, indicating a reverse smile line, abnormal width to height ratios for most of the upper anterior teeth, and smile width of 10 teeth (up to the second premolar on each side).

The clinical examination and radiological investigation (Figures 1 and 2) facilitated in identifying the patient's complaints and formulate a plan for the treatment.

An intervention plan was designed, and the patient's written consent was obtained for the line of treatment. The treatment began by obtaining upper and lower primary alginate impressions for fabricating diagnostic casts and diagnostic wax-up for Porcelain laminate veneers (PLV's), including the upper anterior teeth and premolars, followed by chairside resin composite mock-up fabrication using the clear plastic stent technique. Teeth preparation for PLV's (from tooth #15 up to tooth #25) were carried on, with butt-joint incisal preparation design for the upper anterior teeth and window preparation design for the premolars and medium interproximal wrap for all of the prepared teeth. The amount of required teeth reduction was confirmed utilizing putty indices guides made over the diagnostic wax-up. Following teeth preparation, the final

impression was obtained with a two-stage putty wash technique utilizing polyvinyl siloxane impression materials. Temporization was then performed with a bisacryl composite resin material using putty index over the diagnostic wax-up technique. B1 shade was selected from the Vita Classical A_D arrangement shade guide system for fabricating heat pressed lithium disilicate reinforced glass-ceramic laminate veneers and delivered to the patient mouth after proper try-in and cemented with resin cement.

3 | RESULT

The result shows that discolored teeth in response to dental trauma can be successfully managed with PLV's and provide

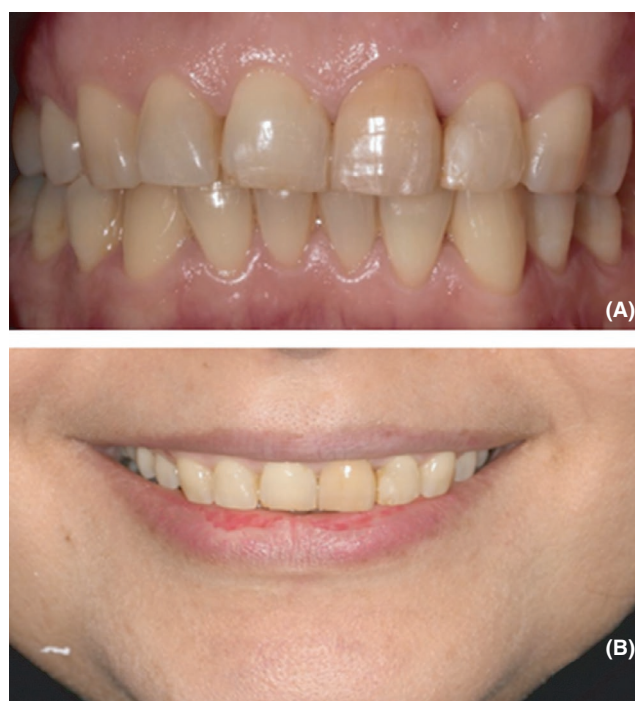

FIGURE 1 Preoperative clinical photographs. A, Retracted frontal view of the maxillary and mandibular teeth in the maximum intercuspation position. B, Frontal smile view

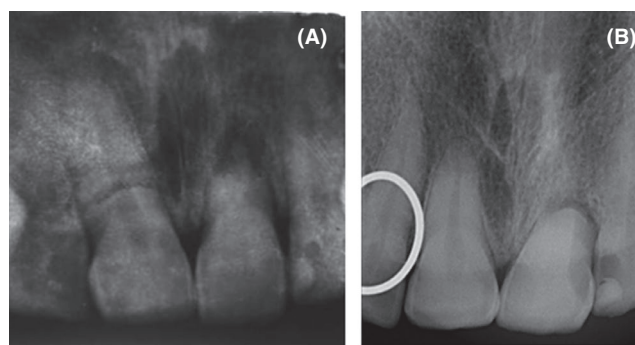


FIGURE 2 Preoperative periapical radiographs for tooth #21. A, 20 years earlier. B, Immediate preoperative

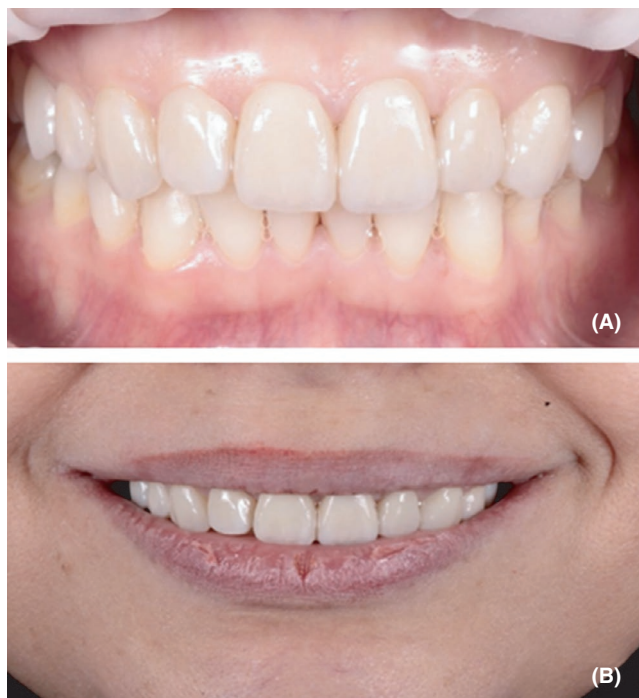

FIGURE 3 Postoperative clinical photographs. A, Retracted frontal view of the maxillary and mandibular teeth in the maximum intercuspation position. B, Frontal smile view

an excellent esthetic appearance and function. PLV is a valuable tool to achieve the desired results in salvaging and restoring the discolored teeth with minimally invasive treatment. A precise diagnosis and treatment plan makes it possible to obtain predictable, optimum, and satisfactory results and support in restoring the patients' confidence (Figures 3 and 4).

4 | DISCUSSION

This unique case provided a challenging opportunity for proper diagnosis and treatment of a resorbed discolored central incisor resulting from an old trauma. The underlying cause of discoloration remained undiagnosed for more than 20 years, and the resorption process was masked due to the physical stability of the tooth and lack of any symptoms. This case highlights the importance of conducting a thorough clinical examination and investigating the underlying cause before initiating treatment on a single discolored tooth. It is tough to manage chronic cases with undetected internal resorption and clinical presentation. Routine clinical examination and history taking would have failed to detect the underlying cause and pathology and get the desired prognosis.

Endodontic treatment and bleaching were successfully used to manage a discolored maxillary central incisor due to internal resorption.⁷ Internal and external tooth whitening using 16% Carbamide Peroxide were also successfully performed to manage a dark tooth with poor esthetic appearance

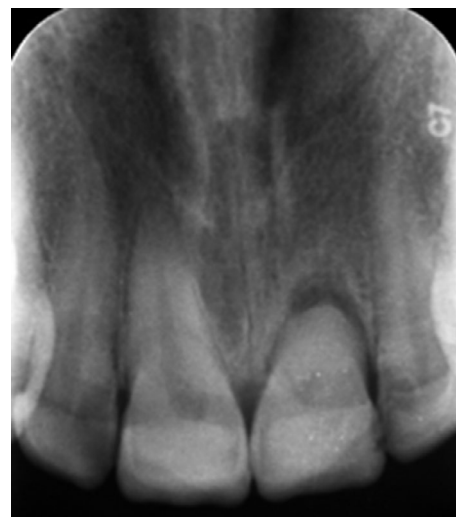

FIGURE 4 Immediate postoperative periapical radiograph for tooth #21

resulting from trauma and root canal management with a satisfying esthetic and functional integration.⁸

However, the use of porcelain veneers is considered an alternative and better treatment option due to their esthetics properties, survival rates, and effect on resorptive teeth.⁹ Faus – Matoses et al¹⁰ obtained a very satisfactory and minimally invasive result by using opaque composite before veneers placement for covering severe tooth discoloration (grade IV tetracycline stains) with optimum esthetic and functional outcome.

A recent report also utilized PLV's to facilitate a successful outcome for the management of discolored, ankylosed, and partially resorbed teeth.⁴ This case report further strengthens the use of PLV for the management of an ankylosed and almost completely resorbed tooth with exceptional esthetic and functional outcomes.

Immediate and proper management of TDI and the type of trauma are considered the crucial factors for teeth survival and maintenance of pulp vitality. However, it is not always possible to save the traumatized teeth, and the treatment goals should be aimed to reduce the consequences as much as possible. Some types of TDI, particularly concussion and subluxation, could be responsible for single tooth discoloration, which becomes more evident with time elapse, and resulted from pulp canal space obliteration.¹¹ The present report proves that PLVs show a promising result in masking intrinsic teeth discoloration and being a conservative approach for comprehensive esthetic treatment and smile makeover.

5 | SUMMARY

This case highlights the significance of conducting an in-depth clinical examination and radiographic analysis before beginning the treatment to correct a single discolored anterior tooth.

There are several causes of discoloration of a single tooth. Teeth resorption due to trauma may be responsible for the discoloration and mask the resorption process if left unattended. Therefore, in cases of suspected resorption, emphasis must be given to determine the extent of resorption and accomplish a favorable prognosis. A detailed clinical examination and history taking with the help of earlier radiographs facilitate identifying the underlying problems. It further highlights that porcelain laminate veneers are an excellent choice for restoring intrinsic teeth discoloration, regardless of the cause and the pathology.

ACKNOWLEDGEMENTS

The authors would like to thank Dr. Mohammed Arshaduddin, Scientific Research Center, MSD, for his valuable contribution in reviewing and editing the manuscript.

CONFLICT OF INTEREST

On behalf of all authors, no conflict of interest is reported.

AUTHOR CONTRIBUTIONS

MA led and designed the research, wrote and organized the manuscript, supervised and participated in the clinical management, directly communicated with the dental technicians, and collected all of the essential data. RA performed most of the clinical treatment steps. EA and AA supervised and participated in clinical management.

ETHICAL APPROVAL

Written informed consent was obtained from the patient for the publication of the text, images, and radiographs, and the study was approved by the Departmental Ethical Committee.

DATA AVAILABILITY STATEMENT

The authors confirm that the data supporting the presented finding are available within the article.

ORCID

Mohamed Alessa  <https://orcid.org/0000-0003-0500-7378>

REFERENCES

1. McTigue DJ. Diagnosis and management of dental injuries in children. *Pediatr Clin North Am.* 2000;47:1067-1084. [https://doi.org/10.1016/s0031-3955\(05\)70258-3](https://doi.org/10.1016/s0031-3955(05)70258-3)
2. Bastone EB, Freer TJ, McNamara JR. Epidemiology of dental trauma: a review of the literature. *Aust Dent J.* 2000;45:2-9.
3. Al-Majed I, Murray JJ, Maguire A. The prevalence of dental trauma in 5–6- and 12–14-year-old boys in Riyadh, Saudi Arabia. *Dent Traumatol.* 2001;17(4):153-158. <https://doi.org/10.1034/j.1600-9657.2001.170403.x>
4. Liebermann A, Edelhoff D, Prandtner O, Saeidi PR. Minimally invasive treatment of an ankylosed, severely discolored, and intruded central incisor with a masking ceramic veneer: a clinical report. *Int J Periodontics Restorative Dent.* 2018;38(1):121-126. <https://doi.org/10.11607/prd.2874>
5. Kishore J, Vatsa R, Singh J, Kumari M, Kumar T, Bandgar S. Psychological impact on maxillofacial trauma patients - an observational study. *J Med Life.* 2020;13(4):458-462. <https://doi.org/10.25122/jml-2020-0111>
6. Al-Sehaibany FS, Alajlan R, Almubarak D, Almaflehi N, Aljabaa A, AlBarakati SF. Knowledge on management of traumatic dental injuries among Saudi mothers. *Clin Cosmet Investig Dent.* 2018;10:123-128.
7. Todd M, Brackett W, Romero M. Correction of a single discolored anterior tooth due to internal resorption: a clinical report. *Compend Contin Educ Dent.* 2017;38:e13-e16.
8. Serrat Baron R, De Ribot Porta J, Jané Noblom L, Ali Hussein A. Dental trauma, aesthetic management: a case report. *Acta Sci Dent Sci.* 2019;3(4):22-27.
9. Morimoto S, Albanesi RB, Sesma N, Agra CM, Braga MM. Main clinical outcomes of feldspathic porcelain and glass-ceramic laminate veneers: a systematic review and meta-analysis of survival and complication rates. *Int J Prosthodont.* 2016;29(1):38-49. <https://doi.org/10.11607/ijp.4315>
10. Faus-Matoses V, Faus-Matoses I, Ruiz-Bell E, Faus-Llácer VJ. Severe tetracycline dental discoloration: restoration with conventional feldspathic ceramic veneers. A clinical report. *J Clin Exp Dent.* 2017;9:e1379-e1382.
11. Oginni AO, Adekoya-Sofowora CA. Pulpal sequelae after trauma to anterior teeth among adult Nigerian dental patients. *BMC Oral Health.* 2007;7(1):11. <https://doi.org/10.1186/1472-6831-7-11>

How to cite this article: Alessa M, Almanea R, Alhazzani E, Alsirhani A. Porcelain laminate veneer management for a discolored central incisor with total root replacement resorption: A case report. *Clin Case Rep.* 2021;9:e04588. <https://doi.org/10.1002/ccr3.4588>