

Laparoscopic Excision of an Adrenal Ganglioneuroma Presented as an Incidentaloma of the Retro Peritoneum

K. SAPALIDIS¹, S. MANDALOVAS¹, I. KESISOGLU¹

¹3rd Department of Surgery, AHEPA University Hospital,
Aristotle University of Thessaloniki, Thessaloniki, Greece

ABSTRACT: Adrenal ganglioneuroma (GN) is a benign tumor of retro-peritoneum that is presented as an incidentaloma. GNs most commonly have been diagnosed by imaging examinations notably by CT scan. Differential diagnosis from other malignant adrenal tumors is often difficult. The only examination that confirms diagnosis is only the histopathological one. Surgical excision of a GN has been proposed as the best solution for both diagnostic and therapeutic purposes. This case report is about a 68-year old male patient presenting with a non-typical abdominal pain. The imaging investigation showed an incidentaloma over 4cm at its large axis. The patient underwent laparoscopic excision of the tumor. We present the steps followed during the diagnosis the appropriate treatment and the follow up examinations as a result of this rare finding.

KEYWORDS: adrenal ganglioneuroma, incidentaloma, retro peritoneum, laparoscopy

Introduction

Adrenal ganglioneuroma (GN) is a rare, slow-growing, benign, neuroblastic tumor that consists of neural crest cells [1,2]. They appear as solid, firm masses with a typical white color when observed with the naked eye. Histologically, the tumor is composed of Schwann mesenchymal cells, mature gangliocytes and fibrous tissue [3]. These tumors most commonly arise from sympathetic ganglia and may be situated at any site of the sympathetic chain from the skull base to the pelvis [4]. They are most commonly located in posterior mediastinum (39-43%), retroperitoneum (32-52%) and the adrenal medulla [5,6]. GNs are non-functioning tumors [1]. They are characterized as incidentalomas (IN) because of the absence of typical symptoms until the tumor gets large enough to cause symptoms due to compression of adjacent structures. The prevalence of an adrenal IN is about 0.2% in younger patients, 3% in populations past the fifth decade of their life, and 7% in those past their seventh decade [1]. GNs comprise about 0-6% of all of adrenal incidentalomas [7,8]. The mean age of patients that present GN is 38.4 years with a range about 25-52 years and with sex ratio 2:1 male to female [9]. Although GN is a benign non-secreting tumor there have been described in the literature some cases of malignant GNs with hepatic metastases [10] as well as cases with hormonal activity [1]. In some cases GNs may secrete catecholamines and patients present symptoms mimicking pheochromocytoma. As

an incidentaloma GN most commonly has been diagnosed by imaging examinations including Ultra sound and CT scan that have been implemented for other clinical reasons. Adrenal incidentalomas (AIs) were found in 2.5% of patients undergoing chest and abdomen CT [11]. The average mass size of AIs in multiple researches that have been published in literature is about 2,75cm [12,13]. In a Chinese retrospective study the initial mean size of GNs in CT scan was about 6.27cm (range, 2.5-14cm) [8]. Differential diagnosis of adrenal tumors based on imaging characteristics is often difficult. Some tumors, many of them malignant like adrenocortical carcinoma (ACC) and pheochromocytoma may be misdiagnosed as GNs [1]. This must be taken seriously into account when deciding the treatment of choice. The diagnosis was actually later confirmed by histopathological examination [2]. Because the initial size of GNs is usually over 4cm and it is difficult to get an exact differential diagnosis with imaging criteria surgical exertion have been proposed as the best solution for both diagnostic and therapeutic reasons [11]. Laparoscopic excision is the procedure of choice. The prognosis after a surgical removal is excellent [1,14]. In this case report, we present the case of a 68-year old male patient with a GN adrenal tumor. The initial diagnosis of this adrenal incidentaloma was revealed after a CT scan of upper and lower abdomen during investigation of a non typical abdominal pain.

Case report

A 68-year old male patient visited his family doctor complained for atypical upper abdominal pain. After obtaining informed consent from the patient, we began with a typical clinical examination. This examination was based on medical history and any probable symptom and signs that were presented by the patient. No typical clinical finding was observed so the physician proposed further investigation with the ultrasound (US) of the upper abdomen. The US performed revealed a mass in the retroperitoneal space, possibly pertaining to the left adrenal gland. This mass was described with clear boundaries, dotted calcification and mild central tumor vasculature. This aspect made the differential diagnosis more complicated, spanning from adrenal adenoma to pheochromocytoma. The size of the tumor was

approximately 5cm as measured by US. For this reason imaging procedure included CT scan for further investigation of this mass. CT scan confirmed the presence of the mass and described a tumor in the left adrenal gland, with mild inhomogeneous solid characteristics and an oval size of approximately 42x38x32mm (Fig.1). The tumor had also low electron levels on the Hounsfield scale (about 15 HU) and the CT showed a small dot calcification over the tumor. The washout percentage of the tumor was measured at a minute and 15 minutes later after intravenous administration of a radiocontrast agent. The washout percentage did not help the differential diagnosis of this adrenal incidentaloma because there observed further intake of the radiocontrast agent in the late CT images of the tumor (about 40-45 HU 15 minute later). Retroperitoneal lymph node involvement or other metastases was not detected.

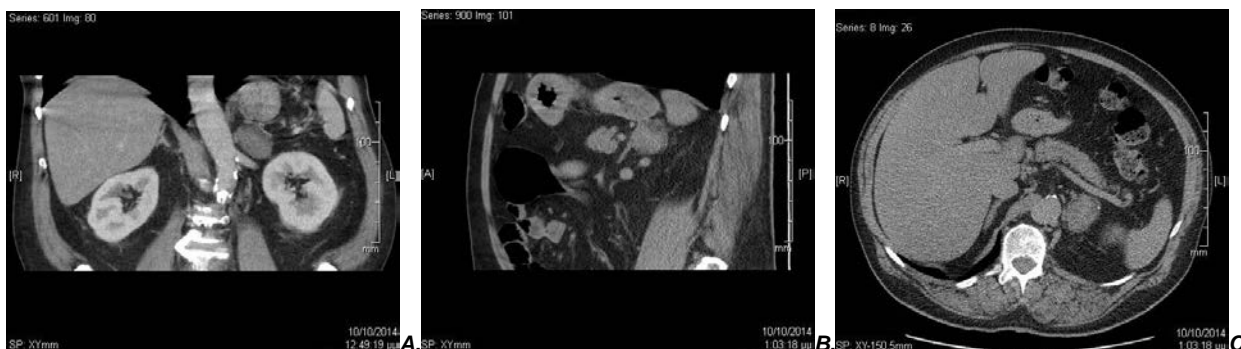


Fig.1. A,B,C: CT scan shows a mass with mild inhomogeneous solid characteristics and an oval size about 42x38x32mm

However the imaging criteria weren't sufficient for the investigation of the AI. Naturally the hormonal activity of the tumor had to be investigated. The patient was referred to the department of endocrinology of the University hospital of AHEPA Thessaloniki to complete the examinations required. These included a 24hr urinary free cortisol and 24hr urinary metanephrine levels as well as catecholamines levels. Plasma aldosterone and renin levels were not required because the patient did not present with medical history of hypertension. Both biochemical examinations showed that hormone levels were within normal parameters.

VMA was 2.67mgr/24h (2-7mg/24 hours) and cortisol was 28.5µgr/24h (3.5-45µg/24h). In conclusion and taking into account the above measured parameters the AI seemed to be a non-secreting adrenal tumor. Only the increased size of the tumor (42mm>40mm) was an inclusion

criteria for the surgical excision of this AI. The non diagnostic washout percentage gave us a little evidence about the malignancy of the tumor. The patient underwent to laparoscopic excision of the tumor for both therapeutic and diagnostic purposes. The surgical specimen had an oval shape and its size was in its longest axis was 4,8cm. The tumor was solid, with no hemorrhage and necrotic signs with its cut surface showing a white color as described in literature (Fig.2,3). The histological examination showed many Schwann cells inside fat tissue as well as gangliocytes. Immunohistochemically Schwann cells were at S100 protein positive [S100(+)] and gangliocytes NSE (+) (Fig.4-7). The postoperative period was free of complications. Six months later a scheduled follow up examination was performed, with a new CT scan. There was no evidence of recurrence of the tumor in the retroperitoneum.

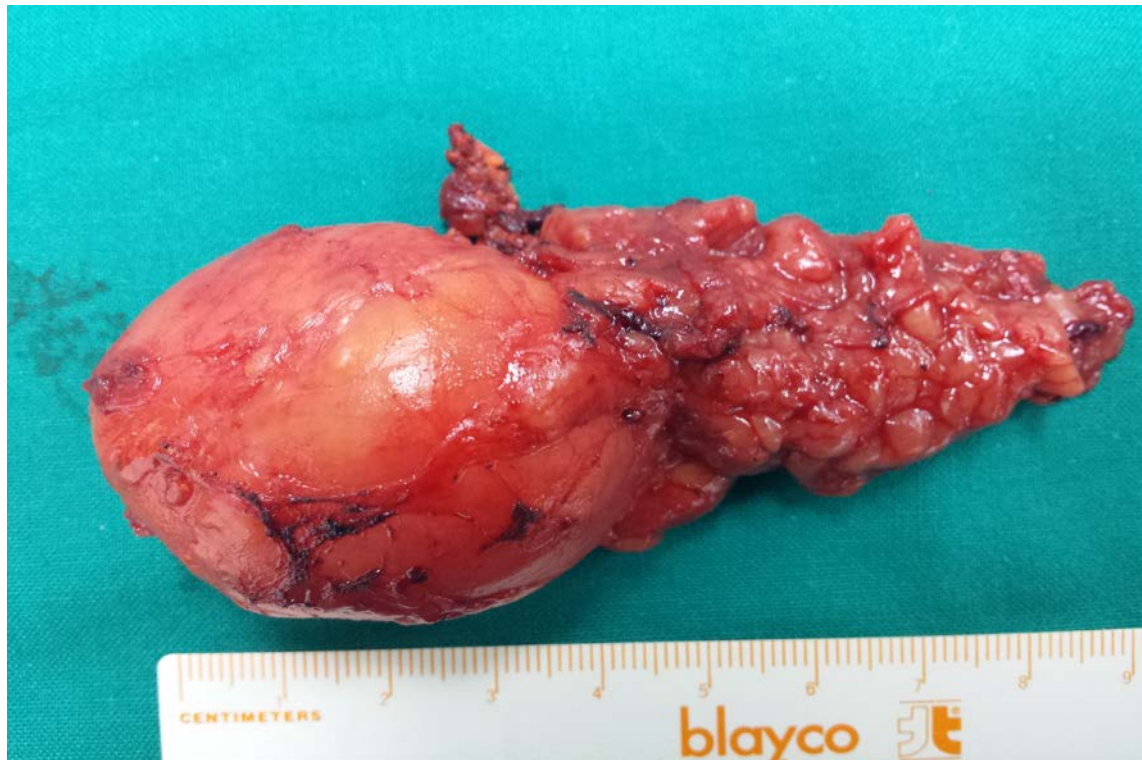

Fig.2. The surgical specimen with its longest axis at 4,8cm

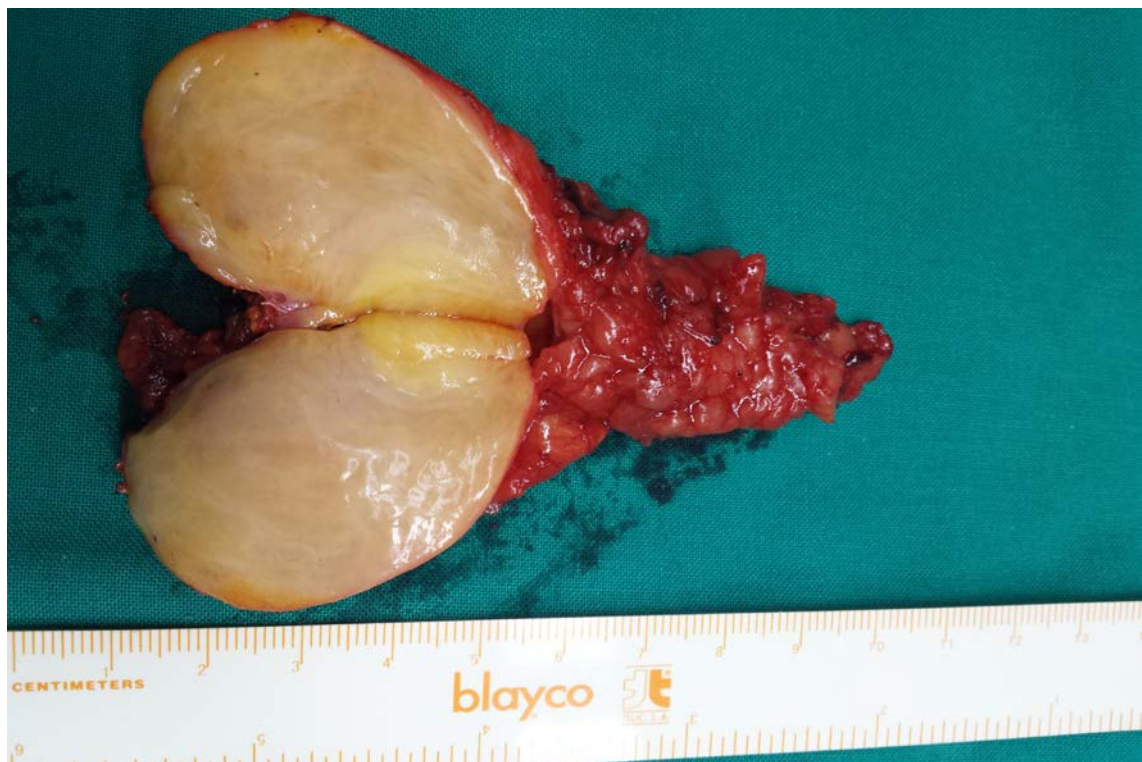

Fig.3. The surgical specimen appears with an oval shape, solid, with no hemorrhage and necrotic signs, with its cut surface showing a white color

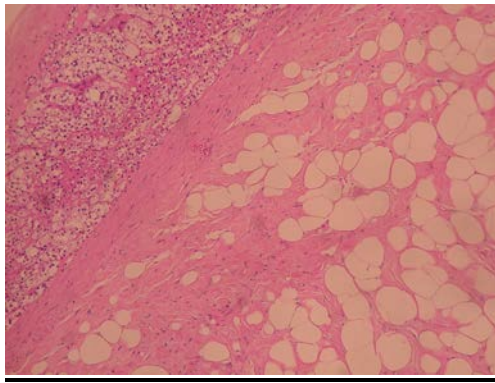


Fig.4. Borderlines form adrenal gland cortex to the tumor with Schwann cells into the fat tissue

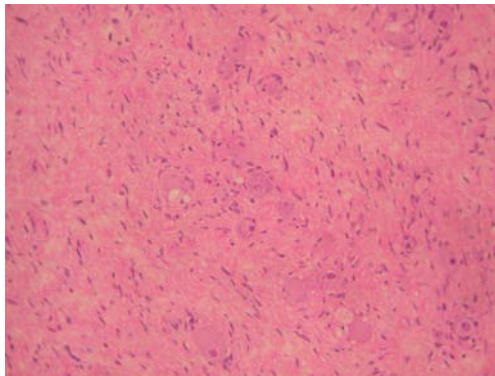


Fig.5. Schwann cells with large gangliocytes

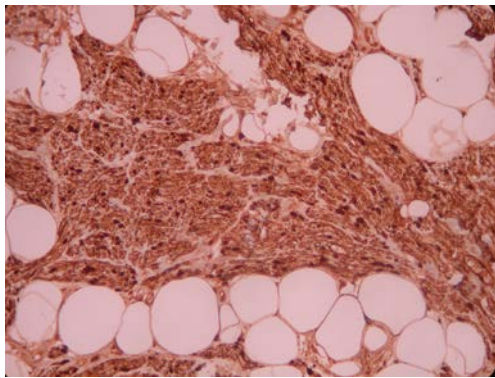


Fig.6. Schwann cells positive at S100 protein

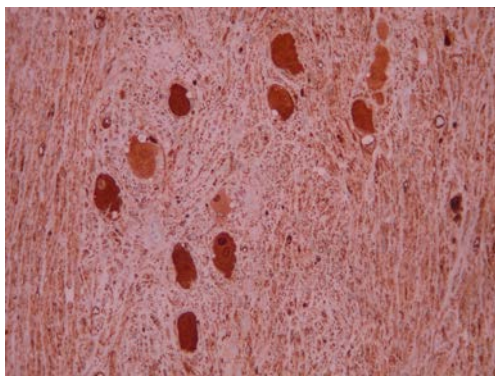


Fig.7. Gangliocytes positive at NSE protein

Discussion

Adrenal Ganglioneuroma (GN) is a non-functional benign tumor that develops slowly. Although there have been described in literature cases of malignant GNs with hepatic metastases and hormonal activity GN is most commonly presented as an adrenal incidentaloma. Adrenal Incidentalomas are the tumors found by coincidence (incidentally) without clinical symptoms or suspicion. Symptoms are presented only if the tumor becomes large enough to cause symptoms by pressure on adjacent organs or if the tumor exhibits any hormonal activity. The examination that confirms the existence of an adrenal incidentaloma is the CT scan. Incidental adrenal masses on imaging are common (0.6 to 1.3% of all abdominal CT). GN comprise about 0-6% of all of adrenal incidentalomas. The initial size of a GN that has been measured by CT is often large. Although the average mass size of AIs is about 2,75cm, in a Chinese retrospective study the initial size of GNs shows a range about 2.5-14cm with a mean size about 6.27cm. There are many indications about the surgical excision of an AI for the risk of malignancy. The most common have to do with the size, the presence hormonal activity and the radiologic appearance of the tumor. Masses with size over 4.0cm should be removed. Incidentalomas of any sizes that display either clinical, imaging or serum abnormalities that may plead for an adrenal hyperfunction or malignancy are candidates for surgery. The differential diagnosis only with imaging criteria is often difficult. It comprises of a long list of tumors witch include pheochromocytoma, adrenocortical carcinoma, lipoma, myelolipoma, cyst, metastases or inflammation from any cause. All these tumors show similar results about their appearance in the Hounsfield scale and the washout percentage [15,16]. In most cases (71%) other malignant tumors like pheochromocytoma and paraganglioma coexist with GN. Because the initial size of GN is often over 4cm and it appears at CT scan with calcifications, similar Hounsfield levels and washout percentage and usually coexists with other malignant tumors complete surgical resection is the preferred approach for both therapeutic and diagnostic reasons. Laparoscopic excision is the gold standard for the surgical treatment of GNs of the adrenal gland. A follow-up is recommended in any case. Histopathological examination is the only way to confirm the diagnosis of an AI. There isn't a commonly accepted procedure for

an optimal follow up in each case. Patients with AI that surgery is not an initial option should be followed up by their physician. It is recommended that imaging follow-up should be performed at 3-6 months intervals for masses having a high suspicion of malignancy or at one year for lesions that may appear benign. If the tumor secretes hormones such as catecholamines or cortisole, the attending team should perform annual clinical and laboratory follow-up, focusing on hormonal disorders, for at least four years.

Conclusion

The prognosis of an AI depends mostly on the histopathological type of the tumor. Following surgical removal, prognosis tends to be very good in the case of GN, with no further chemotherapy or radiotherapy required

References

- Adas M, Koc B, Adas G, Ozulker F, Aydin T. Ganglioneuroma presenting as an adrenal incidentaloma: a case report. *J Med Case Rep*, 2014, 8:131.
- Oderda M, Cattaneo E, Soria F, Barreca A, Chiusa L, Morelli B, Zitella A, Gontero P. Adrenal Ganglioneuroma with Multifocal Retroperitoneal Extension: A Challenging Diagnosis. *The Scientific World Journal*, 2011, 11(5):1548-1553.
- Prasad K Shetty, Balaiah K, Gnana Prakash S, Prasanna K Shetty. Ganglioneuroma Always A Histopathological Diagnosis. *Online J Health Allied Scs*, 2010, 9(4):19.
- Levy DI, Bucci MN, Weatherbee L, Chandler WF. Intradural Extramedullary Ganglioneuroma: Case Report and Review of the Literature. *Surg Neurol*, 1992, 37(3):216-218.
- Chang CY, Hsieh YL, Hung GY, Pan CC, Hwang B. Ganglioneuroma presenting as an asymptomatic huge posterior mediastinal and retroperitoneal tumor. *J Chin Med Assoc*, 2003, 66(6):370-374.
- Zhou Y, Liang Q, Ou WT, Li ZY, Liu QL. Laparoscopic resection of primary adrenal ganglioneuroma: A case report and review of the literature. *Oncol Lett*, 2015, 9(5):2167-2170.
- Zografos GN, Farfaras A, Vasiliadis G, Pappa T, Aggeli C, Vassilatou E, Kaltsas G, Piaditis G. Laparoscopic resection of large adrenal ganglioneuroma. *JLS*, 2010, 14(3):364-368.
- Kacagan C, Basaran E, Erdem H, Tekin A, Kayikci A, Cam K. Case report: Large adrenal ganglioneuroma. *Int J Surg Case Rep*, 2014, 5(5):253-255.
- Li L, Shao J, Gu J, Wang X, Qu L. Adrenal Ganglioneuromas: Experience from a Retrospective Study in a Chinese Population. *Urol J*, 2014, 11(2):1485-1490.
- Jung HR, Kang KJ, Kwon JH, Kang YN. Adrenal ganglioneuroma with hepatic metastasis *J Korean Surg Soc*, 2011, 80(4):297-300.
- Tarantino MR, Machado LA, Neto C, Henriques S, Dutra AH, Mario V. Adrenal ganglioneuroma, case report. *Arq Bras Endocrinol Metab*, 2012, 56(4):270-274.
- Kapoor A, Morris T, Rebello R. Guidelines for the management of the incidentally discovered adrenal mass. *Can Urol Assoc J*, 2011, 5(4):241-247.
- Moreira SG Jr, Pow-Sang JM. Evaluation and Management of Adrenal Masses. *Cancer Control*, 2002, 9(4):326-334.
- Abraham GP, Siddaiah AT, Das K, Krishnamohan R, George DP, Abraham JJ, Chandramathy SK. Laparoscopic extirpation of giant adrenal ganglioneuroma. *J Minim Access Surg*, 2014, 10(1):45-47.
- Sangwaiya MJ, Boland GW, Cronin CG, Blake MA, Halpern EF, Hahn PF. Incidental Adrenal Lesions: Accuracy of Characterization with Contrast-enhanced Washout Multidetector CT10-minute Delayed Imaging Protocol Revisited in a Large Patient Cohort. *Radiology*, 2010, 256(2):504-510.
- Anila KR, Somanathan T, Hews AM, Jayasree K. Incidentally detected Ganglioneuroma of adrenal gland. *Journal of Case Reports in Practice (JCRP)*, 2014, 2(2):45-47.
- Harada T, Kamishima T, Terae S, Onodera Y, Shirato H. Multi-Detector-Row CT Diagnosis of Adrenal Incidentaloma in Patients with Hepatocellular Carcinoma. *ACT*, 2013, 2(1):34-40.
- Petričević J, Librenjak D, Tomić S, Sutalo N, Bošnjak A. Adrenal ganglioneuroma in adult, case report. *Psychiatria Danubina*, 2014, 26(Suppl. 2): S407-S408.

Corresponding Author: K. Sapalidis, 3rd Department of Surgery, St. Kiriakidis 1, P.O. 54636, Ahepa University Hospital, Aristotle University of Thessaloniki, Thessaloniki, Greece, e-mail: sapalidis@med.auth.gr, sapalidiskonstantinos@gmail.com