

Received: 2018.05.29
Accepted: 2018.07.18
Published: 2018.10.25

Pneumomediastinum, Tracheal Diverticulum, and Probable Asthma: Coincidence or Possible Association? A Case Report

Authors' Contribution:
Study Design A
Data Collection B
Statistical Analysis C
Data Interpretation D
Manuscript Preparation E
Literature Search F
Funds Collection G

AEF 1,2 **Ivan Cherrez-Ojeda**
ABEF 1,2 **Miguel Felix**
ABCDEF 1,2 **Emanuel Vanegas**
AEF 1,2 **Valeria L. Mata**

1 Universidad Espíritu Santo (UEES) (Holy Spirit University), Samborondón, Ecuador
2 Respiralab Research Group, Guayaquil, Ecuador

Corresponding Author: Ivan Cherrez-Ojeda, e-mail: ivancherrez@gmail.com
Conflict of interest: None declared
Source of support: This study was partially supported by an unrestricted grant from the Universidad Espíritu Santo

Patient: Male, 25
Final Diagnosis: Spontaneous pneumomediastinum
Symptoms: Chest discomfort • exertional dyspnea • wheezing
Medication: —
Clinical Procedure: —
Specialty: Pulmonology


Objective: Rare co-existence of disease or pathology
Background: Many conditions and triggers have been identified and associated with spontaneous pneumomediastinum (SPM), including asthma, strenuous exercise, chronic obstructive pulmonary disease, diabetic ketoacidosis, inhalational drugs, and other activities associated with the Valsalva maneuver. Among rare findings reported in patients with SPM is tracheal diverticulum. We present a case of SPM that on further evaluation was noted to have a tracheal diverticulum, together with a possible diagnosis of asthma.

Case Report: A 25-year-old male was admitted to the hospital for dyspnea and chest pain. Based on initial assessment, laboratory findings, and imaging, he was diagnosed with SPM. Recovery was successful, and the patient was discharged 3 days later. Follow-up at 2 weeks revealed an abnormality on imaging and abnormal pulmonary function tests. A computed tomography scan revealed a tracheal diverticulum located on the right posterolateral region of the trachea at T1 level. Pulmonary function tests abnormalities included: high fractional exhaled nitric oxide (FeNO), high lung clearance index (LCI), and elevated diffusing capacity of the lungs for carbon monoxide (DLCO).

Conclusions: Although the patient presented with a normal spirometry, the FeNO, LCI, and DLCO findings proved valuable and suggested a possible diagnosis of asthma. The anatomic weakness associated with the tracheal diverticulum could have been the breaking point of sustained increased pressure in the airways, due to a possible asthma exacerbation. In retrospective, we hypothesized this to be a series of events that ultimately ended as a pneumomediastinum.


MeSH Keywords: Asthma • Pneumomediastinum, Diagnostic • Respiratory Function Tests • Tracheal Diseases

Full-text PDF: <https://www.amjcaserep.com/abstract/index/idArt/911413>

 1586

 2

 1

 18



Background

Pneumomediastinum is the presence of air or other gas in the mediastinic cavity. Based on the main etiologic precipitant, it can be classified as traumatic, iatrogenic, or spontaneous [1].

Spontaneous pneumomediastinum (SPM) is a rare entity, occurring predominantly in young male patients without significant medical background [2]. The pathophysiology of SPM is thought to be caused by a sudden increase in intrathoracic pressure, resulting in increased intra-alveolar pressure, leading to alveolar rupture [3]. This rupture leads to further air leakage into the interstitium in a centripetal pattern towards the mediastinum.

Many conditions and triggers have been identified and associated with SPM including asthma, strenuous exercise, chronic obstructive pulmonary disease (COPD), diabetic ketoacidosis, inhalational drugs, and other activities associated with the Valsalva maneuver [4]. A systematic review of the literature identified the most frequently reported symptoms to be chest pain, dyspnea, and cough [5]. Significant physical examination findings include subcutaneous emphysema, neck swelling, and the Hamman sign (a cracking sound auscultated during systole) [1].

Among rare findings reported in patients with SPM is tracheal diverticulum [6]. These outpouchings consist of small air collections from a single or multiple invagination on the tracheal wall, lined by ciliated columnar epithelium [7]. Recent studies identified the prevalence to be around 8% [8].

We present a case of SPM that on further evaluation was noted to have a TD together with a probable diagnosis of asthma. Subsequently, we examine how the diagnosis of asthma, despite having a normal spirometry, was made. Finally, we discuss the possible associations, if any, and hypothesize the sequence of events between these 3 entities.

Case Report

A 25-year-old college male student developed progressive symptoms of dyspnea beginning in the morning. Later that day, symptoms became so severe that he had to be admitted to the hospital. In the Emergency Department the patient mainly complained of dyspnea and chest pain. His body mass index was 22.3 kg/m², and he had a history of allergic rhinitis treated with self-prescribed over the counter H1 antihistamines, and he had a dust mite allergy confirmed by prick test. The patient denied tobacco consumption. Past medical history was unremarkable for arthralgias, chills, weight loss, familial history of asthma, dyspneic episodes, or chest pain. On

Table 1. Laboratory workup at hospitalization.

Laboratory test	Admission laboratories	Discharge laboratories	Ref. values
Platelets	203	225	140–400×10 ⁹ /L
WBC	16.67*	10.73	4.1–11×10 ⁹ /L
Neutrophils	69.10	73.1	55–75%
Lymphocytes	16.3*	18.3	17–45%
Hemoglobin	16.5	15.6	12–16.0 g/dL
CRP	80.2*	36.6*	0–5 mg/L
Glucose	115*	103	64–106 mg/dL
BUN	25	26	20–50 mg/dL
Creatinine	0.98	0.87	0.67–1.17 mg/dL
Sodium	138	140	135–145 mg/dL
Potassium	3.9	3.7	3.5–5.1 mg/dL
Chloride	98	101	98–108 mg/dL

WBC – white blood cells; CRP – C-reactive protein; BUN – blood urea nitrogen. * Denotes a value out of range.

physical examination he was afebrile, with no abnormal cardiac sounds. Wheezing was noted among pulmonary auscultation. At palpation, he had subcutaneous crepitation at the right supraclavicular area.

A computed tomography (CT) scan was performed, which showed presence of air surrounding the supra aortic trunks, ascending and descending aorta, esophagus, trachea, and heart, compatible with pneumomediastinum. There were no signs of pneumothorax or pleural effusions. Ground glass opacities were present in the right medium pulmonary lobe and the left lower pulmonary lobe. No nodules or adenopathies were noted. CT scan of the abdomen was otherwise normal.

Initial laboratory tests revealed a marked C-reactive protein elevation, together with leukocytosis. Gram stain of the sputum revealed gram-positive cocci, with positive IgG serology for adenovirus. Sputum culture negative for any microorganisms (laboratory workup is depicted in Table 1). The patient was started on empiric antibiotic therapy with levofloxacin and clindamycin, intravenous steroids, analgesia, and inhaled bronchodilators. He was discharged 3 days later, with good clinical and radiological response to treatment.

One week after discharge, the patient developed dyspnea while playing sports, which lead him to seek a physician visit. Due to recent events, a CT scan along with pulmonary function tests were performed (Table 2). The CT scan revealed a

Table 2. Pulmonary Function Tests.

	Parameter	Result
Spirometry	FVC	4.55
	FEV1	4.41
	FEV1/FVC%	97.0
	FEF25–75 L/s	7.45
DLCO	Baseline	38.8*
	Baseline	108 ppb*
FeNO	With treatment	39 ppb
	After treatment	79 ppb*
LCI	Baseline	7.13*

* Indicates elevated result. FVC – forced vital capacity; FEV1 – forced expiratory volume in one second; FEF25–75 – forced mid-expiratory flow; FeNO – fractional exhaled nitric oxide; LCI – lung clearance index; DLCO [mL/min/mm Hg] – diffusing capacity of the lung for carbon monoxide.

tracheal diverticulum, measuring 3.79 mm on the horizontal axis by 3.27 mm on the vertical axis; located on the right posterolateral region of the trachea at T1 level. No other abnormalities were noted on the CT scan (Figure 1).

The patient was initiated on bronchodilators with inhaled corticosteroids (fluticasone/salmeterol) with satisfactory clinical response. FeNO measurements 1 week after treatment initiation decreased to normal levels. The patient reported improvement in symptoms. After 1 month, owing to a clinical improvement, the patient discontinued medication on his own, leading to a return of chest tightest and dyspnea induced by strenuous activity or exercise. He was again counseled and prescribed with the appropriate treatment.

Three months from the initial event, the patient remains asymptomatic, with close follow up, and short acting bronchodilators if needed. Regarding the tracheal diverticulum, a watch and wait approach was adopted. Bronchoscopy has not yet been performed at any stage.

Discussion

A follow-up to SPM weeks later, revealed 2 previously undiagnosed conditions: the presence of a tracheal diverticulum on CT scan, and a possible diagnosis of asthma. The patient had symptoms suggestive of the latter (dyspnea induced by physical activity), but on spirometry no demonstrable obstruction was noted. With additional tests performed, the patient was found to have several abnormalities: high FeNO, high LCI, and elevated DLCO.

A study by Spergel et al. evaluating the correlation between FeNO, spirometry, and asthma symptoms suggested that FeNO correlated more closely than forced expiratory volume (FEV1) to symptoms. Of note, is the fact that in the same study [9], FeNO did not correlate with FEV1, suggesting that these parameters measured different aspects of asthma. While spirometry focuses on bronchoconstriction, FeNO measures airway inflammation [10]. These differences translate into various results and clinical implications. Spirometry is vulnerable to reversibility of airway obstruction, and might yield normal measurements in patients with asthma that are asymptomatic when the test is performed [11]. This interaction lowers the sensitivity of spirometry, limiting its clinical value to rule out asthma. On the other hand, FeNO is associated in parallel to airway caliber, with low FeNO measurements on narrow-constricted airways, but elevated and steadier values in periods with normal airway caliber [12–14]. This represents a considerable advantage of FeNO over spirometry in the context of mild to moderate asthma, where patients are usually asymptomatic when

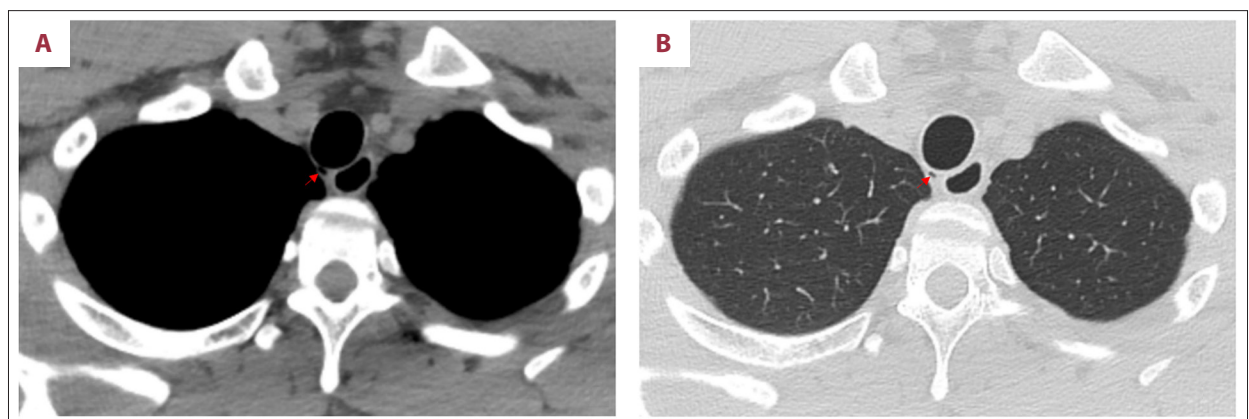


Figure 1. Computed tomography scan reveals a tracheal diverticulum located at T1 level, on the right posterolateral region of the trachea (red arrow points to the tracheal diverticulum). (A) Mediastinal window, (B) Pulmonary window.

attending at the healthcare provider's office. For the diagnosis of asthma in adult individuals, a sensitivity of 29% (95% CI, 21–39) has been reported for spirometry [11]. A recent systematic review and meta-analysis evidenced that FeNO can reach a sensitivity of 80% (95% CI, 72–86) [15]. Thus, proving useful for ruling out the condition. In our case, there were 3 assessments of FeNO. Pretreatment measurement of FeNO yielded a high (108 ppb) value, indicating possible airway inflammation. Following inhaled corticosteroids and bronchodilators, FeNO decreased to 39 ppb, together with improvement in clinical response. A third assessment made following a period when the patient discontinued medication on his own, revealed a higher FeNO (79 ppb), together with worsening of symptoms.

Despite not having an objective demonstration of reversible airway obstruction, the patient had a compatible symptomatology with asthma (mainly chest tightness and dyspnea, both induced by exercise). He also presented with elevated levels of FeNO when symptomatic, which decreased near to normal levels after bronchodilation. When discontinuing medication, a significant increase in FeNO was once again recorded, accompanied with worsening symptoms. In this case, testing for bronchial hyper-responsiveness by performing a methacholine challenge test would have provided a final answer to the diagnosis. Unfortunately, this testing modality is not yet available in our country.

Additionally, the patient was found to have a tracheal diverticulum on CT scan, located on the right posterolateral side of the trachea. This entity can be congenital or acquired in nature, with the latter occurring after long standing periods of increased intraluminal pressure in the presence of a weakened tracheal wall (e.g., COPD) [16]. Congenital tracheal diverticulum is seen more commonly in males, with diameter being smaller than acquired tracheal diverticulum [7]. These outpouchings can sometimes serve as a reservoir of infected mucus, thus being an underlying cause of recurrent respiratory tract infections, associated with episodes of hemoptysis [17]. Due to the location, size, age, and sex of the patient, the tracheal diverticulum found on CT scan appeared to be congenital in nature.

Taking into consideration the previous findings and limitations, after considering a possible asthma diagnosis, we hypothesized

that the tracheal diverticulum might be a preexisting condition contributing to the pathogenesis of the pneumomediastinum. The anatomic weakness associated with this entity could have been the breaking point of sustained increased pressure in the airways, due to a possible asthma exacerbation. Currently, there has been only 1 case of pneumomediastinum associated with tracheal diverticulum, secondary to a perforation caused by tracheal intubation [18]. Evidently, the mechanical force exerted during intubation exceeded the resistance of the tracheal diverticulum wall. Analogous to our case, the mechanical stress was exerted by increased airway pressure. Perhaps, in a scenario without a tracheal diverticulum, no pneumomediastinum would have been manifested.

Conclusions

To the best of our knowledge, this is the first case report to discuss the possible implications and coexistence of asthma and tracheal diverticulum in the pathogenesis of SPM. Furthermore, the possibility of asthma diagnosis was based on compatible symptoms, and throughout the use of novel airway inflammatory, and small airway tests. The clinical utility of these observations could suggest that if SPM recurs during asthma exacerbation, a surgical approach for the tracheal diverticulum might be considered. Additionally, this could imply a stricter control and treatment of asthma control, with a closer follow-up in this particular case.

Acknowledgements

The authors acknowledge the guidance and knowledge imparted by the MECOR Program for this study, especially from Sonia Buist MD, Ana Menezes MD, and Juliana Ferreira M.D. We also express our gratitude to Sofia Cherrez M.D, Cano Jose MD, Karin Plaza MD, and all the members of Respiralab Research Group. We also want to acknowledge Universidad Espiritu Santo for their continuous support.

Conflict of interests

None.

References:

1. Kara H, Uyar HG, Selim D et al: Dyspnoea and chest pain as the presenting symptoms of pneumomediastinum: Two cases and a review of the literature. *Cardiovasc J Afr*, 2015, 26: e1–4
2. Dirweesh A, Alvarez C, Khan M, Christmas D: Spontaneous pneumomediastinum in a healthy young female: A case report and literature review. *Respir Med Case Rep*, 2017, 20: 129–32
3. Caceres M, Ali SZ, Braud R, Weiman D, Garrett HE Jr.: Spontaneous pneumomediastinum: A comparative study and review of the literature. *Ann Thorac Surg*, 2008, 86: 962–66
4. Murayama S, Gibo S: Spontaneous pneumomediastinum and Macklin effect: Overview and appearance on computed tomography. *World J Radiol*, 2014, 6: 850–54
5. Dajer-Fadel WL, Arguero-Sanchez R, Ibarra-Perez C, Navarro-Reynoso FP: Systematic review of spontaneous pneumomediastinum: A survey of 22 years' data. *Asian Cardiovasc Thorac Ann*, 2014, 22: 997–1002
6. Gorgas DL, Miller B: Tracheal diverticulum masquerading as pneumomediastinum in a trauma victim. *Am J Emerg Med*, 2015, 33: 310.e311–13
7. Gayer G: Tracheal diverticula. *Semin Ultrasound CT MR*, 2016, 37: 190–95

8. Boyaci N, Dokumaci DS, Karakas E et al: Paratracheal air cysts: Prevalence and relevance to pulmonary emphysema and bronchiectasis using thoracic multidetector CT. *Diagn Interv Radiol*, 2015, 21: 42–46
9. Spergel JM, Fogg MI, Bokszzczanin-Knosala A: Correlation of exhaled nitric oxide, spirometry and asthma symptoms. *J Asthma*, 2005, 42: 879–83
10. Korevaar DA, Westerhof GA, Wang J et al: Diagnostic accuracy of minimally invasive markers for detection of airway eosinophilia in asthma: A systematic review and meta-analysis. *Lancet Respir Med*, 2015; 3: 290–300
11. Schneider A, Gindner L, Tilemann L et al: Diagnostic accuracy of spirometry in primary care. *BMC Pulm Med*, 2009, 9: 31
12. Haccuria A, Michils A, Michiels S, Van Muylem A: Exhaled nitric oxide: A biomarker integrating both lung function and airway inflammation changes. *J Allergy Clin Immunol*, 2014; 134: 554–59
13. de Gouw HW, Hendriks J, Woltman AM et al: Exhaled nitric oxide (NO) is reduced shortly after bronchoconstriction to direct and indirect stimuli in asthma. *Am J Respir Crit Care Med*, 1998; 158: 315–19
14. Piacentini GL, Bodini A, Peroni DG et al: Reduction in exhaled nitric oxide immediately after methacholine challenge in asthmatic children. *Thorax*, 2002; 57: 771–73
15. Wang Z, Pianosi PT, Keogh KA et al: The diagnostic accuracy of fractional exhaled nitric oxide testing in asthma: A systematic review and meta-analyses. *Mayo Clin Proc*, 2018; 93(2): 191–98
16. Lin H, Cao Z, Ye Q: Tracheal diverticulum: A case report and literature review. *Am J Otolaryngol*, 2014; 35: 542–45
17. Shah M, Joshi JM: Tracheal diverticulum. *Indian J Chest Dis Allied Sci*, 2012; 54: 39–40
18. Moller GM, ten Berge EJ, Stassen CM: Tracheocele: A rare cause of difficult endotracheal intubation and subsequent pneumomediastinum. *Eur Respir J*, 1994; 7: 1376–77