

## Review Article

DOI: 10.22114/ajem.v0i0.78

**Blunt, Penetrating and Strangulating; Suicidal, Homicidal, Accidental and Sport-Related Neck Injuries: a Case Series and Literature Review**Devendra Richhariya<sup>1\*</sup>, Vivekanshu Verma<sup>1</sup>, Yatin Mehta<sup>2</sup>

1. Department of Emergency &amp; Trauma care, Medanta-The Medicity, Gurugram, India.

2. Institute of Critical Care &amp; Anesthesiology, Medanta-The Medicity, Gurugram, India.

\*Corresponding author: Devendra Richhariya; Email: drdev10@yahoo.in

Published online: 2018-01-09

**Abstract**

**Introduction:** Presentation of neck injuries in ER can be with or without neurological deficit. Trauma victims with multiple injuries should be examined for neck injuries as these injuries are potentially life threatening. Further neck movement should be restricted by applying the cervical collar until further radiological investigations rule out the spine injury. Early identification and treatment of neck injuries whether spine, vascular, or muscular injury improve the morbidity and mortality in polytrauma patients.

**Case presentation:** In a series of case presentations of neck injuries through various modes, the first case of neck injury was related to road traffic accident presented with neck pain and paraplegia. In the second case, neck injury was due to suicidal hanging presented with ligature mark over the neck. Third case was related to Indian traditional sport-related neck injury presented with severe neck pain stiffness. In the fourth case, neck injury was due to gunshot and presented with bullet entry wound and quadriparesis.

**Conclusion:** Neck injury in the absence of associated injuries is rarely seen after blunt and penetrating trauma, but can result in devastating outcomes if left unrecognized. A high index of suspicion and early intervention are critical.

**Key words:** Emergency department; Literature; Neck injuries; Wounds, nonpenetrating; Wounds, penetrating

**Cite this article as:** Richhariya D, Verma V, Mehta Y. Blunt, Penetrating and Strangulating; Suicidal, Homicidal, Accidental and Sport-Related Neck Injuries: A Case Series and Literature Review. Adv J Emerg Med. 2018;2(3): e33.

**INTRODUCTION**

Emergency medicine, trauma, anesthesia, radiology, and otolaryngology literature on penetrating and blunt neck trauma is enormous, often contradictory and concentrates more on specific diagnostic modalities and surgical treatment rather than initial management. Neck injuries are usually overlooked while examining multi-system trauma that leads to significant morbidity and mortality due to obstruction of airways, infection, and also due to vascular injuries. So, a high index of suspicion is required for neck injuries because these are life threatening equally for whether they are blunt or penetrating (1, 2). Here we report 4 cases with neck trauma following various mechanism as an excuse to discuss more about this topic.

**CASE PRESENTATION****Case 1: Roadside accident cervical spine dislocation causing quadriparesis**

A conscious-orientated young male was brought into the emergency room (ER) in the early morning by roadside attendants after head-on collision;

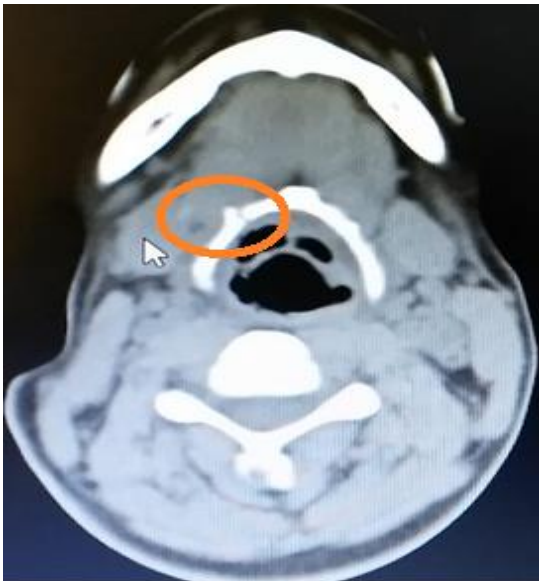
patient was unable to move all of the four limbs, and was complaining of severe neck pain. Cervical spine (C-spine) collar was applied, patient underwent computed tomography (CT) scan of head and neck, and was diagnosed to have cervical spine fracture dislocation at C6-C7 level. Patient was admitted under neurosurgery team and underwent spinal reduction and fixation and steroids were administered for spinal cord injury.

**Case 2: Suicidal hanging by ligature causing strangulation around neck**

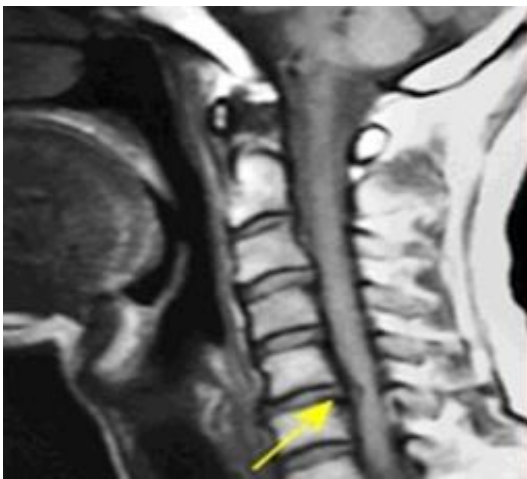
A young married female in altered mental state arrived in ER with alleged history of fall in bathroom with an abraded bruise on neck from right to left obliquely suggestive by a ligature mark (Furrow sign or Parchment paper sign). Cervical spine collar was applied, and she underwent CT scan of head and neck and was diagnosed as having suffered hyoid bone fracture (figure 1) with hypoxic brain injury.

**Case 3: Indian traditional sports-related compressive spinal injury**

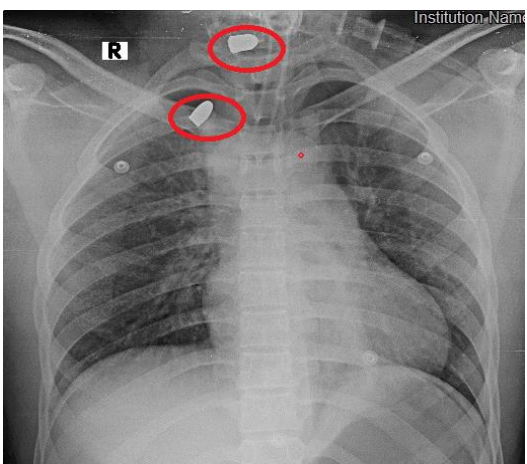
A 40-year-old female villager participating in



**Figure 1:** Hyoid bone fracture due to strangulation by ligature



**Figure 2:** Sagittal T1 view of cervical MRI demonstrate herniated disc of C5-C6

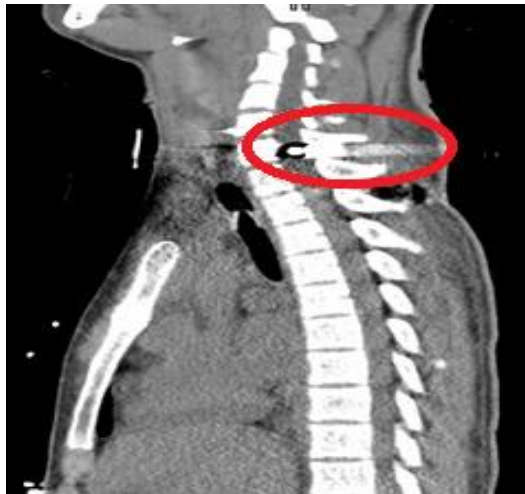

**Figure 3:** Chest X-ray with two bullets detected in neck region

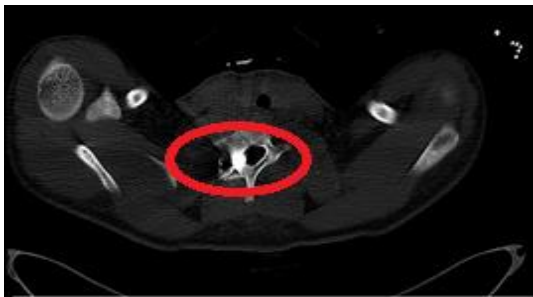
Mataki Race (Matki Race is a sport they play in Indian villages where the participants run with traditional clay pitchers filled with water on their heads) came into the ER with severe neck pain and stiffness in the neck for a few hours. On arrival she was conscious, orientated, and co-operative. Pain score = 6/10 (verbal quantitative scale); blood pressure (BP) = 130/80 mmHg; pulse rate (PR) = 90/min; respiratory rate (RR) = 14/min; O<sub>2</sub>saturation (SPO<sub>2</sub>) = 98% on room air. On physical examination, petechial over right side of neck was seen. There was also paravertebral tenderness in neck accompanied with numbness in right shoulder and paracervical region. Reduced power was noted in right upper limb (4/5) with poor hand grip in right hand. The power of left upper limb and both lower limbs was normal (5/5). Differential diagnosis of injury due to “axial compressive loading” was taken into account as follows: Cervical vertebral compression fracture; cervical vertebral dislocation; cervical ligament tear; cervical muscle tear; cervical intervertebral disc protrusion; cervical radiculopathy; and cervical neuropathy. The patient underwent magnetic resonance imaging (MRI) which revealed cervical disc protrusions at C4-C5 level posterocentrally and mild disc bulge at C5-C6 levels (figure 2). Lmbar disc protrusions at L1-L2, L3-L4, L4-L5 level posterocentrally and annular tear with mild ligamentum flavum thickening were also noted. Patient was managed conservatively after being admitted to the neurosurgery ward with hard cervical collar and bed rest on hard bed, analgesics, and physiotherapy were given. Patient recovered and was discharged after two days.

**Case 4: Homicidal gunshot victim suffering quadriplegia from bullet entry wound in anterior neck**

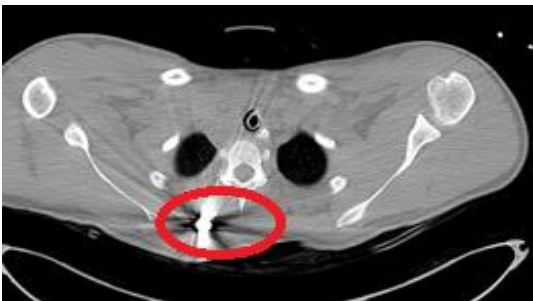A young 17-year-old male in conscious-orientated state was brought into ER early morning from the Medical College hospital with bleeding gunshot entry wound from anterior region of neck, and with quadriplegia. He was on inotropic support for shock with BP=90/50 mmHg, PR=128/min, SPO<sub>2</sub>=98% on two liters of nasal oxygen. Patient was able to speak his name and was orientated in time and place. Cervical spine protection was done with log roll on spine board with cervical collar, and hemostasis of bleeding wound in neck was achieved. Blood was arranged for transfusion and inotropic support was started in view of suspected hemorrhagic shock. Working differential diagnosis was neurogenic, spinal, or hemorrhagic shock for this condition. Portable Chest X-ray revealed two bullets in neck region in situ (figure 3).



**Figure 4:** lateral view of Cervical CT scan with bullet impinging in spinal vertebral canal in C7-D1 neural foramina in neck region



**Figure 5:** Transverse section at C7-D1 foramina of cervical CT scan demonstrate a bullet in right side neck region



**Figure 6:** Cervical CT scan transverse section with bullet right side back of chest region

After performing primary trauma survey and lifesaving management, the patient underwent whole body CT scan with CT-angiography of head and neck vessels. Head CT scan reported focal hyperdensity in the interpenduncular cistern that is meant post-traumatic subarachnoid hemorrhage. Cervical spine CT scan reported metallic foreign bodies consistent with bullet fragment in right pedicle of C7 vertebral body, pointing toward and extending in the right half of the spinal canal at the same level (figure 4). Transverse section of CT scan revealed

comminuted fracture in right lateral half of C7 vertebral body, its right pedicle, transverse process, superior, and inferior facets and central lamina. Bullet was encroaching upon superior margin of right C7-D1 neural foramina (figure 5). Tiny bullet fragment is also noted in right antero-inferior corner of C6. Tiny bullet fragment was also seen in prevertebral soft tissue anterior to C7 vertebral body, another bullet fragment was noted in intramuscular plane medial to upper margin of scapula (figure 6). There was cricoid cartilage fracture with dislocation of the right cricoarytenoid joint. Right vertebral artery occlusion was noted in the cervical fragment. Patient underwent tracheostomy and cervical spine fixation after removal of bullets by neurosurgeon on the same day. Patient showed slow improvement in quadriplegia, but weakness in limbs persisted.

#### DISCUSSION

For the purpose of this article, neck trauma is divided into penetrating, blunt, and strangulation injury. The neck is a complex anatomical region containing important vascular, aerodigestive, and neurological structures that are relatively unprotected. Penetrating neck injury represents 5%–10% of all trauma cases. It is important for clinicians to be familiar with management principles, as mortality rates can be as high as 10%. Penetrating neck injury describes trauma to the neck that has breached the platysma muscle. The pathophysiology of penetrating injury varies with mechanism of injury (2).

Penetrating spine injury (PSI) forms the third most common cause of spine injury next to road traffic accidents and fall. Gunshot wound (GSW) forms the major bulk of PSI. Due to easy availability of firearms and antisocial behavior, GSW, which is predominant in military populations, is now increasingly seen in civilized society (3).

Gunshot wounds may be divided into low- and high-energy wounds. A high velocity military assault rifle fired into the neck at 50 feet will produce greater extensive tissue damage than a low velocity handgun fired from the same distance. In addition to energy, multiple other factors determine the extent of injury, including mass, shape, fragmentation of the missile, and tissue penetration (4).

Low-energy shotgun pellets follow erratic trajectories along the tissue pathway of least resistance and may result in pellet emboli to the heart or other organs. Stab wounds may leave a seemingly innocent wound, but the depth and path of penetration are difficult to predict. Descriptions

regarding blade size, depth of penetration, and body position at impact may be misleading (5).

If any cervical vascular injury is suspected on the basis of trauma survey, Doppler of the neck vessels and CT angiography can be done to exclude a life-threatening situation. Radiological evaluation of neck injuries may include radiographic series and/or CT scan (6).

All penetrating neck wounds are potentially very dangerous and require emergency treatment. Penetrating vascular injuries from a variety of mechanisms can rapidly be fatal. While any large vessel injury can lead to hemorrhagic shock, carotid injuries can cause rapidly expanding hematoma that may lead to life-threatening airway obstruction. Injury to the jugular venous system can produce an air embolism, causing hypotension and respiratory distress (7). Blunt neck trauma may initially go unrecognized due to more noticeable damage to the chest, abdomen, or head. Common mechanisms include a motor vehicle collision involving an unrestrained passenger decelerating against the dash (the padded dash syndrome), or a shoulder harness creating shearing injury to the neck (7). Systematic examination of neck should be done, including inspection, palpation, and auscultation, with careful search for cervical spine tenderness, subcutaneous emphysema, tracheal deviation, and laryngeal fracture. A common sign of potential injury is a seatbelt mark. Auscultate carotid arteries for any bruits. Penetrating injury to the neck mostly gives rise to cervical vascular injuries. On the other hand, intimal disruption, dissection, and thrombosis of blood vessels can occur if there is any blunt injury to the neck or any traction injury to shoulder (7). Blunt carotid injury can present either with coma or without neurologic finding. Complexity and proximity define the challenging anatomy of the neck. The respiratory, vascular, nervous, gastrointestinal, skeletal, endocrine, and lymphatic systems all traverse the narrow confines of this space. The structures of the anterior neck are especially vulnerable. Helmet should be removed carefully to provide extra care to a potentially unstable cervical spine (7).

For their operative evaluation and management, surgical consultation is required for penetrating injuries in the neck, especially those with active bleeding, expanding hematoma, or with airway obstruction. These injuries should not be explored in ER or by those who are not trained to manage such injuries. Upper extremities should be examined carefully and any neurological deficit should be documented and evaluated carefully. The

spine must be protected from excessive mobility to prevent development of or progression of a deficit. The cervical spine is protected with a cervical collar. Spinal injuries mostly occur in the cervical region, followed by the thoracic, thoracolumbar, and lumbosacral area. When airway management is necessary, the cervical collar is opened, and a team member manually restricts motion of the cervical spine (7).

Blunt neck trauma is less frequent and dramatic, yet it is equally life-threatening. While vascular injuries predominate in penetrating trauma, airway injuries prevail in blunt trauma. Blunt neck injuries are often initially overlooked in the setting of multi-system trauma. The neck is a complex framework of supporting fascial planes, musculature, and cartilage injury which result in minimal physical findings and delayed complications. Early evaluation and management are required to avoid significant morbidity and mortality from delayed infection, airway obstruction, or cerebrovascular events (8).

Cervical or upper thoracic spinal cord (T6 and above) injury give rise to impairment of the descending sympathetic pathways, loss of vasomotor tone, and sympathetic innervation to the heart, cause vasodilation of visceral and peripheral blood vessels, pooling of blood, and, consequently, hypotension. Patients do not have tachycardia in response to hypovolemia due to loss of sympathetic innervation to heart. However, when shock is present, it is still necessary to rule out hemorrhagic shock as the most common type of shock in trauma patients that can be present in addition to neurogenic shock. The physiologic effects of neurogenic shock are not reversed with fluid resuscitation alone, and use of vasopressors with moderate volume replacement and atropine may be used to treat hypovolemia and bradycardia. Patients present with flaccidity of muscles and absence of reflexes immediately after spinal cord injury, but after a period of time spasticity occurs (8).

#### CONCLUSIONS

Neck is a complex area consisting of fascia, musculature, cartilages, great vessels, and a complex system of innervation. In the setting of multi-system trauma, neck injuries are often missed and give rise to delayed complications like infections, airway obstruction, or cerebrovascular events. So, systematic early evaluation and management of neck injuries is required to decrease the morbidity and mortality in victims of multi-system trauma.

**ACKNOWLEDGEMENTS**

We acknowledge hard work of all the doctors and nursing staff of the emergency and trauma care department of Medanta the Medicity Gurugram India. We express our thanks to staff who were involved in the management of these cases.

**AUTHORS' CONTRIBUTION**

All the authors fulfil the criteria of authorship based on the recommendations of the International

Committee of Medical Journal Editors (ICMJE). Corresponding author is an Editor in Chief of Text book of Emergency & Trauma Care.

**CONFLICT OF INTEREST**

None declared

**FUNDING**

None declared

**REFERENCES**

1. Walters BC, Hadley MN, Hurlbert RJ, Aarabi B, Dhall SS, Gelb DE, et al. Guidelines for the management of acute cervical spine and spinal cord injuries: 2013 update. *Neurosurgery*. 2013;60 Suppl 1:82-91.
2. Vishwanatha B, Sagayaraj A, Huddar SG, Kumar P, Datta RK. Penetrating neck injuries. *Indian J Otolaryngol Head Neck Surg*. 2007;59(3):221-4.
3. Kochhar LK, Shukul VK, Sharma R. Gun shot wound neck. *Indian J Otolaryngol Head Neck Surg*. 2004;56(1):49-50.
4. Patil R, Jaiswal G, Gupta TK. Gunshot wound causing complete spinal cord injury without mechanical violation of spinal axis: Case report with review of literature. *J Craniovertebr Junction Spine*. 2015;6(4):149-57.
5. Weller HJ. *Firearm investigation*. 5th ed. Delhi, India: Universal Law House; 2016.
6. Saito N, Hito R, Burke PA, Sakai O. Imaging of penetrating injuries of the head and neck: current practice at a level I trauma center in the United States. *Keio J Med*. 2014;63(2):23-33.
7. Richhariya D. *Textbook of Emergency & Trauma Care*. 1st ed: Jaypee Publishers; 2018.
8. Surgeons ACo. *ATLS - Advanced Trauma Life Support*. 10th ed 2018.