

Available online at [www.sciencedirect.com](http://www.sciencedirect.com)

ScienceDirect

journal homepage: [www.elsevier.com/locate/radcr](http://www.elsevier.com/locate/radcr)

## Case Report

# A rare case of anophthalmia without any family history and antenatal risk factors <sup>☆</sup>

Kreshnike Dedushi<sup>a</sup>, Fjolla Hyseni<sup>b</sup>, Juna Musa<sup>c</sup>, Kristi Saliaj<sup>d</sup>, Valon Vokshi<sup>e</sup>, Ali Guy<sup>f</sup>, Atiq Bhatti<sup>g</sup>, Abdur Rahman<sup>h</sup>, Muhammad Tahir<sup>i</sup>, Loran Rakovica<sup>j</sup>, Masum Rahman<sup>k</sup>, Jeton Shatri<sup>l,\*</sup>

<sup>a</sup> Clinical of Radiology, University Clinical Center of Kosovo. Faculty of Medicine, Department of Radiology, University of Prishtina, Kosovo

<sup>b</sup> Research Fellow, NYU Langone Health, New York, USA

<sup>c</sup> Department of General Surgery, Mayo Clinic, Rochester, MN, USA

<sup>d</sup> Mother Teresa Hospital, Tirana, Albania

<sup>e</sup> Department of Anesthesiology, University Clinical Center of Kosovo

<sup>f</sup> Clinical Assistant Professor, Department of Physical Medicine and Rehabilitation, New York University School of Medicine, NYU Medical Center, New York, USA

<sup>g</sup> Department of Neurosurgery, Biomedical Engineering and Physiology, Mayo Clinic, Rochester, MN, USA

<sup>h</sup> Department of Medicine, Life and Care Hospital Ltd, Dhaka, Bangladesh

<sup>i</sup> Medical Officer/General practitioners at Life Care International Hospital Islamabad

<sup>j</sup> Department of Gastroenterology, University Clinic of Kosovo, Prishtina, Kosovo

<sup>k</sup> Department of Neurosurgery, Mayo Clinic, Rochester, MN 55905, USA

<sup>l</sup> Clinical of Radiology, University Clinical Center of Kosovo. Faculty of Medicine, Department of Anatomy, University of Prishtina, Kosovo

## ARTICLE INFO

## Article history:

Received 26 July 2021

Revised 2 September 2021

Accepted 4 September 2021

## Keywords:

Anophthalmia

Micro-ophthalmia

Magnetic resonance imaging

Teratogens

## ABSTRACT

Anophthalmia is a rare genetic disorder. It is defined as the absence of one or both eyes in a patient. It can be unilateral or bilateral. Based on the absence of anatomical structures, it is divided into primary, secondary, and degenerative anophthalmia. It occurs in an infant with a diabetic mother or any exposure to teratogens. Most of the patients have a positive family history of anophthalmia or related genetic disorder. Its diagnosis is crucial as there is a similar condition called micro ophthalmia. Sometimes it is difficult to differentiate between severe microphthalmia and anophthalmia. We present a case of a 5-day-old infant diagnosed with bilateral anophthalmia. In the majority of the cases of bilateral anophthalmia

<sup>☆</sup> Competing Interest: The authors declare that they have no conflict of interest.

\* Corresponding author. Jeton Shatri.

E-mail address: [jeton.shatri@uni-pr.edu](mailto:jeton.shatri@uni-pr.edu) (J. Shatri).

<https://doi.org/10.1016/j.radcr.2021.09.001>

1930-0433/© 2021 Published by Elsevier Inc. on behalf of University of Washington. This is an open access article under the CC BY-NC-ND license (<http://creativecommons.org/licenses/by-nc-nd/4.0/>)

the patients usually have a positive family history of antenatal exposure to teratogenic substances. But in our case, no family history or antenatal teratogenic exposure was noted.

© 2021 Published by Elsevier Inc. on behalf of University of Washington.

This is an open access article under the CC BY-NC-ND license

(<http://creativecommons.org/licenses/by-nc-nd/4.0/>)

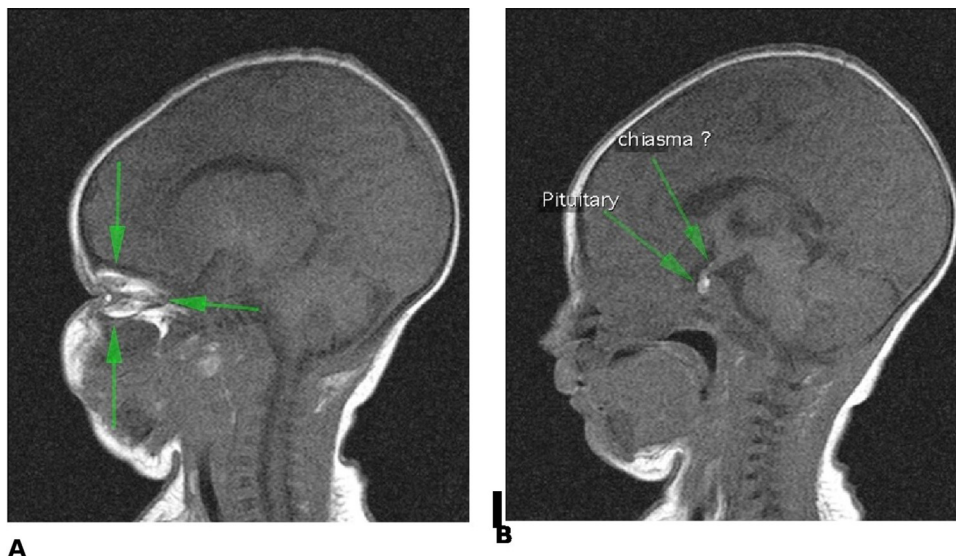
## Introduction

Anophthalmia is the medical term for the absence of one or both eyes. Is a rare anomaly that occurs as a result of insults to the developing eye(s) during the first 8 weeks of life [1]. The prevalence of congenital anophthalmia ranges from 3 to 14 per 100,000 population. It is the result of insufficient development or complete regression of the optic vesicle [2]. Congenital anophthalmia applies to all cases where there are no visible ocular remnants, and there is the complete absence of ocular structures and neuroectodermal tissues inside the sockets. Congenital anophthalmia is a disease of rare occurrence and has been described for the first time in 1547 by Lycosthenes and in 1609 by Schenk [3]. Mann classified anophthalmos as three distinct types: primary, secondary anophthalmos, and Consecutive or degenerative anophthalmos [4]. Primary anophthalmia is caused by failure of formation of the optic pit and optic outgrowths from the forebrain, occurs from arrested development of the eyes in early fourth week of gestation, in 0.18-0.4 cases per 10.000 births [5]. This produces an absence of the lens, optic nerves, and chiasma. Secondary abnormalities of the orbit occur, with orbital growth universally retarded to some extent. Extraocular muscles may be absent and the optic foramen size is often decreased, which occurs from in utero events [5]. degenerative anophthalmia: there is initial ocular development but again for some reason starts to degenerate - possibly from lack of blood supply to the eye and surrounding structures. Anophthalmia may be difficult to differentiate, both clinically and by imaging, from

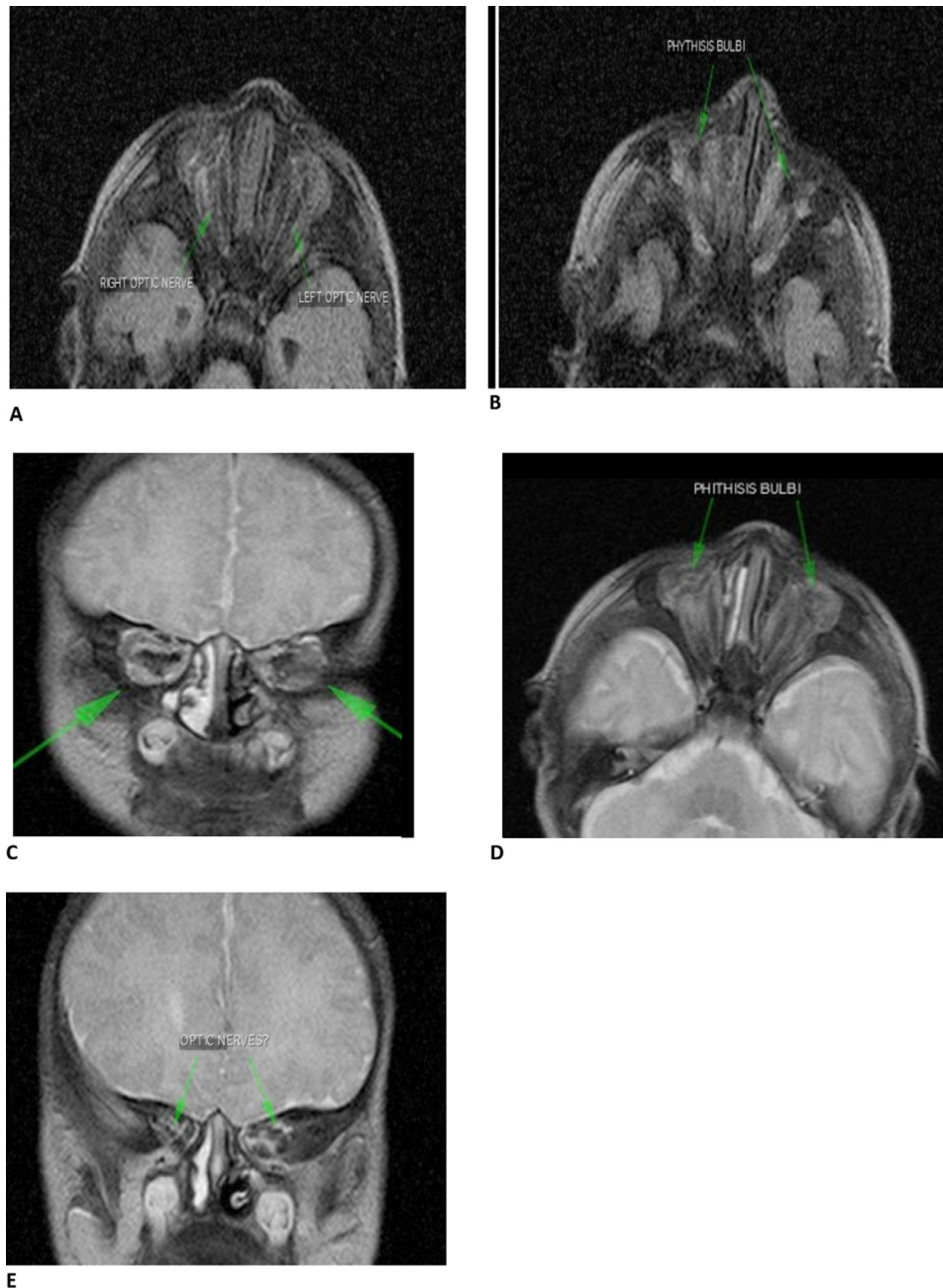
severe microphthalmia [6]. When bilateral, anophthalmia has a high rate of associated central nervous system abnormalities, septo-optic dysplasia, corpus callosum dysgenesis, and pituitary anomalies [7]. However, it is always confused with the term clinical anophthalmia or severe microphthalmia. It is clinically difficult to distinguish severe microphthalmia from anophthalmia in routine ophthalmology practice. Small conjunctival fornices, narrowed palpebral fissure range and common hypoplasia of the periocular soft tissues frequently accompany microphthalmia or anophthalmia. Microphthalmia refers to a reduction in the size of the globe because of congenital developmental disorder or acquired causes. Microphthalmia can be classified as severe, simple, and complex depending on the anatomical appearance of the globe and the degree of reduction in the axial length. Clinical findings, as well as imaging modalities and genetic analysis, are important in making the definitive diagnosis.

## Case presentation

A male infant (5 days) was born at 40 weeks of gestation to a healthy non-consanguineous parent (21 years old mother and 24 years old father). Fetal ultrasound had not noticed any change in the child's development. There was no history of diabetes or any congenital pathology. The mother had no breakthrough processes, nor reported taking medication, alcohol, tobacco, or drugs during pregnancy. Physical examination after birth revealed a birth weight of 3.450 g and a body length of 49 cm. The initial ophthalmic exam of the infant patient re-



**Fig. 1 – (A) Sagittal T1-weighted images visible optic nerve. (B) T1-weighted signal hyperintensity is a common finding at magnetic resonance imaging of the sellar region.**



**Fig. 2 – Magnetic resonance of Brain. (A), (B) Axial plane FLAIR (fluid-attenuated inversion recovery) demonstrates atrophic optic nerve. (C) Coronal plane T2-weighted shows atrophic optic nerve. (D) Axial T2-weighted image show phthisis bulbi. (E) T2-weighted coronal plane demonstrates atrophic optic nerve.**

vealed small palpebral fissures with the absence of both eyes and other eye structures and the absence of extrinsic eye muscles. Brain magnetic resonance imaging (MRI) was performed to exclude any accompanying central nervous system malformation. T1-weighted images (WI), T2-WI, and post-contrast T1-WI were obtained at axial, sagittal, and coronal planes. Orbital MRI was also performed to show intraorbital structures. The globes were found to be quite small and cystic in appearance. Cornea, lens, and sclera were not observed (Fig. 1). On close inspection of brain MR images, we found some more

useful images for orbits. Although both optic nerves were hypoplastic in the intraconal orbital space, the optic nerves were not found at the distal optic canal in both patients (Fig. 2). Since optic nerves/chiasma are visible, we believe this is not a true primary anophthalmia case, but bilateral congenital phthisis bulbi (perhaps secondary to bilateral heavy-form persistent hyperplastic primary vitreous [PHPV]). Congenital phthisis bulbi may well be called “secondary anophthalmia” or “degenerative anophthalmia.” Brain MRI did not show any accompanying central nervous system abnormality. One more thing

for this case is the reason of bright T1-signal on the entire hypophysis (instead of normally being present only at posterior hypophysis hyperintensity), [Figure 2](#).

## Discussion

Anophthalmia is a spectrum of disorders that include true anophthalmia, and clinical anophthalmia, also called severe microphthalmia, in which a small amount of ocular tissue can be found in the orbit on neuroimaging, even though the globe may appear to be absent externally. Once the diagnosis has been established, systematic examination with both ocular and systemic imaging tests (ultrasonography, computed tomography, MRI) should be performed to rule out additional neurological associations. Our patient presented with bilateral anophthalmia. The defect is often bilateral, similar to that in our patient. Reviewing the literature, we couldn't find any case of anophthalmia in Kosovo prior to this case. Although anophthalmia is closely linked to genetic and familiar causes, our patient had no family history of a similar condition [8].

The genetic mechanisms underlying the pathogenesis of anophthalmia/microphthalmia (AM) are complex and involve multiple inheritance patterns, including recessive and dominant autosomal, as well as an X-linked inheritance mode for syndromic anophthalmia. Non-syndromic anophthalmia, has been associated with sporadic de novo arising mutations, as we suspect is the case in our patient. Nevertheless, discerning the inheritance pattern can be challenging, as AM is presented with a wide range of genotypic and phenotypic variability, even in members of the same family. This phenotypic heterogeneity may arise due to mosaicism, genetic modifiers and environmental factors, that modify the expression of proteins crucial to the normal development of the eye.

Anophthalmia/Microphthalmia (AM) has a multifactorial etiology, involving chromosomal abnormalities, monogenic mutations and environmental factors. Chromosomal anomalies involve aneuploidy, triploidy, translocations, deletions and duplications and are responsible for 20%-30% of the cases, whereas monogenic mutations including missense, nonsense, deletions, insertions and splice-site mutations, account for the rest. These loss-of-function mutations affect numerous genes that are heavily implicated in the pathogenesis of AM, with the most important ones including SOX2, PAX6, RAX, OTX2 and CHX10, that code for transcription factors incorporated in the initiation of the eye field and STRA6, ALDH1A3 and RAR $\beta$  involved in the retinoic acid signaling pathway. Studies suggest that around 75% of cases with severe bilateral anophthalmia, as was present in our patient, stem from monoallelic loss-of-function mutations in SOX2 or OTX2 genes and biallelic loss-of-function mutations in the STRA6 gene.

Our patient's condition was diagnosed after birth and antenatal ultrasonography failed to pick the anomaly. A possible reason for not picking the anomaly antenatal is the old equipment used in rural health care centers. Magnetic resonance imaging scans facilitate the diagnosis of anophthalmia. MRI scans show the absence of a globe within the orbit although soft amorphous tissue may be seen. Imaging findings of a clin-

ical anophthalmia case series in which there were a variety of intraorbital, intracranial, and craniofacial anomalies [6]. Congenital microphthalmos and aplasia of the optic nerves, chiasm, and tracts in an otherwise healthy subject were detected [8]. The difference in our case was that the patient has anophthalmia instead of microphthalmos.

The main reason our patient is unique, usually, most of the patients with anophthalmia have a positive family history of anophthalmia or related genetic disorder or any exposure to antenatal risk factors such as diabetes mellitus and teratogens like drugs. But our patients had no such history or antenatal exposure.

## Conclusion

Anophthalmia is a rare genetic disorder. When it is bilateral, most of the time the patient has positive family history or exposure to teratogens during pregnancy. This case is a rare case where a patient with anophthalmia has a negative family history and no exposure to any antenatal teratogen. Due to its similar appearance, it is sometimes difficult to differentiate from clinical anophthalmia also called severe microphthalmia. Investigations like MRI and ultrasound can help to differentiate between them.

## Patient consent

Written consent for publication was obtained from the patient.

## REFERENCES

- [1] James E. Dimmick, *Developmental Pathology of the Embryo and Fetus* Lippincott, Lippincott Williams & Wilkins (November 1, 1991), pp. 875, <https://www.amazon.com/Developmental-Pathology-Embryo-Fetus-Dimmick/dp/0397510403>
- [2] Verma AS, FitzPatrick DR. Anophthalmia and microphthalmia. *Orphanet J Rare Dis* 2007;2(1):1–8. doi:10.1186/1750-1172-2-47.
- [3] Hesselberg C. Congenital Bilateral Anophthalmia. *Acta Ophthalmol* 1951;29(2):183–9. doi:10.1111/j.1755-3768.1951.tb05859.x.
- [4] M I. *Developmental Abnormalities of the Eye*. 2nd ed. JB. Philadelphia; 1957.
- [5] Nagarajan M, Sharbidre KG, Bhabad SH, Byrd SE. MR imaging of the fetal face: comprehensive review. *Radiographics* 2018;38(3):962–80. doi:10.1148/rg.2018170142.
- [6] Albernaz VS, Castillo M, Hudgins PA, Mukherji SK. Imaging findings in patients with clinical anophthalmos. *Am J Neuroradiol* 1997;18(3):555–61.
- [7] Jana M, Sharma S. Bilateral anophthalmia with septo-optic dysplasia. *Oman J Ophthalmol* 2010;3(2):86. doi:10.4103/0974-620x.64233.
- [8] Pearce WG, Nigam S. Primary anophthalmos histological and genetic features. *Can J Ophthalmol* 1974;9(1):141–5.