



Factors associated with subcentimeter pulmonary nodule outcomes followed with computed tomography imaging in oncology patients

André Queiroz de Moraes^a, Thiago Pereira Fernandes da Silva^{a,*},
 Juliana Cristina Duarte Braga^a, Diogo Fábio Dias Teixeira^a, Paula Nicole Vieira Pinto Barbosa^a,
 Fábio José Haddad^a, Jefferson Luiz Gross^a, Pablo Rydz Pinheiro Santana^b, Bruno Hochhegger^c,
 Edson Marchiori^d, Marcos Duarte Guimarães^a

^a Department of Imaging, A.C. Camargo Cancer Center, São Paulo, SP, Brazil

^b Department of Imaging, Beneficência Portuguesa Hospital, São Paulo, SP, Brazil

^c Department of Imaging, Universidade Católica do Rio Grande do Sul, Porto Alegre, RS, Brazil

^d Department of Imaging, Universidade Federal Fluminense, Niterói, RJ, Brazil

HIGHLIGHTS

- PNs with irregular, lobuled or spiculated margins exhibited faster growth than PNs with regular, smooth margins.
- Malignancy was significantly associated with male gender, a colorectal cancer diagnosis and advanced stage disease.
- Oncologic patients should have an individualized CT follow-up strategy, as the rate of malignant pulmonary nodules is higher than in the general population.

ARTICLE INFO

Keywords:

Small lung nodules
 Pulmonary metastasis
 Thoracic CT scan

ABSTRACT

Introduction: Technological advancements in computed tomography (CT) have enabled the frequent detection of small pulmonary nodules (PNs), especially in patients with an oncologic history. It is important the malignant versus benign etiology of PNs be determined. The aim of the present study was to evaluate the behavior and clinical/radiological characteristics of subcentimeter PNs detected by CT in oncologic patients.

Methods: An observational, longitudinal, retrospective and single-center study was conducted with a sample of 100 patients with a diagnosis of a primary malignant solid tumor outside of the lungs who developed indeterminate subcentimeter PNs (n = 251) detected on consecutive thoracic CT scans from 2015 to 2017. Follow-up CTs for each patient were examined in each of three periods (0–3 months, 3–6 months, and 6 months to 1 year).

Results: In our study sample, 28 patients (28 %) showed one or more signs suspicious of pulmonary metastasis, including ≥ 50 % PN growth, nodule growth followed by size reduction in patients undergoing chemotherapy, and the appearance of multiple nodules. The majority (56 %) of the PNs were detected during the 3–6-month follow-up CT scan. PNs with irregular, lobuled, or spiculated margins exhibited faster growth than PNs with regular, smooth margins. Malignancy of PNs was found to be significantly associated with being male, a primary colorectal cancer diagnosis, and advanced stage disease.

Conclusion: Our findings reinforce the necessity of an individualized CT follow-up strategy for patients with an oncologic history, as well as the importance of early nodule screening, with the inter-scan interval being dependent on the primary neoplasm.

1. Introduction

Differentiation between benign and malignant nodules is critical

upon the detection of subcentimetric pulmonary nodules (PNs) in cancer patients. In patients with a history of cancer, solid PNs greater than 5 mm in diameter have an increased chance of malignancy, whereas PNs

* Corresponding author at: A.C. Camargo Cancer Center – Departamento de Imagem. Rua Professor Antônio Prudente, 211, Liberdade. São Paulo, SP, 09015-010, Brazil.

E-mail addresses: pfdsthiago@gmail.com, thiago.fernandes@accamargo.org.br (T.P.F. da Silva).

<https://doi.org/10.1016/j.ejro.2020.100266>

Received 23 June 2020; Accepted 24 August 2020

2352-0477/© 2020 The Authors.

Published by Elsevier Ltd.

This is an open access article under the CC BY-NC-ND license

(<http://creativecommons.org/licenses/by-nc-nd/4.0/>).

that are less than 5 mm in diameter and those juxtaposed to the visceral pleura or interlobar fissures that are smaller than 15 mm are usually benign (scars, granulomas, or intraparenchymal lymph nodes) [1]. In addition to size and location, features such as irregular contours and doubling times in the range of 30–720 days increase indicate increased malignancy risk [1].

Common origins of metastatic PNs include primary cancers of the breast, head and neck, skin (melanoma), colon, kidney, muscle (sarcomas), and germ cells [2,3]. These metastases are usually manifestations of hematogenous disease spread. However, sometimes PNs are found in patients with a known primary malignancy elsewhere [4]. Surgical resection of lung metastases of various origins can prolong survival substantially and, in some patients, be curative [5]. Thus, metastatic PN resection has become a widely accepted treatment approach [6].

The type and stage of the primary neoplasia also influences a PN's risk of malignancy [7]. Patients with high-grade cancers, and those with lymph node metastasis in particular, are at increased risk of malignant PNs [8]. Hence, the monitoring of small emergent PNs (i.e. < 10 mm or < 5 mm) can improve oncological control and thus, potentially, improve survival outcomes when such PNs can be resected. It is important to note that, even in cancer patients, most PNs smaller than 10 mm in diameter that are within 10–20 mm of the pleura are benign [9].

PNs can be identified by chest x-ray or computed tomography (CT) examinations. In 2009, Munden et al. published an early study on the use of multidetector CT to evaluate pulmonary subcentimeter nodules in cancer patients, demonstrating that almost 30 % of the observed nodules were malignant and amenable to being identified within the first year of follow-up.¹ Multidetector CT is now being used commonly to detect pulmonary micronodules, 1–2 mm in diameter [1,10]. The aim of the present study was to evaluate the behavior and clinical/radiological characteristics of subcentimeter PNs detected by multidetector CT in oncologic patients.

2. Materials and methods

2.1. Study design and patient population

This was an observational, longitudinal, retrospective and single-center study carried out after submission and approval by the Institutional Research Ethics Committee of the A.C. Camargo Cancer Center. Consecutive follow-up chest CT scans were performed on cancer patients between the years of 2015 and 2017. The inclusion criteria were: PNs < 10 mm; a cancer diagnosis confirmed by histopathological analysis; CT follow-up for ≥ 1 year with segmented analyzes between 0–3 months, 3–6 months, and 6 months to 1 year; and at least three chest CT scans within a year. The follow-up time period refers to the time since the patient's original staging diagnosis by CT. The exclusion criteria were: calcified nodules; and primary lung cancer diagnosis. The study patients were stratified according to demographic (age and gender), clinical (cancer diagnosis, staging and therapeutic status), and the following radiological criteria: PN size (≤ 4 mm; 4.1–6.0 mm; and 6.1–9.0 mm), growth rate (≥ 50 % and < 50 %), margin regularity (regular or spiculate), and location (lobe, laterality, and central or peripheral).

2.2. CT and characterization of PNs

Images were acquired on a 16-channel scanner (Brilliance CT Big Bore, Philips Medical Systems (Cleveland), Inc., USA) with a 16×0.75 collimation technique, 0.938 pitch, 0.5 s rotation, 1-mm slice thickness, 1-mm slice interval, 120 Kv, and 200 mA/slice. Only 1 mm-thick images from the same scanner were considered. PNs were measured with electronic calipers, always on the same computer. The largest transverse diameter was taken as the PN size.

Malignancy was defined based on histological diagnosis of biopsied or surgically resected specimens. The need for follow-up due to

malignancy suspicion was signified by PN growth of ≥ 50 % in the largest transverse diameter, growth followed by a reduction during chemotherapy, and the appearance of multiple PNs with a secondary tomographic aspect. The PNs were stratified into three subgroups: (I) PNs that grew; (II) stable PNs; and (III) PNs that shrank, whether or not under chemotherapy.

All exams were reviewed by two physicians specialized in radiology and diagnostic imaging, using high-precision electronic calipers for measurement and always using the same software on the same computer. Doubtful cases were resolved by consensus. The procedures and materials described herein were used in accordance with established protocols and controlled studies published in the literature.

2.3. Data analysis

Absolute (N) and relative (%) frequencies are reported. Chi-square (all frequency data and group comparisons with ≥ 5 observations per group) and Fisher's exact tests (all others) were used. All data obtained were stored in a database and analyzed with SPSS version 20.0.0. Results with a type I error probability ≤ 0.05 were considered statistically significant.

3. Results

3.1. Sample characteristics

The study sample of 100 patients included 53 women (53 %) and 47 men (47 %) with a mean (\pm standard deviation) age of 57.8 ± 15.9 years (median, 59 years). The most common primary tumor types were colorectal neoplasms, breast neoplasms, head and neck neoplasms, and sarcomas. The full distribution of primary tumor types are reported in Table 1.

A total of 251 PNs were evaluated in 332 CT scans, and the average evaluated PN size was 4.767 mm. The 251 evaluated PNs included 131 that were ≤ 4 mm (52.2 %), 75 that were 4.1–6.0 mm (29.9 %), and 45 that were 6.1–9.0 mm (17.9 %) in diameter. With respect to PN change over time, 175 (69.7 %) remained stable, 50 (19.9 %) showed an increase in their dimensions, 20 (8 %) showed a reduction in their dimensions, and 6 (2.4 %) showed a dimension increase followed by a reduction. Of the 50 PNs that grew, 44 (88 %) increased in size by > 50 %. Most of the PNs that grew (28/50, 56 %) showed the most

Table 1

Frequency distribution of primary solid tumor malignancy type in the present study sample.

Cancer type	N	%
Colorectal	18	18.0
Breast	17	17.0
Head and neck	17	17.0
Sarcoma	10	10.0
Gastric	7	7.0
Pancreas	5	5.0
Ovary	4	4.0
Urothelial	4	4.0
Lymphoma	3	3.0
Melanoma	2	2.0
Testicle	2	2.0
Cervical	2	2.0
Other (below)	9	9.0
Vulva	1	1.0
Prostate	1	1.0
Desmoid	1	1.0
Choroidal melanoma	1	1.0
Esophagus	1	1.0
Thyroid	1	1.0
Skin, non-melanoma	1	1.0
Endometrium	1	1.0
Penis	1	1.0
Total	100	100.0

pronounced increase in size within the 3–6-month follow-up period ($p < 0.0001$ vs. other follow-up periods); only 3/50 (6 %) grew within the first 3 months and 19/50 (38 %) grew after 6 months. An example of a subcentimetric PN that increased in size over a 4-month interval in a patient diagnosed with rectal adenocarcinoma is shown in Fig. 1.

Growth of PNs was observed more frequently in men (14/47, 42.4 %) than in women (7/53, 15.2 %), showing a significant effect of sex ($p = 0.04$). Meanwhile, the frequency of size-stable PNs did not differ significantly between men (33/47, 70 %) and women (46/53, 87 %; $p > 0.05$). Notably, ≥ 50 % growth was markedly more common in patients undergoing a chemotherapy regimen (37/38, 97 %) than in patients not currently undergoing a chemotherapy regimen (7/12, 58 %; $p = 0.002$) PNs that exhibited growth were most frequently encountered in patients with advanced disease compared to observations in patients with a stable disease, reduction, or growth followed by reduction during chemotherapy (Table 2).

A total of 20 PNs (8 % of all PNs examined) shrank, of which 17 (85 %) were in patients undergoing chemotherapy, showing a statistically significant association between chemotherapy and PN shrinking behavior ($p < 0.0001$ vs. not in chemotherapy) (Fig. 2). In 11 (91.7 %) of the 12 PNs that underwent biopsy or surgical excision, the result was

positive for malignancy (metastasis). Among these 11 PNs, 10 (90.9 %) were growing and one (9.1 %) was stable ($p = .006$).

The most prevalent primary tumors in our cohort of patients with PNs were colorectal cancer and breast cancer. Ultimately 16/45 (35.5 %) and 8/40 (20.0 %) PNs detected in patients diagnosed with colorectal cancer and breast cancer, respectively, were determined to be malignant. As shown in Table 3, we observed very significant association between primary tumor type, between these two major cancer types, and the growth, stability, or reduction behavior observed. PNs in patients with primary colorectal tumors showed a greater tendency toward >50 % growth, whereas PNs in patients with primary breast tumors showed greater tendency toward >50 % reduction or stability (Table 3). PNs with irregular, spiculated, and lobulated margins more frequently showed growth than PNs with regular margins (Table 4).

4. Discussion

In the present study, we found that about a third of the cancer patients followed developed subcentimeter PNs with characteristics suspicious for malignancy. Malignancy of PNs was found to be significantly associated with being male, a primary colorectal cancer diagnosis, and

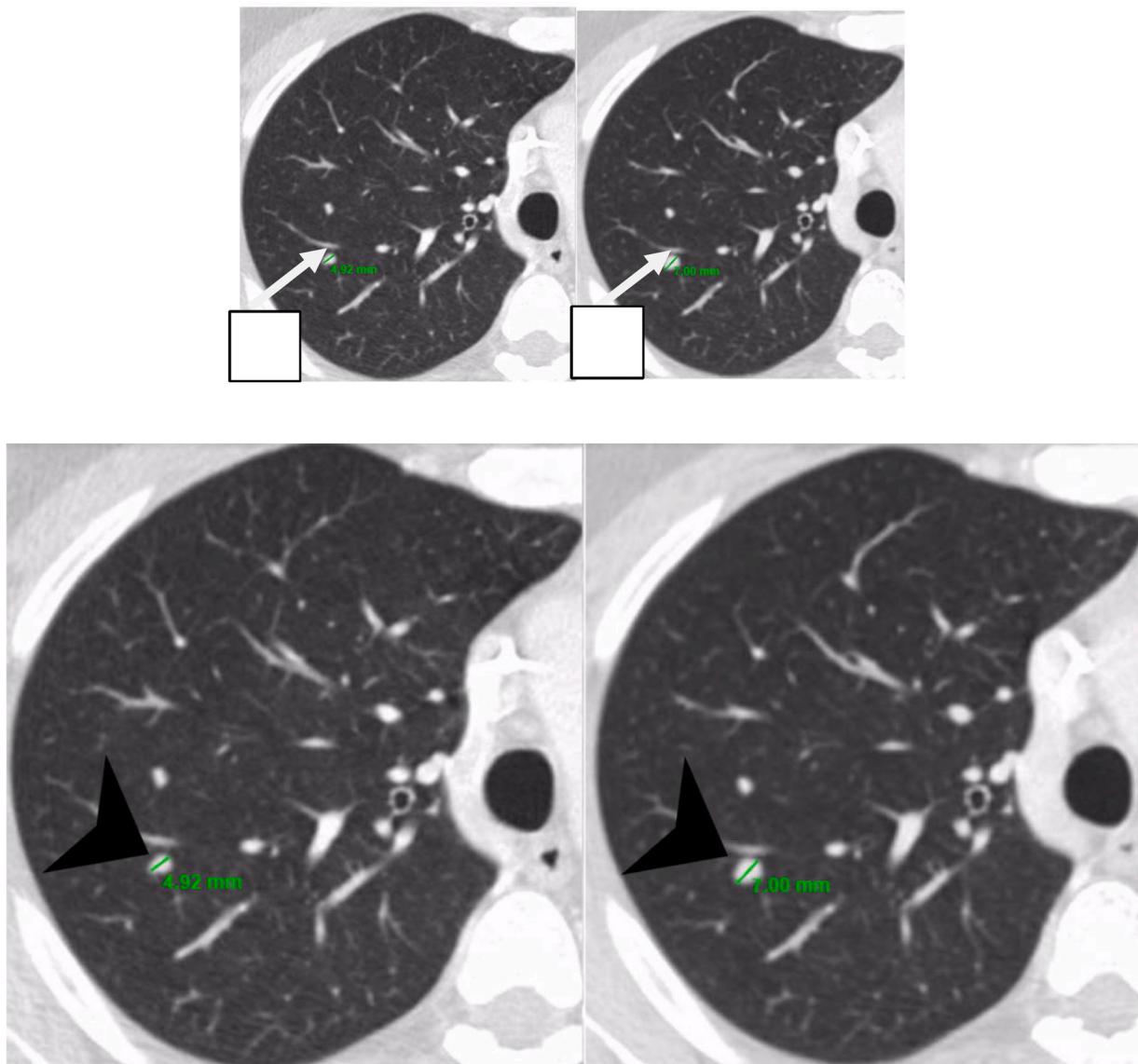


Fig. 1. Non-enhanced chest CT, axial view, lung window, of the right upper lobe in a 28-year-old patient diagnosed with rectal adenocarcinoma. In 4 months, a PN (arrows) detected in a follow-up scan grew from 4.9 mm (A) to 7.0 mm (B), an increase of <50 %.

Table 2
Analysis of associations between disease staging at the time of diagnosis and PN evolution.

Evolution	Total by evolution	Disease stage			Pp-value
		Localized (stage I/II)	Advanced (stage III/IV)	Unknown	
Stable	175 (69.7 %)	55 (31.4 %)	87 (49.7 %)	33 (18.9 %)	<.001
Growth	50 (19.9 %)	7 (14.0 %)	40 (80.0 %)	3 (6.0 %)	
Reduction	20(8.0 %)	11 (55.0 %)	3 (15.0 %)	6 (30.0 %)	<.001
Growth + reduction during chemotherapy	6 (2.3 %)	4 (66.7 %)	2 (33.3 %)	0 (0.0 %)	<.001
All evolutions	251 (100 %)	77 (100 %)	132 (100 %)	42 (100 %)	<.001

All *p* values are from Fisher's exact tests. Within evolution groups, *p* values reflect association between disease stage and the outcome of evolution. For the all evolutions totals, *p* value represents significance of overall association between disease stage and evolution.

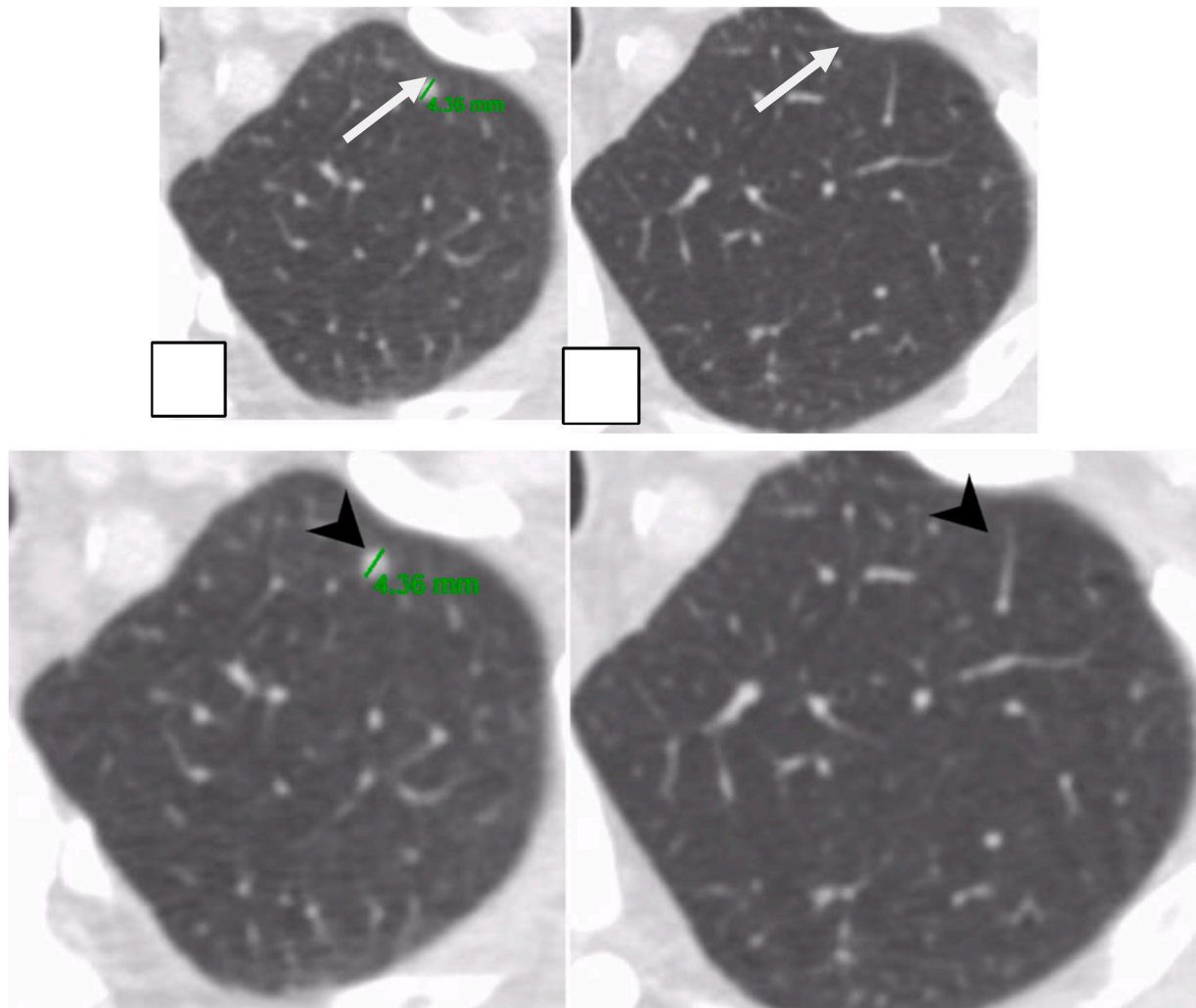


Fig. 2. Non-enhanced chest CT, axial view, lung window, of left upper lobe in a 72-year-old patient diagnosed with pancreatic adenocarcinoma. Over a 6-month period during which the patient underwent chemotherapy, a PN (arrows) detected in a monitoring scan was found to have reduced in size from 4.4 mm (A) to a punctate, non-measurable nodule (B).

advanced stage disease. PNs with irregular, lobulated, or spiculated margins were more likely to be malignant than PNs with regular margins. Most of the suspicious PNs grew during the 3–6-month CT follow-up period. In our series, PNs were most commonly associated with colorectal cancer and breast cancer, with the former being significantly more frequently associated with malignant PNs than the latter. Our finding of 35.5 % of PNs in patients with colorectal cancer with suspicion to being malignant is not consistent with Nordholm-Carstensen et al.'s [8] reported 9 % indeterminate nodules (with an average 10.8 % malignancy rate among those) for PNs in patients diagnosed with colorectal cancer.

Various recommendations have been useful for improving imaging cost-effectiveness for healthcare systems in the management of PNs. Recommendations regarding the diagnostic and therapeutic management of PNs of an undetermined nature depend upon patient history. According to the consensus of the Fleischner Society, CT follow-up may be unnecessary for patients with PNs without a history of cancer owing to their low incidence of PN malignancy (<1 % for PNs <6 mm), whereas 12-month CT follow-up is recommended for patients at risk of malignancy due to a history of cancer [11]. Meanwhile, according to the LUNG-RADS® guidelines provided by the American College of Radiology, smokers should be screened for lung neoplasms to allow for early

Table 3
Analysis of associations between cancer type and neoplasm behavior (outcome).

Neoplasm behavior	Cancer type, N (%)		p-value ^P
	Colorectal	Breast	
Growth > 50 %	16 (35.6 %)	0 (0 %)	<.0001
Growth < 50 %	1 (2.22 %)	0 (0 %)	>.999
Stable	26 (57.8 %)	32 (80 %)	.0364
Reduction < 50 %	2 (4.44 %)	0 (0 %)	.4958
Reduction > 50 %	0(0 %)	8 (20 %)	.0016
Total, all behaviors	45 (100 %)	40 (100 %)	<.0001

All *p* values are from Fisher's exact tests. Within each neoplasm behavior group, *p* values reflect association between cancer type and the outcome variable of growth/reduction behavior. For the all behavioral totals, *p* value represents significance of overall effect of cancer type on evolution outcome.

detection. In one such high-risk population lung cancer screening program, Wood et al. observed a high proportion of benignity among PNs that exhibit size stability [12].

In contrast, a consensus has not been established regarding the management of PNs in patients with a known malignancy. The incidence of malignant subcentimeter PNs is substantially higher in patients with a history of cancer compared to the general population [9] and the discovery of subcentimeter PNs in patients who are undergoing or who have completed treatment for cancer can be cause for severe patient anxiety.¹ Large-scale studies of PN management for oncology patients require substantial financial support due to the need for serial CT imaging as well as the involvement of researchers equipped to handle the particular technical and operational complexities involved, including the difficulty associated with standardizing follow-up examinations, the great biological variability of tumors, the influence of various cancer treatment modalities, and the difficulty of obtaining sufficient tissue material from microlesions for diagnostic confirmation.

In the present study we analyzed the characteristics of a total 251 PNs, found in 100 patients. Importantly, though a relatively small portion of PNs overall (*n* = 44, 17.5 %) showed >50 % growth during follow-up, they were predominantly (37/44, 84.1 %) observed in patients undergoing chemotherapy. Most these PNs were found to be of an advanced disease stage (stage III, *n* = 20; and stage IV, *n* = 16). Of the 12 biopsies of these PNs that were performed, 11 were found to be malignant, and only 1 of these 11 metastatic PNs did not show growth in sequential follow-up CT scans.

We observed a potential relationship between growth and malignancy risk. That is, the number of PNs exhibiting substantial growth (>50 %) and the size of 6.1–9 mm represented 35.6 %. In a study examining small PNs in patients who were considered low-risk for cancer, Gould et al. [14] found that the probability of malignancy was only 0.2 % for PNs smaller than 3 mm and 0.9 % for PNs that were 4–7 mm in size. In a study of smokers considered to be at high risk of lung cancer, but with no history of neoplasms prone to metastasis, Horeweg et al. [15] found that PNs that were >5 mm and 5–10 mm had malignancy rates of 0.4 % and 1.3 %, respectively. By comparison, in our current study of only cancer patients, the probability of malignancy was 13 % for PNs ≤4.0 mm and 22.7 % for PNs between 4.1 mm and 6.0 mm.

Table 4
Analysis of associations between PN margin type and PN evolution (outcome).

Evolution Class	N (%)	Margin type, N (%)				<i>p</i>
		Regular	Irregular	Spiculated	Lobulated	
Stable	175 (69.7 %)	156 (75.0 %)	11 (36.7 %)	3 (60 %)	5 (62.5 %)	<.0001
Growth	50 (19.9 %)	32 (15.4 %)	13 (43.3 %)	2 (40 %)	3 (37.5 %)	.0011
Reduction	20 (8.0 %)	17 (8.2 %)	3 (10 %)	0 (0 %)	0 (0 %)	.9091
Increase, then reduction during chemotherapy	6 (2.4 %)	3 (1.4 %)	3 (10 %)	0 (0 %)	0 (0 %)	.0826
Total, all classes	251 (100 %)	208 (100 %)	30 (100 %)	5 (100 %)	8 (100 %)	.0010

All *p* values are from Fisher's exact tests. Within each evolution class, *p* values reflect association between margin type and the outcome variable of evolution. For the evolution classes totals, *p* value represents significance of overall effect of margin type on evolution outcome.

With respect to follow-up time, in a study of micro-PNs (≤4.0 mm) in size, Munden et al. [1] detected micro-PNs suspicious of malignancy in 29/102 cancer patients, and 90 % of those that showed PN disease progression were found within the first year of follow up. In our study, with a similar sample (100 patients with history of cancer outside of the lungs and PNs 2–9 mm in diameter), expressive growth (increase > 50 %) was observed in 17.5 % (44/251) of PNs. For PNs that were ≤4.0 mm, 4.1–6.0 mm, and 6.1–9.0 mm, expressive growth was observed in 12.2 % (16/131), 17.3 % (13/75), and 33.3 % (15/45) of PNs, respectively. Proportionately, these data are quite similar given that our data reflect only 1 year of follow-up whereas Munden et al.'s study included 2 years of follow-up [1]. Our finding of most PN growth occurring in the 3–6-month follow-up period (including 56 % of the cases) was also consistent with Munden et al.'s report [1]. Notably, Munden et al. found that 85 % of PNs that shrank were found in patients undergoing chemotherapy, inferring a probable malignant etiology [1].

Histopathological analysis, the definitive way to discern whether a PN is benign or malignant, is not feasible in all cases. Manhire et al. [13] recommended performing lung biopsies for diagnostic confirmation when there are multiple PNs, which portends a greater chance of metastasis, or when PNs show progression despite prolonged remission of the primary disease. However, many of the cases in the present study wherein subcentimeter PNs were suspicious for malignancy would not have met these criteria. Our study affirms the practice of using CT to detect subcentimeter PNs and characterizing them in most cases. Notwithstanding, positron emission tomography-CT can be used to clarify the nature of detected PNs whose characterization is elusive in cancer patients [16].

The present study has a couple noteworthy limitations. Firstly, due to the retrospective nature of this work, the CT examination intervals were not standardized and staging information was incomplete in some cases [1]. Secondly, because of the added complexity and challenges associated with obtaining sufficient tissue for histopathology when following very small PNs, lung biopsies were not performed in many cases for the present sample of subcentimeter PNs.

In conclusion, we found that about one third of cancer patients followed at our center developed CT-detectable subcentimeter PNs that presented with characteristics considered suspicious for malignancy. Patient characteristics found to be significantly associated with a higher frequency of malignancy were being male, a primary oncological diagnosis of colorectal cancer, and advanced disease stage. Malignancy was also significantly associated with PNs with irregular, lobulated, or spiculated margins, compared to the incidence observed for PNs with regular margins. Most of the PNs that were suspicious for metastases showed growth during the CT follow-up period of 3–6 months after the first CT (staging) examination. These findings reinforce the importance of early CT follow-up within the first year of follow-up of oncological patients diagnosed with a solid tumor cancer.

CRedit authorship contribution statement

André Queiroz de Morais: Conceptualization, Methodology, Validation, Investigation, Writing - original draft, Formal analysis. **Thiago**

Pereira Fernandes da Silva: Methodology, Data curation, Writing - review & editing, Visualization, Formal analysis. **Juliana Cristina Duarte Braga:** Data curation, Visualization. **Diogo Fábio Dias Teixeira:** Data curation, Visualization. **Paula Nicole Vieira Pinto Barbosa:** Supervision, Resources, Validation, Writing - review & editing. **Fábio José Haddad:** Supervision, Resources, Validation. **Jefferson Luiz Gross:** Supervision, Resources, Validation. **Pablo Rydz Pinheiro Santana:** Supervision, Resources, Validation. **Bruno Hochhegger:** Supervision, Resources, Validation. **Edson Marchiori:** Supervision, Resources, Validation. **Marcos Duarte Guimarães:** Writing - review & editing, Supervision, Project administration, Funding acquisition.

References

- [1] R.F. Munden, J.J. Erasmus, H. Wahba, N.S. Fineberg, Follow-up of small (4 mm or less) incidentally detected nodules by computed tomography in oncology patients: a retrospective review, *J. Thorac. Oncol.* 5 (2010) 1958–1962, <https://doi.org/10.1097/JTO.0b013e3181f2636e>.
- [2] J.B. Seo, J.G. Im, J.M. Goo, M.J. Chung, M.Y. Kim, Atypical pulmonary metastases: significance of pulmonary nodules on thin-section CT in patients with significance of radiologically detected indeterminate pulmonary nodules in spectrum of radiologic findings, *Radiographics* 21 (2001) 403–417, <https://doi.org/10.1148/radiographics.21.2.g01mr17403>.
- [3] D. Ost, A. Fein, Management strategies for the solitary pulmonary nodule, *Curr. Opin. Pulm. Med.* 10 (2004) 272–278, <https://doi.org/10.1097/01.mcp.0000130322.11513.c8>.
- [4] K.W. Kim, K.M. Krajewski, J.P. Jagannathan, et al., Cancer of unknown primary sites: what radiologists need to know and what oncologists want to know, *AJR Am. J. Roentgenol.* 200 (2013) 484–492, <https://doi.org/10.2214/AJR.12.9363>.
- [5] R.N. Younes, A.L. Fares, J.L. Gross, Pulmonary metastasectomy: a multivariate analysis of 440 patients undergoing complete resection, *Interact. Cardiovasc. Thorac. Surg.* 14 (2012) 156–161, <https://doi.org/10.1093/icvts/ivr076>.
- [6] U. Pastorino, M. Buyse, G. Friedel, et al., International Registry of Lung Metastases. Long-term results of lung metastasectomy: prognostic analyses based on 5206 cases, *J. Thorac. Cardiovasc. Surg.* 113 (1997) 37–49, [https://doi.org/10.1016/S0022-5223\(97\)70397-0](https://doi.org/10.1016/S0022-5223(97)70397-0).
- [7] L.E. Quint, C.H. Park, M.D. Iannettoni, Solitary pulmonary nodules in patients with extrapulmonary neoplasms, *Radiology* 217 (2000) 257–261, <https://doi.org/10.1148/radiology.217.1.r00oc20257>.
- [8] A. Nordholm-Carstensen, P.A. Wille-Jørgensen, L.N. Jørgensen, H. Harling, Indeterminate pulmonary nodules at colorectal cancer staging: a systematic review of predictive parameters for malignancy, *Ann. Surg. Oncol.* 20 (2013) 4022–4030, <https://doi.org/10.1245/s10434-013-3062-y>.
- [9] M. Hanamiya, T. Aoki, Y. Yamashita, S. Kawanami, Y. Korogi, Frequency and significance of pulmonary nodules on thin-section CT in patients with extrapulmonary malignant neoplasms, *Eur. J. Radiol.* 81 (2012) 152–157, <https://doi.org/10.1016/j.ejrad.2010.08.013>.
- [10] D. Ost, A.M. Fein, S.H. Feinsilver, Clinical practice. The solitary pulmonary nodule, *N. Engl. J. Med.* 348 (June (25)) (2003) 2535–2542, <https://doi.org/10.1056/NEJMcp012290>.
- [11] H. MacMahon, D.P. Naidich, J.M. Goo, et al., Guidelines for management of incidental pulmonary nodules detected on CT images: From the Fleischner society 2017, *Radiology* 284 (2017) 228–243, <https://doi.org/10.1148/radiol.2017161659>.
- [12] D.E. Wood, G.A. Eapen, D.S. Ettinger, et al., Lung cancer screening, *J. Compr. Canc. Netw.* 10 (2012) 240–265. PMID: 22308518.
- [13] A. Manhire, et al., Guidelines for radiologically guided lung biopsy, *Thorax* 58 (11) (2003) 920–936, <https://doi.org/10.1136/thorax.58.11.920>.
- [14] Michael K. Gould, et al., Evaluation of patients with pulmonary nodules: when is it lung cancer? ACCP evidence-based clinical practice guidelines, *Chest J.* 132 (3 suppl) (2007) 108S–130S, <https://doi.org/10.1378/chest.07-1353>.
- [15] N. Horeweg, J. van Rosmalen, M. Heuvelmans, et al., Lung cancer probability in patients with CT-detected pulmonary nodules: a pre-specified analysis of data from the NELSON trial of low-dose CT screening, *Lancet Onc* 15 (2014) 1332–1341, [https://doi.org/10.1016/S1470-2045\(14\)70389-4](https://doi.org/10.1016/S1470-2045(14)70389-4).
- [16] L. Evangelista, A. Panunzio, R. Polverosi, F. Pommeri, D. Rubello, Indeterminate lung nodules in cancer patients: pretest probability of malignancy and the role of 18F-FDG PET/CT, *AJR Am. J. Roentgenol.* 202 (2014) 507–514, <https://doi.org/10.2214/AJR.13.11728>.