

# Subcutaneous implantable cardioverter-defibrillator update allows for unexpected diagnosis of paroxysmal atrioventricular block causing recurrent syncope



Louisa O'Neill, MD, PhD, Kris Gillis, MD, PhD, Jean-Yves Wielandts, MD, PhD, Benjamin De Becker, MD, Rene Tavernier, MD, PhD, Jean-Benoit Le Polain De Waroux, MD, PhD

*From the Department of Cardiology, AZ Sint-Jan Hospital, Bruges, Belgium.*

## Introduction

The subcutaneous implantable cardioverter-defibrillator (S-ICD) SMART Pass (SP) algorithm (Boston Scientific, Marlborough, MA) is a high-pass filter (ranging from 8 to 9 Hz) that enables accurate sensing and heart rate estimation and reduces the risk of inappropriate shocks associated with T-wave oversensing.<sup>1</sup> To prevent tachyarrhythmia undersensing, this algorithm automatically disables in the setting of low signal amplitude ( $\leq 0.25$  mV) associated with intermittent long intervals ( $> 1.4$  seconds) or in the event of a prolonged asystole ( $> 10$  seconds). When either of these criteria are met, the SP is deactivated and a 44-second subcutaneous electrocardiogram (S-ECG) tracing is captured (20 seconds prior to the event and 24 seconds after the event).<sup>2</sup> In clinical practice, the vast majority of unintended SP deactivations are thought to be related to premature ventricular contractions or other transient changes in amplitude potentially causing intermittent undersensing.<sup>3</sup> However, until very recently, this was impossible to confirm during in-office device check, as no ECG recordings during episodes of SP deactivation were directly viewable from the programmer. Nevertheless, the tracing could be extracted upon request to Boston Scientific technical service or from stored episodes of the latitude platform whenever remote monitoring is used.

Recently, Boston Scientific released the SMR-5 update, which contains, among several important patient safety features, an enhanced version of the SP. This enhanced algorithm was modified to extend the threshold count for low-amplitude beats from 5 contiguous low-amplitude beats up to 7 contiguous low-amplitude beats, while maintaining the other characteristics of the prior version (2 long intervals of

## KEY TEACHING POINTS

- The subcutaneous implantable cardioverter-defibrillator SMART Pass (Boston Scientific) may reduce the risk of inappropriate shocks associated with T-wave oversensing and automatically disables in the setting of low signal amplitudes or prolonged asystole.
- Until recently, subcutaneous electrocardiogram (S-ECG) traces associated with episodes of SMART Pass deactivation were not available for review from the programmer.
- A recent update has allowed for direct visualization of S-ECG traces associated with SMART Pass deactivation on the programmer. This may provide the clinician with important diagnostic information that may have implications for management.

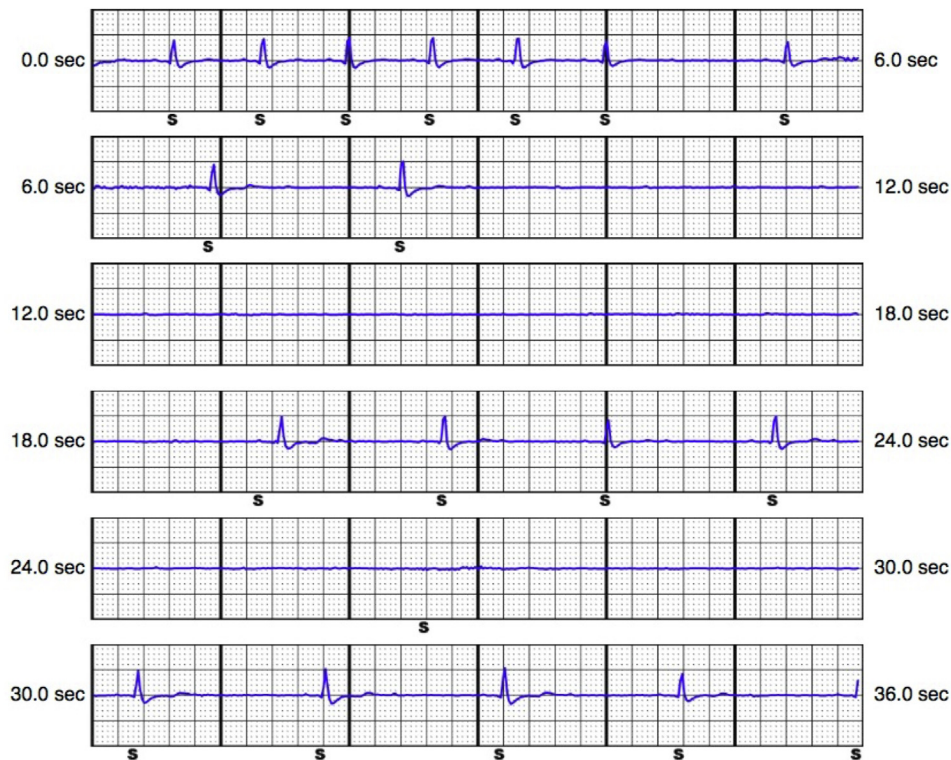
the last 5 intervals). Accordingly, this new version makes the deactivation monitor less sensitive to amplitude changes while maintaining arrhythmia sensitivity and specificity. Also, there is a correction of a software issue where SP is disabled after leaving “MRI” or “Induction” mode. Finally, SP deactivation episodes are now directly viewable on the programmer. We report here the case of a patient in whom the updated SMR-5 version of the SP algorithm allowed for the unexpected diagnosis of episodes of paroxysmal atrioventricular (AV) block.<sup>4</sup>

## Case report

A 30-year-old man received an S-ICD (Boston Scientific; model A219, lead model 3401) after a resuscitated out-of-hospital cardiac arrest owing to ventricular fibrillation. Over the prior few years, he experienced several episodes of abrupt syncope. However, all previous cardiac work-up, including several ECGs, up to 7-day Holter monitoring, echocardiography, coronary angiography, and

**KEYWORDS** S-ICD; ICD; SMART Pass; Bradycardia; Pacemaker (Heart Rhythm Case Reports 2023;9:59–60)

Funding Sources: None. Disclosures: Dr le Polain de Waroux reports nonsignificant speaker fees and honoraria for proctoring and teaching activities from Medtronic, Boston Scientific, Abbott, and Biotronik. **Address reprint requests and correspondence:** Dr Louisa O'Neill, Department of Cardiology, AZ Sint-Jan Hospital, Ruddershove 10, 8000 Bruges, Belgium. E-mail address: [louisa.oneill@azsintjan.be](mailto:louisa.oneill@azsintjan.be).



**Figure 1** SMART Pass (Boston Scientific) disabled episode directly obtained from the programmer and demonstrating an episode of paroxysmal atrioventricular block with a cardiac pause >10 seconds.

electrophysiologic study with pharmacological drug challenge, failed to reveal any specific etiology. Cardiac magnetic resonance imaging before ICD implantation, however, demonstrated a myocarditis with extensive subepicardial lesions in the inferolateral territory. During follow-up, the patient experienced recurrent syncope, several of which were associated with recurrent polymorphic ventricular tachycardia appropriately treated by S-ICD shocks. Subsequently the patient received an epicardial ablation, after which no ventricular arrhythmias were documented. Nevertheless, the patient continued to present with rare episodes of syncope. Baseline ECGs were normal at each evaluation, without evidence of conduction system disease. Since ICD implant, the SP was regularly found to be automatically deactivated. Hypothetically, this was attributed to frequent ventricular extrasystoles. However, at first device check after SMR-5 update, the tracing associated with the automatic SP deactivation demonstrated an episode of paroxysmal complete AV block with a pause >10 seconds (Figure 1). Given the patient reported a near-syncope episode that corresponded to the time of the stored event, and that the battery was depleted, the S-ICD was replaced by a transvenous system. Upon reimplantation, the patient remained asymptomatic.

## Discussion

Monitoring and recording of cardiac events is an important diagnostic feature for implanted cardiac devices. Furthermore,

S-ICD candidates, who are not felt to have an indication for pacing at the time of implantation, may develop a pacing indication over time. Recently Markman and colleagues<sup>4</sup> reported on the use of the SP algorithm to document possibly significant episodes of bradyarrhythmias. However, until now, these recorded S-ICD episodes were not directly viewable for the physician from the programmer. Tracings of SP deactivation were available only upon request to Boston Scientific technical service or through the latitude platform whenever remote monitoring was used to follow the patient. Since the recent introduction of the SMR-5 update, both episodes of automatic SP deactivation and untreated tachyarrhythmia episodes are directly viewable for the physician. This case report illustrates the importance of these enhanced monitoring capabilities for the management of S-ICD patients.

## References

1. Theuns DAMJ, Brouwer TF, Jones PW, et al. Prospective blinded evaluation of a novel sensing methodology designed to reduce inappropriate shocks by the subcutaneous implantable cardioverter-defibrillator. *Heart Rhythm* 2018; 15:1515–1522.
2. Boston Scientific SMART Pass Algorithm Inservice CRM-413109. 2016;AB:1–11. [https://www.bostonscientific.com/content/dam/bostonscientific/Rhythm%20Management/portfolio-group/EMBLEM\\_S-ICD/01\\_Home\\_Page/SICD-SMA RT-Pass.pdf](https://www.bostonscientific.com/content/dam/bostonscientific/Rhythm%20Management/portfolio-group/EMBLEM_S-ICD/01_Home_Page/SICD-SMA RT-Pass.pdf)
3. Masaki T, Hidekazu K, Tetsuji S, Naohiko T. Sudden depression of R-wave amplitude in a patient who underwent subcutaneous implantable cardioverter-defibrillator implantation. *HeartRhythm Case Rep* 2021;7:449–452.
4. Markman TM, Brozoski J, Bode W, Nazarian S. A novel use of a subcutaneous implantable cardioverter-defibrillator algorithm to detect bradycardia. *Heart-Rhythm Case Rep* 2022;8:164–166.