

Outcome of unstable fractures of metacarpal and phalangeal bones treated by bone tie

Jagannath B Kamath, Nikil Jayasheelan, Amaranth Savur, Rejith Mathews

ABSTRACT

Background: Unstable fractures of the metacarpal and phalangeal bones of the hand need surgical stabilization which should be rigid enough for early active mobilization. Conventional methods of open reduction and stabilization in the form of composite fixation or screws with or without plates have served the purpose but can be definitely improvised addressing both biological and mechanical principles of fixation.

Materials and Methods: 34 patients (29 males and 5 females) with an average age of 32 years (range 10–64 years) with unstable fractures of the metacarpal and phalangeal bones of hand who were treated with the modified bone tie between June 2009 and June 2013 were included in this study. 42 fractures, involving the 31 metacarpals and 11 phalanges were included. We have not used this technique in fractures involving the terminal phalanges. Thirty nine of the fractures were treated with K-wires along with the modified bone tie, whereas the other two cases were treated with modified bone tie alone and in one case the bone tie has been used along with the external fixator. The nature of injuries were Road Traffic Accident ($n = 24$), domestic/industrial injuries ($n = 8$) and blast ($n = 2$) injuries. Etiology was crush ($n = 24$), blunt ($n = 7$) and incised ($n = 3$) injuries, respectively. Twenty seven patients were involved with single fractures (either metacarpal or the phalanges), 6 patients had two fractures (both metacarpals or phalanges or one each of metacarpal and phalanx), and 1 patient had three fractures in this study. Dominant hand was involved in 14 patients (40%).

Results: We achieved excellent to good results in 83% of 42 fractures within an average period of 10 weeks. Postoperative grip strength of 85% was achieved with in an average period of 12 weeks. Twenty six (20 metacarpals and 6 phalanges) of the 42 fractures regained >85% of the total active movements (TAMs) compared to the contralateral side were considered excellent results. All patients were followed up for a minimum of 1 year.

Conclusion: This method of composite fixation allowed the surgeon to remove the concomitantly used axial K-wire at or <3 weeks clearly explaining the biomechanical basis for better results with minimum complication rates.

Key words: Bone tie, metacarpal, phalangeal bones, unstable fractures

MeSH terms: Hand, fracture, metacarpal bones, finger phalanges

INTRODUCTION

The majority of the fractures involving the metacarpal and the phalangeal bones of the hand can be treated by nonoperative methods. Almost

all of the open fractures and some of the closed oblique or comminuted fractures in the hand need surgical stabilization. The stabilization should be rigid enough for early mobilization for optimization of the final results. The conventional methods of stable fixation such as a single or double axial K-wire fixation though simple will not impart any rigidity in fixation, especially in terms of rotational stability. The other methods of more rigid fixation such as screws with or without plates are fraught

Department of Orthopedics, Kasturba Medical College, Manipal University (Affiliated to Manipal University), Mangalore, Karnataka, India

Address for correspondence: Dr. Nikil Jayasheelan, Department of Orthopedics, Kasturba Medical College, Manipal University, Mangalore - 575 001, Karnataka, India.
E-mail: dr_nikil@yahoo.com

Access this article online	
Quick Response Code:	Website: www.ijoonline.com
	DOI: 10.4103/0019-5413.181796

This is an open access article distributed under the terms of the Creative Commons Attribution-NonCommercial-ShareAlike 3.0 License, which allows others to remix, tweak, and build upon the work non-commercially, as long as the author is credited and the new creations are licensed under the identical terms.

For reprints contact: reprints@medknow.com

How to cite this article: Kamath JB, Jayasheelan N, Savur A, Mathews R. Outcome of unstable fractures of metacarpal and phalangeal bones treated by bone tie. Indian J Orthop 2016;50:316-21.

with technical difficulty with very little margin of error, and the catastrophic intraoperative complications are difficult to be bailed out by any other method. This makes one to look for simpler and surgeon friendly yet biomechanically uncompromising method of fixation in unstable fractures involving the hand. We describe our experience with a modified bone tie with or without K-wire technique for unstable metacarpal and phalangeal fractures.

MATERIALS AND METHODS

34 patients (29 males and 5 females) with an average age of 32 years (range 10–64 years) involving the fractures of metacarpal and phalangeal bones of the hand distal to the carpus who were treated with the modified bone tie between June 2009 and June 2013 were included in this study. 42 fractures, involving the 31 metacarpals and 11 phalanges were included. We have not used this technique in fractures involving the terminal phalanges. Thirty nine of the fractures were treated with K-wires along with the modified bone tie, whereas the other two cases were treated with modified bone tie alone and in one case the bone tie has been used along with the external fixator.

Natures of injury in the 34 patients were Road Traffic Accident ($n=24$), domestic/industrial ($n=8$), and blast ($n=2$) injuries, respectively. Etiology was crush ($n=24$), blunt ($n=7$) and incised ($n=3$) injuries, respectively. Topographic distributions of the 42 fractures in 34 patients are depicted in Figure 1. Twenty seven patients were involved with single fractures (either metacarpals or the phalanges), 6 patients had two fractures (both metacarpals or phalanges or one each of metacarpal and phalanx), and 1 patient had three fractures in this study. Dominant hand was involved in 14 patients (40%).

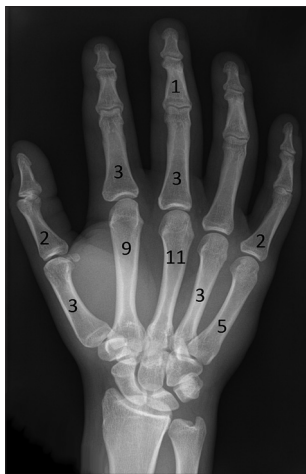

Figure 1: X-ray of hand anteroposterior view showing topographic distributions of the 42 fractures in 34 patients

The inclusion criteria were unstable, oblique, spiral and comminuted fractures which could not be managed by closed methods. The exclusion criteria were transverse fractures, pathological fractures, fractures with loss of bone, skin (which needed either split skin graft or flap cover), or concomitant flexor tendon injury or loss. However, cases associated extensor tendon injuries involving <50% (which did not change the postoperative mobilization protocol nor needed concomitant transarticular K-wire fixation) were included. Thirty nine fractures were open and three were closed in nature. Preoperative evaluation involved personal details like age, occupation, dominance of hand, avocational habits, in addition to a detailed clinical and radiological assessment of the injury of the soft tissue and skeleton involving the hand.

25 patients were operated on day 1 of the injury. Five cases were operated within 5 days of the injury, while two cases were operated after 3 weeks of the original injury. The surgery was performed by the same team headed by the senior author. The choice of anesthesia was brachial block ($n = 31$) unless there were concomitant injuries which needed general anesthesia ($n = 3$). The open wounds dictated the surgical incision and the exposure. Antibiotics were given for 7–10 days (Ceftriaxone 1 gm B.D for closed cases and metrogyl 500 mg B.D (IV) along with ceftriaxone for open cases) in all open fractures. Patients were closely followed up until the suture removal and later in the physiotherapy department every week by the surgeon. Active mobilization was started as soon as possible within the limits of patient's cooperation and compliance. However, the limb was immobilized between the periods of mobilization. Functional assessment, total active movements (TAMs), grip strength using jammer dynamometer, activities of daily living, as well as his or her ability to go back to preinjury occupation, were evaluated during the followup. Personal satisfaction including cosmetics was also enquired about in all patients during the final followup. All patients were followed up for a minimum period of 1 year after the surgery. The postoperative regime followed was early mobilization as dictated by the patient's pain tolerance. Single K-wire was removed at the end of 3 weeks in the first 9 cases and subsequent cases the K-wires were removed at the end of 2–2.5 weeks. However, patients were prescribed buddy strapping which was maintained for 2–3 weeks after K-wire removal.

Among the 42 fractures, thirty nine were treated with a single K-wire supplemented with the modified bone tie [Figures 2 and 3]. The technical details of the fixation using modified bone tie (with or without K-wire) [Figures 4 and 5] have been described and documented in literature¹ [Figure 6]. The device used for the fixation itself is a modification of a previously described technique.² Care was always taken to spare the metacarpophalangeal joint

being impaled by the K-wire through the extensor expansion while treating the metacarpal fractures, similarly the integrity of the proximal interphalangeal joint was not violated while treating the phalangeal fractures. Our preferred method of single K-wire insertion for metacarpal and proximal phalangeal fractures was that of Centrifugal proximal distal configuration (K-wire insertion from the fracture site first into the proximal and subsequently in the distal fragment).³ The same for the middle phalangeal fracture was in the form of centrifugal distal proximal, thus ensuring the preservation of integrity of the important joints of the digits for smooth postoperative mobilization. The K-wire in the metacarpal was central in its placement, while the same in the phalangeal fractures was oblique; the obliquity (radial to

ulnar or ulnar to radial) itself was determined by the fracture configuration. The single K-wire was left bent percutaneous for easy removal as an outpatient procedure.

RESULTS

All patients were followed up for a minimum of 1 year. The average time for the patients to return to their preinjury occupation was 6.5 weeks (range 5–14 weeks). Twenty six (20 metacarpals and 6 phalanges) of the 42 fractures regained >85% of the TAMs compared to the contralateral side were considered excellent results. Fifteen fractures (11 metacarpals and 4 phalanges) regained the TAM between 70% and 84% of the contralateral side were considered as good results. This was achieved with in an average of 10 weeks. The grip strength of 85% comparable to opposite hand was achieved within 12 weeks. Clinically there was no shortening or rotational malalignment in any of the patients. One patient (62 years old) had a poor result due to scar adherence resulting in only 45% of TAM. The fracture involved in this case was the shaft of the proximal phalanx of the mid finger. The patient declined further treatment (tenolysis) after reaching a plateau following physiotherapy.

We did not remove the bone tie or the stainless steel wire (S.S wire) because none of the patients had any issues related to tendon gliding or pain attributed to the implant. Three patients had superficial infections which were managed by the continuation of antibiotics. We did face breakage of S.S wire while tightening on the table in initial 2 cases which we rectified on the table by replacing the wire. Because of the




Figure 2: Photograph showing bone tie with a loop of 28 gauge stainless steel wire

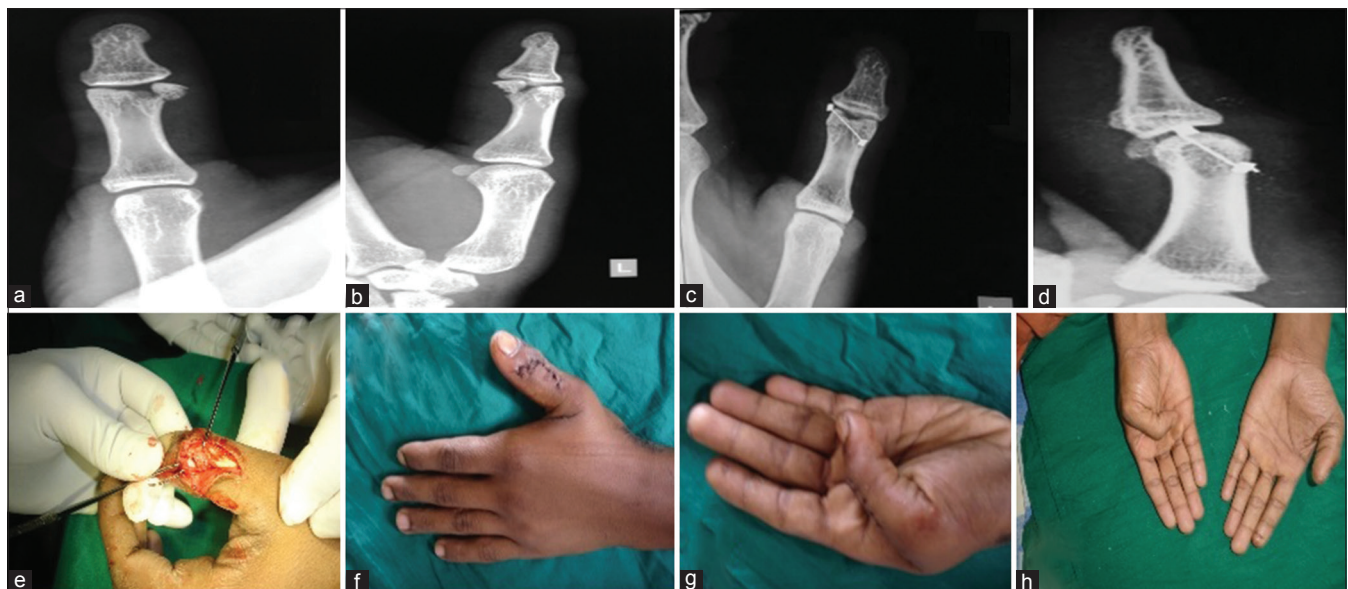

Figure 3: (a and b) X-ray of thumb anteroposterior and oblique views showing displaced condylar fracture of the head of the proximal phalanx of left thumb (c and d) Postoperative X-ray of the same patient fixed with bone tie (e) Intraoperative picture showing stainless steel wire being passed (f) Clinical photographs at 5th postoperative day showing surgical scar mark (g and h) Clinical photograph at 3 months followup showing range of motion

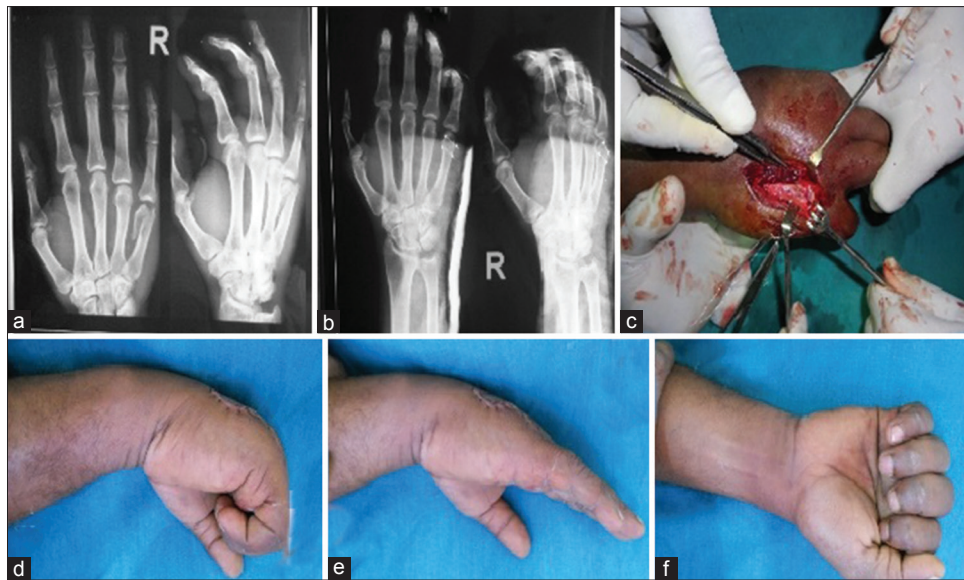


Figure 4: (a) X-ray of the hand anteroposterior and lateral views showing fracture of neck of the 5th metacarpal (b) Postoperative X-ray of the same patient showing fixation with two bone ties (c) Peroperative photograph showing fixation with bone ties (d-f) Clinical photographs showing range of motions

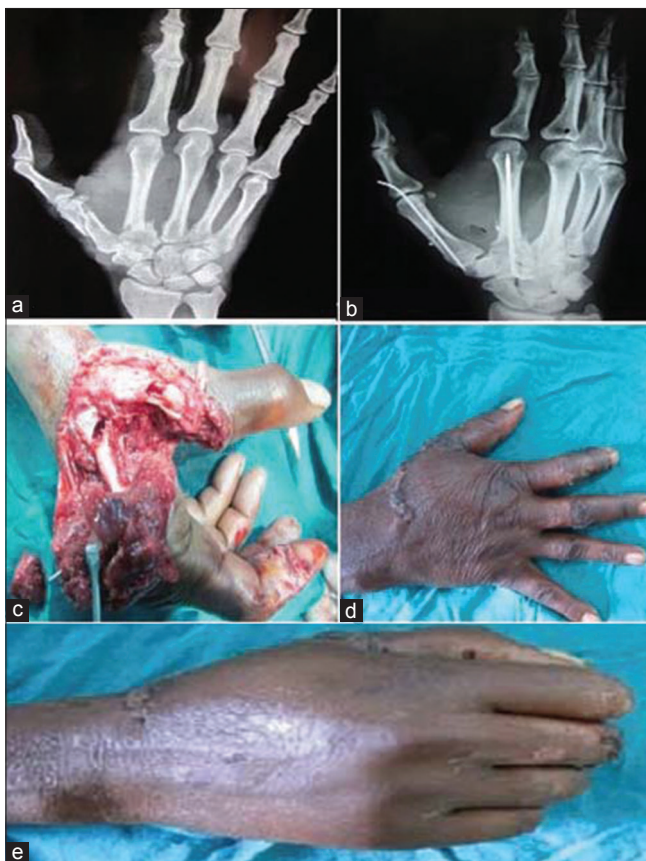

Figure 5: (a) X-ray of the hand showing fractures involving the shaft of the 1st and base of the 2nd metacarpal of right hand following a blast injury (b) Postoperative X-ray of same patient showing composite fixation using bone tie and K-wire of both the metacarpals (c) Intraoperative picture showing wound and fractures (d and e) Followup picture showing range of motion

enhanced stability of the fixation obtained both in the axial plane (by the K-wire) and in the rotatory axis (provided by the modified bone tie), the postoperative mobilization both active and gentle passive were easy and uneventful. We did not give much importance to the time taken for the radiological union as we know that it is a smaller goal when compared to having a pain free, near normal active movements.

DISCUSSION

Rigid fixation of the unstable fractures of the metacarpal and the phalangeal bones is mandatory for the early postoperative mobilization and minimizing the morbidity. Achieving near normal mobility and sending the patient back to his or her preinjury occupation is the need of the hour and the goal in treating these fractures involving the metacarpal and phalangeal bones. While transverse fractures of these short, long bones can be treated with a single axial K-wire imparting reasonable rigidity for early mobilization, the same cannot be always ensured in oblique, spiral, and comminuted fractures. These fractures often need composite wiring or plate and screws. Some of the existing methods of composite wiring are either technically demanding or biologically inferior.

Though it is said that skeletal stability and not the rigidity that is important for the functional movements⁴ of the hand following fracture management, the stability in this context itself is subjective and controversial. Some authors define instability as one in which the patient is able to move in the adjacent joints by <30%⁵ of the expected normal movements.

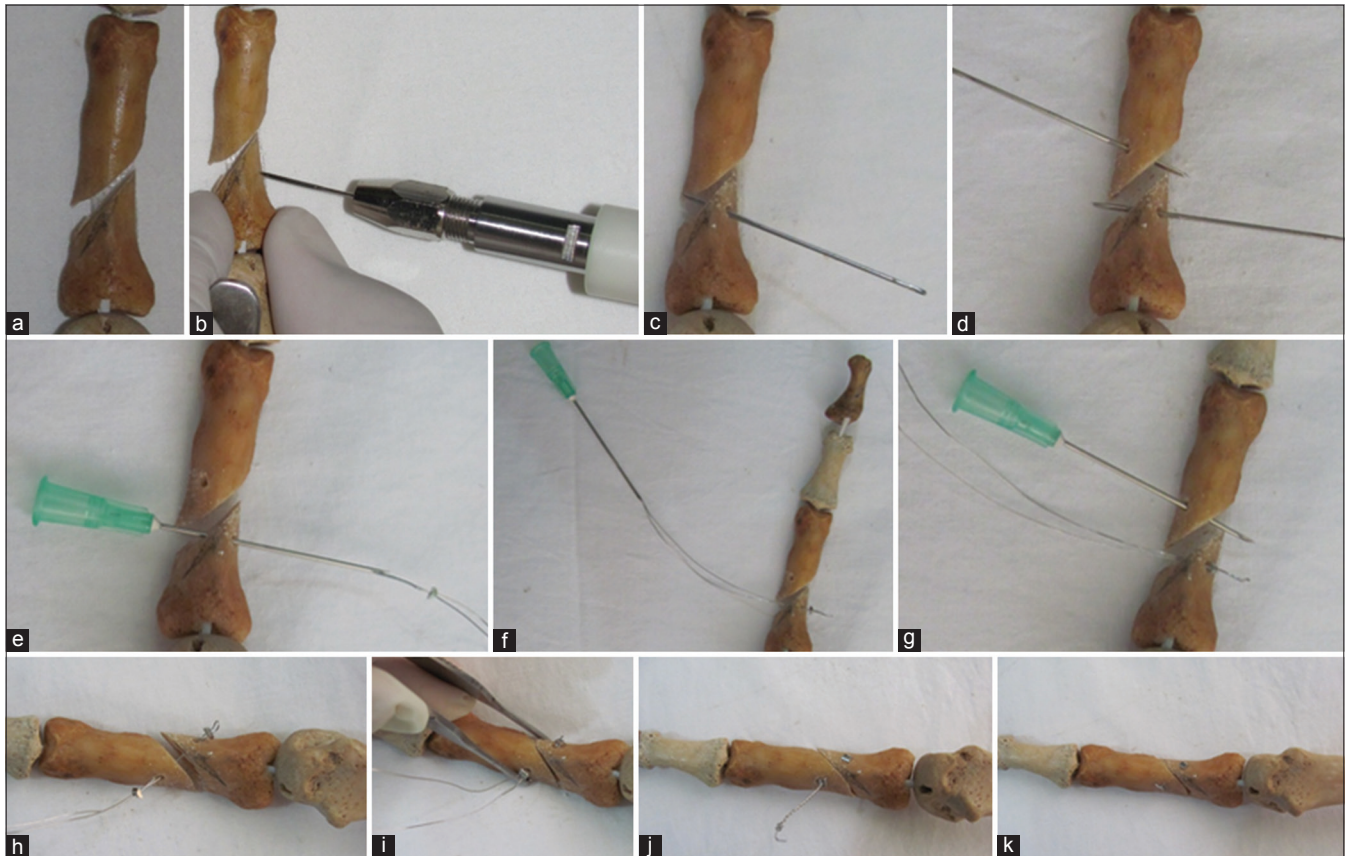


Figure 6: Pictorial depiction of the surgical technique of bone tie. (a) A model of phalangeal bone with an oblique fracture involving the shaft. (b and c) Drilling of the proximal fragment using K-wire (d). Drilling of the distal fragment with K-wire (e and f). Passage of a loop of stainless steel wire with the bone tie mounted and withdrawal of the same using a hypodermic needle (g). Insertion of hypodermic needle through the distal fragment to facilitate the passage of stainless steel wire (h). Passage of bone tie through the distal end of loop (i and j). Compression of the fracture site and tightening of the stainless steel wire (k). Final picture after tightening of the bone tie

Others consider the same figure as 50%.⁶ Radiological stability has been defined when the fractured fragments in two planes show minimal angulation and displacement. Functional instability is one where the fragments cannot be reduced or maintained in safe or functional position in a near anatomical position without an implant. The 4 cardinal factors determining the stability of the fracture are (1) the external force, (2) muscle imbalance, (3) personality of the fracture, and (4) integrity of the soft tissue. These factors make most of the oblique fractures, especially the open fractures highly unstable needing stable internal fixation which is rigid enough for early mobilization for the surgeon to expect the good functional outcome. Though axial pin fixation has been used in most of the circumstances to stabilize the fractures, mechanical stability of such fixation when used alone is insufficient. K-wire, when used alone for stabilization, needs to be maintained for a longer period (more than 4 weeks). Shortening more than 3–4 mm, angulation of the metacarpal fractures (>10–20° in 2nd and 3rd digits and >30–40° in 4th and 5th digits) rotational malalignment >5° (leading to 1.5 cms of digital overlapping or scissoring) are some of the limitations for nonoperative management in unstable fractures. Any fixation, especially in open fractures should be rigid enough and more

importantly should be less biologically interfering, which is why plate and screws are not very popular and uncommonly used. S.S wire, when used circumferentially or transosseously, can impart mechanical stability but is technically demanding and sometimes biologically inferior and detrimental for the vascularity of the fractured fragments which may already have been jeopardized in open fractures.

Single K-wire alone in unstable open fractures of the phalanges does not impart enough stability for early active movements. Double crisscross K-wire fixation though adds to the stability delays the unhindered active movements of the finger further. Delay in mobilization beyond 4 weeks results in 66% decrease in normal active movements and extensive physiotherapy is required.⁷

Literature is unsure and unclear about the safe timing of the removal of the K-wire. Most prefer to keep it for 4–6 weeks.⁸ Some surgeons suggest the wire to be buried under the skin if it needs to be maintained for more than 3–4 weeks.⁸ Pin loosening, pin tract infection, soft tissue irritation, tendon impaling and distraction at the fracture site are some of the known complications of K-wire. The method described by

the authors permits the surgeon for early removal of the wire, which is the single most important beneficial point of the method.

Conventionally, interfragmentary compression can be obtained through screws with or without plates or S.S wires used, either used circumferentially⁹ or as an interosseous¹⁰ single or double loop (parallel or perpendicular to each other). While the interfragmentary compression in larger bones with bigger fragments is easily obtained on the sound principles of AO, the same cannot be extrapolated in the smaller bones. The issue of appropriately selecting the direction of the pilot holes (which is dictated by the fracture anatomy and pattern), need to achieve and maintain the reduction all the time while drilling, tapping, using the depth gauge, over drilling the near cortex in small bone fragments and finally introducing the screw make it technically highly demanding with very little margin of error. Loss of reduction splintering of fragments, when encountered, will invite a situation which is difficult to bailout by any other methods. Screws and plates for metacarpal and phalangeal fractures come in different sizes and lengths making it important to have a large inventory of small implants. The screw fixation in the short, long bones of the hand cannot be used as a composite fixation along with the axial K-wire. Because of these inherent problems the practical usage of screws with or without plates is very limited and even when used is generally restricted to uncommunitated and uncomplicated fractures only.

The device that the authors have been using is very simple and surgeon friendly. It involves only the independent drilling of the pilot holes in the proximal and distal fragments without the prerequisites of the holes being co-linear. The need for holding and maintaining the reduction is important only at the stage of final tightening of the S.S wire. In addition to being simple, the device does not demand a large inventory.

Ten percent of all fractures in the body occur in the metacarpal and phalangeal bones of the hand.¹¹

Gupta *et al.* (2007)¹² have reported an overall 87% good to excellent results in a series of 45 fractures in 31 hands. Their results appear to be slightly better than our (83%), but if the same results are split into open and closed, we have been able to produce better results.

Pun *et al.* (1989)¹³ have, reported in a large series, an overall good results in about 42.4% of cases in open fractures treated by surgical fixation, and the good results in their series of open fracture without a significant soft tissue injury improved to 59.5%.¹³ However they had nearly 10% of mechanical failure, 5% of nonunion as significant complications. Nearly, 14% of their patients had to change their jobs, and about one third of their patients could not work as efficiently as before.

They finally concluded that they cannot determine the best method of managing the unstable fractures of the hand. The advantage of this of composite wiring using modified bone tie includes that it is technically easier, biologically superior (with least interference with the blood supply of the fractured fragments), and mechanically strong not only for early active mobilization but also for early removal of concomitantly used K-wire there by mitigating the deleterious effects of K-wire sticking around the periarticular area either blocking the full movements or impairing the extensor tendon mechanism.

We attribute our good results to: (1) Selection criteria (no soft tissue loss, total or partially torn extensor tendon) (2) Good biomechanical fixation in the form of composite fixation using K-wire and bone tie allowing us to mobilize the digits as early as possible (3) Early removal of K-wire (within 2–3 weeks).

Financial support and sponsorship

Nil.

Conflicts of interest

There are no conflicts of interest.

REFERENCES

1. Kamath JB, Vardhan H, Naik DM, Bharadwaj P, Menezes RJ, Sayoojianadhan BP. Modified bone tie: A new method to achieve interfragmentary compression in unstable oblique metacarpal and phalangeal fractures. *Tech Hand Up Extrem Surg* 2012;16:42-4.
2. Sammut D, Evans D. The bone tie. A new device for interfragmentary fixation. *J Hand Surg Br* 1999;24:64-9.
3. Kamath JB, Harshvardhan, Naik DM, Bansal A. Current concepts in managing fractures of metacarpal and phalangeal. *Indian J Plast Surg* 2011;44:203-11.
4. Rajesh G, Ip WY, Chow SP, Fung BK. Dynamic treatment for proximal phalangeal fracture of the hand. *J Orthop Surg (Hong Kong)* 2007;15:211-5.
5. Drenth DJ, Klases HJ. External fixation for phalangeal and metacarpal fractures. *J Bone Joint Surg Br* 1998;80:227-30.
6. Venkataswami R. *Surgery of the Injured Hand Towards Functional Restoration*. 1st ed. New Delhi: Jaypee Publishers; 2009. p. 409.
7. Strickland JW, Steichen J.B, Kleinman W.B. Phalangeal fractures. Factors influencing digital performance. *Orthop Rev* 1982;11:39-50.
8. Wolfe SW, Pederson WC, Hotchkiss RN, Kozin SH. *Green's Operative Hand Surgery*. 6th ed. Vol. I. Canada: Elsevier; 2011.
9. Gropper PT, Bowen V. Cerclage wiring of metacarpal fractures. *Clin Orthop Relat Res* 1984;188:203-7.
10. Gingrass RP, Fehring B, Matloub H. Intraosseous wiring of complex hand fractures. *Plast Reconstr Surg* 1980;66:383-94.
11. Emmett JE, Breck LW. A review and analysis of 11,000 fractures seen in a private practice of orthopaedic surgery, 1937-1956. *J Bone Joint Surg Am* 1958;40-A:1169-75.
12. Gupta R, Singh R, Siwach R, Sangwan S, Magu NK, Diwan R. Evaluation of surgical stabilization of metacarpal and phalangeal fractures of hand. *Indian J Orthop* 2007;41:224-9.
13. Pun WK, Chow SP, So YC, Luk KD, Ip FK, Chan KC, *et al.* A prospective study on 284 digital fractures of the hand. *J Hand Surg Am* 1989;14:474-81.