



## Spontaneous acute intussusception in a pregnant woman



Radhouane Achour <sup>\*</sup>, Souad Harabi, Khaled Neji

Emergency Department of Maternity and Neonatology Center, Faculty of Medicine of Tunis, El Manar University of Tunis, Tunisia

### ARTICLE INFO

#### Article history:

Received 27 November 2016

Accepted 9 December 2016

Available online 12 December 2016

#### Keywords:

Pregnancy

Spontaneous acute intussusception

### ABSTRACT

Acute intussusception in adults is rare and particularly so in pregnant women. Its incidence ranges from 0.067% to 0.0015% (Choi et al., 2005 Choi et al. (2005) [1]). The non-specific presenting symptoms may be attributed to the pregnancy itself, making the diagnosis difficult. When it happens, however, it causes considerable morbidity and mortality for the pregnant woman and the fetus. In adults, such intussusceptions are mainly secondary to an intestinal disease and frequently a tumor.

We present the case of a 21-year-old pregnant woman who was diagnosed of spontaneous acute intussusception at nine weeks of gestation and therapeutic management.

© 2016 Published by Elsevier B.V. This is an open access article under the CC BY-NC-ND license (<http://creativecommons.org/licenses/by-nc-nd/4.0/>).

### 1. Introduction

Intestinal obstruction complicating pregnancy is one of the surgical emergencies that are associated with high incidence of morbidity and mortality for both mother and fetus.

Making a diagnosis of intestinal obstruction during pregnancy is particularly difficult because most of the symptoms of intestinal obstruction (anorexia, nausea, vomiting and abdominal pain) are often encountered during pregnancy.

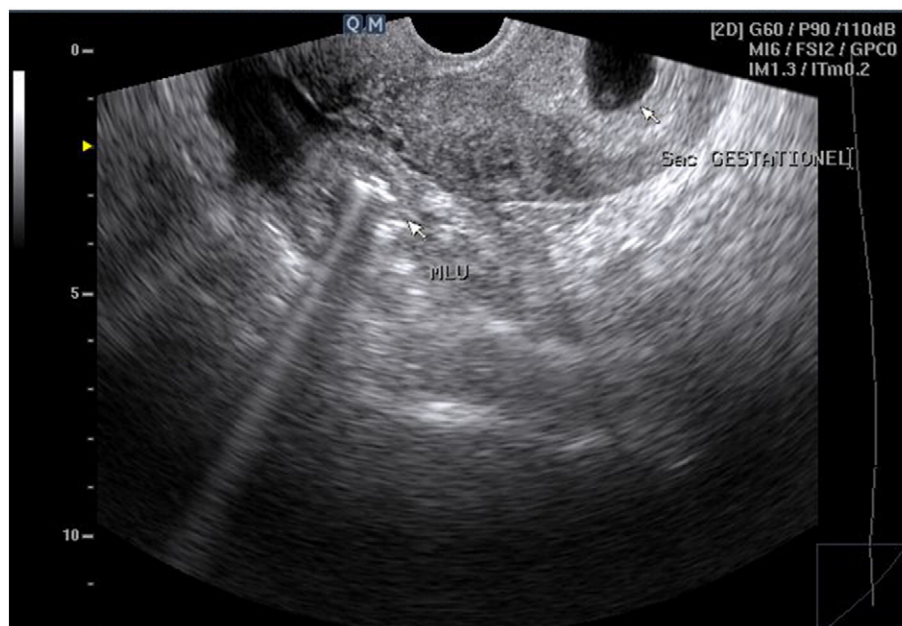


Fig. 1. Adnexal mass with Intrauterine gestational sac and a small amount of fluid in the cul-de-sac.

<sup>\*</sup> Corresponding author.

E-mail address: [radhouane.a@live.com](mailto:radhouane.a@live.com) (R. Achour).

**2. Case Report**

A 21-year-old pregnant woman at nine weeks of gestation, gravida one para one, without medical history, was admitted with sudden start, permanent and paroxysmal pelvic pain two days prior to admission associated with rectorrhagia. She denied any metrorrhagia, nausea, vomit, constipation or fever.

At time of presentation, her blood pressure 110/75, pulse 83. Abdominal examination found a pelvic tenderness on palpation with no peritoneal signs. Speculum examination, vaginal and rectal touch didn't find respectively any metrorrhagia or rectorrhagia. Laboratory tests were normal including a white blood cell count of 10.3.

The abdominopelvic ultrasound examination found an evolutive pregnancy at nine weeks of gestation with adnexal mass with ring of fire sign and a small amount of fluid in the cul-de-sac (Fig. 1). (See Figs. 2,3.)

An emergency surgery was performed by laparoscopy. This showed an ileocecal intussusception with ischemia of the last small bowel. The intussusception was not reduced. An end to end resection anastomosis was performed. We performed a small bowel and ileocecal resection with end to end anastomosis. The total length of small bowel removed was 30 cm (Figs. 2,3).

Histology of the resected bowel segment ileocecal intussusception without evidence of malignancy.

The operating follow ups remained simple. She was discharged on the 10th postoperative day.

**3. Discussion**

Intussusception is a condition commonly seen in the pediatric age group and is exceedingly rare in adults; it accounts for 1% of bowel

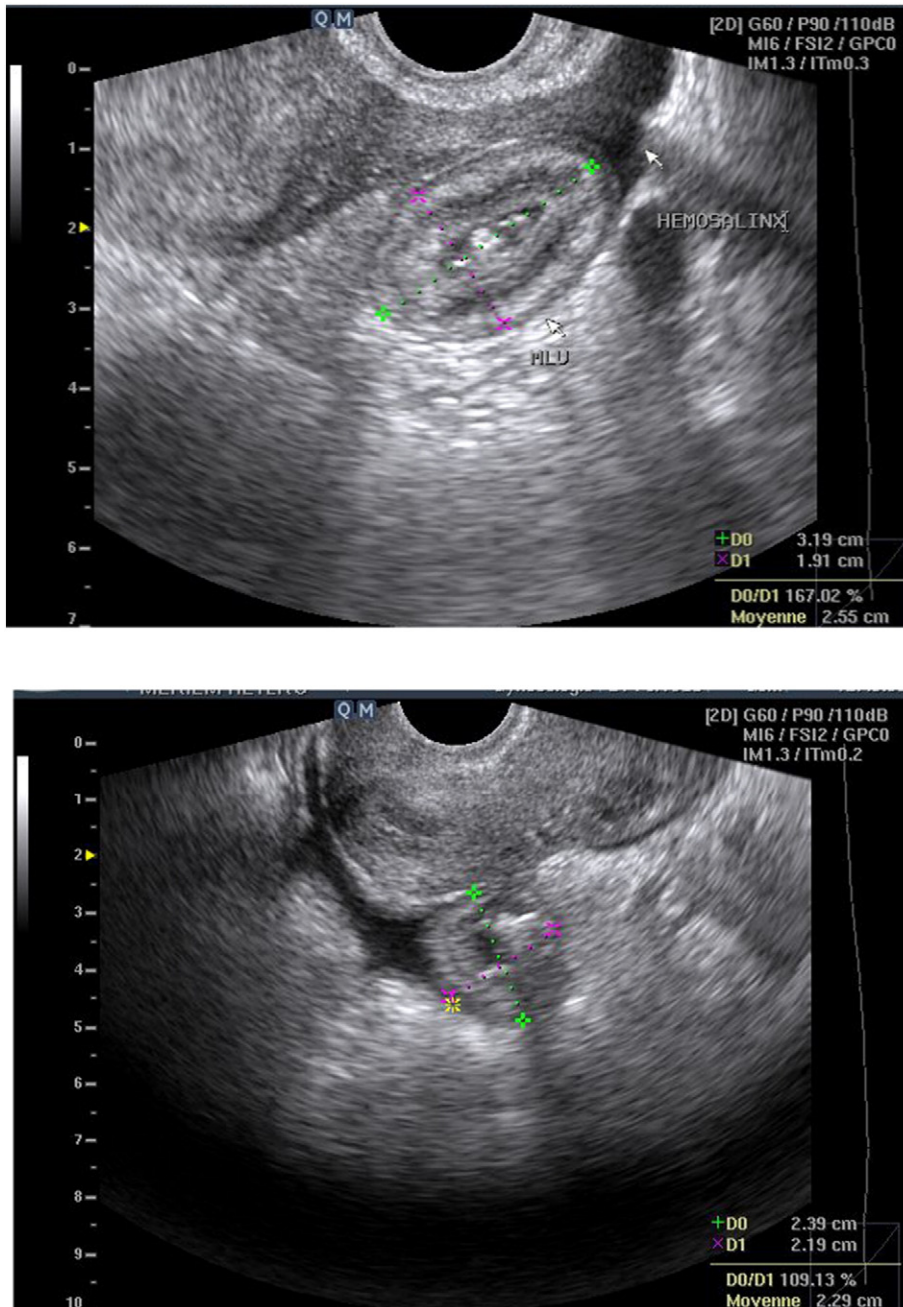


Fig. 2,3. Adnexal mass with double anechoic rings surrounded by a central echogenic focus.

obstructions in adults and is associated with an underlying cause, such as a tumor or polyp, in over 80% of cases [1,2].

Causes of intestinal obstruction in pregnancy include adhesions, volvulus, intussusception, carcinoma, hernia, and acute appendicitis [3] Intestinal obstruction in pregnancy is associated with a maternal and perinatal mortality of 6% and 26%, respectively [4].

Furthermore, the presenting symptoms of nausea, vomiting, abdominal pain and constipation are easily mistaken for some of the common signs and symptoms in pregnancy and the displacement of the bowel by the gravid uterus hampers examination. Therefore, it is important to have a high index of suspicion.

Ultrasound is a useful modality in the diagnosis of intussusception and has the advantage of safety in pregnancy and ease of availability [5]. The sonographic findings are single or double anechoic rings surrounded by a central echogenic focus.

CT is thus the diagnosis of choice in adult intussusceptions. The intussusception will appear as a sausage-shaped mass when the CT beam is parallel to its longitudinal axis, but will appear as a target mass when the beam is perpendicular to the longitudinal axis of the intussusceptions [6]. However, diagnostic imaging in pregnancy is restricted to ultrasound and MRI.

Surgical resection is almost always required in intestinal obstruction during pregnancy.

#### 4. Conclusion

In summary, intussusception in pregnancy is a rare condition. Intussusception can be suspected on the basis of clinical presentation and

ultrasonographic examination, but still exact diagnosis can be made only by surgery. The surgical management of intussusceptions is usually similar to the non-pregnant state. The combined expertise of the obstetrician, radiologist, and surgeon are needed to manage the pregnant patient.

#### Conflict of Interest

We declare that we have no conflict of interest.

#### References

- [1] Choi SA, Park SJ, Lee HK, et al. Preoperative diagnosis of small bowel intussusception in pregnancy with the use of sonography. *J Ultrasound Med* 2005;24:1575–7.
- [2] Toso C, Erne M, Lenzlinger PM, Schmid JF, Buchel H, Melcher C, et al. Intussusception as a cause of bowel obstruction in adults. *Swiss Med Wkly* 2005;135:87–90.
- [3] Chang YT, Huang YS, Chan HM, Huang CJ, Hsieh JS, Huang TJ. Intestinal obstruction during pregnancy. *Kaohsiung J Med Sci* 2006;22:20–3.
- [4] Perdue PW, Johnson Jr HW, Stafford PW. Intestinal obstruction complicating pregnancy. *Am J Surg* 1992;164:384–8.
- [5] Sofia S, Casali A, Bolondi L. Sonographic diagnosis of adult intussusception. *Abdom Imaging* 2001;26:483–6.
- [6] Jabar MF, Prasannan S, Gul YA. Adult intussusception secondary to inflammatory polyps. *Asian J Surg* 2005;28:58–61.