
“Undulation on ventilator wave” may indicate serious lung pathology

Sir,

Real-time examination of ventilator waves and loops helps us understand respiratory mechanics, patient

ventilator interactions, and other pathophysiological conditions.^[1] Therefore, ventilator waves and loops have become an integral part of intensive care and operation theater monitoring. We would like to describe an

interesting characteristic of pressure and flow time wave of three patients, which turned out to be due to a serious, life threatening lung pathology.

A 58-year-old male who was suffering from multidrug-resistant tuberculosis with pneumothorax was admitted to the intensive care unit (ICU) with severe respiratory difficulty. There was a chest tube with water-seal drainage on the right side, and movement of air-fluid level could be appreciated. He was intubated, and ventilation (Ventilator: eXtend, Air liquid, Paris, France) was started with synchronized intermittent mandatory ventilation plus pressure support (SIMV + PS) at 100% fraction of inspired oxygen (FiO_2) and positive end-expiratory pressure (PEEP) of 3 cm H_2O . As the patient required high FiO_2 , PEEP was increased gradually. At that moment, we observed an oscillatory wave in the expiratory phase of pressure and flow time wave resembling the undulation that is usually noticed due to secretion in the ventilator circuit [Figures 1 and 2]. The endotracheal tube was suctioned, but it was dry and the undulation persisted. When we decreased PEEP to 3 cm H_2O , the wave disappeared. But it reappeared again as PEEP was increased. The same phenomenon was observed several times. Portable chest x-ray showed a right-sided pneumothorax with a kinked chest tube *in situ*. The pneumothorax was decompressed with a new 24-Fr chest tube. As soon as the pneumothorax was decompressed, the undulation disappeared. The patient's condition gradually improved and the trachea was extubated the next day.

The second case involved an 11-year-old girl who was admitted because of severe community-acquired pneumonia with left-sided pneumothorax. The pneumothorax was decompressed and the patient was placed on mechanical ventilation (ventilator :Maquet Servo I, Andheri , Mumbai). On the third day of ventilation, oscillatory waves on pressure and flow-time waves were observed. But in this case, the amplitudes of the oscillatory waves were small. We could appreciate the waves only when PEEP was

higher than 7 cm H_2O , and waves were absent when there was no PEEP [Figure 3]. Chest x-ray showed right-sided pneumothorax. Undulation disappeared as the pneumothorax was decompressed by another chest tube on the right side. Unfortunately, after a few days the child died due to severe sepsis and multiple organ failure.

The third case was of a 27-year-old patient who had sustained head and multiple chest injuries following a road traffic accident. The patient had a left-sided pneumothorax, which was drained by a 28-Fr chest tube and water-sealed drainage. Two hours after inserting the tube, the patient developed subcutaneous emphysema along with undulation on the expiratory phase of pressure and flow-time wave of the ventilator, which varied with the amount of PEEP applied. Chest x-ray showed pneumothorax along with a kinked chest tube and the most proximal opening outside the thoracic cavity. Undulation disappeared as the chest tube was repositioned.

Various intrinsic and extrinsic factors such as ineffective respiratory effort, terminal asynchrony, secretions, and electromagnetic interference may influence ventilator display.^[2,3] This sawtooth pattern or oscillation in ventilator waves and loops is usually considered as an indicator of secretion in airways.^[1,4] During exhalation, the presence of secretion in the airway can generate cyclic increments and decrements in flow, secondary to transient obstruction of the airway lumen or the fluctuating movement of its content.^[5] Extensive literature search did not reveal any association between this typical undulation and incomplete decompression of pneumothorax. Though we could not offer any definite explanation for this typical finding in these cases, we observed three interesting and common characteristics. First, endotracheal tube suction did not reveal any secretion.

Second, undulation appeared as PEEP was increased. Third, complete decompression of the pneumothorax abolished these waves permanently. However, we cannot attribute this finding to incomplete decompression of pneumothorax

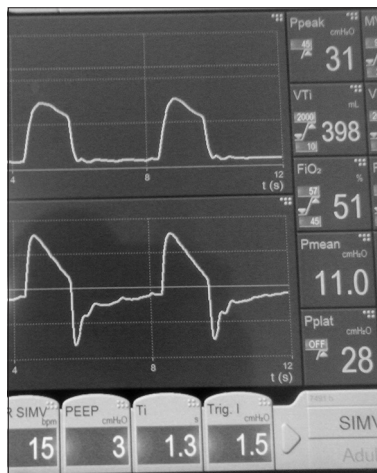


Figure 1: Absence of oscillatory waves on expiratory phase of pressure and flow-time wave at PEEP 3

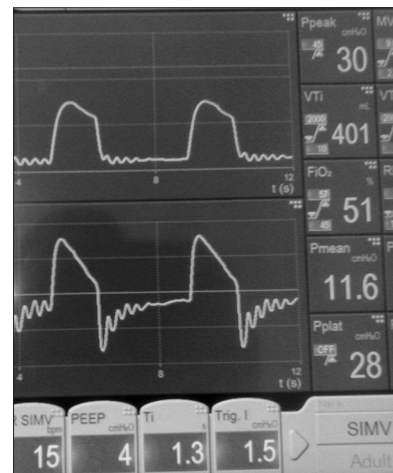

Figure 2: Oscillatory waves on expiratory phase of pressure and flow-time wave at PEEP 4

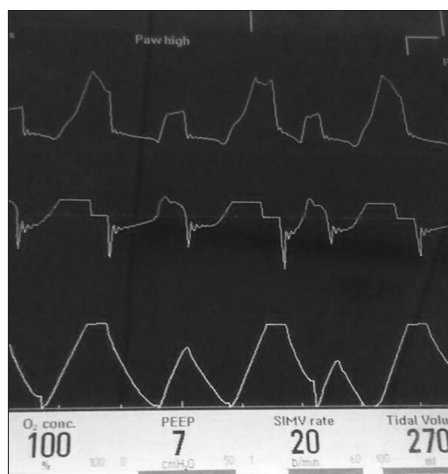


Figure 3: Small oscillatory waves on expiratory phase of pressure and flow-time wave at PEEP 7

only on the basis of these three cases. Further observations or studies are warranted to validate this finding.

Financial support and sponsorship

Nil.

Conflicts of interest

There are no conflicts of interest.

Saurabh Kumar Das, Nang Sujali Chopoo

Department of Anesthesia and Critical Care, Nazareth Hospital,
Shillong, Meghalaya, India
E-mail: drsauravdas1977@gmail.com

REFERENCES

1. Corregre E, Murias G, Chacon E, Estruqa A, Sales B, Lopez-Aquilar J, et al. Interpretation of ventilator curves in patients with acute respiratory failure. *Med Intensiva* 2012;36:294-306.
2. Gonzalvo R, Martí-Sistac O, Blanch L, López-Aquilar J. Bench-to-bedside review: Brain-lung interaction in the critically ill—a pending issue revisited. *Crit Care* 2007;11:216.
3. Lapinsky SE, Easty AC. Electromagnetic interference in critical care. *J Crit Care* 2006;21:267-70.
4. Sokhal N, Goyal K, Chowdhury T, Rath GP. See-saw pattern in ventilator graphic: Is there any story behind? *Niger Med J* 2014;55:359-61.
5. Koutsoukou A, Beskos B, Sotiropoulou C, Koulouris NG, Roussos C, Milic-Emili J. Effects of positive end-expiratory pressure on gas exchange and expiratory flow limitation in adult respiratory distress syndrome. *Crit Care Med* 2002;30:1941-9.

This is an open access article distributed under the terms of the Creative Commons Attribution-NonCommercial-ShareAlike 3.0 License, which allows others to remix, tweak, and build upon the work non-commercially, as long as the author is credited and the new creations are licensed under the identical terms.

Access this article online

Quick Response Code:



Website:

www.lungindia.com

DOI:

10.4103/0970-2113.173081

How to cite this article: Das SK, Chopoo NS. "Undulation on ventilator wave" may indicate serious lung pathology. *Lung India* 2016;33:103-5.