



REVISTA BRASILEIRA DE ANESTESIOLOGIA

Publicação Oficial da Sociedade Brasileira de Anestesiologia
www.sba.com.br



CLINICAL INFORMATION

Selective left mainstem bronchial intubation in the neonatal intensive care unit



Anthony M.H. Ho^a, Michael P. Flavin^b, Melinda L. Fleming^a, Glenio Bitencourt Mizubuti^{a,*}

^a Queen's University, Kingston General Hospital, Department of Anesthesiology and Perioperative Medicine, Kingston, Ontario, Canada

^b Queen's University, Department of Pediatrics, Kingston, Ontario, Canada

Received 13 December 2016; accepted 17 April 2017

Available online 13 May 2017

KEYWORDS

Bullous emphysema;
Endobronchial
intubation;
Neonate

Abstract

Background: Selective neonatal left mainstem bronchial intubation to treat right lung disease is typically achieved with elaborate maneuvers, instrumentation and devices. This is often attributed to bronchial geometry which favors right mainstem entry of an endotracheal tube deliberately advanced beyond the carina.

Case summary: A neonate with severe bullous emphysema affecting the right lung required urgent non-ventilation of that lung. We achieved left mainstem bronchial intubation by turning the endotracheal tube 180° such that the Murphy's eye faced the left instead of the right, and simulated a left-handed intubation by slightly orientating the endotracheal tube such that its concavity faced the left instead of the right as in a conventional right-handed intubation.

Conclusion: Urgent intubation of the left mainstem bronchus with an endotracheal tube can be easily achieved by recognizing that it is the position of the endotracheal tube tip and the direction of its concavity that are the chief determinants of which bronchus an endotracheal tube goes when advanced. This is important in critically ill neonates as the margin of safety and time window are small, and the absence of double-lumen tubes. Use of fiberoptic bronchoscope and blockers should be reserved as backup plans.

© 2017 Sociedade Brasileira de Anestesiologia. Published by Elsevier Editora Ltda. This is an open access article under the CC BY-NC-ND license (<http://creativecommons.org/licenses/by-nc-nd/4.0/>).

PALAVRAS-CHAVE

Enfisema bolhoso;
Intubação
endobrônquica;
Recém-nascido

Intubação seletiva do brônquio principal esquerdo em unidade de terapia intensiva neonatal

Resumo

Justificativa: A intubação seletiva neonatal do brônquio principal esquerdo para tratar a doença pulmonar direita é tipicamente realizada com elaboradas manobras, instrumentação

* Corresponding author.

E-mail: gleniomizubuti@hotmail.com (G.B. Mizubuti).

e dispositivos. Isso é frequentemente atribuído à geometria brônquica que favorece a entrada principal direita de um tubo endotraqueal (TET) deliberadamente avançado para além da carina.

Resumo do caso: Recém-nascido com enfisema bolhoso grave afetando o pulmão direito que precisou com urgência da não ventilação desse pulmão. Conseguimos a intubação brônquica esquerda fazendo uma rotação de 180° do TET, de forma que o olho de Murphy ficasse voltada para a esquerda e não para a direita, e simulamos uma intubação à esquerda orientando ligeiramente o TET, de modo que sua concavidade virasse para a esquerda em vez de para a direita, como em uma intubação convencional à direita.

Conclusão: A intubação urgente do brônquio principal esquerdo com um TET pode ser facilmente obtida reconhecendo-se que é a posição da ponta do TET e a direção de sua concavidade que determinam para qual brônquio o TET irá quando avançado. Isso é importante em neonatos criticamente doentes diante da margem de segurança e janela de tempo pequenas e na ausência de tubos de duplo lúmen. O uso de broncofibroscópio e bloqueadores deve ser considerado como planos de segurança.

© 2017 Sociedade Brasileira de Anestesiologia. Publicado por Elsevier Editora Ltda. Este é um artigo Open Access sob uma licença CC BY-NC-ND (<http://creativecommons.org/licenses/by-nc-nd/4.0/>).

Introduction

Single-lung ventilation may be needed in neonates with unilateral lung disease.¹⁻⁵ This can be achieved by intubating the contralateral mainstem bronchus with an Endotracheal Tube (ETT), or by blocking the ipsilateral mainstem bronchus with a balloon-tipped bronchial blocker. Bronchoscopy is usually needed to guide and/or confirm placement. Bronchial blockers are seldom used in the Neonatal Intensive Care Unit (NICU). Passage of an ETT into the left mainstem bronchus often requires special maneuvers and equipment. In urgent/emergent situations, the timely availability of such equipment may be limited. We herein discuss the management of a neonate who required urgent left mainstem bronchial intubation, and present options available for selective left-lung ventilation in the NICU setting. For clarity purposes, it is important that the reader be familiar with the ETT tip design, in particular the Murphy's eye which is the oval structure located at the distal end and opposed to the ETT's bevel, as the technique described herein will focus around its position within the trachea.

Case report

Written parental consent was provided for the publication of this case. This report complies with HIPAA Privacy Regulations and the appropriate EQUATOR checklist.

An 11 week-old 2100g boy born at 24 weeks gestation had respiratory distress syndrome, interstitial emphysema and bronchopulmonary dysplasia. He developed expanding right lower lobe bullous emphysema with mediastinal shift (Fig. 1). High frequency ventilation resulted in desaturation. Ventilation was via an uncuffed ETT-ID 3 mm.

The decision was made to stop ventilating the right lung. The steps were: (1) the depth of the in situ ETT was noted on

the latest chest X-ray and at the gum line, and an estimate was taken on the ETT tip-carina distance; (2) the ETT was rotated 180° so that it was slightly concave to the left and its Murphy's eye facing left; (3) the ETT was advanced to the desired distance, confirmed by auscultation, X-ray and fiberoscopy (Fig. 1).

There was a tiny gas leak around the ETT at 25 cm H₂O based on auscultation of the right chest. Subsequent X-rays showed that ETT remained in position and the left upper lobe well aerated. The right sided bullae shrank (Fig. 1) and the ETT was withdrawn to the mid-trachea position after 6 days. The patient was extubated to low-pressure BiPAP 13 days later. At follow-up the right lung bullous emphysema had resolved but there was complete left lung consolidation/atelectasis and compensatory emphysema of the right lung. He required 0.25 L.min⁻¹ of supplemental oxygen at home and was thriving. The infant's breathing continued to improve and he was weaned off oxygen at 9 months of age. Rigid bronchoscopy at 12 months for persistent left lung atelectasis revealed no scarring of the left bronchus mucosa and a fish-mouth occlusion of the bronchus suggesting severe bronchomalacia.⁶ Chest computerized tomography showed external bronchial compression.

Discussion

Some NICU staff and anesthesiologists might consider left mainstem intubation a challenge. This is often attributed to the bifurcation of the carina (32° on right to midline vs. 51° on left in neonates)⁷ which favors right mainstem bronchial intubation of a deeply placed ETT. Left lung ventilation to treat right pulmonary disease in neonates typically includes use of a stylet and/or flexible or rigid bronchoscopy or fluoroscopy to guide an ETT into the left mainstem bronchus or to guide a balloon-tipped bronchial blocker into the right bronchus.¹⁻³ Passing an ETT into the left mainstem bronchus

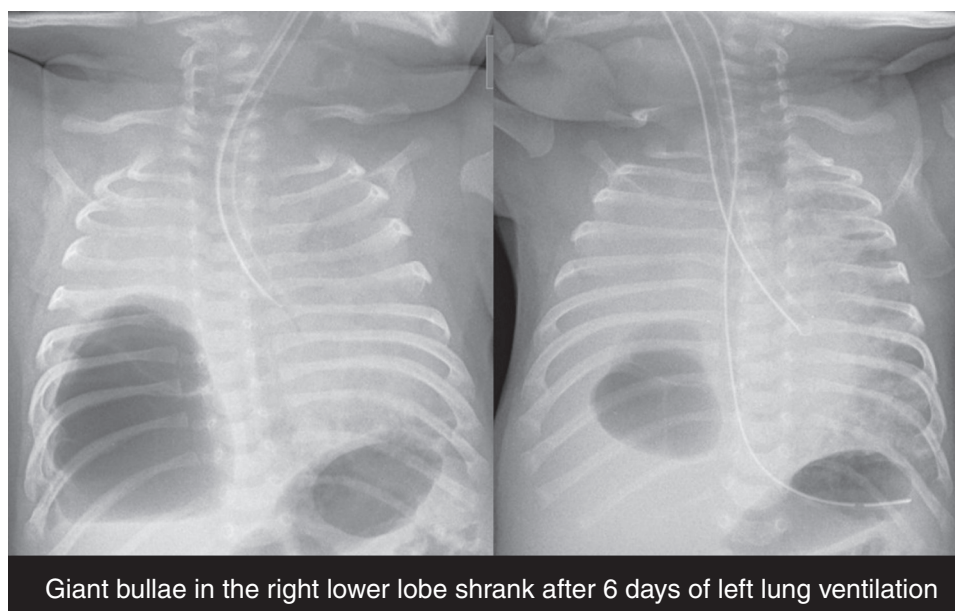


Figure 1 Chest X-ray showing left mainstem bronchial intubation with an endotracheal tube immediately after (left panel) bronchial placement and 6 days later (right panel). The right lung bullae had clearly shrunk over time allowing resumption of bilateral ventilation.

without instrumentation has been described but is cumbersome, consisting of right-tilting the patient 45° laterally, turning the head to the extreme right, and rotating the ETT 180° before advancing the ETT to beyond the carina.^{4,5} As tilting the patient and turning the head change the ETT depth estimation, we completed our task by only rotating the ETT by 180°, orientating it slightly concave to the left, and advancing it.

In humans, 99% of normally placed ETT (bevel facing left, Murphy's eye facing right and the ETT held in right hand slightly concave to the right) would intubate the right bronchus if deliberately advanced.⁸ However, 61% and 92% of ETTs when rotated 180° (bevel facing right and Murphy's eye facing left) and the head in the neutral and right-turned positions, respectively, would intubate the left bronchus if advanced.⁸ In other words, the carinal bifurcation asymmetry is not the most important reason why a deeply placed ETT typically enters the right mainstem bronchus. The main determinants are, in fact, the direction of the ETT tip and the right hand placement from right side of the mouth. We believe in a left mainstem intubation, the purpose of turning the head to the right is to simulate a left-handed ETT placement from the left corner of the mouth, and that orientating the ETT slightly concave to the left achieves the same purpose.

We used fiberoscopy and X-ray to verify that the left upper lobe was unobstructed. Another concern was pressure on the left bronchial mucosa from the ETT (external diameter 4.3 mm). The left mainstem bronchial:cricoid ratio diameter remains constant across all ages but is slightly larger for girls than for boys (0.81 ± 0.16 vs. 0.77 ± 0.13 respectively).⁹ A small leak at 25 cm H₂O provided some reassurance but since the mainstem bronchus is not perfectly round, parts of the mainstem bronchial mucosa could still be subjected to pressure. We suspect that the 6 days of

left lung mechanical ventilation was the cause of this child's bronchomalacia.⁶

Several authors have described the use of rigid¹ or flexible^{2,10} bronchoscopy or a stylet³ to guide left bronchial intubation. Flexible bronchoscope allows direct visualization of the airway and prompt diagnosis of anatomic abnormalities that may preclude advancement of the ETT into the left main bronchus.¹⁰ Even though we used flexible bronchoscopy to verify our ETT position after left mainstem intubation, we achieved our goal much more efficiently and with less interference with ventilation by not initially relying on bronchoscopy. We also needed to have a technique that would allow us to efficiently intubate the left mainstem should dislodgement of the ETT into the trachea occur, given the low margin of error. Furthermore, resumption of bilateral ventilation may be required several times before oxygen saturation stabilizes. It would be much easier to be able to slide the ETT in and out of the left bronchus without relying on fiberoscopy every time.

One other technique is the use of balloon-tipped bronchial blocker.¹¹ However, NICU staff are not familiar with this device. Furthermore, blocker placement would have involved passing it within the in situ ETT lumen, leaving insufficient room for suctioning and bronchoscopy, without which blocker placement could only have been performed using fluoroscopy. Fluoroscopy is impractical and since blockers may dislodge into the trachea, repeated repositioning is sometimes needed. The alternative of placing the blocker extraluminal of the ETT would have necessitated extubation first, a daunting task in a sick neonate. One other disadvantage of a bronchial blocker is the possibility of a ball-valve effect created by fluctuations in bronchial caliber with respiration. Air trapping that can over-inflate the blocked lung can occur if the balloon is under-inflated, while over-zealous inflation of the balloon increases the chance of

bronchial injury, bronchomalacia, and displacement of the bronchial blocker into the trachea.

Finally, to avoid the more challenging task of intubating the left mainstem bronchus, one group modified an ETT by occluding the end hole of an ETT and fashioning two proximal side holes approximately at the position of the carina. This allowed them to intubate the right mainstem bronchus and yet be able to ventilate the left.¹² Unfortunately, mucous blockage of the side holes after 18 h of ventilation occurred.¹² Furthermore, this technique would have necessitated an ETT exchange in our sick neonate and it would have taken precious time to modify an ETT.

In conclusion, selective blind intubation of the left mainstem bronchus should be part of NICU and pediatric anesthesiologists' armamentarium, and should be especially considered in urgent/emergent situations when special equipment is not readily available. Selective intubation of the left bronchus is not much more difficult than the right; a task NICU staff is accustomed to. The ETT concavity and tip direction are the main determinants of which mainstem bronchus is entered as the ETT is advanced. Even though left mainstem intubation successfully reversed a dire situation in our case of severe right lung disease, it might have caused severe left bronchomalacia. The duration of mainstem intubation should be kept to a minimum.

Conflicts of interest

The authors declare no conflicts of interest.

References

1. Georgeson KE, Vain NE. Intubation of the left mainstem bronchus in newborn infants: a new technique. *J Pediatr*. 1980;96:920–1.
2. Vahey TN, Pratt GB, Baum RS. Treatment of localized pulmonary interstitial emphysema with selective bronchial intubation. *Am J Radiol*. 1983;140:1107–9.
3. Jakob A, Bender C, Henschen M, et al. Selective unilateral lung ventilation in preterm infants with acquired bullous emphysema: a series of nine cases. *Pediatr Pulmonol*. 2013;48:14–9.
4. Chalak LF, Kaiser JR, Arrington RW. Resolution of pulmonary interstitial emphysema following selective left main stem intubation in a premature newborn: an old procedure revisited. *Paediatr Anaesth*. 2007;17:183–6.
5. Joseph LJ, Bromiker R, Toker O, et al. Unilateral lung intubation for pulmonary air leak syndrome in neonates: a case series and a review of the literature. *Am J Perinatol*. 2011;28:151–6.
6. Ho AMH, Winthrop A, Jones EF, et al. Severe pediatric bronchomalacia. *Anesthesiology*. 2016;124:1395.
7. Ryan S, Curran JF. Embryology and anatomy of the neonatal chest. In: Donoghue V, editor. *Radiological imaging of the neonatal chest*. Berlin Heidelberg GmbH: Springer-Verlag; 2002. p. 1–9.
8. Kubota H, Kubota Y, Toyada Y, et al. Selective blind endobronchial intubation in children and adults. *Anesthesiology*. 1987;67:587–9.
9. Wani TM, Rafiq M, Terkawi R, et al. Cricoid and left bronchial diameter in the pediatric population. *Paediatr Anaesth*. 2016;26:608–12.
10. Van Dorn CS, Sittig SE, Koch CA, et al. Selective fiberoptic left mainstem intubation to treat bronchial laceration in an extremely low birthweight neonate. *Int J Pediatr Otorhinolaryngol*. 2010;74:707–10.
11. Jishi NA, Kyer D, Sharief N, et al. Selective bronchial occlusion for treatment of bullous interstitial emphysema and bronchopleural fistula. *J Pediatr Surg*. 1994;29:1545–7.
12. Balegar VKK, Barr PA, McCauley JC, et al. Selective bronchial intubation in a preterm infant with congenital cystic adenomatoid malformation and pulmonary air leak syndrome. *J Paediatr Child Health*. 2013;49:E93–6.