

Management of Pediatric Benign Ovarian Tumors in England and Egypt: A Comparative Study

Ahmed Elgendy¹, Bhanumathi Lakshminarayanan², Ahmed Elrouby³, Mahmoud Mostafa⁴, Mohamed Abouelmagd Salem⁵, Kerry Turner⁶, Ahmed Khairi³, Roly Squire², Sherif M. K. Shehata⁷, Sameh Shehata³, Mark Powis²

¹Surgical Oncology Unit, Department of Surgery, Tanta University, ²Department of Pediatric Surgery, Tanta University, Tanta, ³Department of Pediatric Surgery, Alexandria University, Alexandria, ⁴Department of Pediatric Surgery, Assiut University, ⁵Department of Surgical Oncology, South Egypt Cancer Institute, Assiut University, Assiut, Egypt, Departments of ⁶Pediatric Surgery and ⁷Pathology, Leeds Teaching Hospitals NHS Trust, Leeds, England, UK

Abstract

Aim of the Study: We aimed to compare the management of pediatric benign ovarian tumors between an English center and three Egyptian institutions. **Materials and Methods:** This was a retrospective review of all children presenting with benign ovarian tumors between January 2014 and January 2019. A standardized dataset was used to compare between both sides. **Results:** Eighty-nine patients were included (54 English and 35 Egyptians). Median age at diagnosis in England was 13 years (2-16y), while in Egypt it was 7 years (9m-16y) with $P=0.001$. Mature teratomas or dermoid cysts were the most common findings in England and Egypt; 75.9% and 82.8% of cases, respectively. The presentation with an acute abdomen represented 27.8% of English and 28.6% of Egyptian patients. Incidentally diagnosed lesions constituted 15% of English patients, whereas none of the Egyptian cases were discovered incidentally. There were variations in diagnostic imaging; England: Ultrasound (USS) (54), magnetic resonance imaging (MRI) (37), and computed tomography (CT) (only one)–Egypt: USS (35), CT (17), and MRI (only one). Minimally invasive surgery (MIS) was performed in 15% of English and 23% of Egyptian patients ($P=0.334$). Ovarian-sparing surgery (OSS) was performed in: England 35%, Egypt 37%; $P=0.851$. OSS was performed using MIS in 87.5% (7/8) of English patients and 100% (8/8) of Egyptians. Patients presented as emergencies generally had open oophorectomies: England; 86.7% open and 80% oophorectomy–Egypt; 100% open and 90% oophorectomy. Recurrences or metachronous disease occurred in 5.6% of English and 5.7% of Egyptian patients. **Conclusions:** There were no significant differences regarding surgical management, tumor pathology, and recurrence or metachronous disease. However, age, incidental diagnosis, and imaging modalities showed notable differences. MIS was correlated with ovarian preservation, whereas emergency surgery generally resulted in open oophorectomy.

Keywords: Children, minimally invasive surgery, ovarian-sparing surgery, ovarian tumors

The initial result of this study has been presented as an Oral Poster Presentation by the Corresponding Author at the 51st Congress of the International Society of Paediatric Surgical Oncology (SIOP - IPSO 2019), Lyon, France.

INTRODUCTION

Ovarian tumors are the most common neoplasms of the female genital tract in the pediatric population.^[1] The suggested incidence of adnexal masses has been calculated to be 2.6 patients/100,000 children per year,^[2] and about 75% of them are of benign pathology.^[3] Mature teratomas with solid and cystic components represent the vast majority of benign ovarian tumors.^[4]

The diagnosis of such neoplasms is usually based on clinical features, radiological characteristics, and serum tumor markers.^[5] The initial presentations of these entities are diverse. Patients are referred most commonly, due to abdominal pain associated with a palpable pelvic mass.^[6] In many cases, they present acutely with an acute abdomen and signs of peritonitis as a consequence of hemorrhage or torsion. Occasionally, these tumors are diagnosed incidentally during

Address for correspondence: Dr. Ahmed Elgendy, Surgical Oncology Unit, Faculty of Medicine, Tanta University, Tanta, Egypt. E-mail: ahmed.elgendy@med.tanta.edu.eg

Received: 15-05-2020 Revised: 12-07-2020 Accepted: 09-09-2020 Available Online: 21-10-2020

Access this article online

Quick Response Code:



Website:
www.afrijpaedsurg.org

DOI:
10.4103/ajps.AJPS_64_20

This is an open access journal, and articles are distributed under the terms of the Creative Commons Attribution-NonCommercial-ShareAlike 4.0 License, which allows others to remix, tweak, and build upon the work non-commercially, as long as appropriate credit is given and the new creations are licensed under the identical terms.

For reprints contact: WKHLRPMedknow_reprints@wolterskluwer.com

How to cite this article: Elgendy A, Lakshminarayanan B, Elrouby A, Mostafa M, Salem MA, Turner K, *et al.* Management of pediatric benign ovarian tumors in England and Egypt: A comparative study. Afr J Paediatr Surg 2020;17:33-8.

the investigation of other issues such as menstrual irregularities or hydronephrosis.^[6,7]

An adequate understanding of the management of pediatric benign ovarian neoplasms is important, as surgeons encounter both emergency and elective presentations. Early diagnosis is a prerequisite for proper treatment and fertility preservation.^[8] The management options include oophorectomy or ovarian-sparing surgery (OSS), and recently, the surgical approaches have been expanded to the use of minimally invasive surgery (MIS) in addition to the conventional open approach.^[9]

The objectives of this study were to compare the clinicopathological features and management strategies of benign ovarian tumors in children between an English-based tertiary referral center and three Egyptian tertiary institutions, including their affiliated hospitals.

MATERIALS AND METHODS

The authors retrospectively reviewed the medical records of all girls with benign ovarian tumors who were managed by the aforementioned centers in England and Egypt between January 2014 and January 2019. Simple ovarian cysts and torsions without an associated ovarian lesion were excluded from enrollment and analysis. Written informed consents were obtained from all parents or guardians before surgery, anesthesia, and data use in scientific purposes at the time of management.

Following the Institutional Review Board (IRB) approval from all participating institutions, a standardized dataset was designed by the first author, then was reviewed and approved by the second and senior authors. This uniform sheet was used to compare the patients' baseline criteria, diagnostic modalities, surgical approaches, types of surgery performed, histopathological types, and follow-up, including recurrence or metachronous disease between both countries. The WHO pathological classification of ovarian neoplasms was used throughout.^[10] Tumors' characteristics, including components and size were taken from preoperative radiology scans or postoperative pathology reports. Gonadal preservation was analyzed in correlation with the operative approach and the occurrence of ovarian torsion. Tumor size was assessed with respect to operative approach, MIS, or conventional open surgery. Follow-up data until January 2020 were collected. Recurrences or metachronous diseases were reported based on clinical signs, imaging, and biological markers.

Statistical analysis was performed using Student's *t* and Chi-square tests, in addition to the usual descriptive analysis. The quantitative variables were expressed as mean and standard deviation. We considered the statistical significance of the variables when $P \leq 0.05$.

RESULTS

Diagnosis

Eighty-nine children with unilateral tumors were included for analysis. There were 54 English and 35 Egyptian

patients. The median age at diagnosis in England was 13 years (range, 2–16 years), whereas in Egypt, it was 7 years (range, 9 months–16 years) with a significant difference ($P = 0.001$). In England, 31 patients (57.4%) were presented with chronic abdominal pain and/or a palpable mass, compared to 25 patients (71.4%) in Egypt. Emergency admissions with an acute abdomen secondary to ovarian torsion constituted 15 (27.8%) and 10 (28.6%) cases in England and Egypt, respectively. There were 8 (15%) English patients diagnosed with ovarian lesions during the investigation for other symptoms or diseases, whereas none of the Egyptian children were discovered incidentally. The preoperative clinical presentations in both countries are listed in Table 1.

Abdominal ultrasound (AUUS) was the primary imaging modality used for all patients in both countries. In England, magnetic resonance imaging (MRI) was the most common additional modality used in 37 (68.5%) patients, whereas 17 (48.5%) of Egyptian patients had computed tomography (CT) in addition to AUUS. The assessment of preoperative tumor markers included alpha-fetoprotein (AFP), human chorionic gonadotropins (HCG), and cancer antigen 125 (CA 125). The results of these markers were available for 69 cases (44 English and 25 Egyptians). In England; AFP and HCG levels were assessed in 32 patients, whereas AFP, HCG and CA125 were assessed in 12. In Egypt; AFP and HCG levels were assessed in 25 patients. Elevated serum tumor markers were found in 12 patients: seven and five patients from England and Egypt, respectively. For girls who presented as an emergency, 13 English cases had preoperative tumor markers compared with only one Egyptian case. Mature teratomas or dermoid cysts were the most common

Table 1: Clinical presentation

Main symptoms and signs	Number of patients (%)
England (54 patients)	
Acute abdomen	15 (27.8)
Chronic abdominal pain	12 (22.2)
Incidental	8 (14.8)
Menstrual irregularities	2
UTI	1
Constipation	1
Type 2 DM and obesity	1
Horseshoe kidney during follow-up	1
Clicky hips during follow-up	1
Renal cyst during follow-up	1
Abdominal pain and palpable mass	6 (11.1)
Palpable mass	7 (13)
Abdominal distention and increased girth	6 (11.1)
Egypt (35 patients)	
Acute abdomen	10 (28.6)
Palpable abdominal mass	10 (28.6)
Abdominal pain and palpable mass	8 (22.8)
Chronic abdominal pain	7 (20)

UTI: Urinary tract infection, DM: Diabetes mellitus

pathological findings reported: 41 (75.9%) of English patients and 29 (82.8%) of Egyptian patients. Five children with pure high-grade immature teratoma were included (3 English and 2 Egyptians). Table 2 summarizes the comparison between both countries regarding age, radiology modalities, biological markers, and pathological types.

Management

All children included in this study were surgically managed. Diagnostic laparoscopy was performed in four cases because of diagnostic uncertainty; in one and three cases in England and Egypt, respectively. The four patients had mature teratomas, and all converted into open surgery. Open conventional surgery was the most common surgical approach used, 85.2% of English and 77.2% of Egyptian cases. In England, MIS was performed in 8 (14.8%) patients (6 by laparoscopic surgery and 2 by robotic surgery) compared to 8 (22.8%) Egyptian patients (laparoscopic MIS). There was no significant difference ($P = 0.334$) between both countries with regard to the surgical approach. Oophorectomy was performed in 65% of English patients compared to 63% of Egyptian patients. OSS was performed in 35% and 37% of cases in England and Egypt, respectively. There was no statistical significance between the two countries ($P = 0.851$) with respect to the surgical procedure performed. Surgical approaches and types of surgery performed are shown in Figures 1 and 2.

In both countries, MIS had a significant correlation with ovarian tissue preservation. Out of 19 English patients who had OSS, 7 were managed by MIS when compared to only one patient

who underwent a laparoscopic oophorectomy ($P < 0.001$). All 8 Egyptian children who were treated using MIS had tumor resection with gonadal preservation ($P < 0.001$). Median tumor diameters in MIS operations were significantly smaller than those in the conventional surgery group: England 7 cm (range, 5–9) versus 14 cm (range, 7.5–23), $P = 0.001$; Egypt 5.5 cm (range, 3.5–8) versus 12.5 cm (range, 9–20), $P = 0.001$.

Children who presented as a surgical emergency were generally managed by an open oophorectomy. Twelve English patients (80%) underwent oophorectomy versus 9 Egyptian patients (90%). Only 2 English children (13.3%) had MIS, whereas none of the Egyptian cases underwent MIS procedures in the emergency situation. Figure 3 shows the management of patients with ovarian torsion in both countries.

Table 2: Comparison of age, radiology, biological markers, and pathological types between countries

Parameters	England (n=54)	Egypt (n=35)
Age		
Mean (years)	11.49±3.4	6.42±3.87
Range	2-16 years	9 months-16 years
Imaging modality		
US	54	35
MRI	37	1
CT	1	17
Tumor markers		
Available	44	25
Elevated	7	5
Normal	37	20
Not done	4	10
Missed	6	-
Pathology, n (%)		
Mature teratoma	33 (61.1)	22 (62.8)
Dermoid cyst	8 (14.8)	7 (20)
Cystadenoma (serous or mucinous)	8 (14.8)	4 (11.5)
Papillary serous cystadenofibroma	2 (3.7)	-
Immature teratoma	3 (5.6)	2 (5.7)

US: Ultrasound, MRI: Magnetic resonance imaging, CT: Computed tomography

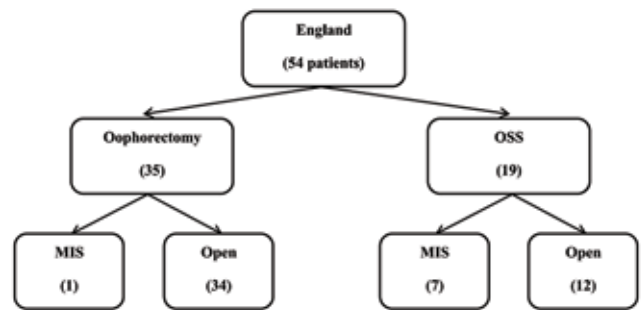


Figure 1: Surgical approach and type of surgery performed in English patients

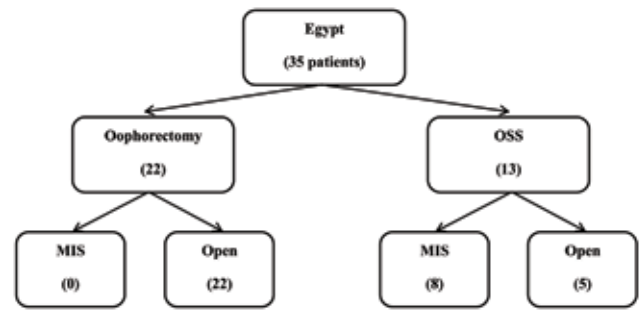


Figure 2: Surgical approach and type of surgery performed in Egyptian patients

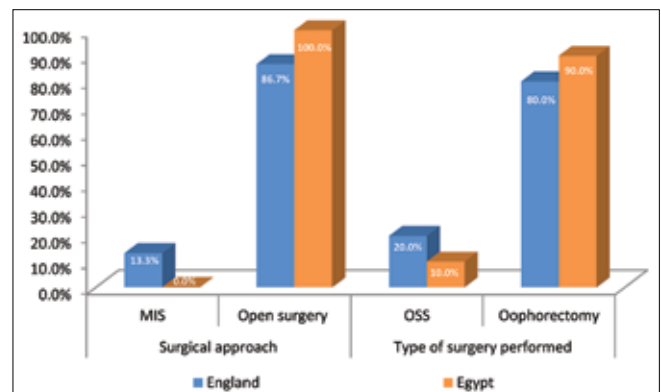


Figure 3: Management of patients with ovarian torsion in both countries

Operative staging procedures were performed in England as follows: 18 cases had collection of peritoneal fluid, two underwent omentectomy, and one case had para-aortic lymph node sampling. In Egypt, there were five patients who underwent peritoneal fluid aspiration. Procedures were performed relying on intraoperative suspicion of the pathological type of tumor, and all these procedures were negative for malignancy in both countries. All tumors were completely resected and there were no intraoperative complications. Postoperative complications occurred in two English patients; one wound infection and one hypertrophic scar, and in two Egyptian patients; one incisional hernia and one wound infection.

Follow-up

There were no deaths in the series. Three English patients (5.6%) had a recurrence or metachronous disease in comparison to two (5.7%) Egyptian patients. All cases were discovered by postoperative imaging studies. In England, there were two patients presented with the metachronous disease after being treated initially by classic oophorectomies, whereas one patient developed tumor recurrence following laparoscopic OSS. In Egypt, two girls had metachronous lesions after open oophorectomy. All cases with metachronous disease or recurrence in both countries were managed by conventional OSS. All patients with pure immature teratomas were Stage I and did not receive adjuvant therapy. They have been followed up with regular imaging and tumor markers assay, with no evidence of recurrence.

DISCUSSION

This study compares the management of pediatric benign ovarian tumors between two different countries. We observed that Egyptian patients presented at a significantly younger age than English patients. Differences in referral patterns could explain this. Other studies have shown that the median age varied from 9 to 17 years between different countries.^[11-14]

In this study, over 25% of patients in both countries presented with an acute abdomen and ovarian torsion that required urgent surgery. Similar findings were reported by previous studies.^[7,11] Although the clinical presentations of elective patients were nearly identical in the two countries, incidentally diagnosed patients were only seen in England. This significant observation can direct the Egyptian authors to inform parents and physicians that a remarkable percentage of such tumors can be discovered during follow-up of certain conditions or with other unrelated symptoms.

Radiological imaging is essential in the diagnosis of any ovarian pathology, and AUUS still remains the first imaging test of choice when assessing such neoplasms.^[15] Nevertheless, it is recommended to perform additional studies such as CT or MRI if complex lesions are identified by AUUS, especially if OSS is planned.^[6] The present study demonstrated notable difference regarding the second imaging modality between the two countries, with CT scanning mainly adopted in Egypt, whereas MRI was the principal study modality in England.

Abdominal CT offers a faster scanning time; mostly, it does not need sedation and may be better for tumor staging.^[16] In contrast, MRI does not expose children to radiation and may show superior results compared to CT in the diagnosis of pelvic lesions.^[13,17] Finally, the expertise of radiologists or institutional guidelines might decide the modality, CT or MRI.

Serum biological markers are imperative in the assessment of any pediatric ovarian tumor, however they are not always within the normal range in some benign lesions as Spinelli *et al.* observed. They found that 20% of benign entities had elevated markers.^[18] In this study, raised tumor markers were also encountered in 13% and 14% of English and Egyptian patients, respectively. Interestingly, Loh *et al.* reported AFP specificity of 88% and sensitivity of 50% for benign versus malignant tumors.^[19] As a consequence, the management of these neoplasms cannot be only based on markers results, and clinical, imaging, and histopathological correlations are crucial for correct decision-making.

This study did not reveal any significant difference between both countries regarding the surgical approach used for management. Open classical surgery was adopted for the majority, whereas MIS was performed in only selected patients. The adoption of the MIS technique was principally based on tumor diameter in our study. This is similar to the study by Michelotti *et al.* who reported median sizes of 6 cm versus 11.5 cm between MIS and laparotomy groups, respectively.^[9] Similarly, in two recent surveys conducted among pediatric surgeons in both countries, 55% and 62% of English surgeons with and without an oncology interest would perform MIS in benign-looking tumors with diameters between 3 and 10 cm, and 66% of all Egyptian surgeons would do the same.^[20,21] Features such as cystic lesions, with a maximum of 8–10 cm, and negative markers are more likely to be predictive of benign nature, as previously reported.^[10,22] Laparoscopic management of ovarian tumors is an accepted modality with well-known advantages, however careful selection of patients is fundamental to avoid potential complications such as rupture and spillage.

In this study, the type of surgery performed did not differ significantly between the two countries, and OSS was applied in the presence of a clear plane between the tumor wall and normal ovarian tissue. Based on the fact that vast majority of ovarian tumors in children are of benign nature, OSS should be considered for every patient whenever possible. This approach is supported by 94% and 79% of English surgeons with and without an oncology interest and also by 82% of all Egyptian surgeons in the previously mentioned practice-based surveys.^[20,21]

We demonstrated that gonadal preservation was significantly correlated with the use of MIS in both English and Egyptian patients. The link between the laparoscopic approach and OSS has been previously reported.^[16,23,24] The authors of this study believe that high magnification of endoscopic camera and availability of energy devices in addition to the

dissection on small-sized lesions are reasonable explanations for such a correlation. In the present study, oophorectomy was more commonly performed in patients with ovarian torsion. Gonzalez *et al.* similarly found that children with emergency admissions were significantly less likely to have OSS.^[25] Rousseau *et al.*, however, reported that about half of their patients were managed by OSS, and this difference could be attributed to the time of referral or discovery of torsion.^[26] It is imperative that any girl presenting with an acute abdomen, ovarian torsion has to be excluded, as early detection could save the patient's ovary.

The analysis of tumor pathology demonstrated that there was a very similar spectrum between both countries. Two cases of papillary serous cystadenofibroma were observed in English patients, but none within the Egyptian cohort. Immature teratoma is a distinct pathological subtype where there is still ongoing debate regarding the necessity of adjuvant chemotherapy. All adult women with immature teratoma should receive postoperative chemotherapy except stage IA low grade, whereas surgery and surveillance are sufficient in girls with completely resected tumors regardless of their grading.^[27] In our study, all cases of immature teratomas were managed by complete surgical resection only. At the end of the follow-up period, they were all disease free. Tumor recurrence and metachronous disease percentages were the same in both countries. These variables remain controversial, Taskinen *et al.* showed that 23% of girls developed tumors in the contralateral ovary during their observation time.^[28] Other studies, however, did not report any recurrences or metachronous neoplasms,^[12,29] and probably a longer follow-up time is required for a more definitive answer.

Eventually; this study revealed that there was no significant difference in the management of ovarian tumors in children between England and Egypt. This reflects that practice in the pediatric oncology field is now more standardized, and the guidelines are followed within tertiary centers in different countries.

CONCLUSIONS

There were no significant differences in surgical management, tumor pathology, and recurrence or metachronous disease between both countries. However, age at presentation, incidental diagnosis, and imaging modalities showed notable differences. In England and Egypt, MIS was significantly correlated with ovarian tissue preservation and tumor size was a significant factor for the adoption of MIS. Patients presenting as surgical emergencies due to torsion were generally managed by open oophorectomies in both countries.

Acknowledgment

The authors would like to thank Mr. Ahmed Samir Ryad for the technical assistance in the manuscript.

Financial support and sponsorship

Nil.

Conflicts of interest

There are no conflicts of interest.

REFERENCES

- Zhang M, Jiang W, Li G, Xu C. Ovarian masses in children and adolescents-An analysis of 521 clinical cases. *J Pediatr Adolesc Gynecol* 2014;27:e73-7.
- Lindfors O. Primary ovarian neoplasms in infants and children. A study of 81 cases diagnosed in Finland and Sweden. *Ann Chir Gynaecol Fenn Suppl* 1971;177:1-66.
- Martelli H, Patte C. Gonadal tumours in children. *Arch Pediatr* 2003;10:246-50.
- Ehrlich PF, Teitelbaum DH, Hirschl RB, Rescorla F. Excision of large cystic ovarian tumors: Combining minimal invasive surgery techniques and cancer surgery-the best of both worlds. *J Pediatr Surg* 2007;42:890-3.
- Sarnacki S, Brisse H. Surgery of ovarian tumors in children. *Horm Res Paediatr* 2011;75:220-4.
- Al Jama FE, Al Ghamdi AA, Gasim T, Al Dakheel SA, Rahman J, Rahman MS. Ovarian tumors in children and adolescents-A clinical study of 52 patients in a university hospital. *J Pediatr Adolesc Gynecol* 2011;24:25-8.
- Cass DL, Hawkins E, Brandt ML, Chintagumpala M, Bloss RS, Milewicz AL, *et al.* Surgery for ovarian masses in infants, children, and adolescents: 102 consecutive patients treated in a 15-year period. *J Pediatr Surg* 2001;36:693-9.
- Spinelli C, Pucci V, Strambi S, Piccolo RL, Martin A, Messineo A. Treatment of ovarian lesions in children and adolescents: A retrospective study of 130 cases. *Pediatr Hematol Oncol* 2015;32:199-206.
- Michelotti B, Segura BJ, Sau I, Perez-Bertolez S, Prince JM, Kane TD. Surgical management of ovarian disease in infants, children, and adolescents: A 15-year review. *J Laparoendosc Adv Surg Tech A* 2010;20:261-4.
- Hayes-Jordan A. Surgical management of the incidentally identified ovarian mass. *Semin Pediatr Surg* 2005;14:106-10.
- De Backer A, Madern GC, Oosterhuis JW, Hakvoort-Cammel FG, Hazebroek FW. Ovarian germ cell tumors in children: A clinical study of 66 patients. *Pediatr Blood Cancer* 2006;46:459-64.
- Özcan R, Kuruoğlu S, Dervişoğlu S, Eliçevik M, Emir H, Büyükkunal C. Ovary-sparing surgery for teratomas in children. *Pediatr Surg Int* 2013;29:233-7.
- Emil S, Youssef F, Arbash G, Baird R, Laberge JM, Puligandla P, *et al.* The utility of magnetic resonance imaging in the diagnosis and management of pediatric benign ovarian lesions. *J Pediatr Surg* 2018;53:2013-8.
- Ryoo U, Lee DY, Bae DS, Yoon BK, Choi D. Clinical characteristics of adnexal masses in Korean children and adolescents: Retrospective analysis of 409 cases. *J Minim Invasive Gynecol* 2010;17:209-13.
- Deligeoroglou E, Eleftheriades M, Shiadoes V, Botsis D, Hasiakos D, Kontoravdis A, *et al.* Ovarian masses during adolescence: Clinical, ultrasonographic and pathologic findings, serum tumor markers and endocrinological profile. *Gynecol Endocrinol* 2004;19:1-8.
- Luczak J, Baglaj M. Selecting treatment method for ovarian masses in children – 24 years of experience. *J Ovarian Res* 2017;10:59.
- Balan P. Ultrasonography, computed tomography and magnetic resonance imaging in the assessment of pelvic pathology. *Eur J Radiol* 2006;58:147-55.
- Spinelli C, Pucci V, Buti I, Liserre J, Messineo A, Bianco F, *et al.* The role of tumor markers in the surgical approach of ovarian masses in pediatric age: A 10-year study and a literature review. *Ann Surg Oncol* 2012;19:1766-73.
- Loh AH, Gee KW, Chua JH. Diagnostic accuracy of preoperative alpha-fetoprotein as an ovarian tumor marker in children and adolescents: Not as good as we thought? *Pediatr Surg Int* 2013;29:709-13.
- Braungart S, Craigie RJ, Losty PD. Controversies in the management of ovarian tumours in prepubertal children-A BAPS and UK CCLG surgeons cancer group national survey. *J Pediatr Surg* 2018;53:2231-4.
- Elgendy A, Shehata S. National survey on current management of ovarian tumors in pediatric age group. *Egypt Pediatr Assoc Gaz* 2018;66:91-95.

22. Papic JC, Finnell SM, Slaven JE, Billmire DF, Rescorla FJ, Leys CM. Predictors of ovarian malignancy in children: Overcoming clinical barriers of ovarian preservation. *J Pediatr Surg* 2014;49:144-7.
23. Karpelowsky JS, Hei ER, Matthews K. Laparoscopic resection of benign ovarian tumours in children with gonadal preservation. *Pediatr Surg Int* 2009;25:251-4.
24. Malkan AD, Loh AH, Sandoval JA. Minimally invasive surgery in the management of abdominal tumors in children. *J Pediatr Surg* 2014;49:1171-6.
25. Gonzalez DO, Cooper JN, Aldrink JH, Hewitt GD, Fallat ME, Minneci PC, *et al.* Variability in surgical management of benign ovarian neoplasms in children. *J Pediatr Surg* 2017;52:944-50.
26. Rousseau V, Massicot R, Darwish AA, Sauvat F, Emond S, Thibaud E, *et al.* Emergency management and conservative surgery of ovarian torsion in children: A report of 40 cases. *J Pediatr Adolesc Gynecol* 2008;21:201-6.
27. Faure-Contier C, Pashankar F. Immature ovarian teratoma: When to give adjuvant therapy? *J Pediatr Hematol Oncol* 2017;39:487-9.
28. Taskinen S, Urtane A, Fagerholm R, Lohi J, Taskinen M. Metachronous benign ovarian tumors are not uncommon in children. *J Pediatr Surg* 2014;49:543-5.
29. Manjiri S, Padmalatha SK, Shetty J, Ahmed A, Monita N. Prospective observational study of ovarian tumors among children in tertiary care Indian teaching hospital. *Indian J Gynecol Oncolog* 2015;13:14.