

Submitted: 05/09/2017

Accepted: 16/03/2018

Published: 22/03/2018

Correlations between the equine metacarpophalangeal joint angulation and toe conformation in statics

Jenny Hagen^{1,*}, Kaid Kojah¹ and Michael Geiger²

¹Institute of Veterinary Anatomy, Histology and Embryology, Faculty of Veterinary Medicine, Leipzig University, Germany

²University Hospital for Horses, Faculty of Veterinary Medicine, Leipzig University, Germany

Abstract

The angulation of the equine fetlock determines the load of associated tendons and probably their predisposition for injuries. However, it is questionable how the individual toe conformation and tendon properties interact with the dorsal metacarpophalangeal joint angle (DMPJ). Data are needed for a tangible evaluation of the equine limb conformation for more specific orthopaedic treatment. The aim was to evaluate the correlation between the DMPJ, toe conformation and cross-sectional area (CSA) of both flexor tendons; the superficial digital flexor tendon (SDFT) and deep digital flexor tendon (DDFT). Thirty Warmblood horses were available for the study. Lateromedial radiographs of the toe and fetlock and transverse ultrasound images of both flexor tendons were obtained from three zones. The DMPJ, length and angle of the phalanges and CSA SDFT/DDFT were measured. In addition, hoof angle, wither height, age, and sex were documented. Correlations were calculated using Pearson's test. A paired t-test was used to evaluate left-right differences. Length and angle of the proximal and middle phalanx were significantly associated with the DMPJ ($r = -0.28 - -0.45$, $p < 0.001 - 0.04$). Neither the angle of the hoof and distal phalanx nor the CSA SDFT/DDFT, showed a noticeable correlation with the DMPJ. Significant left-right differences occurred for the DMPJ ($p < 0.002$) and the angle of the proximal and middle phalanx ($p < 0.01 - 0.002$). A moderate negative correlation was shown between the DMPJ and wither height ($r = -0.31$, $p = 0.04$). Results represent only a specific population. The study provides only a static evaluation of a dynamic situation. In a clinical context, it might be useful to focus on the angulation and length of the pastern to evaluate the individual load affecting the DMPJ and its associated structures. These findings might be relevant for orthopaedic treatments and shoeing recommendations.

Keywords: Fetlock, Flexor tendons, Horse, Joint angle, Toe conformation.

Introduction

The incidence of disorders affecting the metacarpophalangeal joint (MPJ) and its associated structures is reported to be high in equine athletes (Dyson, 2002; Murray *et al.*, 2010). Therefore, the equine fetlock is of significant interest in diagnostics and treatment (Floyd and Mansmann, 2007; Ross and Dyson, 2011).

In particular, the sagittal angulation of the MPJ determines the load on associated tendons and ligaments and their susceptibility to injuries (Rooney, 1984; Weller *et al.*, 2006; Lawson *et al.*, 2007). The equine fetlock provides dynamic stability due to its complex architecture and strongly extended orientation (Clayton *et al.*, 1998; Hodson *et al.*, 2000; Dyce *et al.*, 2010).

The equine limb acts as a mass-spring system due to the extension of the MPJ and the elastic recoil in long tendons of the distal limb (Clayton *et al.*, 1998; McGuigan and Wilson, 2003; Patel, 2010). In particular, the superficial digital flexor tendon (SDFT) is specialised for enhanced elastic energy storage

(Biewener, 1998; McNeill Alexander, 2002; Dowling and Dart, 2005). Additionally, both flexor tendons and further associated structures are arranged and interact as suspensory apparatus of the MPJ. These structures support the MPJ in resisting hyperextension during load (Dyce *et al.*, 2010). High load causes a high incidence of pathologies in these structures (Dyson, 2002; Murray *et al.*, 2010), as is frequently seen in the SDFT and DDFT (Dowling *et al.*, 2000; Patterson-Kane and Firth, 2009).

The dorsal metacarpophalangeal joint angle (DMPJ) determines the degree of extension in the fetlock. It is reported to be one evaluable parameter that can be used to estimate the load affecting the MPJ and the flexor tendons (Herbst, 1985; Anderson *et al.*, 2004). Corrective shoeing is frequently used to influence the hoof angulation with the intention to change the DMPJ to relieve associated structures, such as the SDFT or DDFT (Crevier-Denoix *et al.*, 2001; Denoix *et al.*, 2007; Lawson *et al.*, 2007). The individual DMPJ seems to be influenced by further factors (Hüppler *et al.*, 2016; Hagen *et al.*, 2017).

*Corresponding Author: Dr. Jenny Hagen. Institute of Veterinary Anatomy, Histology and Embryology, Faculty of Veterinary Medicine, Leipzig University, An den Tierkliniken 43, 04103 Leipzig, Germany. Email: hagen@vetmed.uni-leipzig.de

The aim of the present study was to examine how the individual toe conformation and the dimensions of supporting structures, such as the cross-sectional area (CSA) of both flexor tendons, are associated with the DMPJ. These objective data shall provide a base for a tangible evaluation of the equine limb conformation as a basis for more specific orthopaedic treatment, trimming or shoeing (Denoux *et al.*, 2007; Floyd and Mansmann, 2007). Therefore, this study examined the correlation between the individual toe conformation, the CSA SDFT/DDFT, and the DMPJ based on the following hypotheses:

1. No significant left–right differences in the DMPJ occur in the forelimbs of an individual horse.
2. The steeper the dorsal wall angle of the hoof (DWA) or the angle of the distal phalanx in relation to the ground (APIII), the lower the DMPJ.
3. The longer length of the proximal phalanx (LenPI), length of the middle phalanx (LenPII) and lower angle of the proximal phalanx in relation to the ground (API), angle of the middle phalanx in relation to the ground (APII) the proximal and middle phalanx, the lower the DMPJ.
4. The larger the CSA SDFT/DDFT, the lower the DMPJ.
5. Withers height is correlated with the DMPJ, whereas sex and age do not interact with this parameter.

Materials and Methods

Animals

A cohort of 30 clinically sound Warmblood horses without any history of orthopaedic disorders was selected from a larger population (n = 110) of horses resident in two riding stables. The horses showed the following signalment: mean withers height measured at the fifth thoracic vertebra 155.24 cm (145–172 cm), mean age 12.24 years (4–25 years), 15 geldings, 15 mares; breeds: 13 German Warmbloods, 2 Oldenburger, 5 Pura Raza Espanola, 10 Warmblood crossbreed. All animals were kept, fed, managed, and used under similar conditions. In both stables all the horses experienced 8–14 hours of exercise per week. No high performance horses used for a specific discipline were included in this study. All horses were barefoot and trimmed regularly. Before the beginning of the study, the horses were clinically, orthopaedically, sonographically (SDFT, DDFT), and radiologically (overview toe, lateromedial and dorsopalmar projection) examined by 2 independent veterinarians. The orthopaedic examination included inspection, palpation, and a lameness exam on hard and soft surface. Based on all examinations, horses with orthopaedic disorders or other diseases were excluded. Before any examination, the hooves were trimmed by the same certified farrier to ensure an equal hoof status. The trim was performed by cleaning the frog and removing the brittle horn of the sole to show the length

of the overgrown weight bearing margin, which was shortened following the level of the cleaned sole. Severe reorientation of the limb and straightening of the outer hoof wall was avoided. Horses with severe flares in the dorsal hoof wall were excluded.

Ethical approval

This study was approved as an animal experiment by the Ethics Committee of the Thuringian state authority (Landesdirektion Thüringen, Office Langensalza) (Permit No: 15-003/15). Client-owned horses were included with informed consent. All parameters, their abbreviations and references are described in Figure 1 and Table 1.

Assessment of withers height and DWA

The withers height of all horses was assessed with a standardised [Albenisa: Handmeasure for horses, ALBENISA GmbH, Friedensstraße 13a, 06184 Kabelsketal, Germany] horse measuring stick marked with hand measures. A [Dallmer gauge: Dallmer Hoof Gauge, Dallmer GmbH + Co. KGWiebelsheidestr. 25, 59757 Arnsberg, Germany] was used to measure the DWA (Moleman *et al.*, 2005). This gauge uses the ground plane and an area of contact on the dorsal hoof wall and measures the angle of the loaded foot. All measurements were performed three times by the same operator. For further analysis the mean values of all three measurements were used. The horses had to stand square and relaxed on a plane concrete surface.

Radiographic examination

The radiographic examinations were carried out by using a portable x-ray unit [Gierth HF80 MLul@: Gierth X-Ray International, Riesa, Sachsen, Germany] and a digital detector system [SCOPE–XXS 80C, Detector Canon CXDI-80C wireless: Canon Inc., Tokyo, Ohta-ku, Japan]. A standardised setup (60kV, 0.2mAs/s, focus-film distance 75cm) was followed. Initially, the hooves were permanently marked according to published guidelines to ensure a standardised centring of the radiation beam (Caudron *et al.*, 1997). Two radiographs were acquired respectively for the left and the right front foot. First, a lateromedial radiograph with the x-ray beam centred in the midline of the dorsal hoof wall, 2 cm over the weight bearing margin to visualise the distal and the middle phalanx was produced (Caudron *et al.*, 1997; Kummer *et al.*, 2006). Second, the beam was centred on the MPJ to obtain a lateromedial projection representing the proximal phalanx, the sesamoid bones, and at least the distal third of the metacarpal bone. The horses were standing square with a straight body axis and relaxed with both forelimbs positioned parallel on a 6 cm podoblock [MetronPX podoblock: EponaTech LLC, Creston, CA, USA] with embedded reference marks for subsequent analyses (Rocha *et al.*, 2004). If the podoblock was not in the examination window, the calibration aid [Metron Auto-Scaler: EponaTech LLC,

Creston, CA, USA] was attached in the region of the fetlock including the same reference points as the podoblock to calibrate the software for magnification and distortion of the radiographs. No sedation was necessary. All radiographs were directly monitored on the computer screen to check consistency of quality and projection according to guidelines published by Dyson *et al.* (2011). Radiograph image control involved the assessment of parallelism of the condyles of the middle and proximal phalanx, superimposition of the lateral and medial solar borders and the palmar aspects of the extensor process of the distal phalanx and clearly defined interphalangeal joint spaces.

Ultrasound examination

The ultrasound examination was carried out directly after the radiographic examination. For the examinations, a portable ultrasound unit [Honda electronics HS-1200V: Honda Electronics Co., LTD., Aichi 441-3193, Japan] and a variable frequency linear transducer [Honda electronics HLS 584M linear probe: Honda Electronics Co., LTD., Aichi 441-3193, Japan] (6.0-11MHz; Width: 40mm), set at 8.5 MHz and a field depth of 4 cm with a stand-off pad to ensure optimal coupling, were used. The palmar aspect of the metacarpus was clipped and scrubbed with alcohol. [Ultrasound coupling gel: DocCheck Ultraschall-Gel, DocCheck Medizinbedarf und Logistik GmbH, Weil im Schönbuch, Germany] was applied prior to and during the examination. The probe was placed at the most palmar aspect of the metacarpal region, perpendicular to its surface. Dividing the metacarpal region into different zones is an established method in equine practice to compare the morphology of the DDFT and SDFT throughout both their ranges where most pathologies are likely to occur (Denoix, 1994; Dowling *et al.*, 2000; Dyson, 2002). Within each of the three previously described zones, specific points were chosen for examination. Transverse images of the SDFT and the DDFT were acquired at 8 cm (zone B1), 12 cm (zone A2), and 16 cm (zone B2) distal to the accessory carpal bone according to Padaliya *et al.* (2015) (Figure 1).

The probe was manipulated in all planes to obtain an optimal image showing the widest CSA possible of each tendon at the specific zone. To analyse the ultrasound images, a frozen representative image of the SDFT and the DDFT of each level was saved when the accurate identification and tracking of the outer margin of both flexor tendons was possible.

Data analysis

Parameters of interest, their references and interpretation are shown in Figure 1 and Table 1. The Dicom files generated during the radiographic examinations were converted into JPEG files and imported into the software [MetronPXH hoof®: EponaTech LLC, Creston, CA, USA].

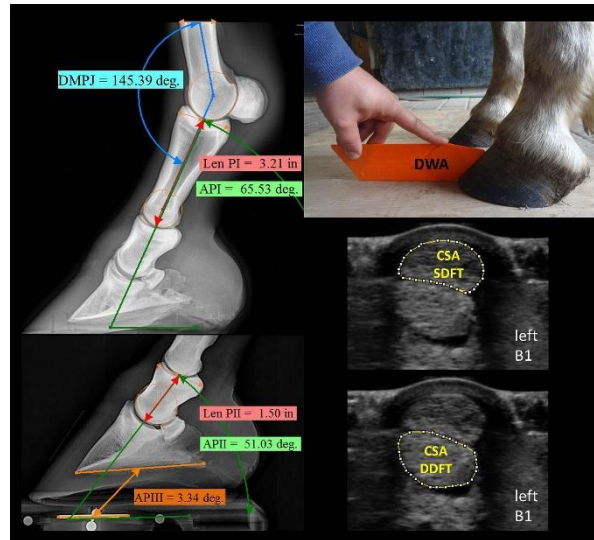


Fig. 1. Parameters of interest and their references.

After calibration, the parameters of interest were measured three times by the same person and by following standardised references (Table 1). All ultrasound images were analysed using the image processing software [ImageJ: vers. 2.0.0-rc-39/1.50b; Build: 8dcf1e65a6 Copyright 2010-2017]. The CSA SDFT and the DDFT was measured three times by one operator by outlining the structures of interest with a cursor and then calculating the encompassed area. The person responsible for data analysis was not involved in data acquisition and was blinded to the hypothesis of this study. The average of all three measurements was used for further calculations.

Statistical analysis

Statistical analysis was carried out with the software [R: A language and environment for statistical computing, R Foundation for Statistical Computing, Vienna, Austria]. Significance tests for normally distributed data were performed using the 'Welch t-test'. Mean and standard deviations were calculated for all parameters of interest. To assess the relationships between the measured variables, pairwise correlations were calculated (Pearson). Correlations between the variables based on the calculations were interpreted as followed: $r < 0.19$ – no correlation, $r > 0.2$ and < 0.29 – weak correlation, $r > 0.3$ and < 0.49 – moderate correlation, $r > 0.5$ and < 0.69 – strong correlation, $r > 0.7$ and < 0.99 – very strong correlation, $r = 1$ – perfect correlation. A paired t-test was used to evaluate the left–right differences. The significance level was set to $p < 0.05$.

Results

$N = 30$ horses were included into the calculations. Data were normally distributed. Mean value, standard deviation of all measures and p-value of the left–right differences between both forelimbs are shown in Table 2.

Table 1. Parameters of interest with their abbreviations, references and interpretation.

Parameter (Unit) - Abbreviation	References	Increase	Decrease
Dorsal metacarpophalangeal joint angle (°) - DMPJ	rotation centre at the condyles of the metacarpal bone (point 1) and the proximal phalanx (point 2), middle of the metacarpal bone in the most proximal aspect (point 3)	decreased extension in the MPJ	increased extension in the MPJ
Dorsal wall angle of the hoof (°) - DWA	midline of the dorsal hoof wall parallel to the horn tubules	steep hoof orientation	flat hoof orientation
Angle of the proximal phalanx in relation to the ground (°) - API	horizontal determined by Metron reference combined with a line through the rotation centre at the condyles and the middle of the proximal phalanx	steep orientation of the proximal phalanx	flat orientation of the proximal phalanx
Angle of the middle phalanx in relation to the ground (°) - APII	horizontal determined by Metron reference combined with a line through the rotation centre at the condyles and the middle of the middle phalanx	steep orientation of the middle phalanx	flat orientation of the middle phalanx
Angle of the distal phalanx in relation to the ground (°) - APIII	angulation of a line from the apex to the end of the palmar processes of the distal phalanx in relation to a horizontal determined by Metron references	steep orientation of the distal phalanx	flat orientation of the distal phalanx
Length of the proximal phalanx (cm) - LenI Length of the middle phalanx (cm) - LenII	longest distance between proximal and distal joint surface	long proximal phalanx	short proximal phalanx
Cross-sectional area of the superficial digital flexor tendon (mm ²) - CSA SDFT Cross-sectional area of the deep digital flexor tendon (mm ²) - CSA DDFT	tracking the outer margin of both flexor tendons in transverse ultrasound images	larger tendon	thinner tendon

Table 2. Mean and standard deviations of all parameters and differences between the left and the right forelimb.

Parameter	Left limb (mean ± SD)	Right limb (mean ± SD)	Diff. left-right (p-val.)
DWA (°)	49.45 ± 5.32	49.00 ± 4.47	0.11
APIII (°)	4.20 ± 3.50	4.1 ± 3.14	0.29
APII (°)	54.57 ± 6.90	50.31 ± 5.73	0.002
API (°)	69.89 ± 4.76	66.18 ± 6.34	0.01
DMPJ (°)	149.11 ± 5.33	148.16 ± 5.97	0.002
LenPII (cm)	4.28 ± 0.24	4.34 ± 0.29	0.28
LenPI (cm)	8.14 ± 0.52	8.12 ± 0.51	0.19
CSA SDFT 1B (mm ²)	7.99 ± 1.50	8.01 ± 1.47	0.95
CSA SDFT 2A (mm ²)	7.81 ± 1.59	7.83 ± 1.42	0.96
CSA SDFT 2B (mm ²)	8.21 ± 1.43	8.14 ± 1.23	0.83
CSA DDFT 1B (mm ²)	10.48 ± 1.87	10.15 ± 1.69	0.50
CSA DDFT 2A (mm ²)	9.88 ± 1.74	9.65 ± 1.56	0.61
CSA SDFT 2B (mm ²)	14.91 ± 2.00	14.46 ± 1.98	0.41

A significant difference (p=0.002) between the DMPJ of the left and the right limb occurred. Less extension in the left MPJ was found. Additionally, a left–right difference occurred for the orientation of the proximal and middle phalanges, API (p=0.01) and APII (p=0.002). At the left limbs a steeper orientation of the

middle and proximal phalanx occurred. No significant bilateral differences were shown for the DWA, APIII, LenPI, LenPII, or the CSA SDFT/DDFT at any zone. An overview of the correlation between the DMPJ and the toe conformation or the CSA of the flexor tendons is given in Table 3.

Table 3. Correlation between the parameters of interest, with $r = 1$ perfect correlation, 0.7–0.99 very strong correlation, 0.5–0.69 strong correlation, 0.3–0.49 moderate correlation, 0.2–0.29 weak correlation, ≤ 0.19 no correlation.

Parameter	DMPJ left		DMPJ right		Correlation
	Corr coef (r)	P value	Corr coef (r)	P value	
LenPI	-0.30	0.03	-0.45	0.01	moderate to strong correlation
LenPII	-0.28	0.04	-0.44	0.01	
API	0.41	0.02	0.38	0.03	
APII	0.63	< 0.001	0.40	0.02	
DWA	-0.17	0.34	0.05	0.77	No to weak correlation
APIII	-0.17	0.34	0.14	0.43	
CSA SDFT 1B	-0.03	0.88	-0.01	0.98	
CSA SDFT 2A	0.11	0.59	0.21	0.29	
CSA SDFT 2B	0.14	0.51	-0.13	0.50	
CSA DDFT 1B	-0.08	0.68	-0.01	0.98	
CSA DDFT 2A	0.01	0.96	0.05	0.81	
CSA SDFT 2B	-0.02	0.94	0.21	0.29	

Calculation of the interaction between the DWA and APIII with the DMPJ showed no correlation. The API, APII, LenI, and LenII showed the highest correlations with the DMPJ. At the left and in particular the right limb, the LenPI and the LenPII showed a moderate negative correlation with the DMPJ. The longer the proximal and middle phalanges, the smaller the DMPJ, indicating higher extension in this joint. Additionally, a moderate to strong correlation occurred between the DMPJ and the API and APII. The more upright the orientation of the proximal and middle phalanges, the greater the DMPJ, meaning less extension in this joint. No or only a very weak correlation between the DMPJ and the CSA of both flexor tendons was demonstrated at any level. A moderate correlation was shown between the DMPJ and the wither height ($r = -0.31$, $p=0.04$). Neither sex nor age had an impact on the DMPJ ($r < 0.19$).

Discussion

Although in the current examinations no left–right differences in the dorsal wall angle of the hoof or the sagittal orientation of the distal phalanx were shown, a significant uneven angulation of the middle and proximal phalanx and higher extension in the MPJ of the right limb was found. Therefore, hypothesis 1 was not confirmed. Other authors have stated the prevalence of uneven feet to be on average 5.3%, without providing specific data for the fetlock (Ducro *et al.*, 2009a). Most previous studies were performed to compare left–right symmetry in hooves. It has been stated that foals develop unevenness in the foot conformation as a consequence of an uneven loading pattern caused by a preference to protract the same limb systematically while grazing (Heel *et al.*, 2006).

Moreover, studies have shown a relationship between uneven feet and laterality connected with a side preference for trot-canter transition in young horses (Deuel and Lawrence, 1987; van Heel *et al.*, 2010). Considering handedness in horses, the same authors found that the right forelimb is preferentially used for support, and, as the trailing limb, it experiences greater stress than the leading left forelimb (Deuel and Lawrence, 1987; van Heel *et al.*, 2010). Based on these findings the authors of the current study assume that lateralised grazing and motor behaviour determining handedness and uneven load bearing in horses might also lead to asymmetry in the DMPJ, API, and APII with higher extension in the right MPJ. This is supported by the findings of previous radiographic examinations in 75 sound horses, which also showed a lower palmar angle of the middle (APII) and proximal (API) phalanx in the right feet (Hagen *et al.*, 2018). However, the correlation between these observations and lateralised grazing or motor behaviour requires further investigation. The relevance of 1° to 3° bilateral difference in DMPJ, APII or API on the load of joints, tendons or ligaments remains unclear. For differences in the palmar angle (APIII) of the distal phalanx it was demonstrated that for a 1° change in APIII the forces experienced by the DDFT changed by 4% (Eliashar *et al.*, 2004). Similar calculation about the relation between a 1° change in DMPJ, API, and APII are lacking, in particular for left-right differences in bilateral feet. Nevertheless, uneven feet conformation in horses is a frequently examined topic assumed to be of clinical relevance. It was shown that differences in the contralateral foot conformation are related to different lever arms affecting the digital joints

(Kroekenstoel *et al.*, 2006; van Heel *et al.*, 2010). In addition, the study by Ducro *et al.* (2009b) showed a relationship between uneven foot conformation and a shortened competitive life.

With regard to hypothesis 2, the individual hoof orientation and angle of the distal phalanx do not interact with the DMPJ. The length and sagittal orientation of the proximal phalanges have the greatest impact on the DMPJ, thus proving hypothesis 3. It can be confirmed, the longer the proximal phalanges, the higher the extension in the fetlock joint. This might be explained geometrically by the fact that with increasing length of these phalanges, a longer lever arm affects the fetlock joint. Furthermore, the present study showed that the lower the API and APII, the higher the extension of the fetlock joint. In line with earlier findings it seems highly probable that the conformation of the proximal locomotor system influences the DMPJ and not the hoof conformation (Hüpler *et al.*, 2016; Hagen *et al.*, 2017). It is likely that the orientation of the third metacarpal bone as well as the conformation of the upper locomotor system, such as the shoulder, elbow, or carpal joint, also have a strong influence on the DMPJ (Anderson *et al.*, 2004).

With regard to hypothesis 4 of the current study, it was assumed that flexor tendons with a larger CSA, in relation to wither height, cause decreased extension in the MPJ. The performed morphological measures do not allow any direct conclusions about mechanical properties of the tendons to be drawn. The extensional strain (ϵ) of a tendon is determined by the applied force (F), Young's Modulus (E) and the CSA (A), $= \frac{F}{E \cdot A}$. Thus, the larger the CSA, the lower the extensional strain of a tendon. It is assumed that with increasing CSA more passive support of the fetlock is provided. However, no correlations were found between the CSA and the DMPJ, but the digital flexor tendons have to be considered in context with their connected muscles. Kubo *et al.* (2010) showed that the passive stiffness of muscles in humans was independent of the elasticity of tendons. Whether or not the internal structure of the flexor tendons or the muscle stiffness interacts with the angulation of the MPJ is a topic that requires further examination.

Considering hypothesis 5, although the sex and age of an animal might also affect the tendon properties by hormones or age-related changes of the internal texture of the tissue (Gillis *et al.*, 1995; Blackburn *et al.*, 2004), no correlations between these factors and the DMPJ were shown. Furthermore, a moderate negative correlation between the height of the animals and the DMPJ was found. An increasing wither height was associated with higher extension in the MPJ, which has been confirmed with a mild positive correlation of wither height and LenPI, LenPII. In this context, weighing the horse would have been more valuable to

the correlation with the DMPJ. However, a precise weighing of the animals was not possible at the available location.

Study design and morphometric measurements

The examinations and measurements used in this study are commonly used techniques in equine practice. A standardised protocol for the radiographic and ultrasound examinations was followed. All horses were cooperative and calm.

The radiographic measurements with [MetronPXHoof: EponaTech LLC, Creston, CA, USA] were already evaluated as an objective method to analyse morphometric parameters of the equine foot (Rocha *et al.*, 2004). However, the authors want to stress that radiography is an examination technique that provides a two-dimensional image of a three-dimensional object representing a static snapshot of a dynamic situation. Due to this limitation, projection obliquity, superposition and distortion influence the measurements and might interact with the relevance of the observed 1° changes in DMPJ. However, due to the standardised measuring and analysis protocols the measuring error for this parameter was below 1° and obtained results are in line with previous findings where the same technique was used for data acquisition and analysis (Hagen *et al.*, 2018). In this study calibration aids were used and all images were checked for quality. Aid lines were drawn onto the radiographs using clear bony protuberances as a guide, and all measurements were taken by the same experienced operator, because bony references used for analysing the angles are subjective and difficult to standardise. However, the high standard deviation in the calculated angles might be in part related to the measurements. Nevertheless, the measure failure is not considered clinically relevant by other authors (Rocha *et al.*, 2004). The precision of ultrasound image acquisition and analysis to assess the CSA of both flexor tendons at different levels was tested in advance with the given setup under the same conditions and with the same operator. The overall concordance correlation coefficient for image acquisition was between 0.84 and 0.98 (CSA DDFT 2A) and > 0.99 (CSA SDFT) (Kojah *et al.*, 2017). The OCCC for the analysis of the CSA was > 0.99 for all zones at each tendon (Kojah *et al.*, 2017). These values and those stated by other authors prove the high accuracy and precision of the ultrasound examination performed in this study (Pickersgill *et al.*, 2001).

Due to the nature of radiographic and ultrasound imaging, presented results are only valid for static conditions. The study provides only a static evaluation of a dynamic situation. Load of the limbs and weight shift might interact with the DMPJ and the parameters found to be correlated to the extension of the fetlock. Furthermore, results are obtained only for a specific

population of horses. Examinations in other populations might differ in particular for the values obtained for the length and angle of the phalanges and the CSA of the SDFT and DDFT. Additionally, left-right differences might occur differently in other horses.

This study provides additional data about the angulation of the MPJ and how it is related to the toe conformation. Significant left-right differences in the DMPJ occurred for the individual horse. In the authors' opinion, the length and the sagittal orientation of the proximal phalanges might have a greater impact on the DMPJ than the hoof conformation, represented in the current study by the DWA and the APIII. In a clinical context, it might be useful to focus more on the conformation of the equine pastern during static and dynamic evaluation of the horse as a basis for orthopaedic treatment, trimming or shoeing. Further research on this topic is required.

Acknowledgements

Prof. Ch. K. W. Mülling, Stud farm Kappe, Lothar Kappe, Neustadt/Orla, Germany, Stud farm Schatz, Alexandra Schatz, Drebsdorf, Germany, Paul Tönnies, Elizabeth Kelly, Mandy Vogel. Sources of funding: Institute of Veterinary Anatomy, Faculty of Veterinary Medicine, Leipzig University and Saudi Arabian Embassy Berlin/Cultural Bureau.

Conflict of interest

The authors declare that there is no conflict of interests.

References

- Anderson, T.M., McIlwraith, C.W. and Douay, P. 2004. The role of conformation in musculoskeletal problems in the racing Thoroughbred. *Equine Vet. J.* 36, 571-575.
- Biewener, A.A. 1998. Muscle-tendon stresses and elastic energy storage during locomotion in the horse. *Comp. Biochem. Physiol. B Biochem. Mol. Biol.* 120, 73-87.
- Blackburn, J.T., Riemann, B.L., Padua, D.A. and Guskiewicz, K.M. 2004. Sex comparison of extensibility, passive, and active stiffness of the knee flexors. *Clin. Biomech.* 19, 36-43.
- Caudron, I., Miesen, M., Grulke, S., Vanschepdael, P. and Serteyn, D. 1997. Clinical and radiological assessment of corrective trimming in lame horses. *J. Equine Vet. Sci.* 17, 375-379.
- Clayton, H.M., Lanovaz, J.L., Schamhardt, H.C., Willemen, M.A. and Colborne, G.R., 1998. Net joint moments and powers in the equine forelimb during the stance phase of the trot. *Equine Vet. J.* 30, 384-389.
- Crevier-Denoix, N., Roosen, C., Dardillat, C., Pourcelot, P., Jerbi, H., Sanaa, M. and Denoix, J.-M., 2001. Effects of heel and toe elevation upon the digital joint angles in the standing horse. *Equine Vet. J.* 33, 74-78.
- Denoix, J.-M. 1994. Diagnostic techniques for identification and documentation of tendon and ligament injuries. *The Veterinary Clinics of North America. Equine Pract.* 10, 365-407.
- Denoix, J.-M., Chateau, H. and Crevier-Denoix, N. 2007. Corrective shoeing of equine foot injuries. *Proceedings of the Geneva Congress of Equine Medicine and Surgery* 10, 136-143.
- Deuel, N.R. and Lawrence, L.M. 1987. Laterality in the gallop gait of horses. *J. Biomech.* 20, 645-649.
- Dowling, B.A., Dart, A.J., Hodgson, D.R. and Smith, R.K.W. 2000. Superficial digital flexor tendonitis in the horse. *Equine Vet. J.* 32, 369-378.
- Dowling, B.A. and Dart, A.J. 2005. Mechanical and functional properties of the equine superficial digital flexor tendon. *Vet. J.* 170, 184-192.
- Ducro, B.J., Bovenhuis, H. and Back, W. 2009a. Heritability of foot conformation and its relationship to sports performance in a Dutch Warmblood horse population. *Equine Vet. J.* 41, 139-143.
- Ducro, B.J., Gorissen, B., Eldik, P. and Back, W. 2009b. Influence of foot conformation on duration of competitive life in a Dutch Warmblood horse population. *Equine Vet. J.* 41, 144-148.
- Dyce, K.M., Sack, W.O. and Wensing, C.J.G. 2010. *Textbook of veterinary anatomy.* Saunders Elsevier, St. Louis, Mo.
- Dyson, S.J. 2002. Lameness and poor performance in the sports horse: Dressage, show jumping and horse trails. *J. Equine Vet. Sci.* 22, 145-150.
- Dyson, S.J., Tranquille, C.A., Collins, S.N., Parkin, T.D.H. and Murray, R.C. 2011. An investigation of the relationships between angles and shapes of the hoof capsule and the distal phalanx. *Equine Vet. J.* 43, 295-301.
- Eliashar, E., McGuigan, M.P. and Wilson, A.M. 2004. Relationship of foot conformation and force applied to the navicular bone of sound horses at the trot. *Equine Vet. J.* 36, 431-435.
- Floyd, A.E. and Mansmann, R.A. 2007. *Equine Podiatry.* Elsevier Saunders, Philadelphia, Pa, London.
- Gillis, C., Sharkey, N., Stover, S.M., Pool, R.R., Meagher, D.M. and Willits, N. 1995. Effect of maturation and ageing on material and ultrasonographic properties of equine superficial digital flexor tendon. *Am. J. Vet. Res.* 56, 1345-1350.
- Hagen, J., Hüppler, M., Geiger, S.M., Mäder, D. and Häfner, F.S. 2017. Modifying the height of horseshoes: Effects of wedge shoes, studs and rocker shoes on the phalangeal alignment, pressure

- distribution and hoof-ground contact during motion. *J. Equine Vet. Sci.* 53, 8-18.
- Hagen, J., Mäder, D., Wuttke, W. and Vogel, M. 2018. Short- and long-term effects of different hoof trimming methods on the equine phalangeal alignment. *Aust. Equine Vet.* 37, *in press*.
- Heel, M.C.V., Kroekenstoel, A.M., Dierendonck, M.C., Weeren, P.R. and Back, W. 2006. Uneven feet in a foal may develop as a consequence of lateral grazing behaviour induced by conformational traits. *Equine Vet. J.* 38, 646-651.
- Herbst H. 1985. Die Sehnenerkrankungen und ihre Beziehungen zur Stellung und Winkelung der Gliedmaße und zum Hufbeslag. *Z. Veterinärkrankheiten* 7, 149-157.
- Hodson, E., Clayton, H.M. and Lanovaz, J.L. 2000. The forelimb in walking horses: 1. Kinematics and ground reaction forces. *Equine Vet. J.* 32, 287-294.
- Hüppler, M., Häfner, F., Geiger, S., Mäder, D. and Hagen, J. 2016. Modifying the Surface of Horseshoes. Effects of Eggbar, Heartbar, Open Toe, and Wide Toe Shoes on the Phalangeal Alignment, Pressure Distribution, and the Footing Pattern. *J. Equine Vet. Sci.* 37, 86-97.
- Kojah, K., Vogel, M. and Hagen, J. 2017. Precision and accuracy of repeat ultrasound image acquisition and analysis of the cross-sectional areas of the equine flexor tendons of the forelimbs for follow-up assessments. *Pferdeheilkunde - Equine Med.* 33, 320-328.
- Kroekenstoel, A.M., Heel, M.C.V., Weeren, P.R. and Back, W. 2006. Developmental aspects of distal limb conformation in the horse. The potential consequences of uneven feet in foals. *Equine Vet. J.* 38, 652-656.
- Kummer, M., Geyer, H., Imboden, I., Auer, J. and Lischer, C. 2006. The effect of hoof trimming on radiographic measurements of the front feet of normal Warmblood horses. *Vet. J.* 172, 58-66.
- Lawson, S.E.M., Chateau, H., Pourcelot, P., Denoix, J.-M. and Crevier-Denoix, N. 2007. Effect of toe and heel elevation on calculated tendon strains in the horse and the influence of the proximal interphalangeal joint. *J. Anat.* 210, 583-591.
- McGuigan, M.P. and Wilson, M.A. 2003. The effect of gait and digital flexor muscle activation on limb compliance in the forelimb of the horse *Equus caballus*. *J. Exp. Biol.* 206, 1325-1336.
- McNeill Alexander, R. 2002. Tendon elasticity and muscle function. *Comp. Biochem. Physiol. A Mol. Integr. Physiol.* 133, 1001-1011.
- Moleman, M., van Heel, M.C.V., van den Belt, A.J.M. and Back, W. 2005. Accuracy of hoof angle measurement devices in comparison with digitally analysed radiographs. *Equine Vet. Educ.* 17, 319-322.
- Murray, R.C., Walters, J.M., Snart, H., Dyson, S.J. and Parkin, T.D.H. 2010. Identification of risk factors for lameness in dressage horses. *Vet. J.* 184, 27-36.
- Padaliya, N.R., Ranpariya, J.J., Kumar, D., Javia, C.B. and Barvalia, D.R. 2015. Ultrasonographic assessment of the equine palmar tendons. *Vet. World* 8, 208-212.
- Patel, B.A. 2010. The interplay between speed, kinetics, and hand postures during primate terrestrial locomotion. *Am. J. Phys. Anthropol.* 141, 222-234.
- Patterson-Kane, J.C. and Firth, E.C. 2009. The pathobiology of exercise-induced superficial digital flexor tendon injury in Thoroughbred racehorses. *Vet. J.* 181, 79-89.
- Pickersgill, C.H., Marr, C.M. and Reid, S.W.J. 2001. Repeatability of diagnostic ultrasonography in the assessment of the equine superficial digital flexor tendon. *Equine Vet. J.* 33, 33-37.
- Rocha, J.V., Lischer, C.J., Kummer, M., Hässig, M. and Auer, J.A. 2004. Evaluating the measuring software package Metron-PX for morphometric description of equine hoof radiographs. *J. Equine Vet. Sci.* 24, 347-354.
- Rooney, J.R. 1984. The angulation of the forefoot and pastern of the horse. *J. Equine Vet. Sci.* 4, 138-143.
- Ross, M.W. and Dyson, S.J. 2011. *Diagnosis and management of lameness in the horse*. Elsevier, Saunders, St. Louis, Mo.
- van Heel, M.C.V., van Dierendonck, M.C., Kroekenstoel, A.M. and Back, W. 2010. Lateralised motor behaviour leads to increased unevenness in front feet and asymmetry in athletic performance in young mature Warmblood horses. *Equine Vet. J.* 42, 444-450.
- Weller, R., Pfau, T., Verheyen, K., May, S.A. and Wilson, A.M. 2006. The effect of conformation on orthopaedic health and performance in a cohort of National Hunt racehorses. Preliminary results. *Equine Vet. J.* 38, 622-627.