



# Metastatic Malignant Melanoma of Brain: A Rare Case Report

Manoj Kumar Seervi<sup>1</sup> Surendra Jain<sup>1</sup> Ugan Singh Meena<sup>1</sup> Devendra Kumar Purohit<sup>1</sup>

<sup>1</sup> Department of Neurosurgery, Sawai Man Singh Medical College, Jaipur, Rajasthan, India

Address for correspondence Devendra Kumar Purohit, MCh Neurosurgery, Department of Neurosurgery, SMS Hospital, Jaipur 302004, Rajasthan, India (e-mail: devendrapurohit@rediffmail.com).

Asian J Neurosurg 2024;19:777–781.

## Abstract

Malignant melanoma is third most common cause of brain metastasis after lung and breast cancer. Most patients with brain metastases from malignant melanoma are diagnosed after treatment for known extracranial metastases and have a poor outcome despite various local and systemic therapeutic approaches. Here we discuss an unusual case of a 61-year-old male patient who presented with a brain metastasis as the initial disease presentation and the presumed primary lesion was later found in the gastrointestinal tract and the scalp. Treatment consisted of a surgical removal of the large intracranial lesion. Further evaluation for primary lesion was done by general physical examination, contrast-enhanced computed tomography (CECT) of the chest and whole abdomen. Apart from that, colonoscopy was done, and a biopsy was taken from a suspicious colonic lesion. The scalp pigmented lesion was also evaluated. Both biopsies were in favor of melanoma. Recently, management of metastatic melanoma of the brain is decided according to the number of lesions, accessibility, visceral metastasis, and resectability of the lesion. Various treatment options are surgical resection, whole brain radiotherapy (WBRT) and stereotactic radiosurgery (SRS). Malignant melanoma is relatively radioresistant, so the results are debatable. In conclusion, the prognosis of intracranial malignant melanoma is determined by the following factors: (1) the type of lesion; (2) the involvement of the leptomeninges; (3) the extent of tumor excised; and (4) the molecular immunology borstel number 1 (MIB 1) antibody index, which is the most relevant factor for prognosis in this type of cancer.

## Keywords

- melanoma
- surgical resection
- WBRT
- SRS

## Introduction

Central nervous system (CNS) melanoma is a rare type of neoplasm and accounts for 0.07 to 0.17% of all intracranial neoplasms.<sup>1</sup> CNS primary melanoma only accounts for approximately 1% of all cases of melanoma.<sup>2</sup> Primary CNS melanoma is generally diagnosed following the exclusion of a primary cutaneous or mucosal/retinal malignant melanoma, as differential

histological diagnosis between primary and metastatic origins is often difficult.<sup>3</sup> Malignant melanoma is the third most common cause of brain metastasis after lung and breast cancer,<sup>4</sup> and it accounts for 6 to 11% of all metastatic intra-axial tumors.<sup>5</sup> Among all the primary cancers, melanoma is considered to have highest tendency to metastasize to the brain, with 10 to 40% of patients with advanced melanoma estimated to develop intracranial metastasis. These metastases usually develop late in

article published online  
August 7, 2024

DOI <https://doi.org/10.1055/s-0044-1788633>.  
ISSN 2248-9614.

© 2024. Asian Congress of Neurological Surgeons. All rights reserved.

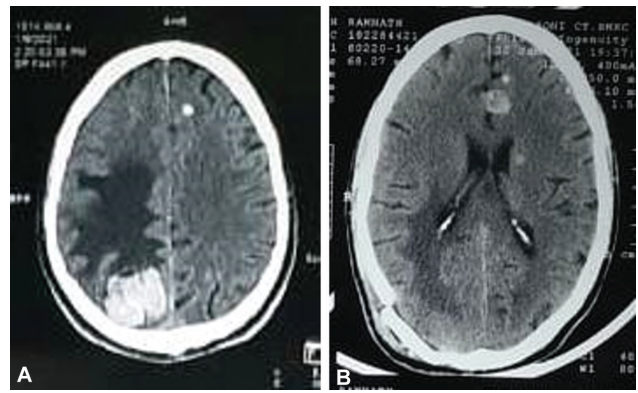
This is an open access article published by Thieme under the terms of the Creative Commons Attribution-NonDerivative-NonCommercial-License, permitting copying and reproduction so long as the original work is given appropriate credit. Contents may not be used for commercial purposes, or adapted, remixed, transformed or built upon. (<https://creativecommons.org/licenses/by-nc-nd/4.0/>)

Thieme Medical and Scientific Publishers Pvt. Ltd., A-12, 2nd Floor, Sector 2, Noida-201301 UP, India

the course of the disease. A higher incidence of brain metastasis is seen in head and neck melanoma when compared with other locations. It also has high incidence of extracerebral metastasis at the time of cerebral involvement. The time interval from the diagnosis of the primary lesion to cerebral metastasis varies from 6 to 60 months. Melanoma-related brain metastases have been associated with significant neurologic morbidity and a poor median overall survival. Surgically treated patients have an overall survival ranging from 5 to 22 months, those treated with radiotherapy has a survival rate ranging from 2 to 4 months, and in those treated with palliative therapy overall survival ranges from 2 weeks to 2 months.<sup>6</sup> Malignant melanomas are typically solitary lesions, but they can also present as multiple lesions. In all, 75% cases of malignant melanomas with intracranial metastasis mainly involve the frontal and parietal lobes. Various studies in the literature have found an association between the development of brain metastasis and various factors like male gender, head and neck primary lesions, deeply invasive primary lesions, primary lesions located on the mucosal surfaces, ulcerated primary lesions, lesions with large diameter and acral lentiginous and nodular histology, and presence of lymph nodes or visceral metastasis at the time of initial diagnosis. Malignant melanomas have a characteristic appearance on computed tomography (CT) and magnetic resonance imaging (MRI), and they are usually seen at the gray-white matter junction with a slight hyperdense mass lesion with moderate contrast enhancement with perilesional edema and leptomeningeal spread. On MRI, it shows T1 and T2 shortening due to the presence of melanin. Until recently, management of brain metastases has primarily focused on local, intracranial control of the disease. In cases of a single metastatic lesion or large, symptomatic lesions in oligometastatic disease, resection is typically advised. There are some contraindications for resection, such as inaccessible lesion, multiple visceral metastasis, leptomeningeal spread, and life-threatening comorbidities. For patients with more than a single brain metastasis with poor accessibility, radiation therapy, including stereotactic radiosurgery and whole brain radiation therapy (WBRT), has been the mainstay of treatment.<sup>7</sup> Factors that predict survival include age, performance status, and the number of brain metastases. In this study, the authors discuss a rare case where a patient presented with a brain metastasis as the first symptom of disease with pigmented lesion over the scalp. After evaluation, we found the primary lesion in the gastrointestinal tract.

## Case Report

A 61-year-old Caucasian man presented with unsteady gait, weakness in his left upper and lower limb, headache, and vomiting for 7 days. There were no other significant past medical or surgical history to contribute to the presenting complaints. The patient had history of small black pigmented lesion over the scalp at the parietal region for 2 years. All routine blood tests were within normal limits. Contrast-enhanced CT (CECT; ▶Fig. 1) of the brain revealed a large size oval-shaped hyperdense intra-axial mass in the right parieto-occipital lobe with moderate degree of perilesional edema and mass effect with multiple small lesions in the

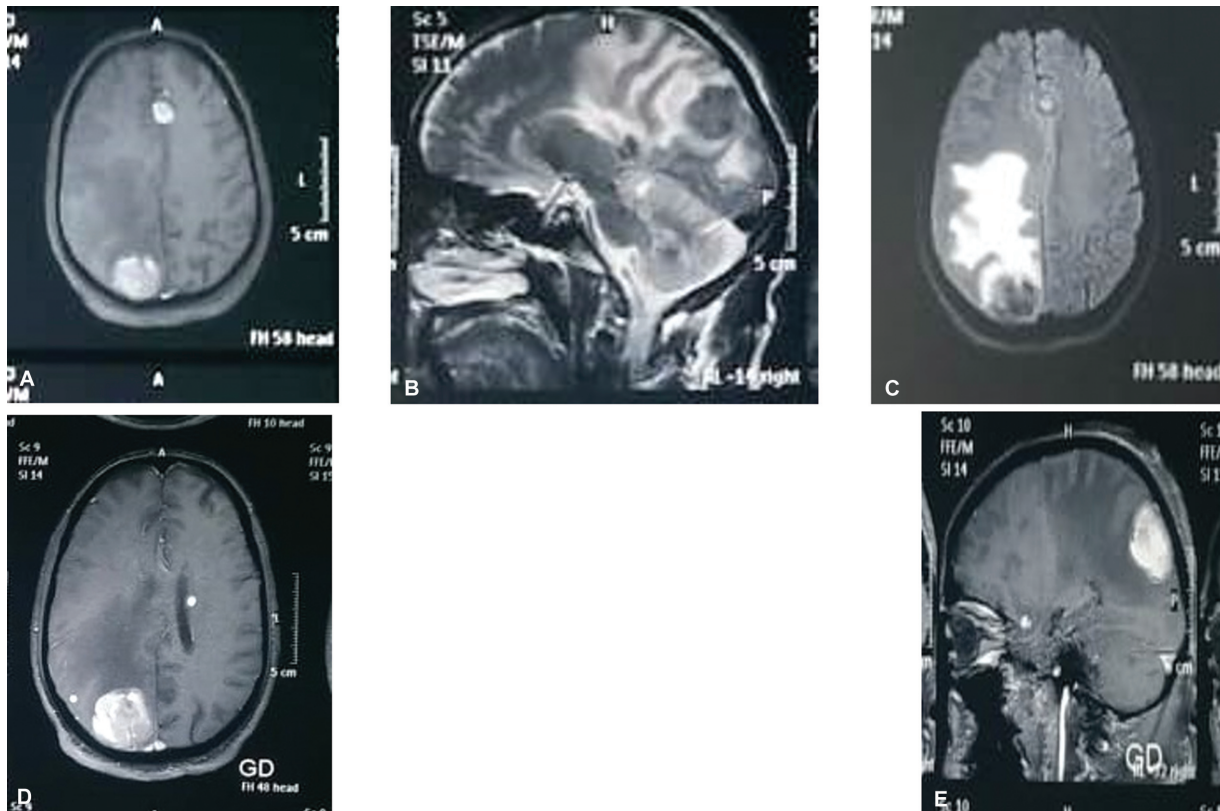


**Fig. 1** (A) Axial preoperative noncontrast computed tomography (CT) of the head shows a hyperdense mass lesion in the right parieto-occipital region with significant surrounding perilesional edema with a left frontal small hyperdense lesion. (B) Postoperative CT of the head shows complete resection of the right parieto-occipital lesion.

right temporal and bifrontal lobes. An MRI scan (▶Fig. 2) of the brain revealed a large solid single T1 and T2 hyperintense brightly enhancing intra-axial mass lesion in the right parieto-occipital lobe with multiple small lesions. Further staging workup included general examinations of the eyes, head, neck mucosa, skin, and computed tomography (CT) scans of the chest and the whole abdomen and pelvis did not show any significant primary lesion. Colonoscopy revealed a 1 cm × 1 cm pigmented polypoid lesion in the sigmoid colon, and biopsy was suggestive of malignant melanoma. There was a *brownish pigmented scalp lesion* at the *right frontoparietal region* just posterior to the coronal suture and punch biopsy was taken (▶Fig. 3), which was suggestive of a malignant melanoma. This *scalp lesion* was lying totally different from *intracranial lesion*, suggestive of a metastatic spread. Right parieto-occipital craniotomy was performed and gross total excision of the mass lesion was done. Intraoperative finding (▶Fig. 4) was a highly vascular dark black color mass at the right parieto-occipital region and the *dura* was *adherent at small area of mass*, but there was *no involvement of overlying bone*. Histopathological reports were suggestive of malignant melanoma with neuroparenchyma diffusely infiltrated by high-grade malignant neoplasm composed of nests of tumor cells, large pleomorphic vesicular nuclei, conspicuous macronuclei, and high nuclear-to-cytoplasmic ratio (N:C ratio). There is abundant melanin pigment both intracellularly and extracellularly. Perivascular arrangement of tumor cells and increased mitotic activity were noted. Later on, the right frontoparietal scalp lesion was treated by wide excision followed by skin grafting, and the patient was referred to the gastroenterologist for colonic polyp, which was managed by local excision and follow-up with colonoscopy. The patient was in our follow-up for 2 years. There was no other intracranial lesion, and the patient is doing well.

## Discussion

Neurological symptoms as the first sign of malignant melanoma are relatively uncommon, as is the inability to identify

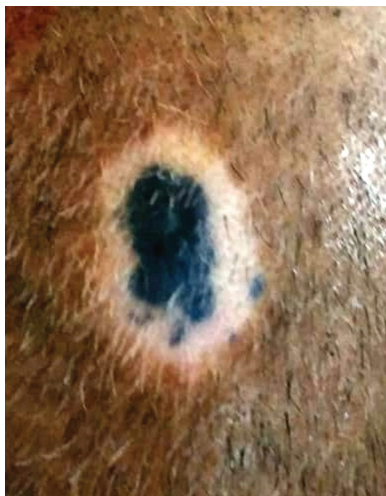

**Fig. 2** Magnetic resonance imaging (MRI) of the brain. (A) T1W axial, (B) T2W sagittal, (C) axial fluid attenuated inversion recovery (FLAIR), (D) axial contrast-enhanced MRI, and (E) sagittal view.

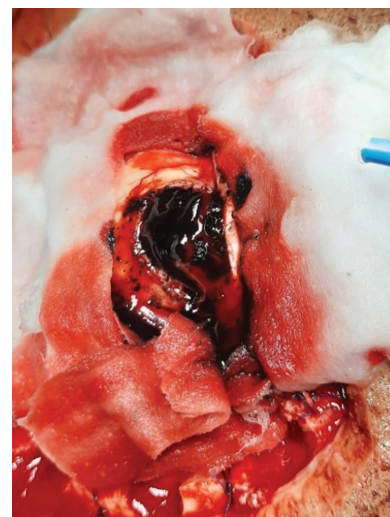
the primary tumor in patients with brain metastases from this disease. In this patient, further evaluation and workup for the primary lesion revealed a small polypoid lesion in the sigmoid colon, which was probably the primary lesion in this patient. Primary melanoma arising from the mucosal epithelium of the gastrointestinal tract is also a rare entity and the differentiation between metastatic and primary tumors is very difficult.<sup>8</sup> However, no other lesion that might represent the primary was detectable in this patient. Resection is mainly limited to patients with a solitary or single brain

metastasis and is often performed for symptomatic relief. Compared with radiation therapy alone, an overall survival benefit in all patients with single brain metastases who undergo resection has been demonstrated.<sup>9</sup> There may also be a role for resection in oligometastatic disease of dominant, symptomatic lesions.

Radiotherapy plays an important role in palliative treatment in malignant melanoma. Patients with a single brain metastasis managed with surgical resection plus WBRT have a 2-year survival rate of 20 to 25%.<sup>10</sup> Recently re-irradiation



**Fig. 3** Pigmented scalp lesion at the right frontal region near midline. A punch biopsy was taken.



**Fig. 4** Highly vascular dark black color mass.



in primary and metastatic brain tumors has increasingly been adopted as a valuable therapeutic option without unacceptable toxicity risk.<sup>11</sup> Gamma Knife radiosurgery for melanoma brain metastases was reported to result in 1-year local control in 49% and overall survival in 25% of the patients, with survival being dependent on the score index for radiosurgery (SIR).<sup>12</sup> Our patient belonged to the favorable SIR group (age  $\leq 50$  years, Karnofsky performance status [KPS]  $> 70\%$ , no evidence of systemic disease at the time of radiosurgery, and limited number of brain lesions). Patients with controlled systemic disease, single brain metastasis, and KPS of 90 to 100% have better survival.<sup>13,14</sup> Throughout the melanoma literature, long-term survival after complete resection of metastatic disease has been reported repeatedly.<sup>15,16</sup> Despite new drugs, there is low incidence of local responses after systemic treatment, as evidence by a recent report where only 10% showed such responses. However, local response is significantly associated with longer survival.<sup>17</sup> Based on these facts and illustrated through the case discussed here, effective local therapeutic measures including, for example, surgical resection and high-dose stereotactic radiotherapy should be considered in patients with favorable prognostic factors and absence of rapid and synchronous multi-organ spread.

Meningeal melanocytomas and primary CNS melanomas share a similar origin, and represent the benign and malignant ends of the spectrum, respectively.<sup>18</sup> Malignant transformation of melanocytoma to malignant melanoma has been previously reported.<sup>19–22</sup> Intracranial malignant melanoma often progresses, as it is not eradicated easily and tends to recur. Primary intracranial melanoma should be treated by thorough resection, followed by postsurgical radiotherapy and chemotherapy.<sup>23</sup> Currently, the most common and effective chemotherapeutic agent is dacarbazine, which presents an effectiveness rate of 16 to 20%, and is administered intravenously following surgery or radiotherapy. Previous studies have demonstrated that stereotactic radiosurgery (SRS) is able to treat one to three lesions, and is more effective at treating metastatic intracranial melanoma than the traditional WBRT, since a single exposure to a large dose of SRS may overcome resistance to radiation and limit the damage to peripheral brain tissue. Salpietro et al<sup>24</sup> reported that specific immunotherapy was an important adjuvant method in the treatment of small residual malignant melanoma lesions, and presented low toxicity. High doses of interferon- $\beta$  (IFN $\beta$ ) or IFN $\alpha$ -2b may improve disease control and prolong survival time, but the dosage required is disputed and difficult to tolerate. Various literature compared the genomics of brain metastases and primary tumors across multiple histology and demonstrated that greater than 50% of brain metastases have genetic alterations that were not detected in the clinically sampled primary tumor.

## Conclusion

Malignant melanoma is the third most common cause of brain metastasis. Brain metastasis in patients with melanoma has poor prognosis, and it is a significant cause of morbidity and mortality in this population. Surgical management of metastatic

melanoma of the brain depends on the number of lesions, accessibility, visceral metastasis, and resectability of lesion. Various treatment options are surgical resection, WBRT, and stereotactic radiosurgery. Malignant melanoma is relatively radioresistant, so results are debatable with multiple studies.

## Funding

None.

## Conflict of Interest

None declared.

## References

- Bhandari L, Alapatt J, Govindan A, Sreekumar T. Primary cerebellopontine angle melanoma: a case report and review. *Turk Neurosurg* 2012;22(04):469–474
- Greco Crasto S, Soffietti R, Bradac GB, Boldorini R. Primitive cerebral melanoma: case report and review of the literature. *Surg Neurol* 2001;55(03):163–168, discussion 168
- Ferraresi V, Ciccarese M, Zeuli M, Cognetti F. Central nervous system as exclusive site of disease in patients with melanoma: treatment and clinical outcome of two cases. *Melanoma Res* 2005; 15(05):467–469
- Barnholtz-Sloan JS, Sloan AE, Davis FG, Vigneau FD, Lai P, Sawaya RE. Incidence proportions of brain metastases in patients diagnosed (1973 to 2001) in the Metropolitan Detroit Cancer Surveillance System. *J Clin Oncol* 2004;22(14):2865–2872
- Nayak L, DeAngelis LM, Robins HI, et al. Multicenter phase 2 study of patupilone for recurrent or progressive brain metastases from non-small cell lung cancer. *Cancer* 2015;121(23):4165–4172
- Sperduto PW, Chao ST, Sneed PK, et al. Diagnosis-specific prognostic factors, indexes, and treatment outcomes for patients with newly diagnosed brain metastases: a multi-institutional analysis of 4,259 patients. *Int J Radiat Oncol Biol Phys* 2010;77(03): 655–661
- Chowdhury IH, Ojerholm E, McMillan MT, et al. Novel risk scores for survival and intracranial failure in patients treated with radiosurgery alone to melanoma brain metastases. *Radiat Oncol* 2015;10:248
- Schuchter LM, Green R, Fraker D. Primary and metastatic diseases in malignant melanoma of the gastrointestinal tract. *Curr Opin Oncol* 2000;12(02):181–185
- Goldinger SM, Panje C, Nathan P. Treatment of melanoma brain metastases. *Curr Opin Oncol* 2016;28(02):159–165
- Brastianos PK, Carter SL, Santagata S, et al. Genomic characterization of brain metastases reveals branched evolution and potential therapeutic targets. *Cancer Discov* 2015;5(11):1164–1177
- Combs SE, Gutwein S, Thilmann C, Debus J, Schulz-Ertner D. Reirradiation of recurrent WHO grade III astrocytomas using fractionated stereotactic radiotherapy (FSRT). *Strahlenther Onkol* 2005;181(12):768–773
- Selek U, Chang EL, Hassenbusch SJ III, et al. Stereotactic radiosurgical treatment in 103 patients for 153 cerebral melanoma metastases. *Int J Radiat Oncol Biol Phys* 2004;59(04):1097–1106
- Mathieu D, Kondziolka D, Cooper PB, et al. Gamma knife radiosurgery in the management of malignant melanoma brain metastases. *Neurosurgery* 2007;60(03):471–481, discussion 481–482
- Samlowski WE, Watson GA, Wang M, et al. Multimodality treatment of melanoma brain metastases incorporating stereotactic radiosurgery (SRS). *Cancer* 2007;109(09):1855–1862
- Wong SL, Coit DG. Role of surgery in patients with stage IV melanoma. *Curr Opin Oncol* 2004;16(02):155–160
- Young SE, Martinez SR, Essner R. The role of surgery in treatment of stage IV melanoma. *J Surg Oncol* 2006;94:344–351

- 17 Richtig E, Ludwig R, Kerl H, Smolle J. Organ- and treatment-specific local response rates to systemic and local treatment modalities in stage IV melanoma. *Br J Dermatol* 2005;153(05):925–931
- 18 Faillace WJ, Okawara SH, McDonald JV. Neurocutaneous melanosis with extensive intracerebral and spinal cord involvement. Report of two cases. *J Neurosurg* 1984;61(04):782–785
- 19 Rades D, Schild SE, Tatagiba M, Molina HA, Alberti W. Therapy of meningeal melanocytomas. *Cancer* 2004;100(11):2442–2447
- 20 Roser F, Nakamura M, Brandis A, Hans V, Vorkapic P, Samii M. Transition from meningeal melanocytoma to primary cerebral melanoma. Case report. *J Neurosurg* 2004;101(03):528–531
- 21 Uozumi Y, Kawano T, Kawaguchi T, et al. Malignant transformation of meningeal melanocytoma: a case report. *Brain Tumor Pathol* 2003;20(01):21–25
- 22 Wang F, Li X, Chen L, Pu X. Malignant transformation of spinal meningeal melanocytoma. Case report and review of the literature. *J Neurosurg Spine* 2007;6(05):451–454
- 23 Kurita H, Segawa H, Shin M, et al. Radiosurgery of meningeal melanocytoma. *J Neurooncol* 2000;46(01):57–61
- 24 Salpietro FM, Alafaci C, Gervasio O, et al. Primary cervical melanoma with brain metastases. Case report and review of the literature. *J Neurosurg* 1998;89(04):659–666