




“Old School” Islet Purification Based on the Unit Gravity Sedimentation as a Rescue Technique for Intraportal Islet Transplantation—A Case Report

Cell Transplantation
Volume 29: 1–10
© The Author(s) 2020
Article reuse guidelines:
sagepub.com/journals-permissions
DOI: 10.1177/0963689720947098
journals.sagepub.com/home/ccl


Justyna E. Gołębiewska^{1,*} , Karolina Gołąb^{2,*}, Tomasz Gorycki³,
Maciej Śledziński⁴, Jacek Gulczyński^{5,6}, Iwona Żygowska⁵,
Bogumił Wolnik⁷, Michał Hoffmann⁸, Piotr Witkowski² , Camillo Ricordi⁸,
Edyta Szurowska³, Zbigniew Śledziński⁴, and Alicja Dębska-Ślizień¹

Abstract

Here, we present a case that required a supplemental “old school” islet purification for a safe intraportal infusion. Following pancreas procurement from a brain-dead 26-year-old male donor (body mass index: 21.9), 24.6 ml of islet tissue was isolated after continuous density gradient centrifugation. The islet yield was 504,000 islet equivalent (IEQ), distributed among the following three fractions: 64,161 IEQ in 0.6 ml of pellet, 182,058 IEQ in 10 ml, and 258,010 IEQ in 14 ml with 95%, 20%, and 10% purity, respectively. After a 23-h culture, we applied supplemental islet purification, based on the separation of tissue subfractions during unit gravity sedimentation, a technique developed over 60 years ago (“old school”). This method enabled the reduction of the total pellet volume to 11.6 ml, while retaining 374,940 IEQ with a viability of over 90%. The final islet product was prepared in three infusion bags, containing 130,926 IEQ in 2.6 ml of pellet, 108,079 IEQ in 4 ml of pellet, and 135,935 IEQ in 5 ml of pellet with 65%, 40%, and 30% purity, respectively, and with the addition of unfractionated heparin (70 units/kg body weight). Upon the islet infusion from all three bags, portal pressure increased from 7 to 16 mmHg. Antithrombotic prophylaxis with heparin was continued for 48 h after the infusion, with target activated partial thromboplastin time 50–60 s, followed by fractionated heparin subcutaneous injections for 2 weeks. β -Cell graft function assessed on day 75 post-transplantation was good, according to Igl's criteria, with complete elimination of severe hypoglycemic episodes and 50% reduction in insulin requirements. Time spent within the target glucose range (70–180 mg/dl) improved from 42% to 98% and HbA1c declined from 8.7% to 6.7%. Supplemental “old school” islet purification allowed for the safe and successful utilization of a robust and high-quality islet preparation, which otherwise would have been discarded.

Keywords

islet transplantation, diabetes

¹ Department of Nephrology, Transplantology and Internal Medicine, Medical University of Gdańsk, Gdańsk, Poland

² Transplantation Institute, University of Chicago, Chicago, IL, USA

³ Department of Radiology, Medical University of Gdańsk, Gdańsk, Poland

⁴ Department of General, Endocrine and Transplant Surgery, Medical University of Gdańsk, Gdańsk, Poland

⁵ Laboratory for Cell and Tissue Banking and Transplantation- CellIT, Gdańsk, Poland

⁶ Department of Pathology and Neuropathology, Medical University of Gdańsk, Gdańsk, Poland

⁷ Department of Hypertension and Diabetology, Medical University of Gdańsk, Gdańsk, Poland

⁸ Diabetes Research Institute and Cell Transplantation Center, University of Miami, Miami, FL, USA

* Both the authors contributed equally to this article

Submitted: March 8, 2020. Revised: June 15, 2020. Accepted: July 14, 2020.

Corresponding Author:

Alicja Dębska-Ślizień, Department of Nephrology, Transplantology and Internal Medicine, Medical University of Gdansk, Gdansk, Poland.

Email: adeb@gumed.edu.pl



Creative Commons Non Commercial CC BY-NC: This article is distributed under the terms of the Creative Commons Attribution-NonCommercial 4.0 License (<https://creativecommons.org/licenses/by-nc/4.0/>) which permits non-commercial use, reproduction and distribution of the work without further permission provided the original work is attributed as specified on the SAGE and Open Access pages (<https://us.sagepub.com/en-us/nam/open-access-at-sage>).

Introduction

Pancreatic islet transplantation (ITx) is a vital therapeutic option for patients with the brittle form of type 1 diabetes mellitus (T1DM), suffering from frequent severe hypoglycemic episodes despite intensive insulin treatment¹.

By enabling endogenous insulin production, ITx improves blood glucose control and restores hypoglycemic awareness. Pancreatic islets are isolated from a deceased donor pancreas by enzymatic digestion, purified, and infused directly into the portal vein as a minimally invasive procedure. Since the islet purification technique is still imperfect, the final islet product always contains some acinar tissue. High tissue volume infused intraportally may occlude portal small vasculature and reduce blood flow, triggering portal vein thrombosis. Maximal tissue volume is limited usually to 15 ml to prevent this complication².

Islet purification by the centrifugation in continuous gradient is currently considered as the most efficient method to separate islets from acinar tissue and is used by almost all islet transplant centers. Nevertheless, islet purification remains challenging especially for tissue from relatively young donors³. In such cases, enzymatic digestion usually does not efficiently dissociate islets from acinar tissue. High-quality islets remain embedded and mantled with attached acinar tissue, which precludes effective purification by centrifugation in continuous gradient. As a result, high-quality islets cannot be transplanted due to excessive tissue volume and are discarded.

Here, we present a clinical case involving the implementation of an “old school” rescue supplemental islet purification technique, which resulted in a substantial reduction of the excessive islet pellet volume and allowed for safe and successful ITx.

Recipient

A 41-year-old Caucasian male with history of T1DM since the age of 9 was referred for ITx due to a 3-year history of frequent severe hypoglycemic episodes despite intensive insulin treatment. He had a history of severe retinopathy with blindness and end-stage renal disease (ESRD) caused by diabetic nephropathy. At the age of 32 he received simultaneous pancreas kidney (SPK) transplantation to treat ESRD and T1DM followed by pancreas graft failure 3 years post-transplantation. At the time of referral for ITx, the patient presented with excellent and stable kidney allograft function with serum creatinine of 0.9 mg/dl. His diabetes was maintained with multiple daily injections of short-acting insulin aspart and a single injection of insulin glargine (total daily insulin dose of 40 units). Despite targeting higher than optimal blood glucose levels (HbA1c of 72 mmol/mol, 8.7%), the patient experienced frequent severe hypoglycemic episodes and hypoglycemic unawareness with a Gold score of 5. Continuous glucose monitoring (CGM) (iPROTM2, Medtronic, Inc., Northridge, CA, USA) showed mean standard

deviation (SD) sensor glucose of 76 mg/dl with 2.0% of the time spent in hypoglycemia (<70 mg/dl), 56% of the time spent in hyperglycemia (>180 mg/dl), and only 42% of the time spent within the target glucose range (Fig. 1A). His body mass index (BMI) was 20.8 kg/m² with a height of 165 cm and a weight of 56.5 kg. Extensive lipoatrophy and lipohypertrophy were found at the insulin injection sites. His c-peptide was undetectable at fasting and after mixed meal stimulation. His past medical history also included hepatitis C with no replication of the virus, normal synthetic liver function, and no laboratory signs of liver injury. The patient was found to be seronegative for class I and II human leukocyte antigen (HLA) antibody in enzyme-linked immunosorbent assay test.

Donor

The pancreas was retrieved from a 26-year-old brain-dead male donor with a BMI of 21.9 kg/m² (height 180 cm and weight 71 kg) and body surface area of 1.88 m². The donor was supported with norepinephrine after his death due to the head trauma. His labs were within normal limits. His scoring as a donor was 64 based on the North American Islet Donor Score (NAIDS) and 75 in the Islet Donor Score (IDS) system^{4,5}. HLA mismatching was 1:2:2 (A, B, and DR), respectively. There were no repeated mismatches with the SPK donor. A pre-transplant complement-dependent crossmatch using donor T and B lymphocytes and the basic microlymphocytotoxicity test were negative. The pancreas was preserved with the Store Protect Plus solution (CarnaMedica LLC, Warsaw, Poland) and 4 h of cold storage.

Islet Isolation and Preparation for Transplantation

Islet Isolation. Human islet isolation was conducted in the cGMP facility at the Laboratory for Cell and Tissue Therapy and Transplantation (CellT) in Gdańsk, following a standard Ricordi automated islet processing procedure that was described previously². Briefly, 12-min automatic perfusion was performed with Liberase MTF C/T (Roche Diagnostics GmbH, Mannheim, Germany): 25 Wuensch units of collagenase and 700 units of neutral protease (thermolysin) per 1 g of pancreas, with the enzyme solution injection through the main pancreatic duct. Next, pancreas was digested for 12 min, followed by tissue collection into RPMI 1640 (Mediatech, Manassas, VA, USA) supplemented with 4% human serum albumin (Baxter, Vienna, Austria), 0.4 U/ml insulin (Bioton SA, Warsaw, Poland), and 20 U/ml heparin (Polfa Warszawa S.A., Warsaw, Poland). After washing, 50 ml of collected pancreatic tissue was divided into two equal portions and each was suspended in Cold Storage Solution (Mediatech) with 20% PentaStarch (Mediatech) and 10 U/ml heparin (Polfa Warszawa S.A.) to a final volume of 100 ml for a standard continuous gradient iodixanol-based (OptiPrepTM, Sigma-Aldrich, Oslo, Norway) purification^{2,6}.

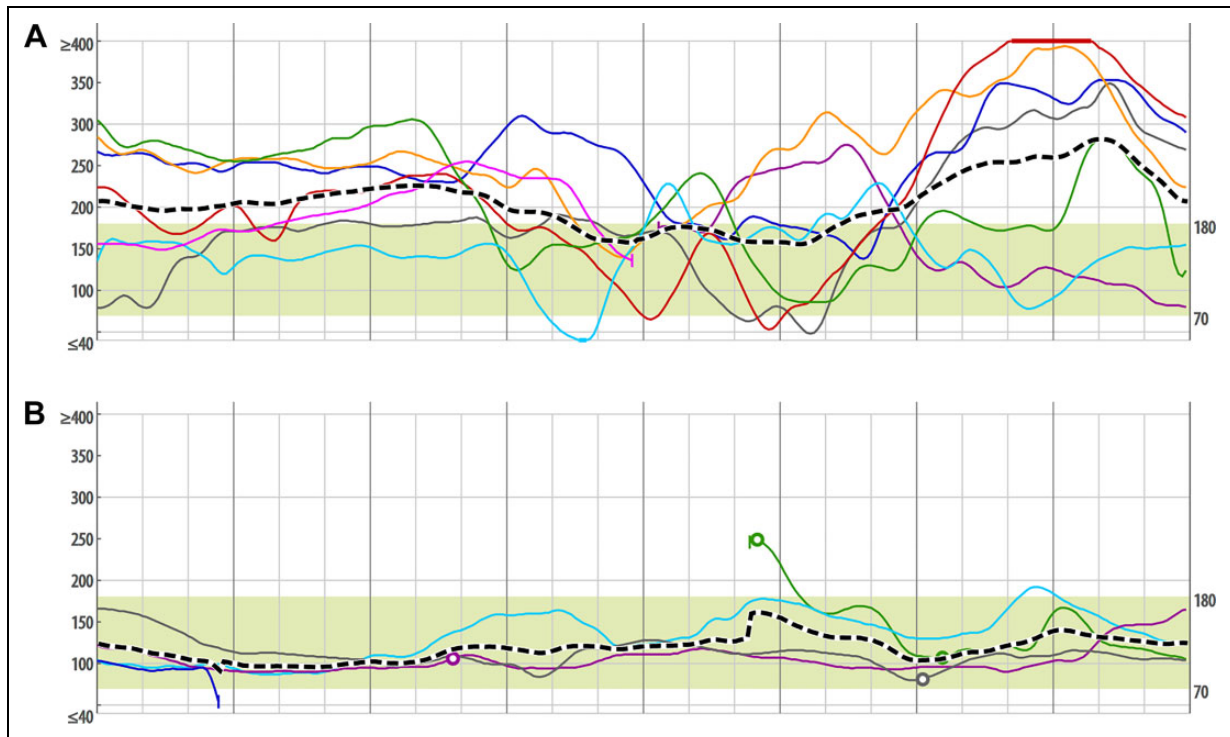


Figure 1. (A) Baseline continuous glucose monitoring. (B) Day 75 continuous glucose monitoring.

Fractions collected after purification were checked for purity after staining with dithizone (Sigma-Aldrich, St Louis, MO, USA) solution (0.16% w/v). Pellets with greater than 70% islet purity were pooled together as high-purity fraction. Pellets with less than 30% islet purity were collected separately and divided into two subfractions of 20% and 10% purity. Samples were taken from each purity grade and assessed for an islet equivalent (IEQ) count². In total, 24.6 ml of tissue was collected after continuous density gradient purification, and the islet yield was 504,229 IEQ, distributed among the following fractions: 64,161 IEQ in 0.6 ml of pellet volume (95% purity), 182,058 IEQ in 10 ml (20% purity), and 258,010 IEQ in 14 ml (10% purity).

Islet Culture. Islets were cultured in 24 T-175 flasks (Thermo Fisher Scientific, Roskilde, Denmark) in 30 ml of CIT Culture Medium: CMRL 1066 (Mediatech) supplemented with 0.4% human serum albumin (Baxter) and 10 U/ml heparin (Polfa Warszawa S.A.) per flask in the incubator (Binder, Tuttlingen, Germany, Model CB160) at 22°C and 5% carbon dioxide. High-purity islets were divided and placed into two flasks (30,000 IEQ/flask), 20% purity islets into 10 flasks (18,000 IEQ/flask), and 10% purity islets into 14 flasks (18,000 IEQ/flask). All islets were cultured for 22 h and 50 min before being collected for supplemental purification. Medium in each flask was exchanged after the first 12 h of culture.

Unit Gravity Sedimentation-based “Old School” Supplemental Islet Purification. The volume of the collected pellet after the

culture remained the same as after the isolation. Islet tissue from the fraction with 20% purity post-isolation was collected into 250 ml conical tubes (Corning, Amsterdam, the Netherlands) and then combined into a single tube. The tissue was allowed to settle for 10 min, after which the supernatant was removed from above the pellet to wash the islets from the culture medium. Then, the pellet was resuspended in 20 ml of CIT Transplant Wash Medium: CMRL 1066 (Mediatech) with 2% of human serum albumin (Baxter), 1 M of 4-(2-hydroxyethyl)-1-piperazineethanesulfonic acid (HEPES; Mediatech), and 10 U/ml of heparin (Polfa Warszawa S.A.) and again allowed to settle for 5 min. Clear supernatant from the above of the sedimenting tissue was collected and discarded, and the tissue pellet was immediately segregated using a 10 ml pipet as follows: the first 7 ml was collected from the surface of the pellet and transferred to separate 250 ml conical tubes (Corning), the next 7 ml from the middle portion and transferred to separate 250 ml conical tubes (Corning), and the bottom portion was left in the same conical tube. The schema of islet purification by sedimentation at gravity unit is shown in Fig. 2.

The settled tissue volume for each collected fraction was estimated and then the tissue was resuspended in 100 ml of CIT Transplant Wash Medium. Next, 100 µl of islet sample was taken from each fraction, stained with dithizone, and used to calculate the IEQ. The pellet volumes and IEQ for each fraction during the supplemental purification are presented in Fig. 3. The same procedure was performed for the islet tissue from the fraction with 10% purity post-isolation.

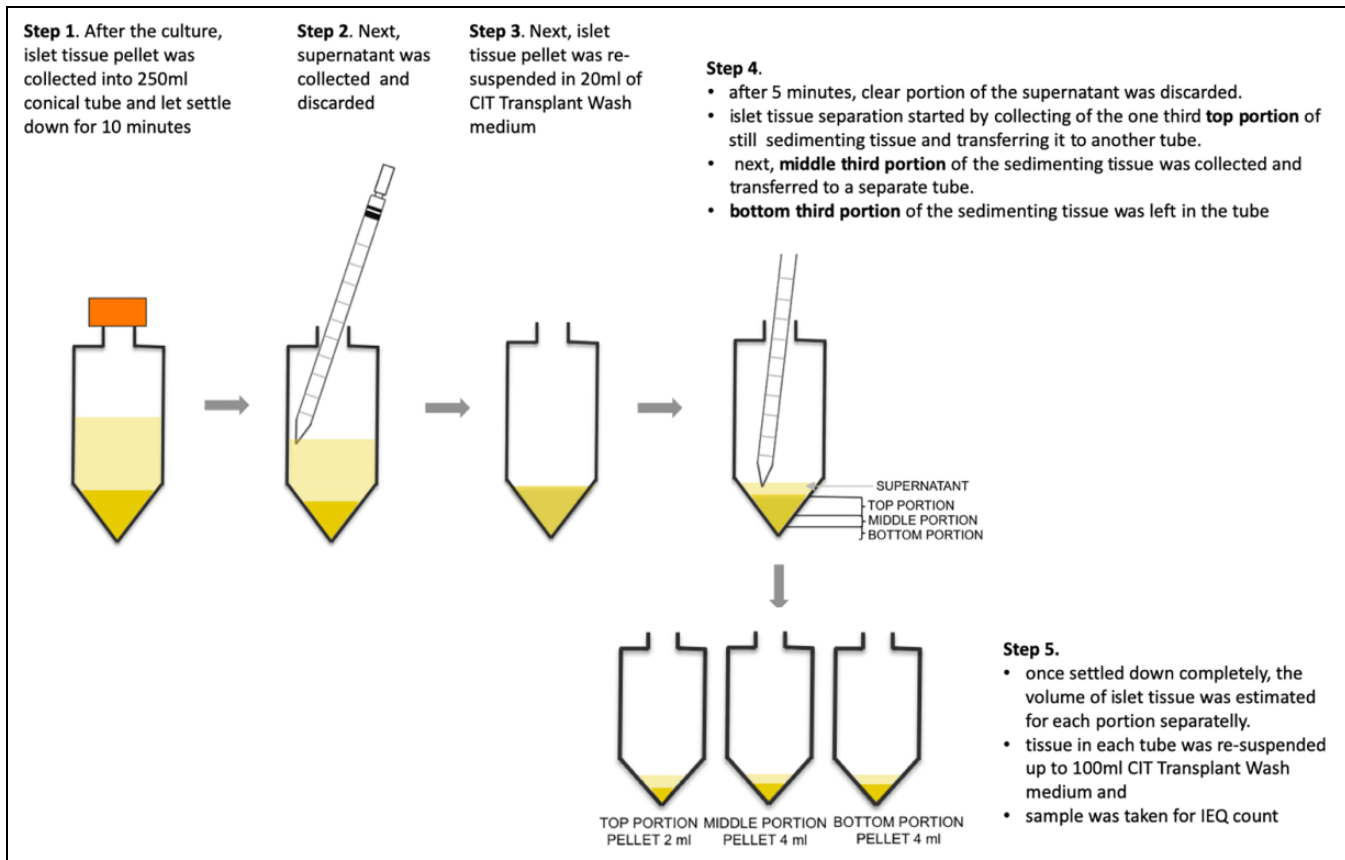


Figure 2. The “old school” purification schema.

After islet tissue collection from the culture, the separation process was performed once per each fraction.

The heparin was added to the all islet isolation, islet culture, and islet transplant preparation solutions to reduce the effect of instant blood-mediated inflammatory reaction (IBMIR) based on the CIT SOPs^{6–13}.

Preparation of the Final Islet Product and Release Criteria Testing.

Islets from the post-isolation high-purity fraction (0.6 ml) were collected from T-175 flasks (Thermo Fisher Scientific) into a 250 ml conical tube (Corning) and washed three times with CIT Transplant Wash Medium (Fig. 3). Individual fractions with the highest IEQ per milliliter pellet volume were selected from the post-isolation fractions with purity >30% for the final product transplantation (2 ml from the upper and 4 ml from the middle-purity fraction) (Fig. 3). The final islet product was suspended in CIT Transplant Medium: CMRL 1066 (Mediatech) supplemented with 2% human serum albumin (Baxter) and 1 M HEPES (Mediatech) and prepared in three infusion bags (Transfer Pack Container, Fenwal, Lake Zurich, IL, USA) as follows: post-isolation high-purity islets (0.6 ml) and the upper fraction of tissue retrieved from the post-isolation 20% islet purity were combined and prepared in the first bag (beige rectangles in Fig. 3). The middle fraction of the tissue from the post-isolation 20% islet purity fraction was prepared in the second

bag (blue rectangle in Fig. 3) and the bottom portion of the tissue from the post-isolation 10% islet purity fraction was prepared in the third bag (green rectangle in Fig. 3). Next, the final islet product from each bag was tested in the release criteria assays (Tables 1 and 2). No microbial contamination was found on Gram stain or 14-day anaerobic, aerobic, and fungal culture and the endotoxin test was negative (EndoSafe[®] PTS[™] Endotoxin System, Charles River, Charleston, SC, USA). Islet viability, assessed with fluorescein diacetate (Sigma-Aldrich) and propidium iodide (Sigma-Aldrich), met release criterium. Islet function based on the *in vitro* glucose-stimulated insulin response (GSIR) was performed retrospectively (after the transplant). Briefly, during GSIR, islets were incubated in high (28 mM) and then in low (2.8 mM) glucose concentrations in Krebs-Ringer buffer solution for 1 h at 37°C in each. The high and low glucose solutions were then collected and send for the analysis of the insulin concentration to the Central Clinical Laboratory of the University Clinical Centre in Gdańsk.

Before islet infusion, 4,000 IU of heparin (Polfa Warszawa S.A)—70 IU per kg of recipient’s body weight was added to the final islet product, divided equally into three bags. The first infusion bag contained 130,926 IEQ in 2.6 ml of tissue (65% purity), the second bag contained 108,079 IEQ in 4 ml of tissue (40% purity), and the third bag contained 135,935 IEQ in 5 ml of tissue (30% purity).

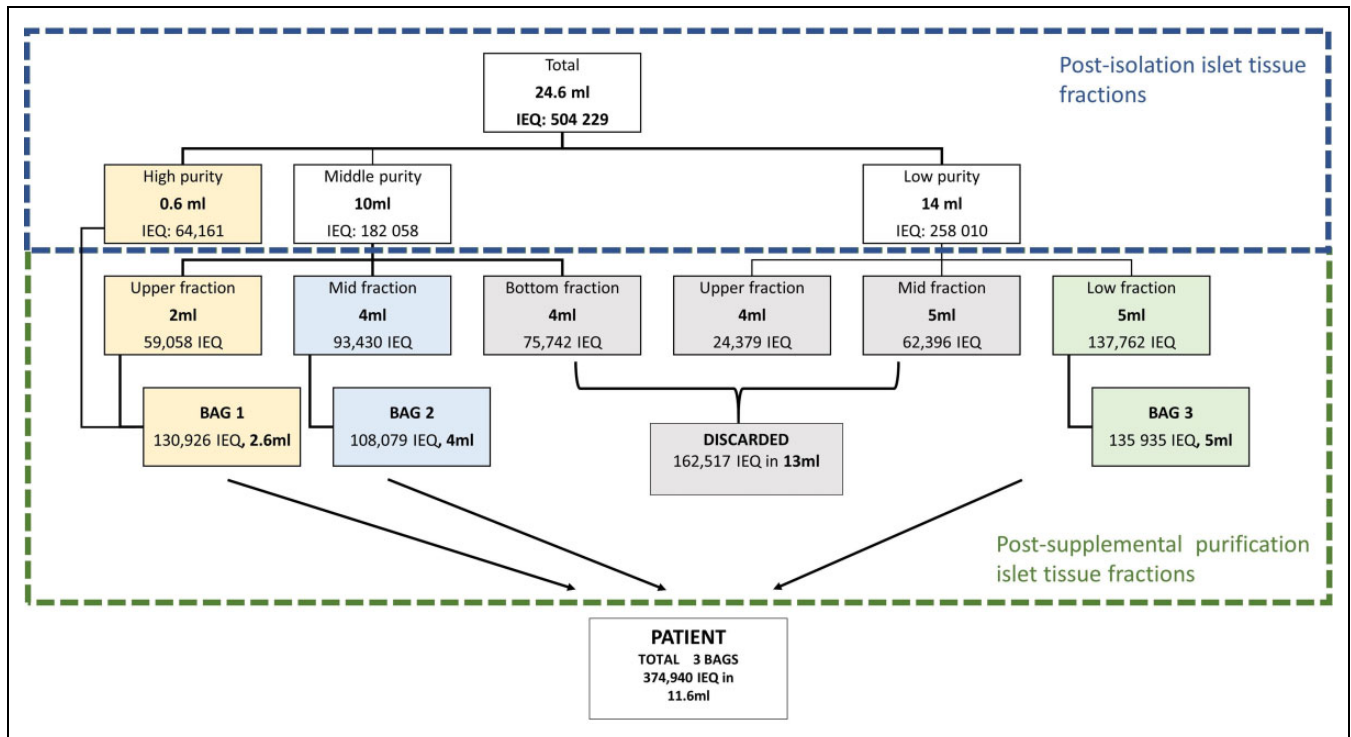


Figure 3. The pellet volumes and IEQ for each fraction during the initial and supplemental purification. IEQ: islet equivalent.

Table 1. Isolation Results.

	Pre-purification	Post-purification	Post-culture	Post “old school”
IPN	299,000	288,000	Not done	179,000
IEQ	458,819	504,229	Not done	
Settled tissue volume	50 ml	24.6 ml	~24 ml	11.6 ml
GSIR	Not done	Not done	Not done	1.27

GSIR: glucose-stimulated insulin release; IEQ: islet equivalents; IPN: islet particle number.

Table 2. Release Criteria.

	Release criteria					
	IEQ	IEQ/kg	Pellet volume (ml)	Viability (%)	Endotoxin (EU/kg)	Gram stain/culture
Reference value	N/A	Total ≥ 5,000	Total < 12	Total >70	<5	Negative
Bag 1	130,926	—	2.6	94	0.697	Negative
Bag 2	108,079	—	4	91	0.760	Negative
Bag 3	135,935	—	5	94	0.697	Negative
Total	374,940	6,637	11.6	>91	2.15	Negative

IEQ: islet equivalents.

Transplantation

In addition to standard maintenance immunosuppression related to the kidney transplant, the patient received 6 mg/kg thymoglobulin divided into six daily doses, one prior to the procedure and the rest over the first 10 days post-transplantation. Etanercept was injected subcutaneously:

50 mg on day 0 and 25 mg on days 3, 7, and 10. Tacrolimus was increased with a target trough level of 10–14 mcg/l and the dose of mycophenolate sodium was increased to 720 mg, given twice daily. Islets were infused into the portal vein through percutaneous transhepatic access placed by an interventional radiologist. The opening portal pressure was

7 mmHg and increased to 11 and 20 mmHg after the infusion of islets from the first and second bags, respectively. Next, after the portal vein was flushed with 50 ml of plain transplant medium, the portal pressure gradually dropped to 10 mmHg within 20 min. Upon infusion of islets from the third bag, the portal pressure stabilized at 16 mmHg. Subsequent thromboembolic prophylaxis consisted of continuous unfractionated heparin infused intravenously over 48 h at the rate of 400 UI per hour adjusted for the target activated partial thromboplastin time of 50–60 s, followed by subcutaneous fractionated heparin injections daily for 2 weeks.

Outcomes

No signs of portal vein thrombosis were found on Doppler ultrasound on postoperative days 1 and 3. Serum transaminases peaked at 82–88 U/l on day 3 and returned to normal by postoperative day 7. There was also a transient drop in hemoglobin level from 14.1 to 12.2 g/dl, which normalized by day 75. Kidney allograft function remained stable with serum creatinine of 0.96 mg/dl. HLA antibodies remained negative on days 7 and 75 post-ITx.

After initial improvement in glucose control, there was a transient deterioration accompanied by a raise in the anti-GAD65 antibody titers from 21.8 to 1346.9 IU/ml (normal range: <10 IU/ml) on post-ITx day 14. In order to enhance immunosuppression to facilitate islet engraftment, patient received three plasma exchanges followed by the infusion of 135 g of intravenous immunoglobulin (IVIg) (2.4 g/kg bw).

The metabolic outcome of β -cell graft function, assessed according to the Igls criteria¹⁴ on day 75 post-ITx, was good with the complete elimination of severe hypoglycemic episodes, HbA1c improvement from 8.7% to 6.7%, and a 50% reduction in insulin requirements. Mixed meal (BOOST® High-protein, 6 ml/kg, Nestlé Health Science, Bridgewater, NJ, USA; 360 calories, 9 g fat, 49.5 g carbohydrate, 22.5 g protein) stimulated c-peptide response was assessed on day 7 and day 75 (3.6- and 7-fold increase from fasting value: from 0.52 to 1.65 ng/ml and 0.31 to 2.05 ng/ml, respectively).

Continuous glucose monitoring (iPRO™2, Medtronic, Inc.) showed improved glycemic control on day 75 after the transplant. The mean SD sensor glucose was improved to 28 from 76 mg/dl prior to the islet infusion, the percentage of time spent within the target glucose range (70–180 mg/dl) improved from 42% to 98% post-transplantation, and the patient spent less time in hyperglycemia (glucose >180 mg/dl): 2% vs 56% prior to the transplantation. There was no time spent in hypoglycemia comparing to 2% before islet graft (Fig. 1B). The improvement in glucose control was accompanied by significant improvement in the patient's quality of life. The patient reported no fear of a sudden death and became much more socially active.

On day 80 post-ITx, the patient had transient infectious diarrhea. Otherwise, the post-ITx course was uneventful without significant adverse events. Eight months later

patient received supplemental islet infusion, supporting islet graft function with the final goal of complete insulin independence. Opening portal pressure measured directly, while accessing a portal vein was 7 mmHg, exactly the same as prior to the first transplant.

Discussion

Islet isolation and purification from young donors remains a major challenge leading to underutilization of otherwise high-quality donors of viable islet allografts. Different strategies have been proposed to facilitate islet recovery in such cases. Based on the hypothesis that in young donors, pancreatic ductal system collapse after the cold storage, additional injection of collagenase into the pancreatic duct at the procurement site, rather than only after the cold preservation was recommended to improve enzyme distribution and organ digestion, but was later abandoned¹⁵. Additionally, a modified digestion system was proposed to enhance enzymatic action over mechanical digestion by slow shaking of the Ricordi chamber³. Next, investigators tried optimizing the concentration of collagenase¹⁶ or more recently blending different enzymes (e.g., increasing the dose of protease relative to that of collagenase¹⁷). As the intraportal infusion of digested, but unpurified pancreatic tissue led to frequent portal vein thrombosis, the need for the elimination of excessive acinar tissue from the islet preparation became obvious. Segregating different purity fractions of islets with a pipette during their sedimentation was the natural first step in the attempt to limit tissue volume for intraportal islet infusion. Therefore, we called it “old school” purification¹⁸. Many purification methods have been subsequently tested including hand-picking¹⁹, phototerminolysis²⁰, radiation²¹, osmolality-dependent isolation²², cryo-isolation,²³ and cell sorting²⁴. However, most of these methods have only been used in research settings. Since the 1960s, density gradient centrifugation has been found to be the most effective and has become the gold standard islet purification method²⁵. This procedure utilizes differences in physical density between islets and acinar tissue to permit islet purification. With time, more efficient continuous variations replaced discontinuous gradient purification. However, the latter might still be utilized for a rescue supplemental purification²⁶.

Nevertheless, outcomes of gradient purification still remain very inconsistent, mostly due to the variability of islet and acinar tissue density related to the deceased donor characteristics as well as organ quality. Several conditions, such as warm and cold ischemia time, preincubation time before purification, and osmolality of both preincubation solution and purification solution, have been shown to affect the relative density gradient of islets and acinar tissue²⁷. As a result, final tissue volume, even after the purification, might still be too high for safe intraportal infusion as we showed in our case. In such a situation, the islet preparation may need to be discarded, despite sufficient islet mass and appropriate

islet quality. Several modifications have been tested to address the problem.

Since poor recovery after the standard continuous gradient purification was attributed to higher than average density of imbedded islets tissue, therefore use of higher density and osmolality of the discontinuous gradient was reported successful for rescue purification²⁸. The disadvantage of this method is additional exposure of islets to potentially toxic gradient environment and shearing forces compromising quality and quantity of the islets. Since we had excess of islets already collected, we chose to apply less “stressful” for islets “old school” purification method, prioritizing preservation of islet quality. Another possible option was to apply a higher density than standard ($>1.095 \text{ g/cm}^3$) gradient during the primary purification with continuous gradient; however, we have not had any experience with that technique so we did not use it²⁹.

With current technology, even in the most experienced centers, only up to 40%–50% of islet clinical products actually meet clinical release criteria. This is related most commonly to insufficient postpurification islet yield, but might also be due to excessive pellet volume or insufficient purity²⁸.

A high pellet volume, especially exceeding 15 ml, was found to substantially increase the risk of thrombosis or persistent portal hypertension after intraportal infusion. A number of other less common serious adverse events related to the intraportal transplantation of unpurified pancreatic preparations have also been reported, including wedge splenic infarction, splenic capsular tear, bleeding esophageal varices, disseminated intravascular coagulation, systemic hypertension, persistent portal hypertension, liver failure, and even death^{30,31}.

In our report, we demonstrate successful supplemental sedimentation-based “old school” purification in the event of high islet yield and islet product of low purity and high tissue volume. The procedure allowed for a reduction of the total pellet volume from 24.6 to 11.6 ml, containing less, but sufficient islet mass with 374,940 IEQ and viability of over 90%. In our case, discarding lower islet purity fractions to reduce the pellet volume would have led to insufficient islet mass that could not have been applied for transplantation. Considering disadvantage of rescue discontinuous gradient purification described before and low chance for success as over 85% of islets were still trapped in acinar tissue, we decided to culture islets from all three obtained fractions and later perform the “old school” sedimentation-based method of islet purification to reduce tissue pellet volume. While “old school” purification has the advantage of being much less detrimental to islets than other methods, it needs to be highlighted that will lead to the substantial loss of islet mass (26% in our case) so can be applied only in the excess of the islet mass. We have not found any description of clinical use of “old school” purification in the literature over last 30 years, besides one personal communication about utility for pellet volume reduction in setting of islet autotransplantation

by Dr. Hongjun Wang from the Medical University of South Carolina. Altogether, we propose utilizing “old school” purification only as an alternative rescue method for a pellet volume reduction, and only in highly selected cases of islet allotransplantation with robust islet yield and quality, but excessive final product volume. Moreover, the procedure requires minimal islet manipulation so can be repeated, if necessary for further pellet volume reduction.

Our final islet preparation after supplemental purification had a relatively low overall purity of 30%–60%. There is a debate whether very pure, “naked” islets have survival and functional advantages over less pure, embedded islets surrounded by more acinar tissue. Highly pure preparations were shown to facilitate engraftment with reduced graft immunogenicity³¹. The high content of acinar cells in impure preparations is a source of a variety of proteolytic enzymes, such as trypsin, chymotrypsin, and elastase, which could affect islet integrity, viability, and functionality³². For that reason, islet loss after the culture was reported to be significantly higher in impure preparations. In animal studies, a higher number of duct cells infused along with islets, even with comparable numbers of β -cells, resulted in the failure to achieve normoglycemia³³. Duct cells also synthesize both the classical membrane-bound and the soluble form of tissue factor and therefore exert a potent factor VII-dependent procoagulant activity³⁴. The infusion of impure preparations may result in more extensive thrombotic and inflammatory events causing damage of neighboring β -cells. The mantle of exocrine tissue may also impair the diffusion of oxygen and nutrients both in culture and after the transplantation, exacerbating central necrosis within large clumps of cells and thus affecting cell survival and islet engraftment^{35,36}. Recently it was also shown that duct cells secrete IL-1 β ², which could lead to increase inflammation and further damage of islets³⁷.

Nevertheless, the transplantation of impure islets in the setting of autotransplantation and has been well tolerated by the recipients. Non-islet tissue, potentially containing progenitor cells, was shown to increase islet viability and functionality, and improve clinical outcomes. The *in vitro* co-culture of islets with ductal epithelial cells prevented reductions in the structural integrity and functional viability of islets, isolated according to the standard protocols^{38,39}. In *in vitro* experiments both effects described above of increased tissue factor and IL-1 β secretion by duct cells that lead to IBMIR cannot be observed.

A recently published study by Benomar et al. showed favorable metabolic outcomes, including lower HbA1c values, reduced daily insulin requirements, and a higher rate of insulin independence 5 years after ITx in patients who received islet preparations with a mean purity of less than 50%, as opposed to those who received islets with a mean purity of greater than 50%. The authors suggested that non-islet cells in low purity preparations may exert their beneficial effect through promoting ductal-to-endocrine cell differentiation⁴⁰.

Favorable clinical outcome with improvement in glycemic control reflected by CGM readings and improvement in hypoglycemia awareness supports the utilization of the “old school” purification method. Of note, 10 months after the procedure portal pressure remained the same as prior to the first transplant, indicating that infusion of 11.6 ml of islet tissue did not affect portal pressure in the long term.

On the other hand, the infusion of embedded islets might have led to exacerbated necrosis and additional β -cell loss due to impaired diffusion of oxygen and nutrients, as mentioned earlier. Since GAD65 was shown to be a marker of early β -cell loss³³, it is possible that an over 60-fold raise in anti-GAD65 antibody titers in this case was just a response to the release of GAD65 antigen from necrotic β -cells, which possible would have subsidized on its own as it was previously reported^{41,42}. In such case, it may have not really reflected ongoing auto- or alloimmune destruction of the transplanted islets, and the application of plasma exchange and IVIG might have not been necessary.

Altogether “old school” sedimentation-based purification can be successfully applied in cases of high-yield islet isolations, enabling the reduction of tissue volume and utilization of high-quality islet grafts that would otherwise be wasted. In our case, relatively low overall purity of the islet product did not compromise clinical outcome and our patient benefitted from the procedure. Supplemental purification may be a useful tool to increase the utilization of pancreata and islet grafts from young donors for ITx.

We would like to highlight that utilization of described method of purification was possible only thanks to the international collaboration with islet centers in Chicago and Miami, which shared their extensive knowledge and experience with the new islet isolation facility in Poland, leading to the first clinical ITx in Gdańsk⁴³.

Acknowledgments

We would like to thank the European Society for Organ Transplantation, which supported the training for Justyna Gołębiewska with ESOT Study Scholarship 2017. We would also like to thank Natalia Niedziałek and Maria Bugajska-Liedtke, who provided data from islet processing in the CellT Laboratory.

Ethical Approval

Ethical approval to report this case was obtained from Bioethics Committee of the Medical University of Gdańsk Approval No. NKBBN/58/2020.

Statement of Human Rights

All procedures in this study were conducted in accordance with Bioethics Committee of the Medical University of Gdańsk Approval No. NKBBN/58/2020.

Statement of Informed Consent

Written informed consent was obtained from the patient for his anonymized information to be published in this article.



Declaration of Conflicting Interests

The author(s) declared no potential conflicts of interest with respect to the research, authorship, and/or publication of this article.

Funding

The author(s) disclosed receipt of the following financial support for the research, authorship, and/or publication of this article: Justyna Gołębiewska received the ESOT Study Scholarship from the European Society for Organ Transplantation. The funder had no role in study design, data collection and analysis, decision to publish, or preparation of the manuscript.

ORCID iDs

Justyna E. Gołębiewska  <https://orcid.org/0000-0001-5346-8369>
Piotr Witkowski  <https://orcid.org/0000-0002-4459-6673>

References

1. Bottino R, Knoll MF, Knoll CA, Bertera S, Trucco MM. The future of islet transplantation is now. *Front Med (Lausanne)*. 2018;5:202.
2. Ricordi C, Goldstein JS, Balamurugan AN, Szot GL, Kin T, Liu C, Czarniecki CW, Barbaro B, Bridges ND, Cano J, Clarke WR, et al. National Institutes of Health-sponsored clinical islet transplantation consortium phase 3 trial: manufacture of a complex cellular product at eight processing facilities. *Diabetes*. 2016;65(11):3418–3428.
3. Balamurugan AN, Chang Y, Bertera S, Sands A, Shankar V, Trucco M, Bottino R. Suitability of human juvenile pancreatic islets for clinical use. *Diabetologia*. 2006;49(8):1845–1854.
4. Wang LJ, Kin T, O’Gorman D, Shapiro AMJ, Naziruddin B, Takita M, Levy MF, Posselt AM, Szot GL, Savari O, Barbaro B, et al. A multicenter study: North American islet donor score in donor pancreas selection for human islet isolation for transplantation. *Cell Transplant*. 2016;25(8):1515–1523.
5. Gołębiewska JE, Bachul PJ, Wang LJ, Matosz S, Basto L, Kijek MR, Fillman N, Gołęb K, Tibudan M, Dębska-Ślizień A, Millis JM, et al. Validation of a new North American islet donor score for donor pancreas selection and successful islet isolation in a medium-volume islet transplant center. *Cell Transplant*. 2019;28(2):185–194.
6. NIH CIT Consortium Chemistry Manufacturing Controls Monitoring Committee, NIH CIT Consortium. Purified human pancreatic islets, CIT purification density gradients: a standard operating procedure of the NIH clinical islet transplantation consortium. *CellR4 Repair Replace Regen Reprogram*. 2014;2(3):e991.
7. NIH CIT Consortium Chemistry Manufacturing Controls Monitoring Committee, NIH CIT Consortium. Purified human pancreatic islets CIT enzyme solution roche enzymes: standard operating procedure of the NIH clinical islet transplantation consortium. *CellR4 Repair Replace Regen Reprogram*. 2015;3(1):e1360.
8. NIH CIT Consortium Chemistry Manufacturing Controls Monitoring Committee, NIH CIT Consortium. Purified human pancreatic islets, CIT purification solution: a standard operating procedure of the NIH clinical islet transplantation consortium. *CellR4 Repair Replace Regen Reprogram*. 2014;2(3):e993.

9. NIH CIT Consortium Chemistry Manufacturing Controls Monitoring Committee, NIH CIT Consortium. Purified human pancreatic islets, CIT transplant wash media: a standard operating procedure of the NIH clinical islet transplantation consortium. *CellR4 Repair Replace Regen Reprogram*. 2014;2(3):e987.
10. NIH CIT Consortium Chemistry Manufacturing Controls Monitoring Committee, NIH CIT Consortium. Purified human pancreatic islets, CIT culture media: a standard operating procedure of the NIH clinical islet transplantation consortium. *CellR4 Repair Replace Regen Reprogram*. 2014;2(3):e981.
11. NIH CIT Consortium Chemistry Manufacturing Controls Monitoring Committee, NIH CIT Consortium. Purified human pancreatic islets (PHPI) master production batch record: a standard operating procedure of the NIH clinical islet transplantation consortium. *CellR4 Repair Replace Regen Reprogram*. 2014;2(2):e891.
12. NIH CIT Consortium Chemistry Manufacturing Controls Monitoring Committee, NIH CIT Consortium. Purified human pancreatic islets, CIT digestion solution: a standard operating procedure of the NIH clinical islet transplantation consortium. *CellR4 Repair Replace Regen Reprogram*. 2014;2(3):e985.
13. Bennet W, Groth CG, Larsson R, Nilsson B, Korsgren O. Isolated human islets trigger an instant blood mediated inflammatory reaction: implications for intraportal islet transplantation as a treatment for patients with type 1 diabetes. *Ups J Med Sci*. 2000;105(2):125–133.
14. Rickels MR, Stock PG, de Koning EJP, Piemonti L, Pratschke J, Alejandro R, Bellin MD, Berney T, Choudhary P, Johnson PR, Kandaswamy R, et al. Defining outcomes for β -cell replacement therapy in the treatment of diabetes: a consensus report on the Igl criteria from the IPITA/EPITA opinion leaders workshop. *Transpl Int*. 2018;31(4):343–352.
15. Soggi C, Davalli AM, Vignali A, Vignali A, Pontiroli AE, Maffi P, Magistretti P, Gavazzi F, De Nittis P, Di Carlo V, Pozza G. A significant increase of islet yield by early injection of collagenase into the pancreatic duct of young donors. *Transplantation*. 1993;55(3):661–663.
16. Shimoda M, Noguchi H, Naziruddin B, Fujita Y, Chujo D, Takita M, Peng H, Tamura Y, Olsen GS, Sugimoto K, Itoh T, et al. Improved method of human islet isolation for young donors. *Transplant Proc*. 2010;42(6):2024–2026.
17. Loganathan G, Subhashree V, Narayanan S, Tweed B, Andrew Goedde M, Gunaratnam B, Tucker WW, Goli P, Mokshagundam S, McCarthy RC, Williams SK, et al. Improved recovery of human islets from young donor pancreases utilizing increased protease dose to collagenase for digesting peri-islet extracellular matrix. *Am J Transplant*. 2019;19(3):831–843.
18. Buitrago A, Gylfe E, Henriksson Ch, Hgkan P. Rapid isolation of pancreatic islets from collagenase digested pancreas by sedimentation through Percoll at unit gravity. *Biochem Biophys Res Commun*. 1977;79(3):823–828.
19. Ramirez-Dominguez M, Castaño L. Filtration is a time-efficient option to Histopaque, providing good quality islets in mouse islet isolation. *Cytotechnology*. 2015;67(2):199–206.
20. Brunicaudi F, Suh E, Castro D, Mullen Y, Kleinman R. Selective photodynamic laser treatment of dispersed pancreatic tissue for islet isolation. *Transplant Proc*. 1992;24(6):2796–2797.
21. Nason R, Rajotte V, Procyshyn A, Pedersen JE. Purification of pancreatic islet cell grafts with radiation. *Transplant Proc*. 1986;18(1):174–181.
22. Shimoda M, Itoh T, Sugimoto K, Takita M, Chujo D, Iwahashi S, SoRelle JA, Naziruddin B, Levy MF, Grayburn PA, Matsumoto S. An effective method to release human islets from surrounding acinar cells with agitation in high osmolality solution. *Transplant Proc*. 2011;43(9):3161–3166.
23. Taylor M, Baicu S. Cryo-isolation: a novel new method for enzyme-free isolation of pancreatic islets involving in situ cryopreservation of islets and selective destruction of acinar tissue. *Cryobiology*. 2011;3(63):331.
24. Jiao L, Gray D, Gohde W, Flynn G, Morris P. *In vitro* staining of islets of Langerhans for fluorescence activated cell sorting. *Transplantation*. 1991;52(3):450–452.
25. Ramirez-Dominguez M. Historical background of pancreatic islet isolation. *Adv Exp Med Biol*. 2016;938:1–9.
26. Miki A, Ricordi C, Messinger S, Yamamoto T, Mita A, Barker S, Haetter R, Khan A, Alejandro R, Ichii H. Toward improving human islet isolation from younger donors: rescue purification is efficient for trapped islets. *Cell Transplant*. 2009;18(1):13–22.
27. Eckhard M, Brandhorst D, Brandhorst H, Brendel M D, Bretzel RG. Optimization in osmolality and range of density of a continuous ficoll-sodium-diatrizoate gradient for isopycnic purification of isolated human islets. *Transplant Proc*. 2004;36(9):2849–2854.
28. Ichii H, Pileggi A, Molano RD, Baidal DA, Khan A, Kuroda Y, Inverardi L, Goss JA, Alejandro R, Ricordi C. Rescue purification maximizes the use of human islet preparations for transplantation. *Am J Transplant*. 2005;5(1):21–30.
29. Noguchi H, Ikemoto T, Naziruddin B, Jackson A, Shimoda M, Fujita Y, Chujo D, Takita M, Kobayashi N, Onaca N, Levy MF. Iodixanol-controlled density gradient during islet purification improves recovery rate in human islet isolation. *Transplantation*. 2009;87(11):1629–1635.
30. Casey JJ, Lakey JR, Ryan EA, Paty BW, Owen R, O’Kelly K, Nanji S, Rajotte RV, Korbitt GS, Bigam D, Kneteman NN, et al. Portal venous pressure changes after sequential clinical islet transplantation. *Transplantation*. 2002;74(7):913–915.
31. Lakey JR, Burridge PW, Shapiro AM. Technical aspects of islet preparation and transplantation. *Transpl Int*. 2003;16(9):613–632.
32. Loganathan G, Dawra RK, Pugazhenth S, Guo Z, Soltani SM, Wiseman A, Sanders MA, Papas KK, Velayutham K, Saluja AK, Sutherland DE, et al. Insulin degradation by acinar cell proteases creates a dysfunctional environment for human islets before/after transplantation: benefits of α -1 antitrypsin treatment. *Transplantation*. 2011;92(11):1222–1230.
33. Ling Z, De Pauw P, Jacobs-Tulleneers-Thevissen D, Mao R, Gillard P, Hampe CS, Martens GA, In’t Veld P, Lernmark Å, Keymeulen B, Gorus F, et al. Plasma GAD65, a marker for early β -cell loss after intraportal islet cell transplantation in

- diabetic patients. *J Clin Endocrinol Metab.* 2015;100(6):2314–2321.
34. Beuneu C, Vosters O, Movahedi B, Rimmelink M, Salmon I, Pipeleers D, Pradier O, Goldman M, Verhasselt V. Human pancreatic duct cells exert tissue factor-dependent procoagulant activity: relevance to islet transplantation. *Diabetes.* 2004;53(6):1407–1411.
35. Gray DW, Sutton R, McShane P, Peters M, Morris PJ. Exocrine contamination impairs implantation of pancreatic islets transplanted beneath the kidney capsule. *J Surg Res* 1988;45(5):432–442.
36. Heuser M, Wolf B, Vollmar B, Menger MD. Exocrine contamination of isolated islets of Langerhans deteriorates the process of revascularization after free transplantation. *Transplantation* 2000;69(5):756–761.
37. Marín-Cañas S, Estil Les E, Llado L, San José P, Nacher M, Téllez N, Montanya E. Pancreatic ductal cells may have a negative effect on human islet transplantation. *PLoS One.* 2019;14(7):e0220064.
38. Murray HE, Paget MB, Bailey CJ, Downing R. Sustained insulin secretory response in human islets co-cultured with pancreatic duct-derived epithelial cells within a rotational cell culture system. *Diabetologia.* 2009;52(3):477–485.
39. Webb MA, Dennison AR, James RF. The potential benefit of non-purified islets preparations for islet transplantation. *Bio-technol Genet Eng Rev.* 2012;28(1):101–114.
40. Benomar K, Chetboun M, Espiard S, Jannin A, Le Mapihan K, Gmyr V, Caiazzo R, Torres F, Raverdy V, Bonner C, D’Herbomez M, et al. Purity of islet preparations and 5-year metabolic outcome of allogenic islet transplantation. *Am J Transplant.* 2018;18(4):945–951.
41. Jaeger C, Hering BJ, Hatziagelaki E, Federlin K, Bretzel RG. Glutamic acid decarboxylase antibodies are more frequent than islet cell antibodies in islet transplanted IDDM patients and persist or occur despite immunosuppression. *J Mol Med Berl Ger.* 1999;77(1):45–48.
42. Bosi E, Braghi S, Maffi P, Scirpoli M, Bertuzzi F, Pozza G, Secchi A, Bonifacio E. Autoantibody response to islet transplantation in type 1 diabetes. *Diabetes.* 2001;50(11):2464–2471.
43. Ricordi C, Japour A. Transplanting islet cells can fix brittle diabetes. Why isn’t it available in the U.S.? *STAT,* 2019, August 21. Online article, Boston Globe Media.